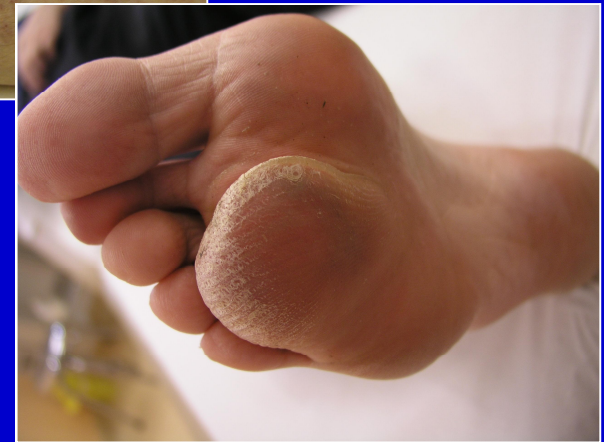
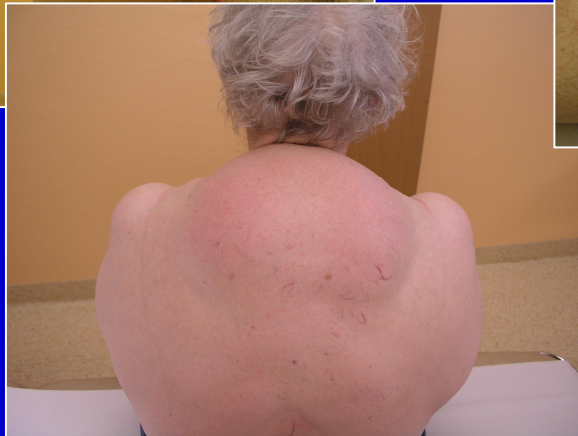
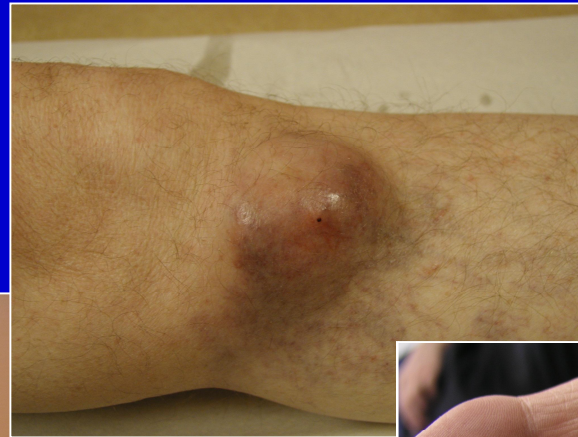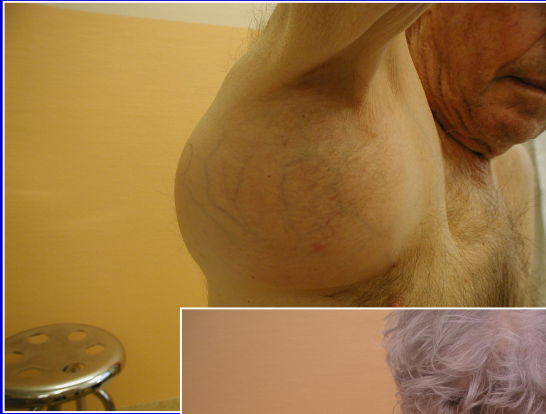# POSITION OF FNAC IN THE ANALYSIS OF SOFT TISSUE TUMORS



IAP- Finish Division  
May 6-7, 2010

Henryk. A. Domanski,  
University and Regional Laboratories Region Skåne , Department of Pathology  
Lund, Sweden

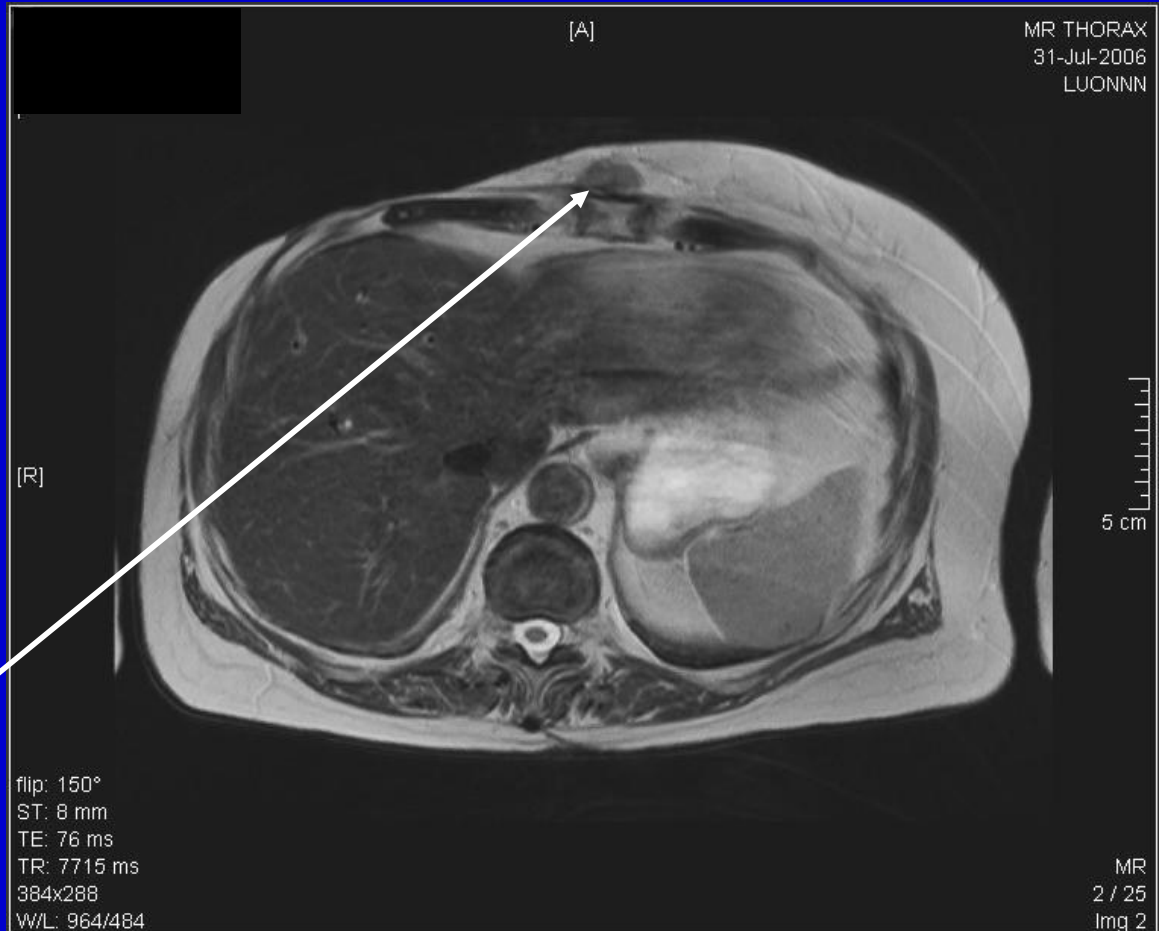
- ✓ FNAC of soft tissue lesions- Lund experience
- ✓ Practical approach for FNAC of soft tissue neoplasm:
  - ✓ Examples
  - ✓ Complications

# FNAC in the examination of soft tissue

- FNAC of recurrent sarcomas and metastatic soft tissue sarcomas (generally accepted)

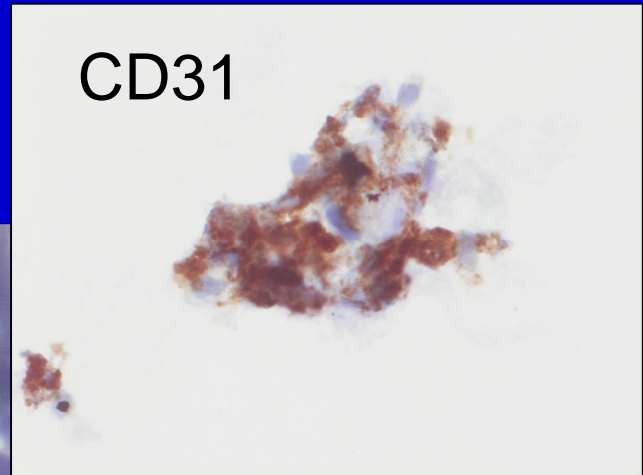
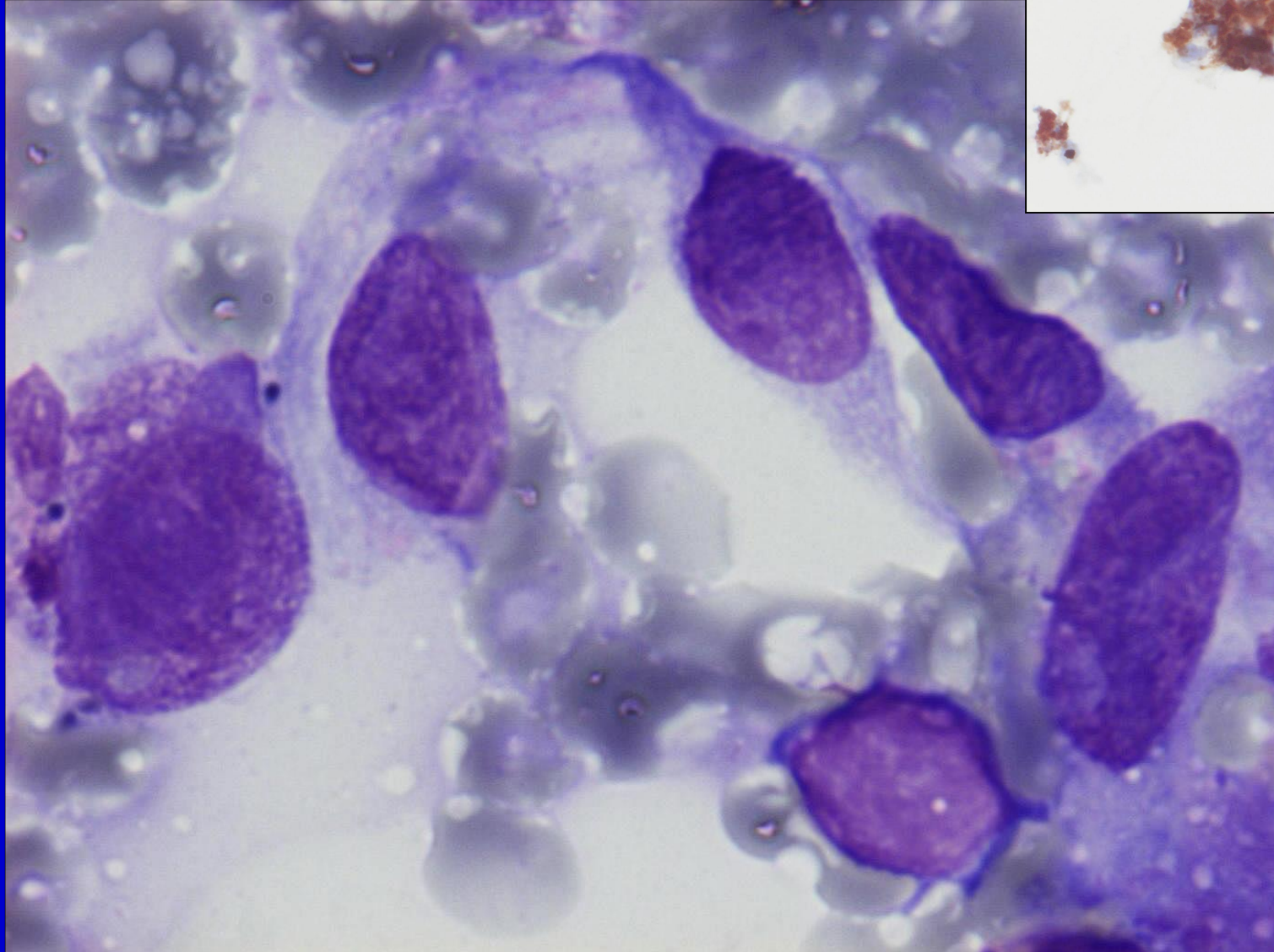
# Clinical history

- A 73-year-old woman with history of breast carcinoma 1995 - treated by mastectomy and radiation;
- 2004- surgical excision of radiation induced angiosarcoma
- August 2006 - 2,5 cm subcutaneous mass in the chest wall





# FNAC: recurrent angiosarcoma



# FNAC in the examination of soft tissue

- FNAC of primary soft tissue masses (increasing acceptance by clinicians and pathologists)

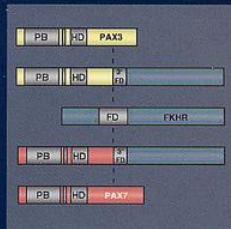
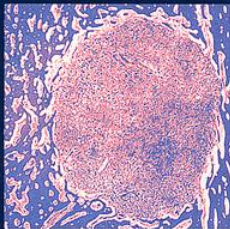
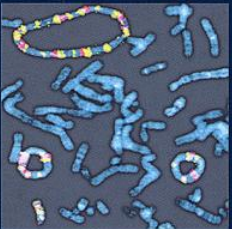
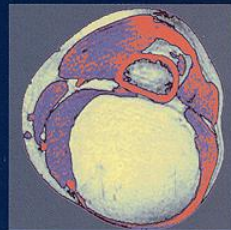
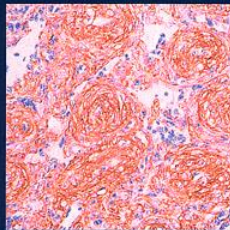
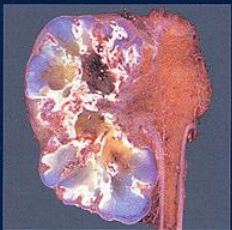World Health Organization Classification of Tumours



## Pathology & Genetics

### Tumours of Soft Tissue and Bone

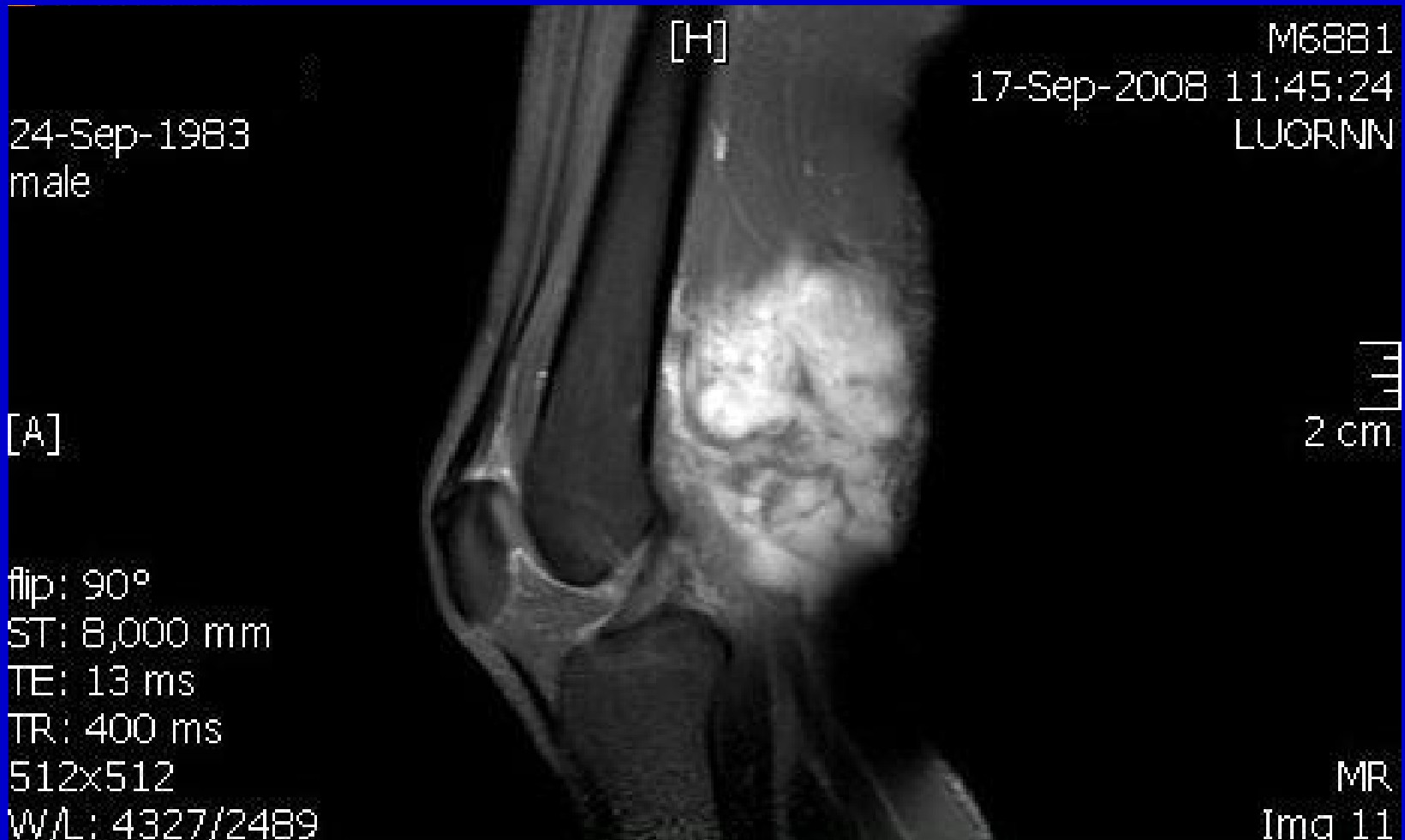Edited by Christopher D.M. Fletcher, K. Krishnan Unni, Fredrik Mertens



”Fine needle aspiration cytology is generally best limited to those centers with a high case volume and with a well-integrated multidisciplinary team, since careful clinico-radiologic correlation and considerable experience are required in order to make accurate diagnoses”

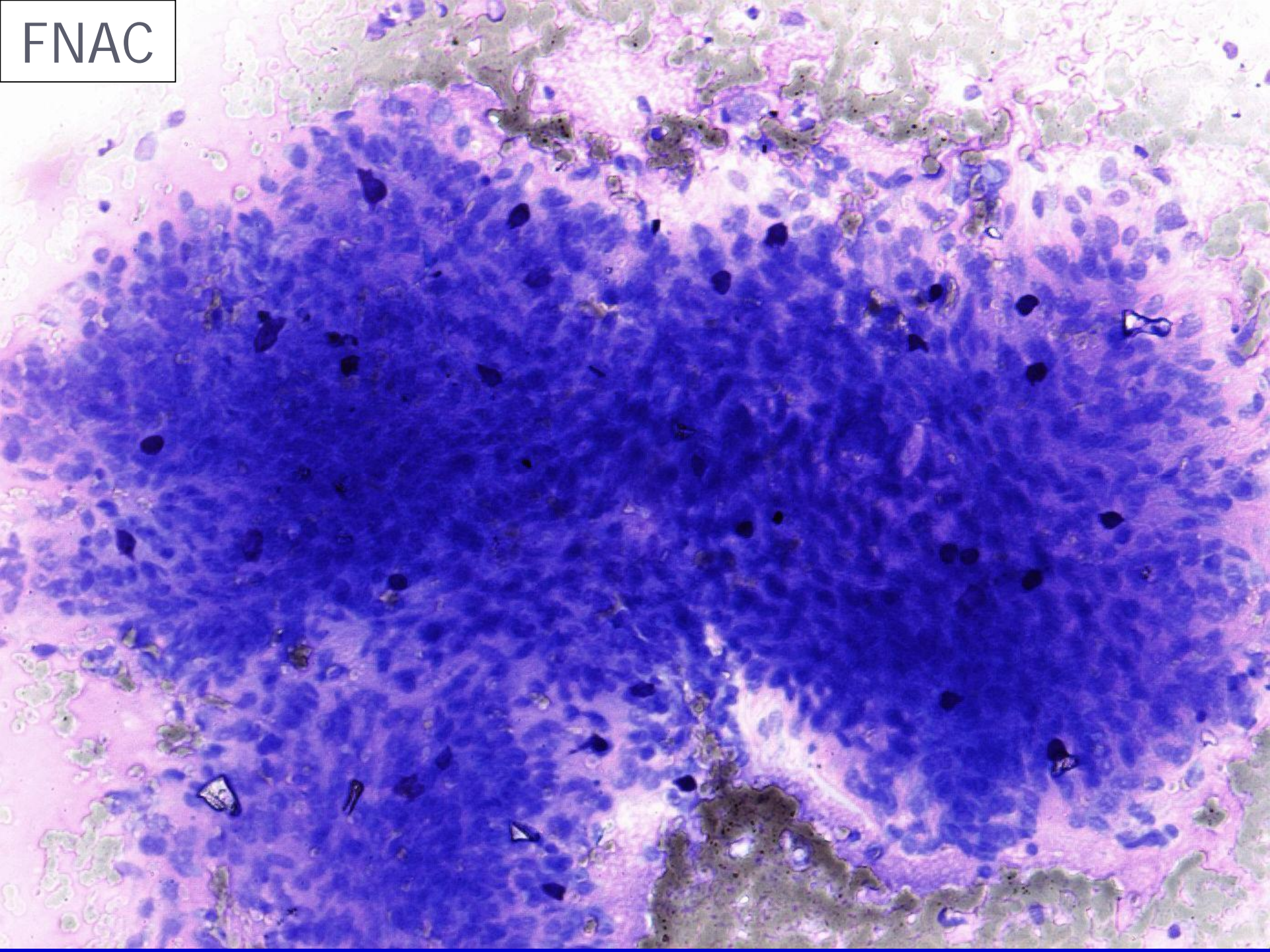
# Clinical history

- 25-year-old man
- 2 month history of a slowly growing mass in the left popliteal fossa



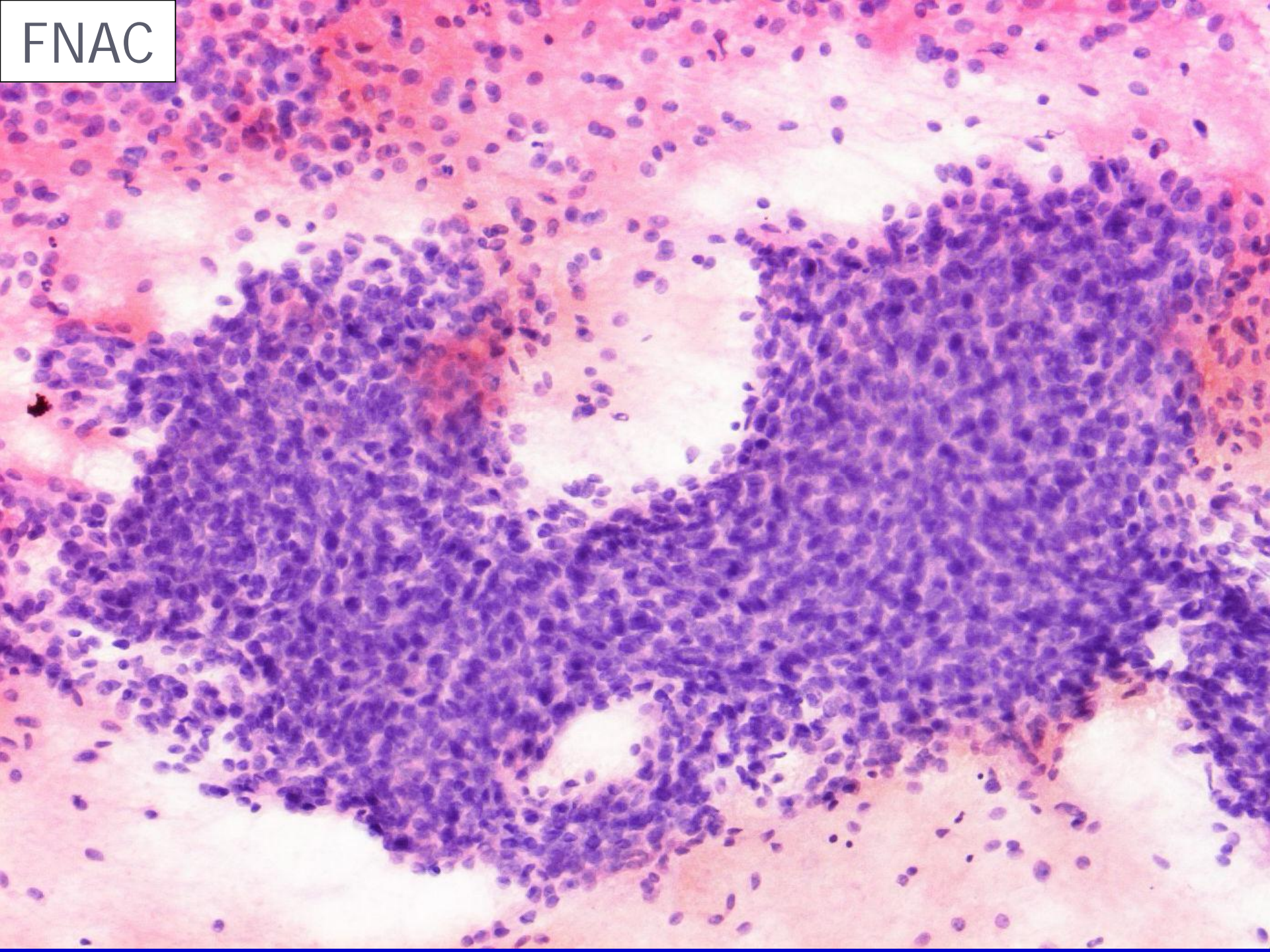


FNAC



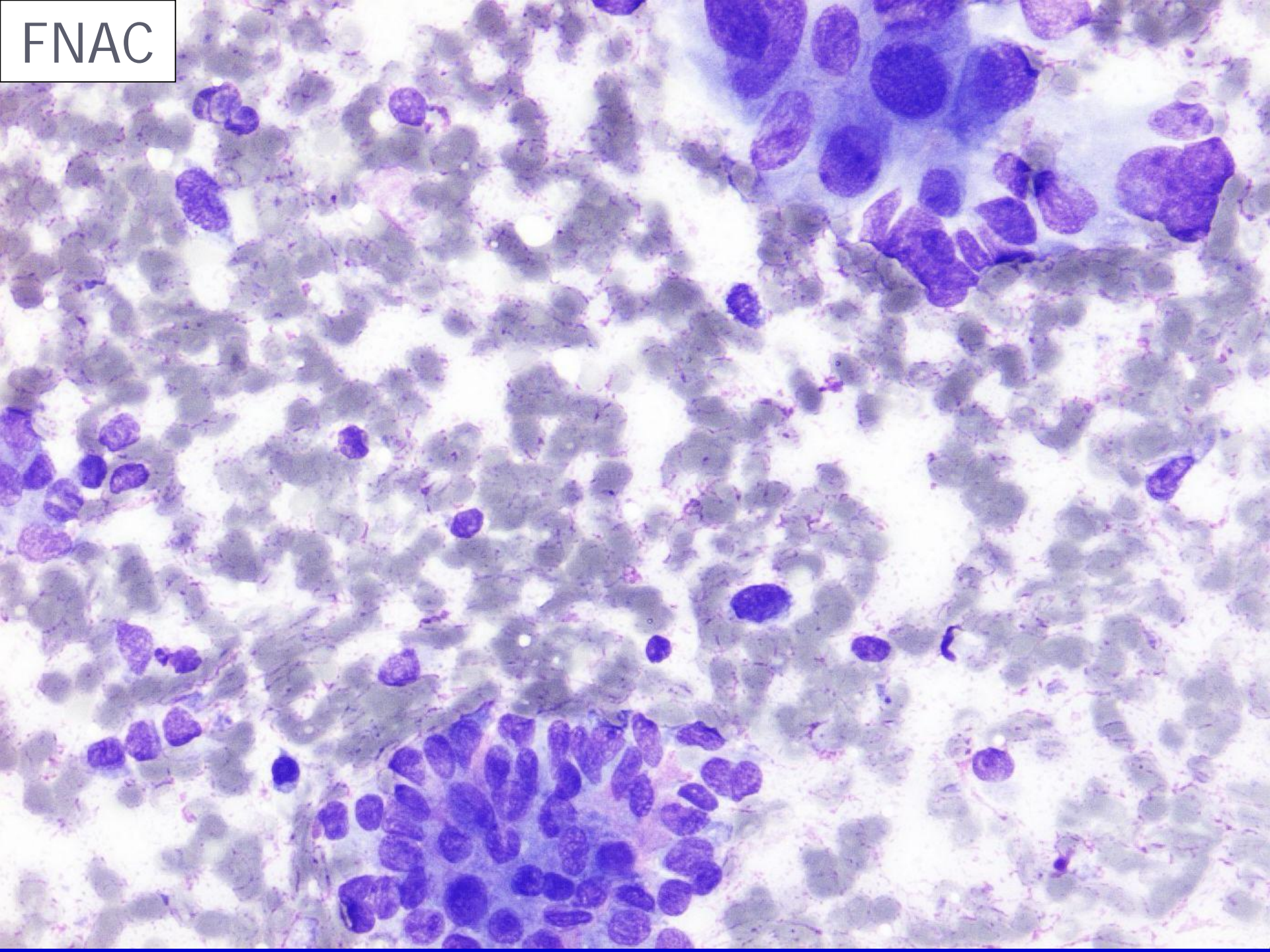


FNAC



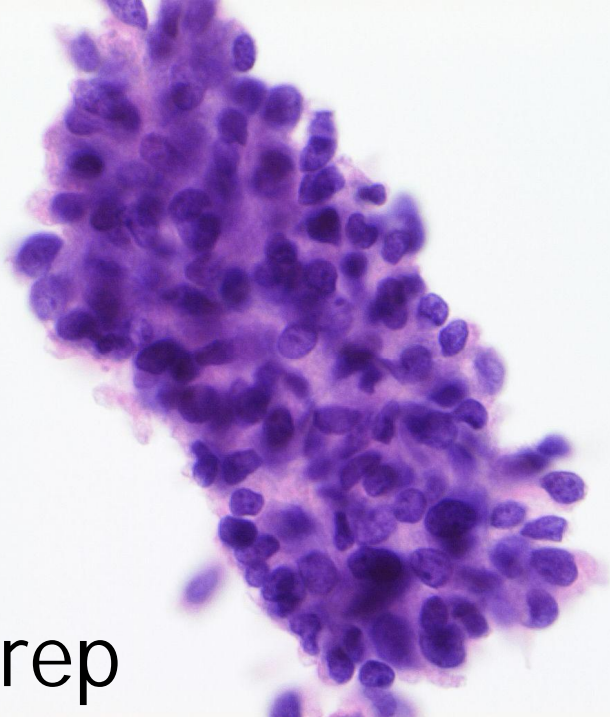


FNAC

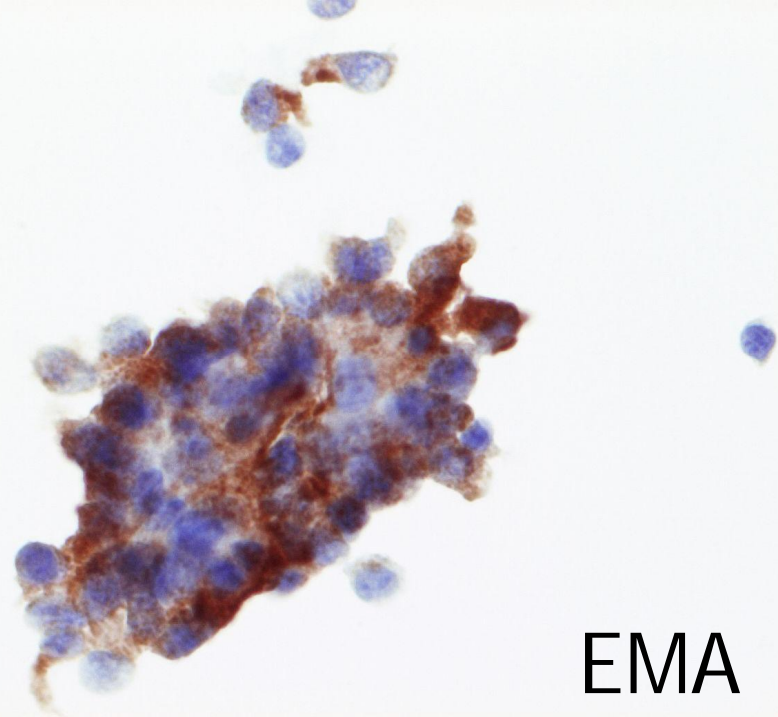




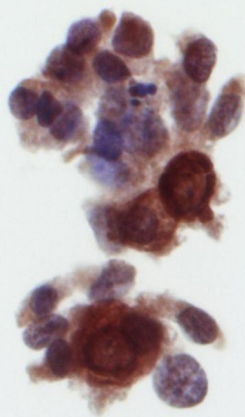
ThinPrep



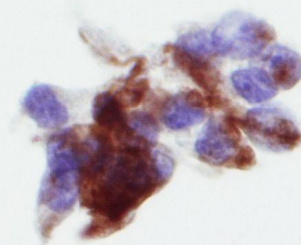
EMA



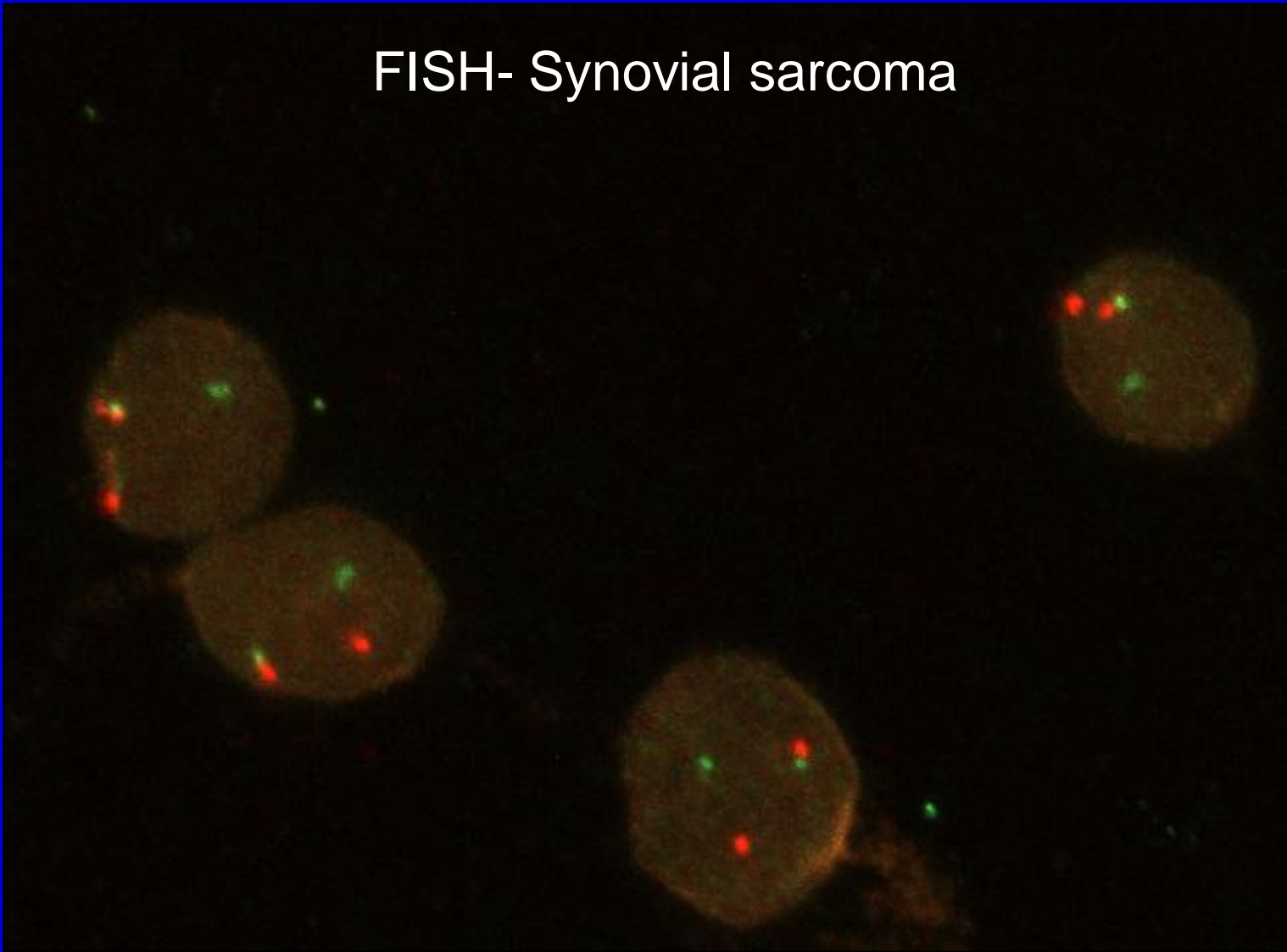
CK 19



CK 7



## FISH- Synovial sarcoma



- Separate red and green signals indicative of a rearrangement of one copy of the SYT gene region

# Why FNAC?

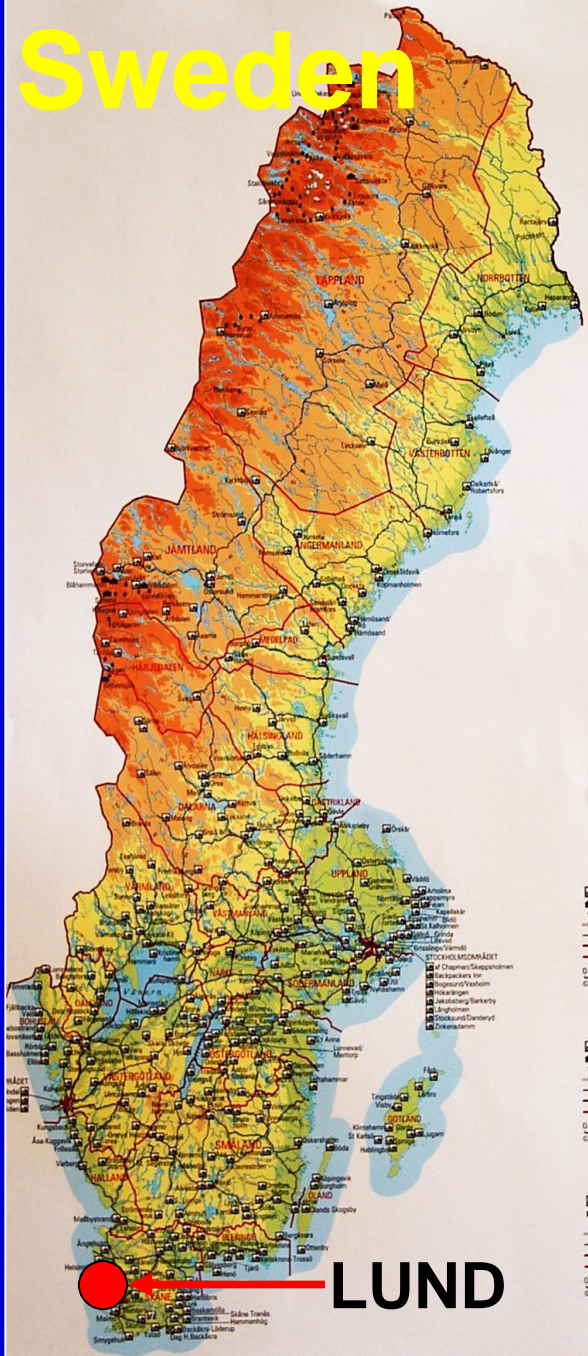- Outpatient procedure
- Does not interfere with subsequent treatment
- Low risk of complications
- Cost saving

# Disadvantages of FNAC

- Architecture lost
- FNAC samples suboptimal for ancillary studies.



# Sweden



# FNAC of soft tissue lesions

- Well proven technique in Lund since 1972
- Cytopathologist (most often) or radiologist

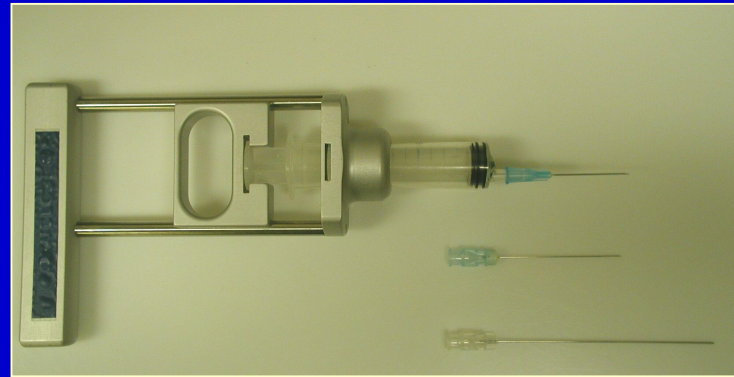
# Principles for tripple diagnostics

- Clinical examination
  - ✓ history
  - ✓ physical examination
  - ✓ blood tests
- Radiological examination
  - ✓ MR / CT / US
- Morphological examination
  - ✓ FNA or/and CNB
  - ✓ open biopsy

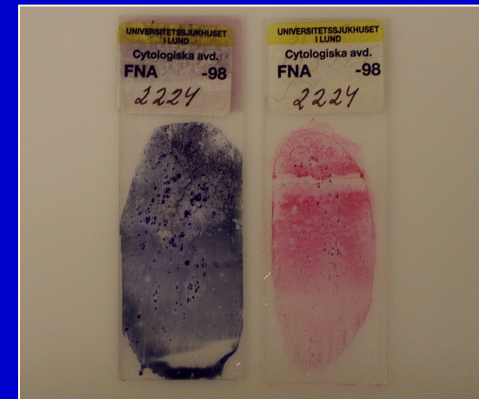

# Technique at the FNA clinic in Lund

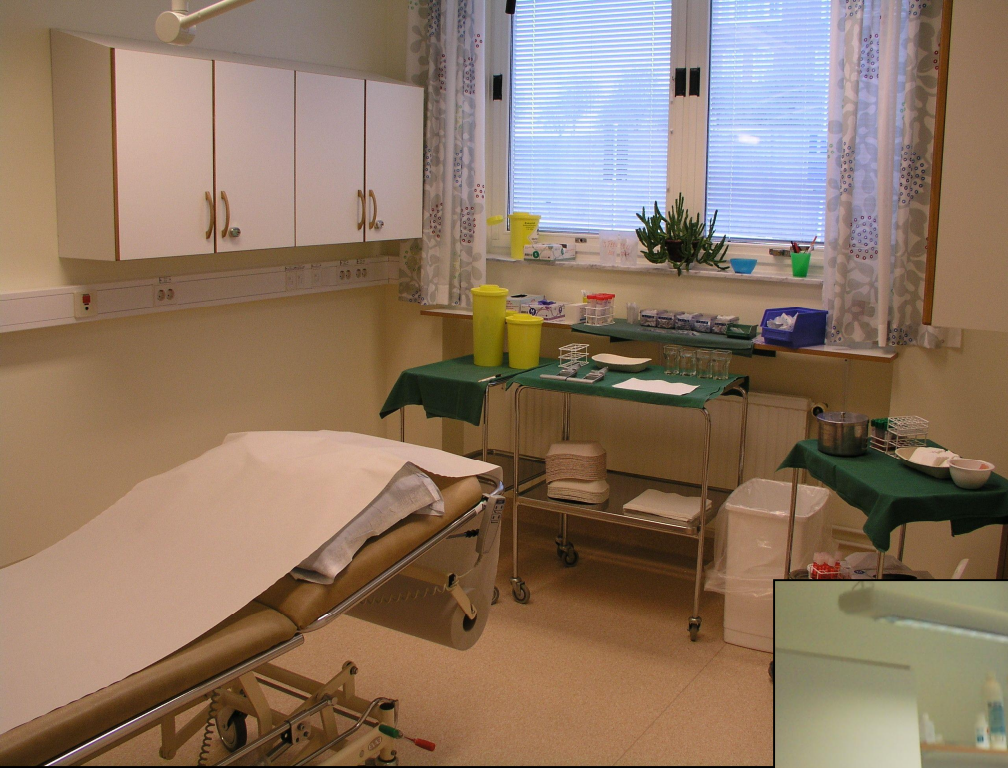- 2 to 3 passes, needles 0.4- 0.7mm



- Wet- fixed and air- dried smears, stained by DiffQuick, MGG and H&E



- If ancillary studies are needed, 1-3 additional passes are taken for CB and/or TP (immunostains), molecular genetics





# DiffQuick





Cytogenetic/ molecular genetic analysis

ThinPrep

Cell block

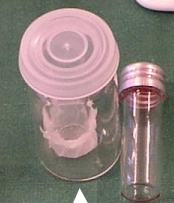
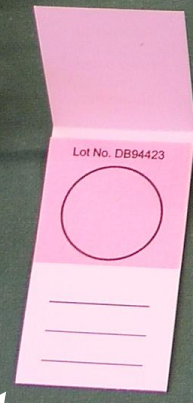
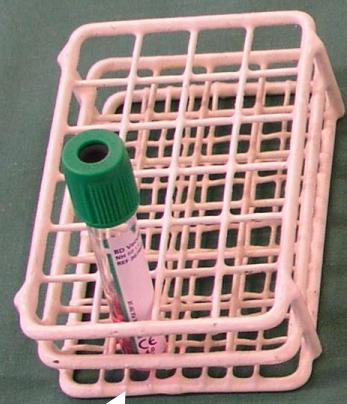
Hank's solution-  
Flow cytometry

Microcard-  
Multiplex PCR

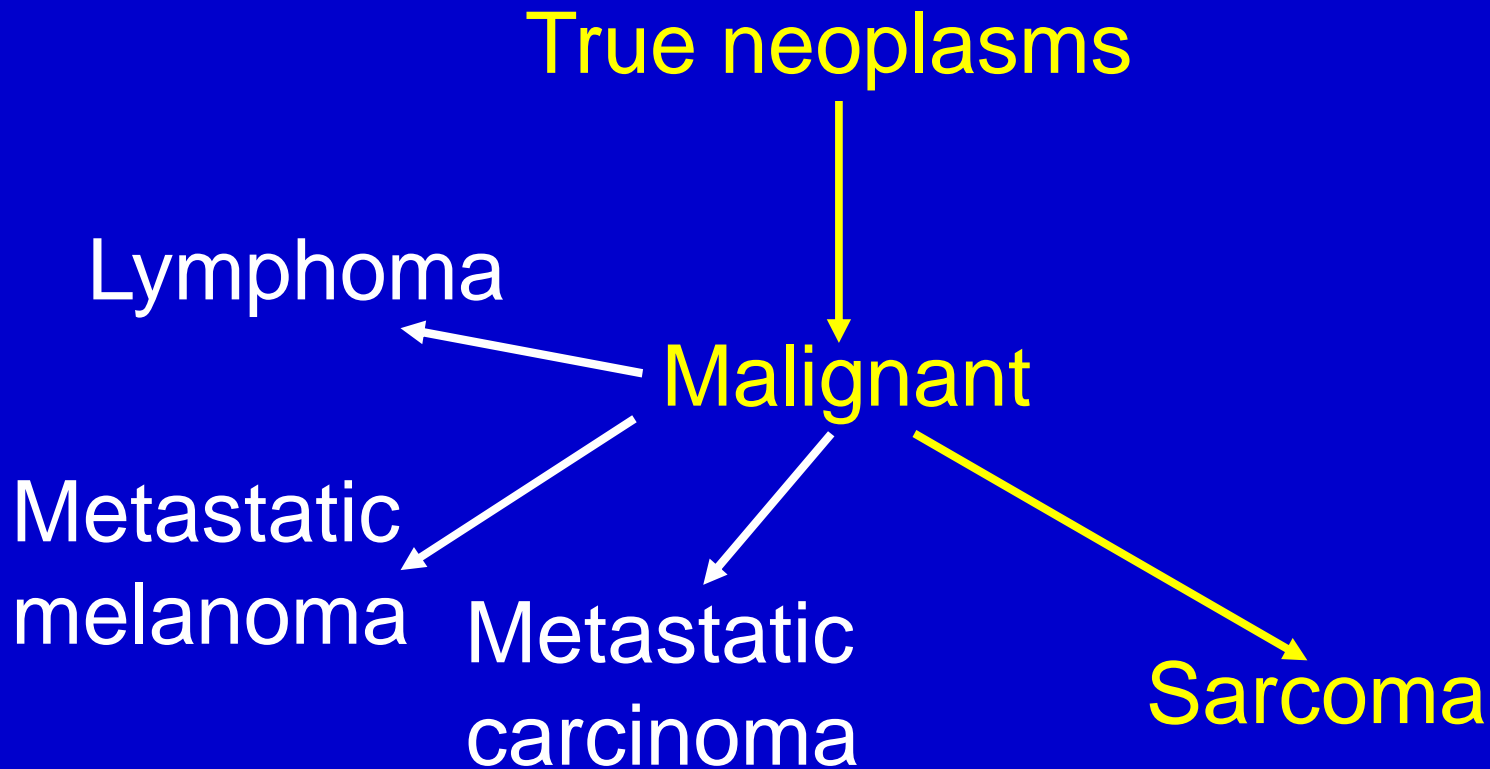
Electron microscopy

Culture

Ancillary techniques at the FNA clinic



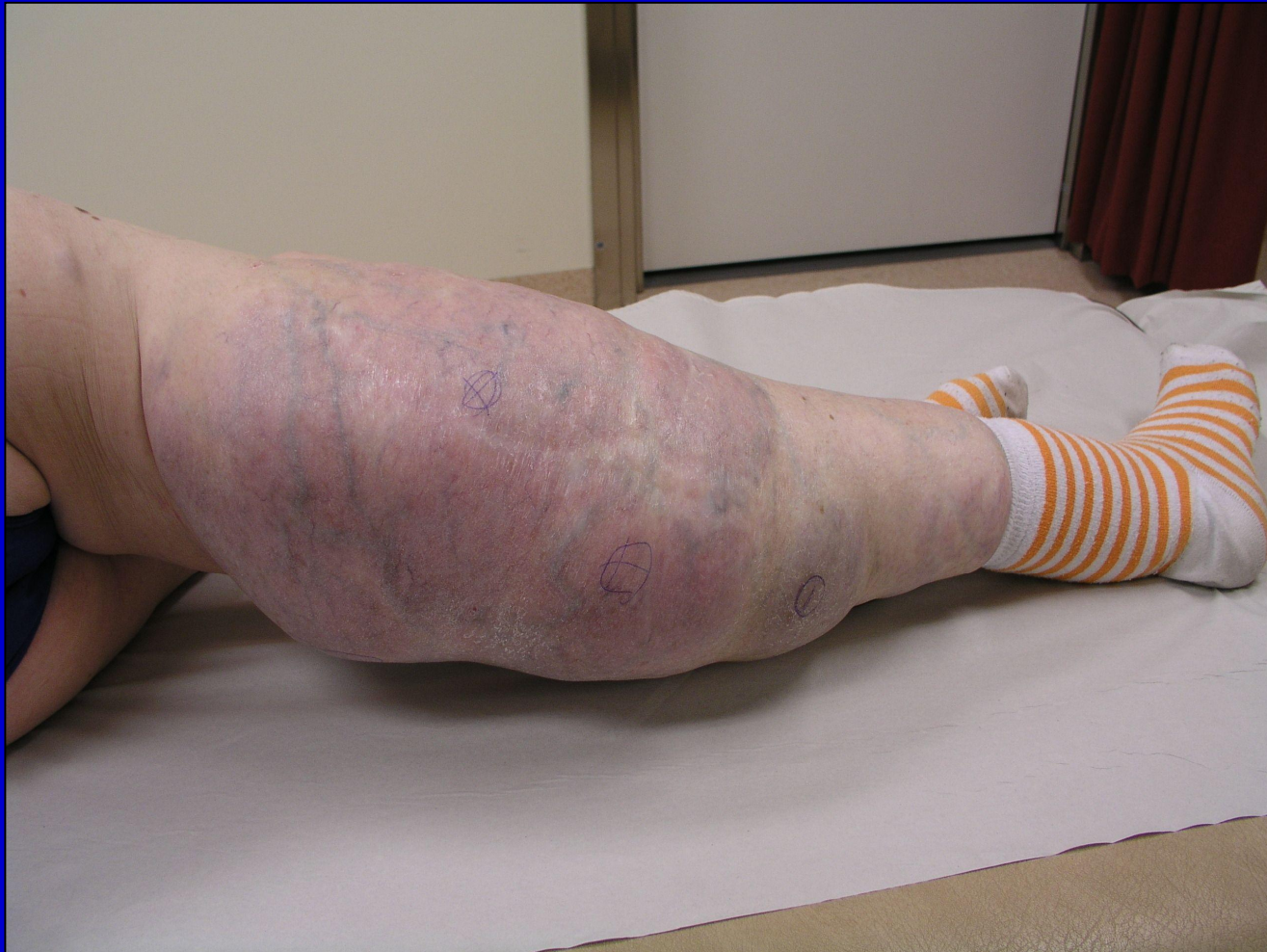# Work up of adult soft tissue sarcomas



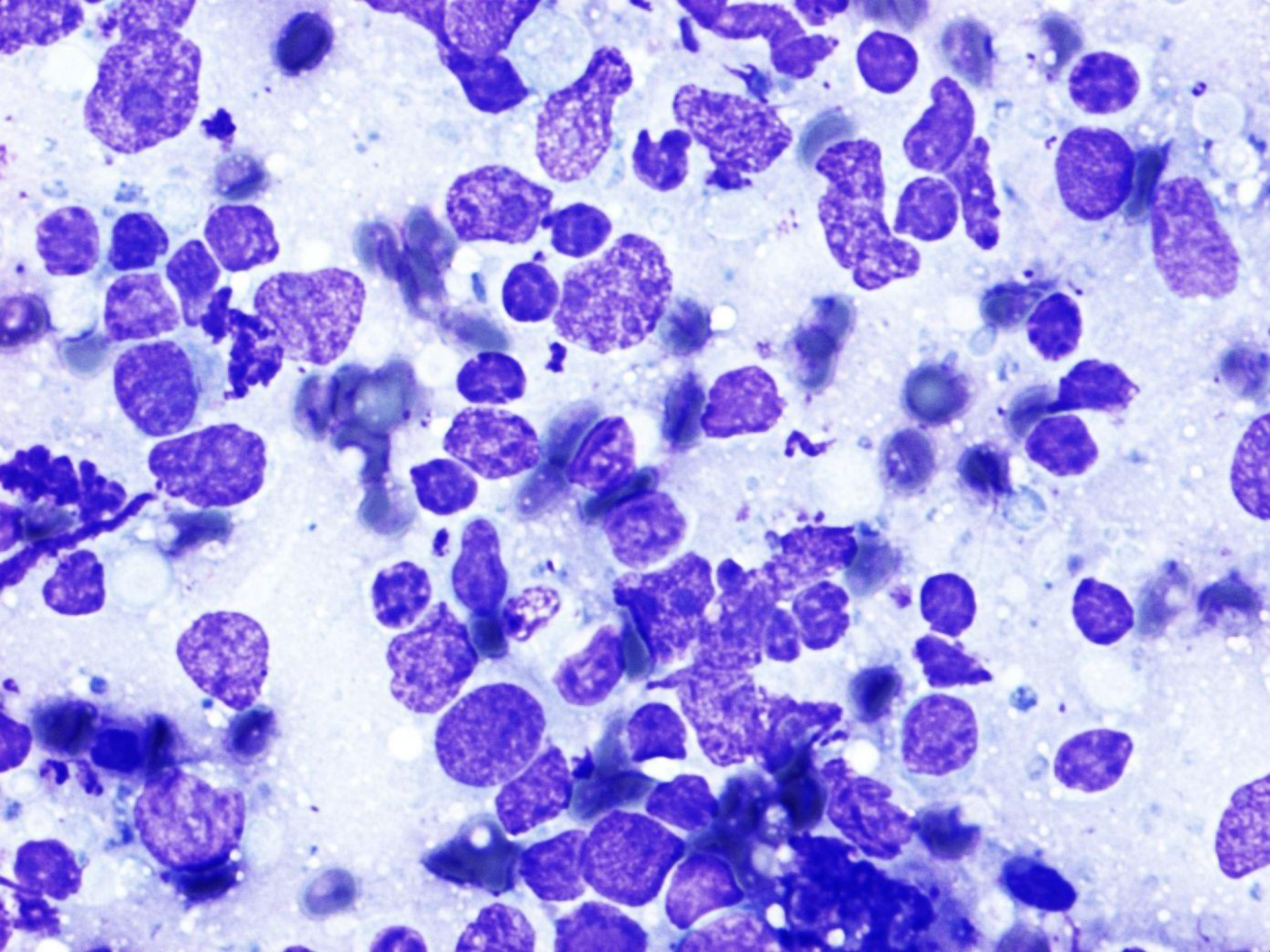


# Clinical history

- 79-year-old woman
- huge mass in the right groin and thigh
- clinical diagnosis: Sarcoma vs NHL

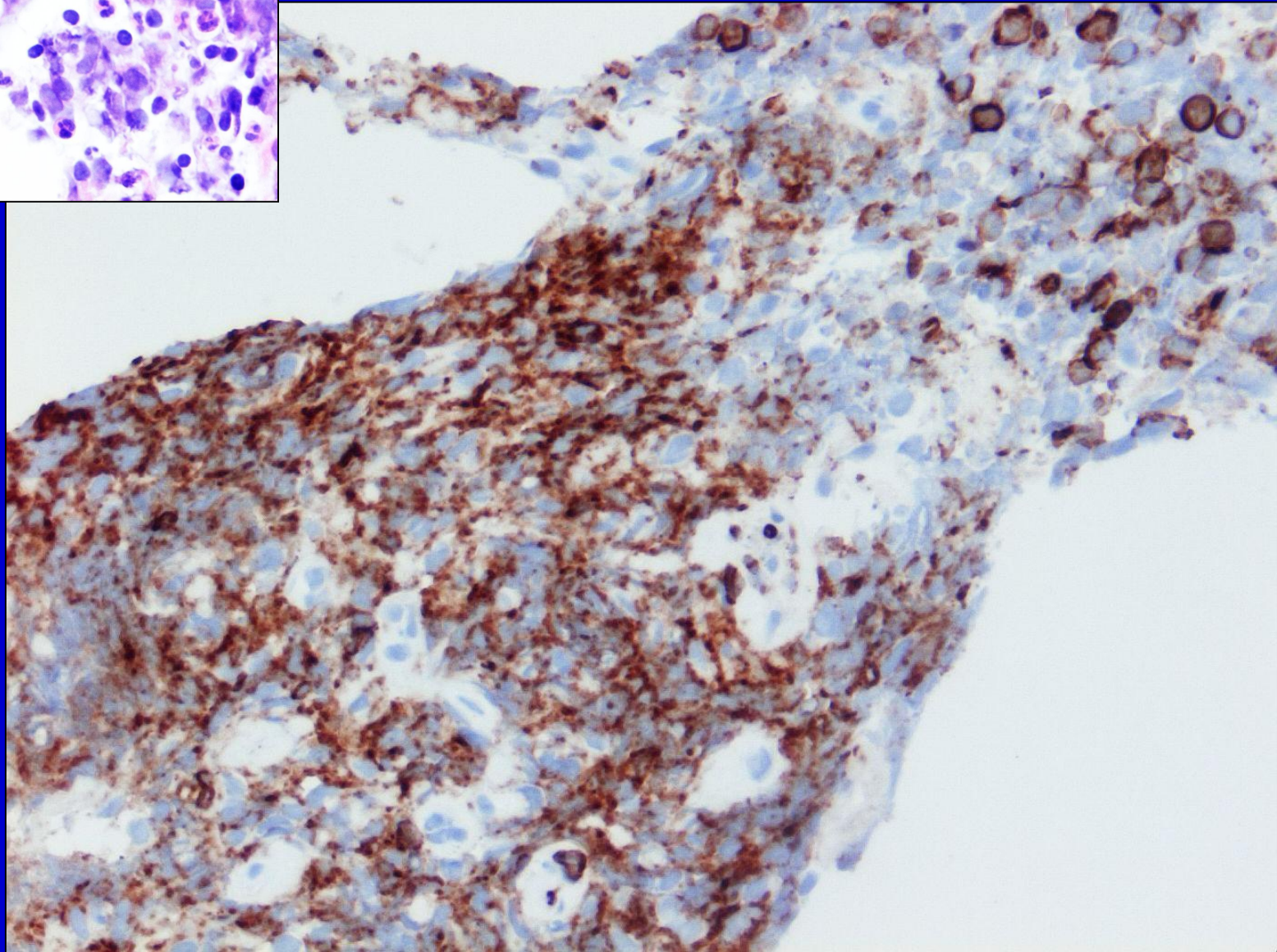
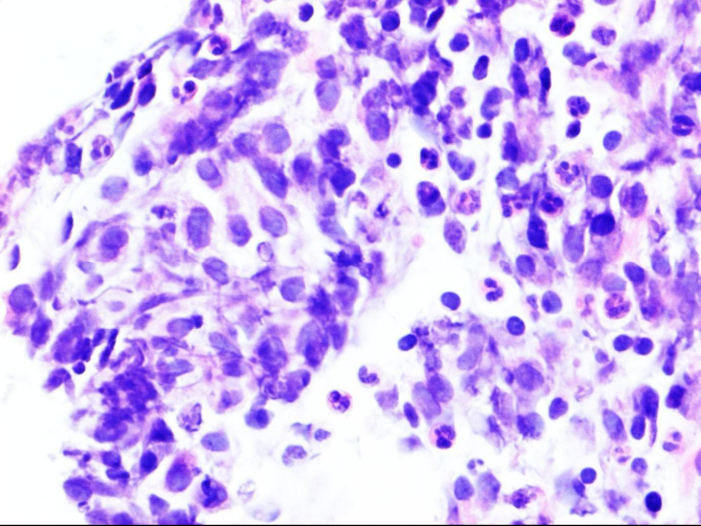








- Cell block: CD 45 (+) and
- Flow cytometry: NHL



# Treatment of most adult soft tissue sarcoma (regardless of type)

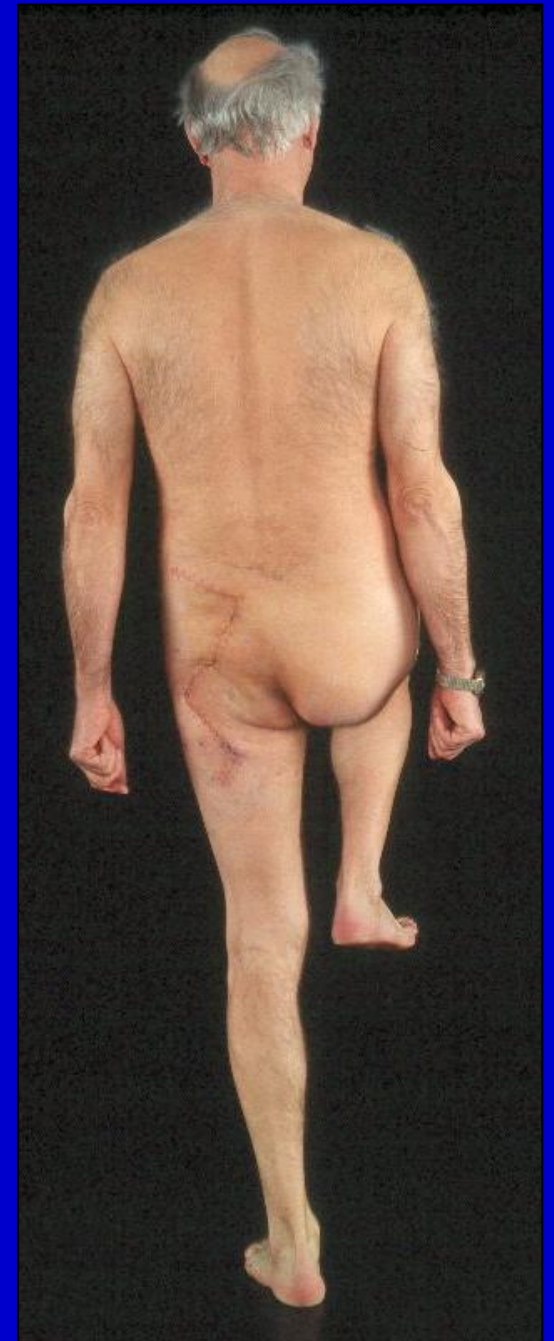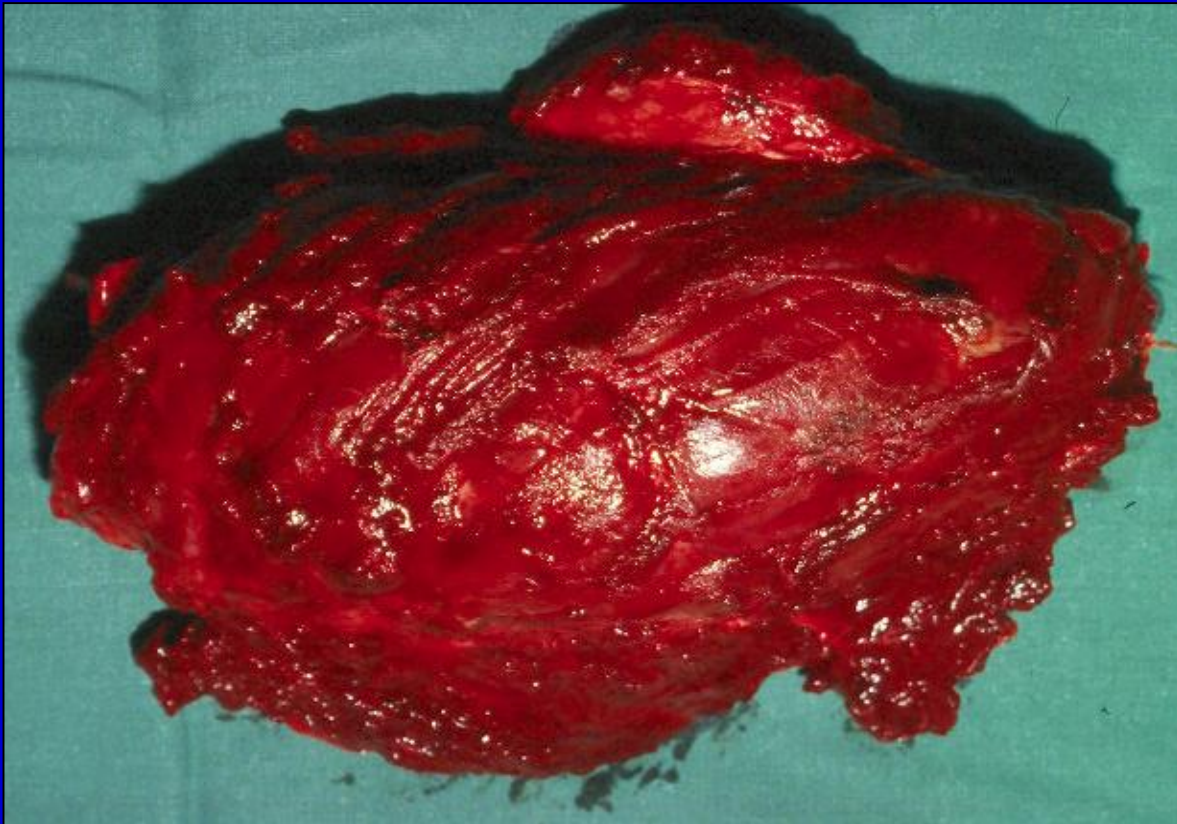
- surgical removal of tumor
- adjuvant radiotherapy
- adjuvant chemotherapy
- isolated extremity perfusion with TNF-alpha and melphalan

# Surgical treatment of adult soft tissue sarcomas

- The type of surgery which is chosen in the individual case depends on the size, the anatomical location and the relationship of the tumor to vital structures (vessels, nerves and bone)
- not the specific histologic diagnosis (!)



# Intramuscular soft tissue sarcoma, myectomy



# Treatment of most pediatric sarcomas but also some adult sarcomas

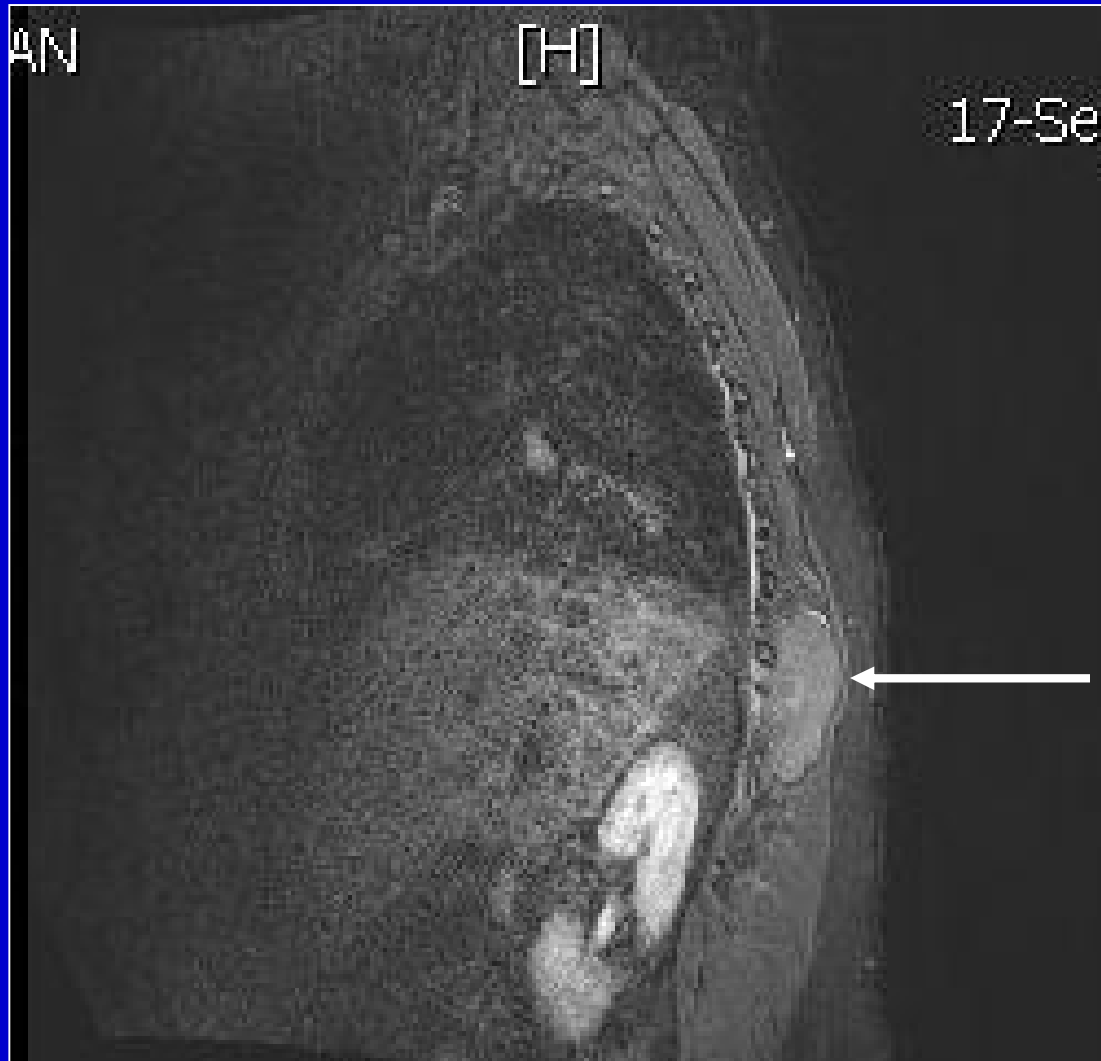
- Neoadjuvant chemotherapy:  
histogenetic-specific protocols !!!
- Surgery
- Adjuvant radiotherapy
- Adjuvant chemotherapy

# Benign soft tissue lesions

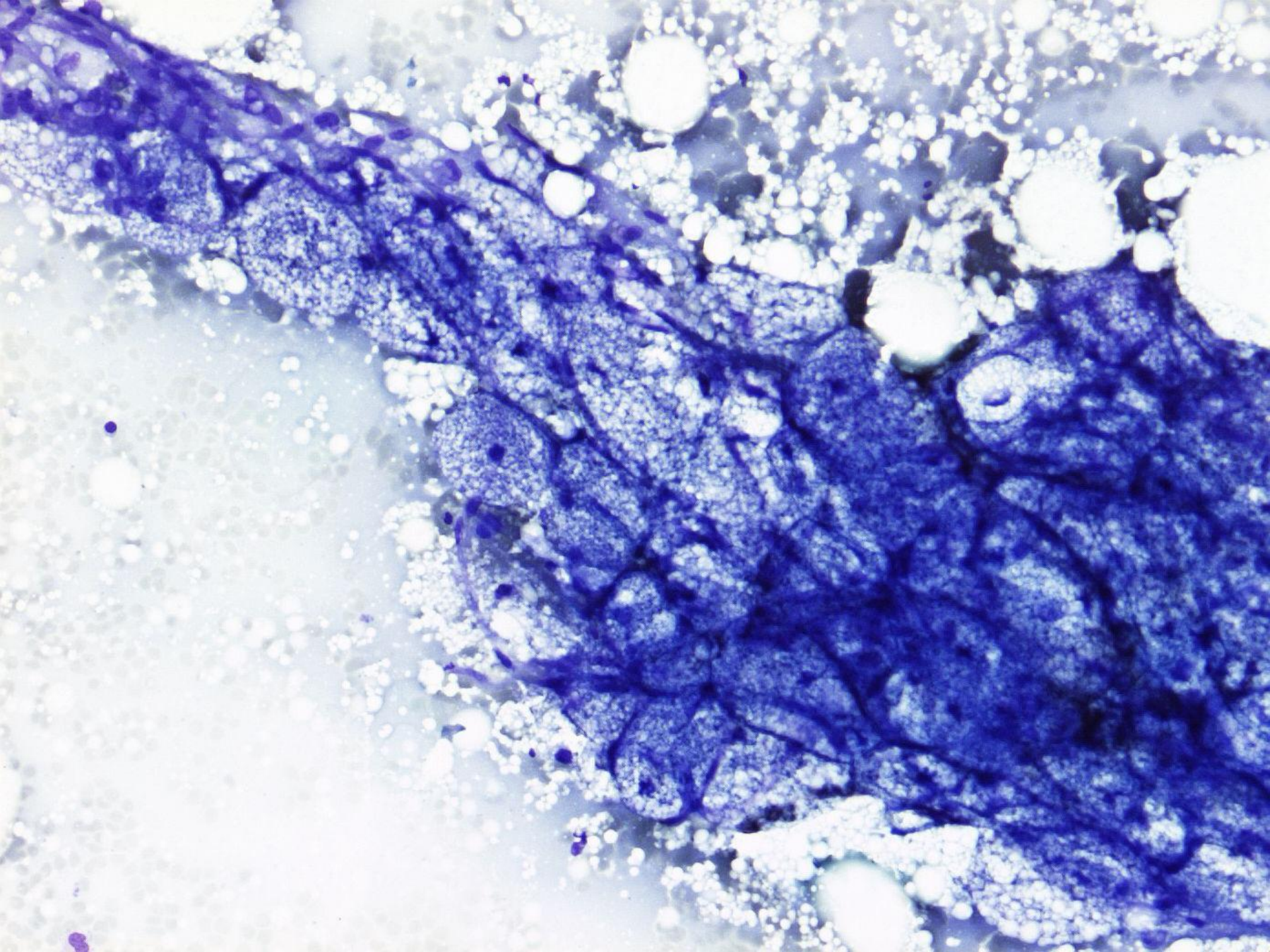
- Histologic diagnosis required
- Treatment not always required
- Surgery often simple and without sequelae

# Clinical History

- 42-year-old woman presented with a 6cm deep mass in the back

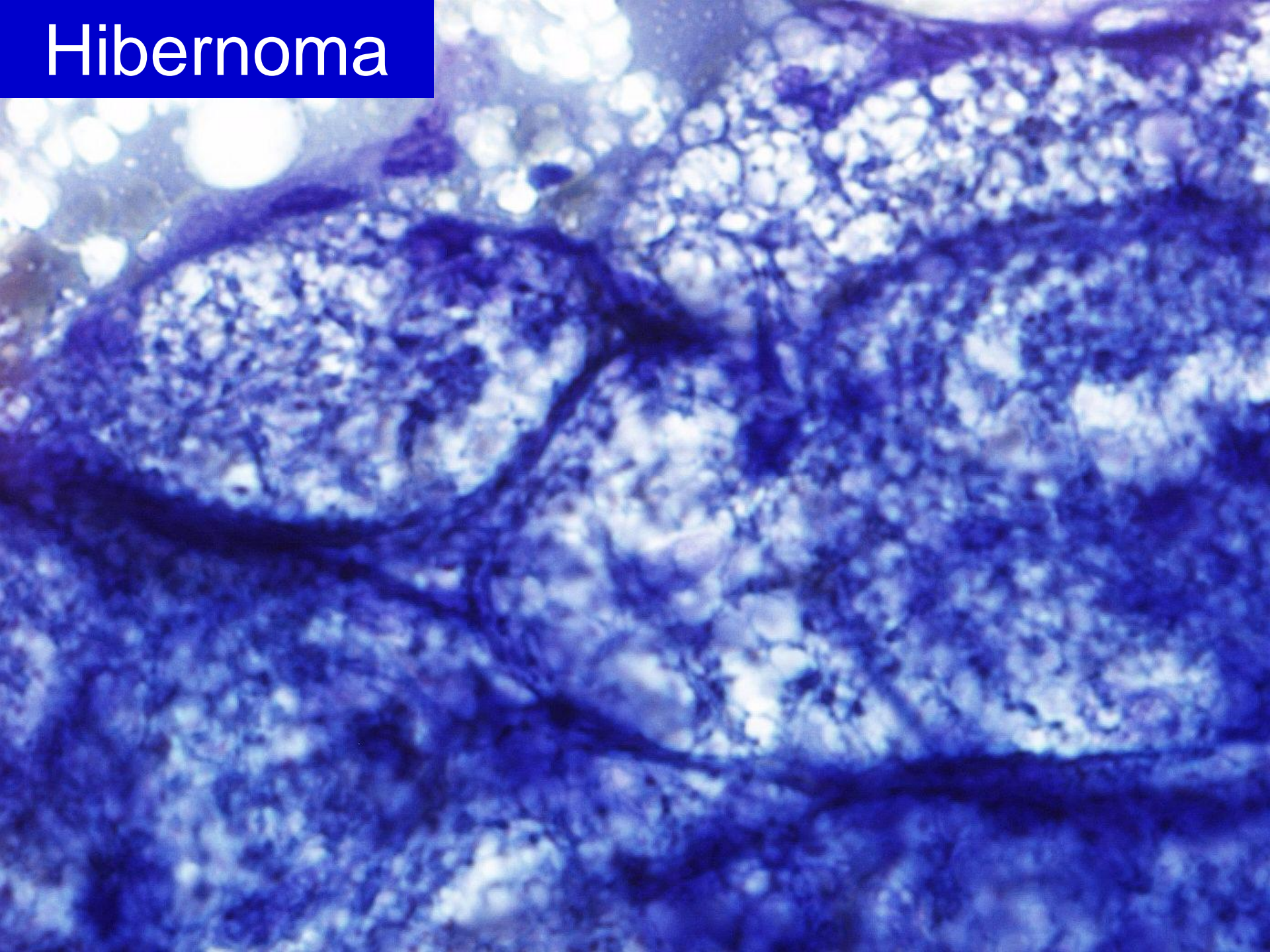






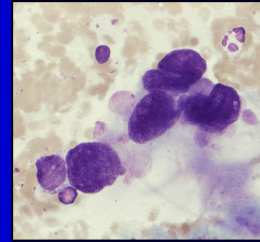


# Hibernoma

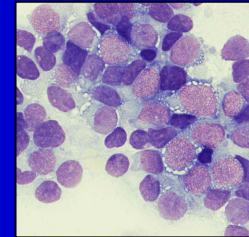


# SOFT TISSUE TUMORS

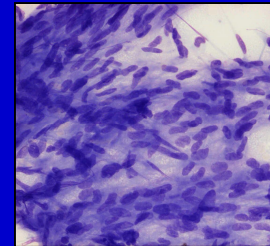
- Pleomorphic cell tumors



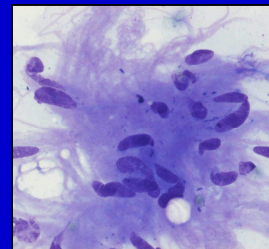
- Small round cell tumors



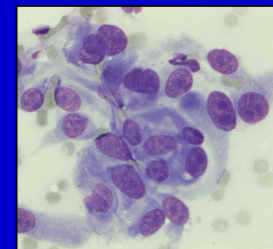
- Spindle cell tumors



- Myxoid tumors

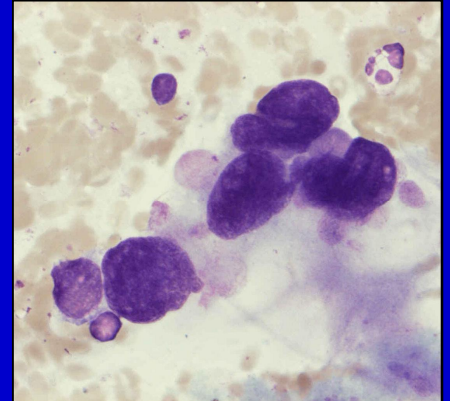


- Epithelioid/Polygonal cells tumors



- Pleomorphic cell tumors

Example:

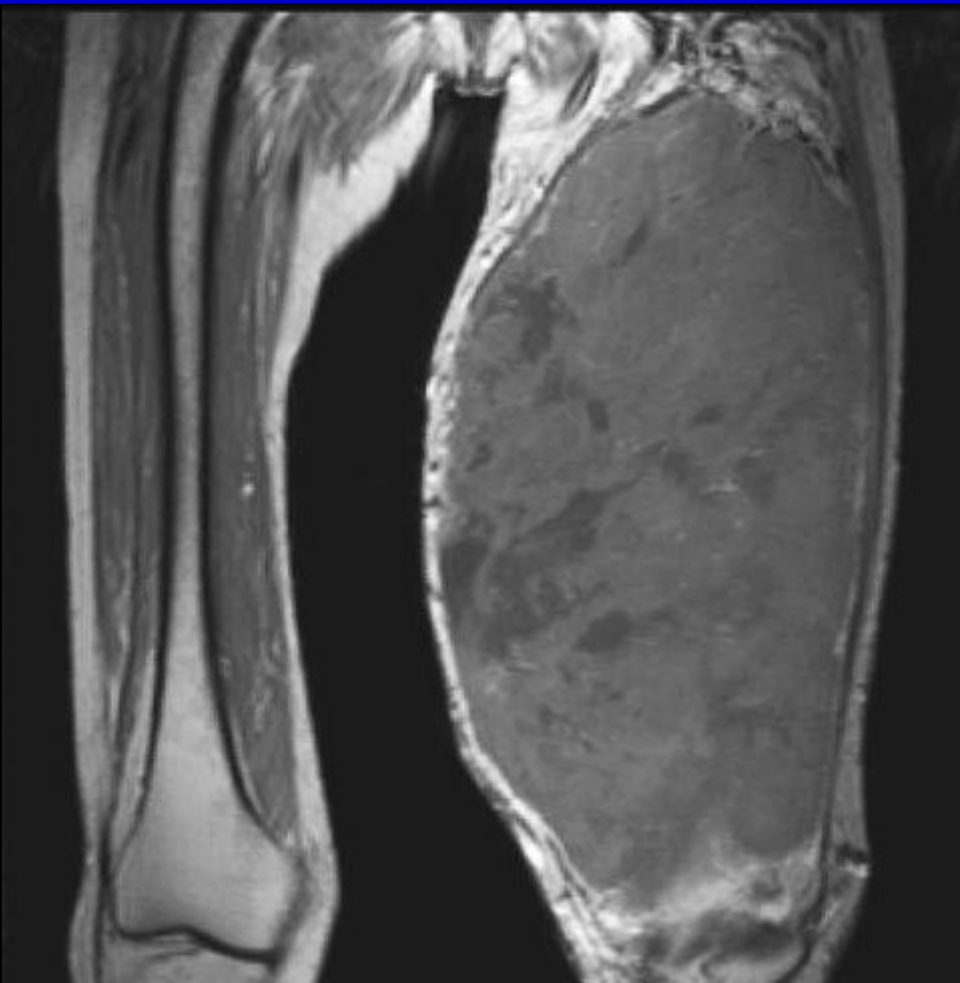
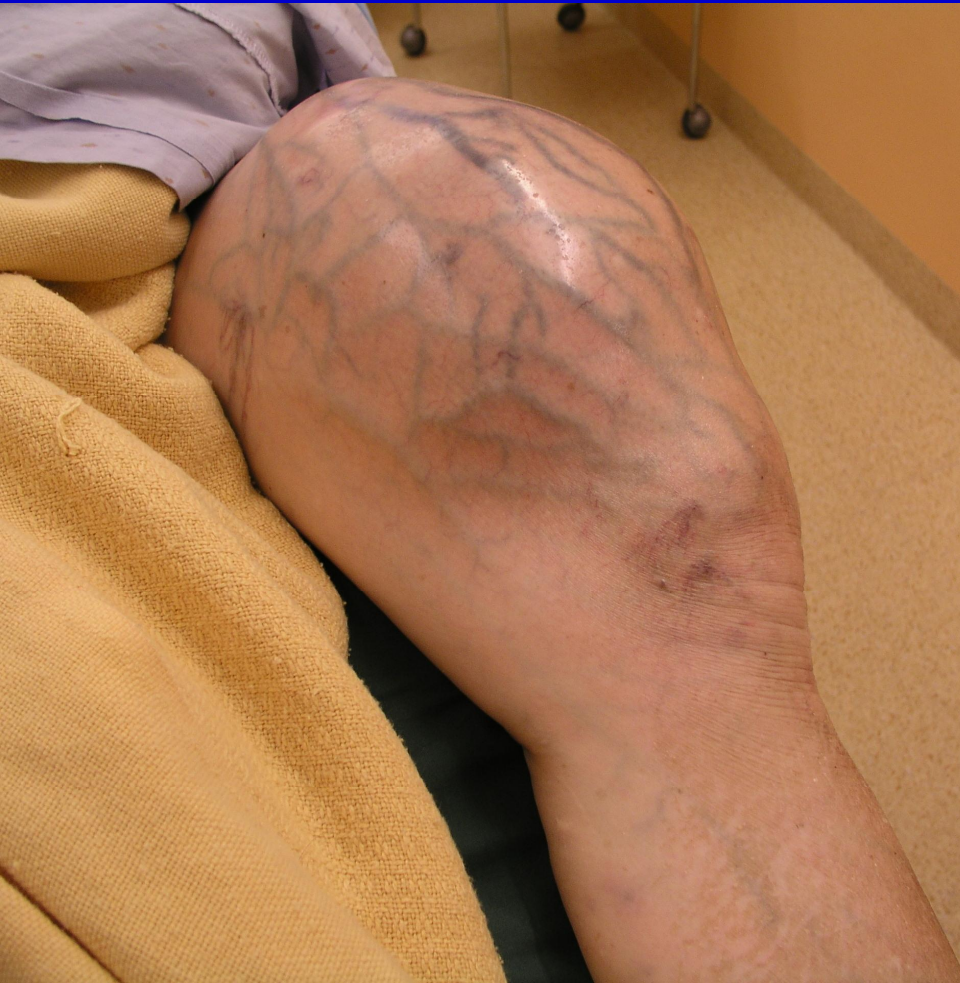

- High-grade pleomorphic sarcoma (MFH-like)
- Pleomorphic liposarcoma
- Pleomorphic leiomyosarcoma
- Pleomorphic rhabdomyosarcoma

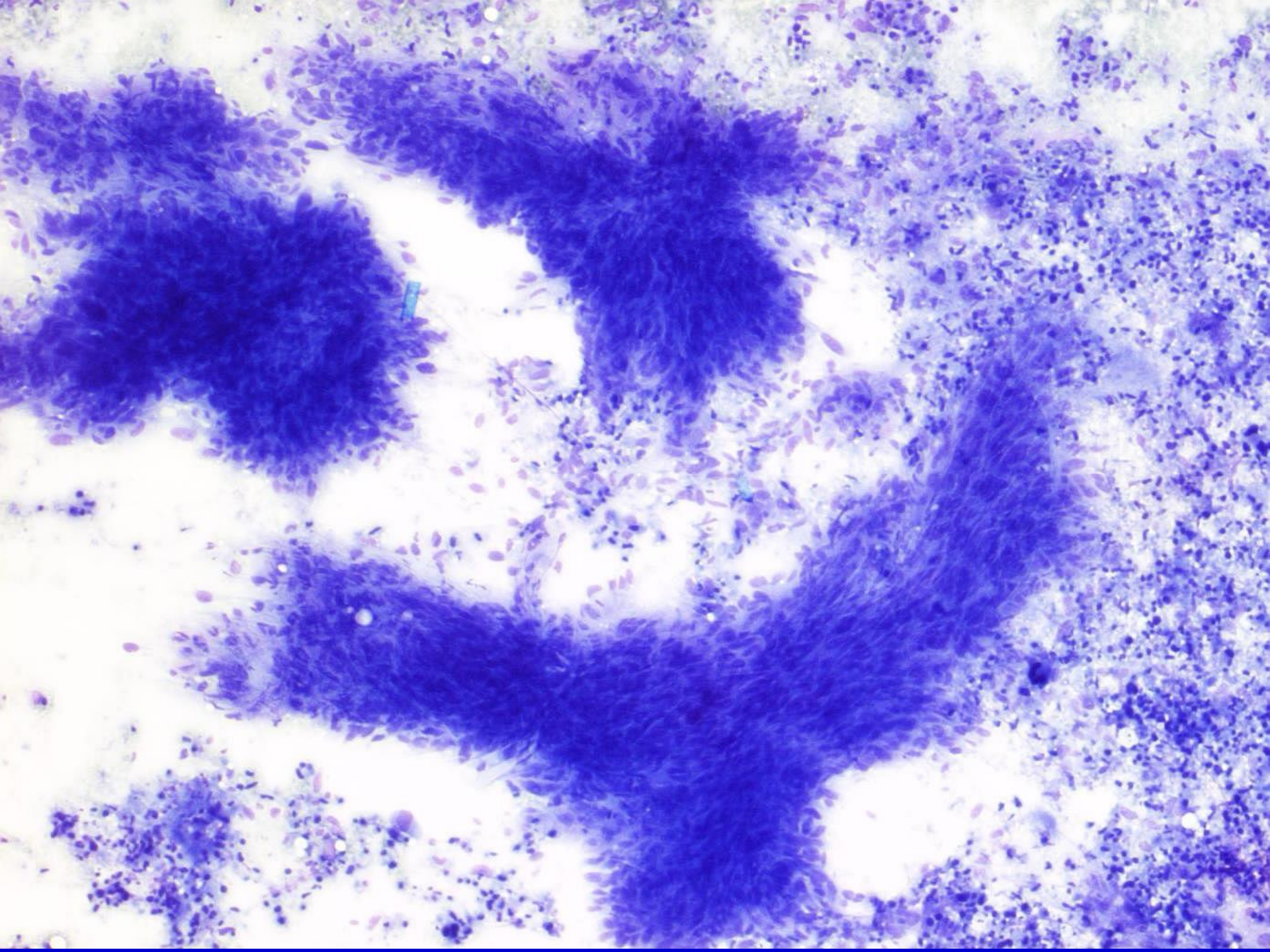


# Clinical history

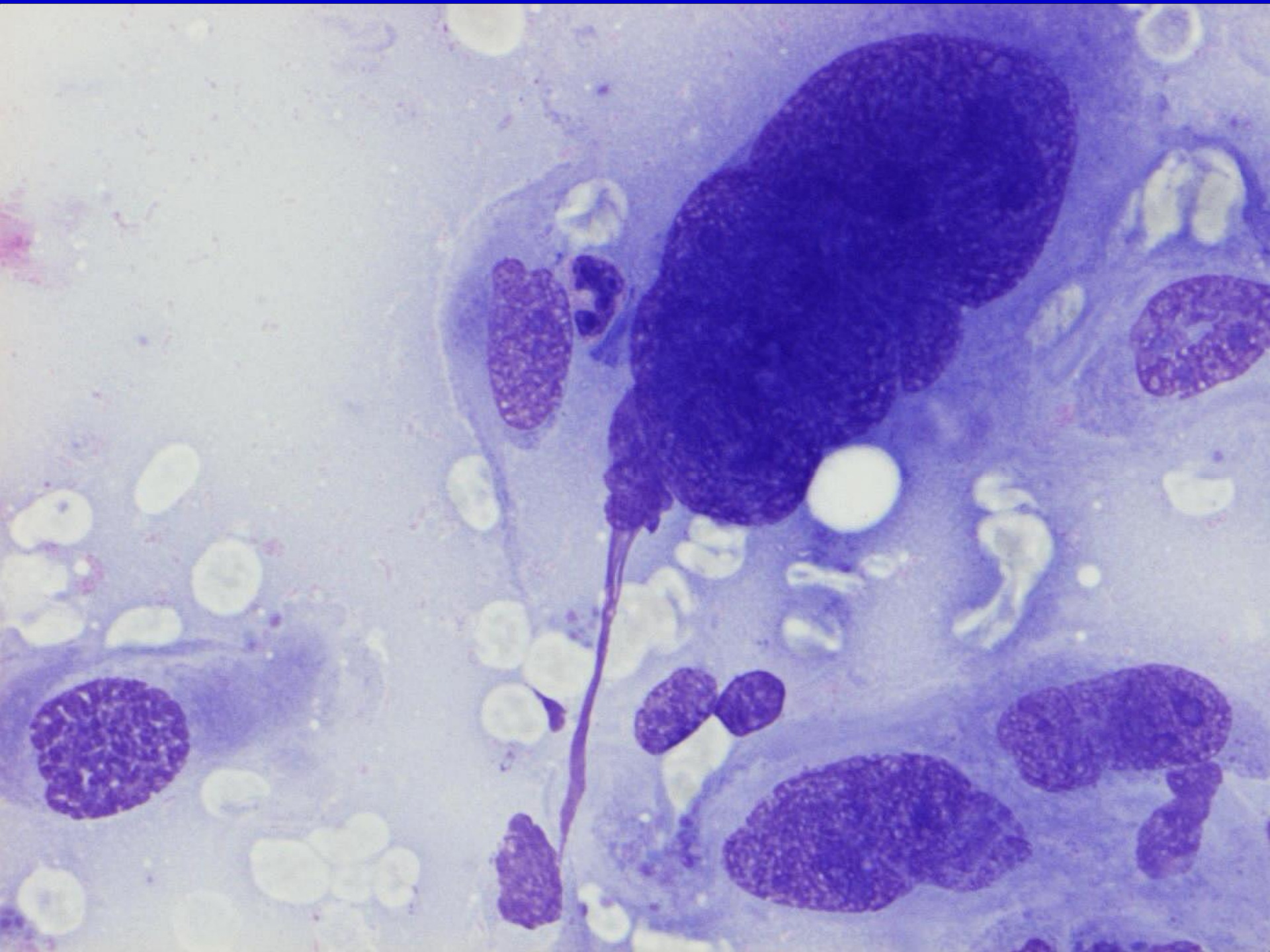
- 79-year-old woman presented with a huge mass in the left thigh and lung metastases

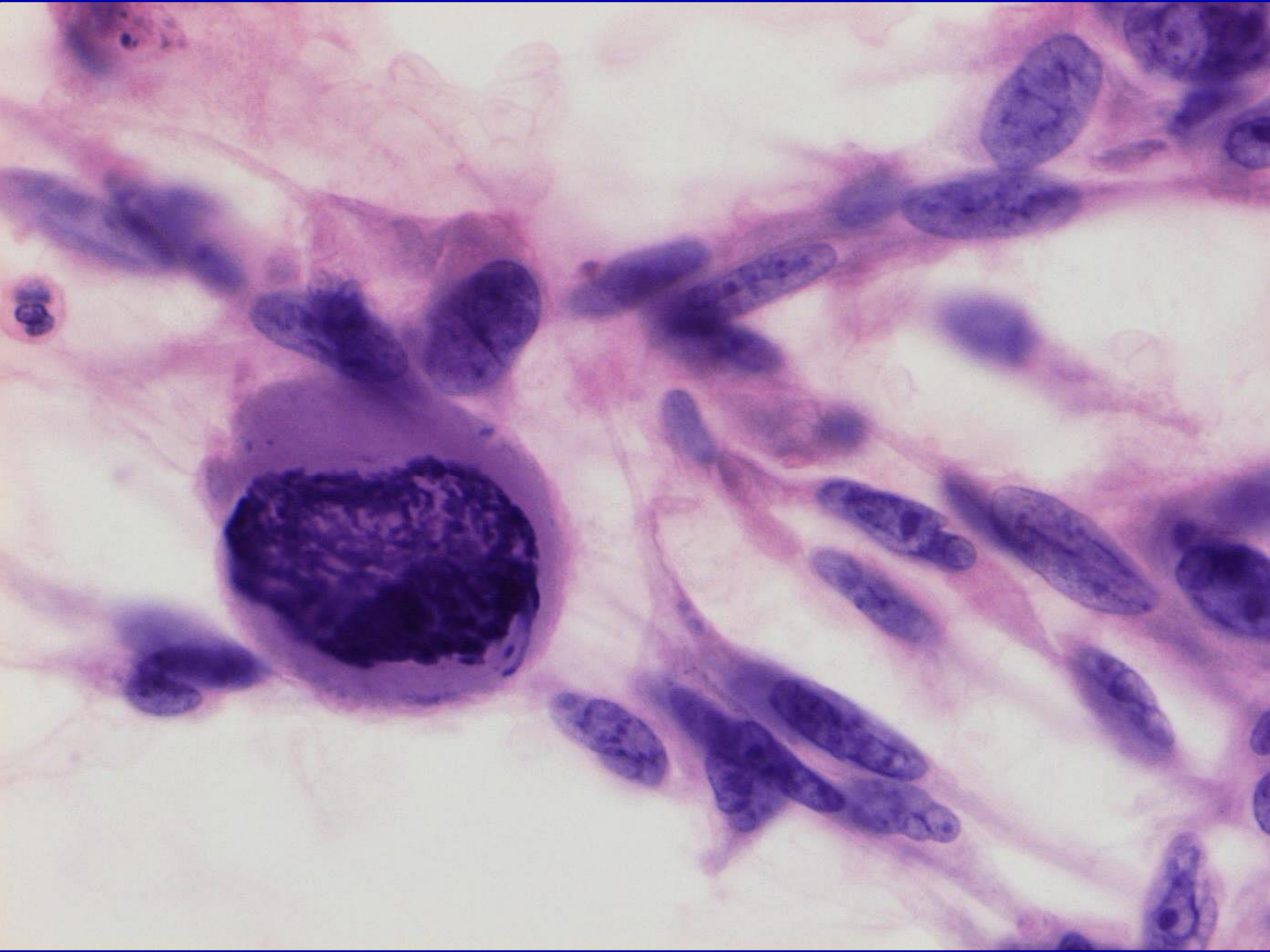






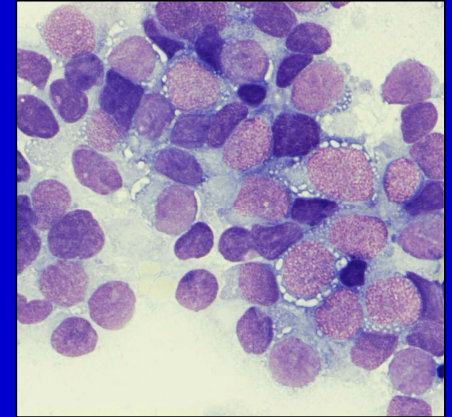








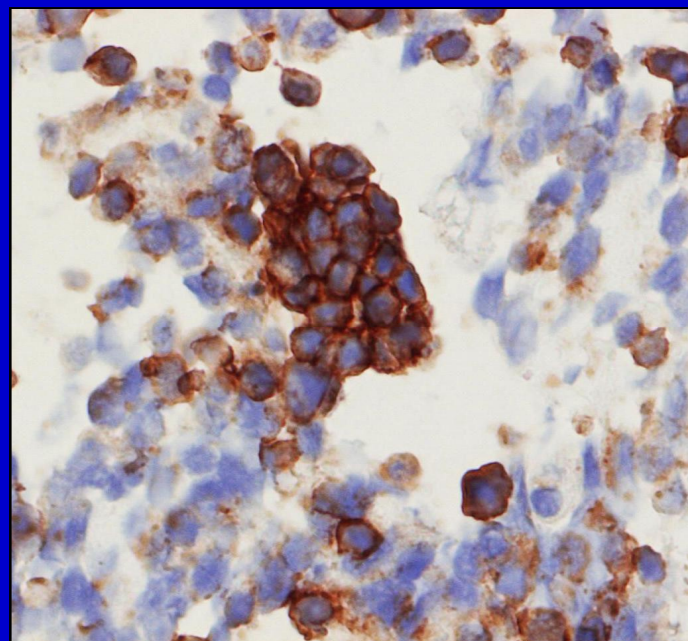
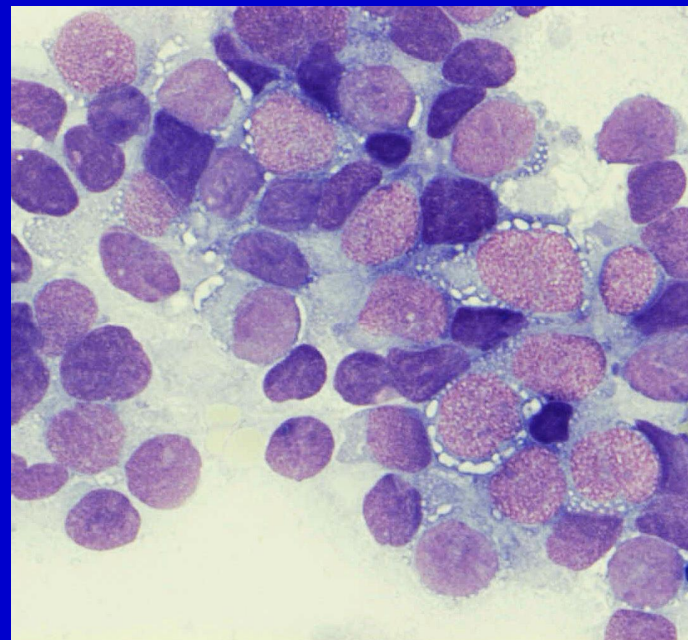
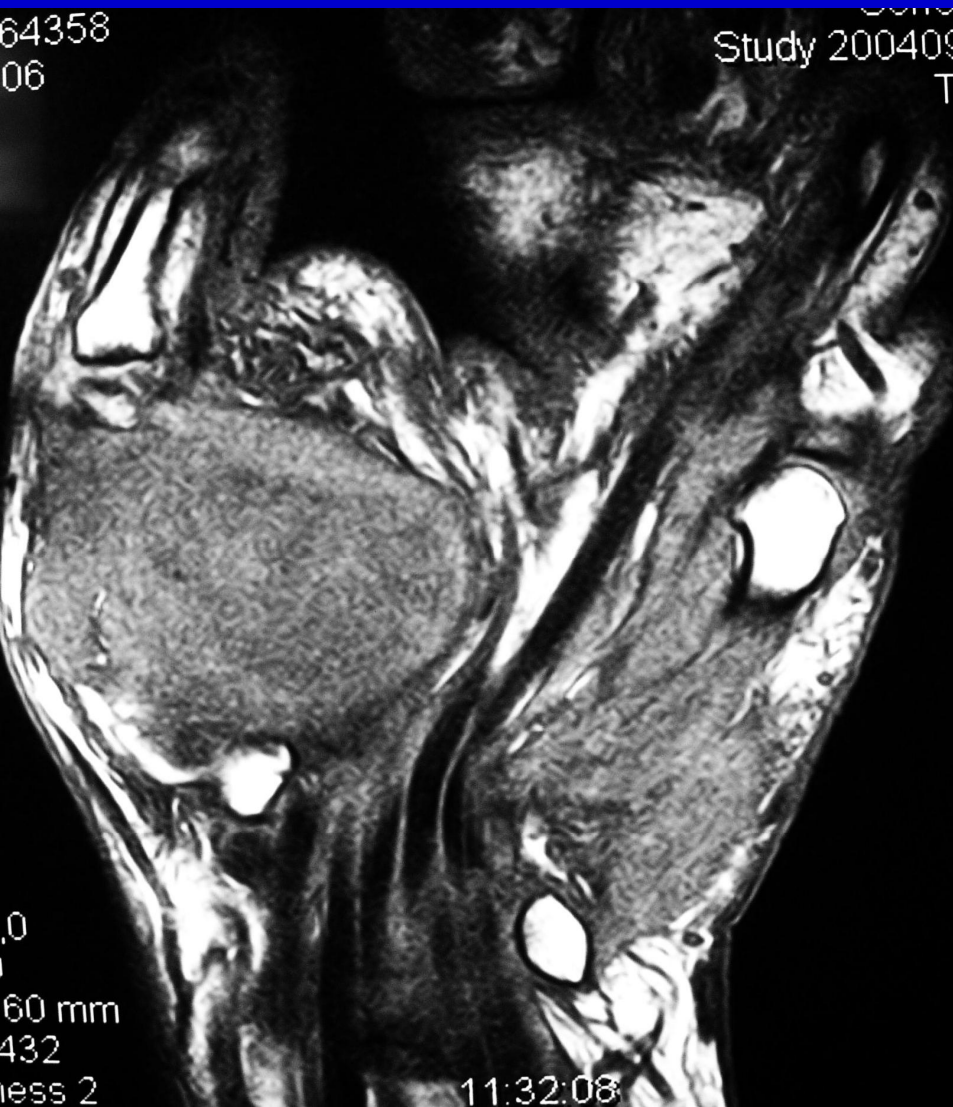- Small round cell tumors



Example:

- Rhabdomyosarcoma
- Ewing sarcoma / PNET
- Small round cell desmoplastic tumor
- Neuroblastoma

# Ewing sarcoma

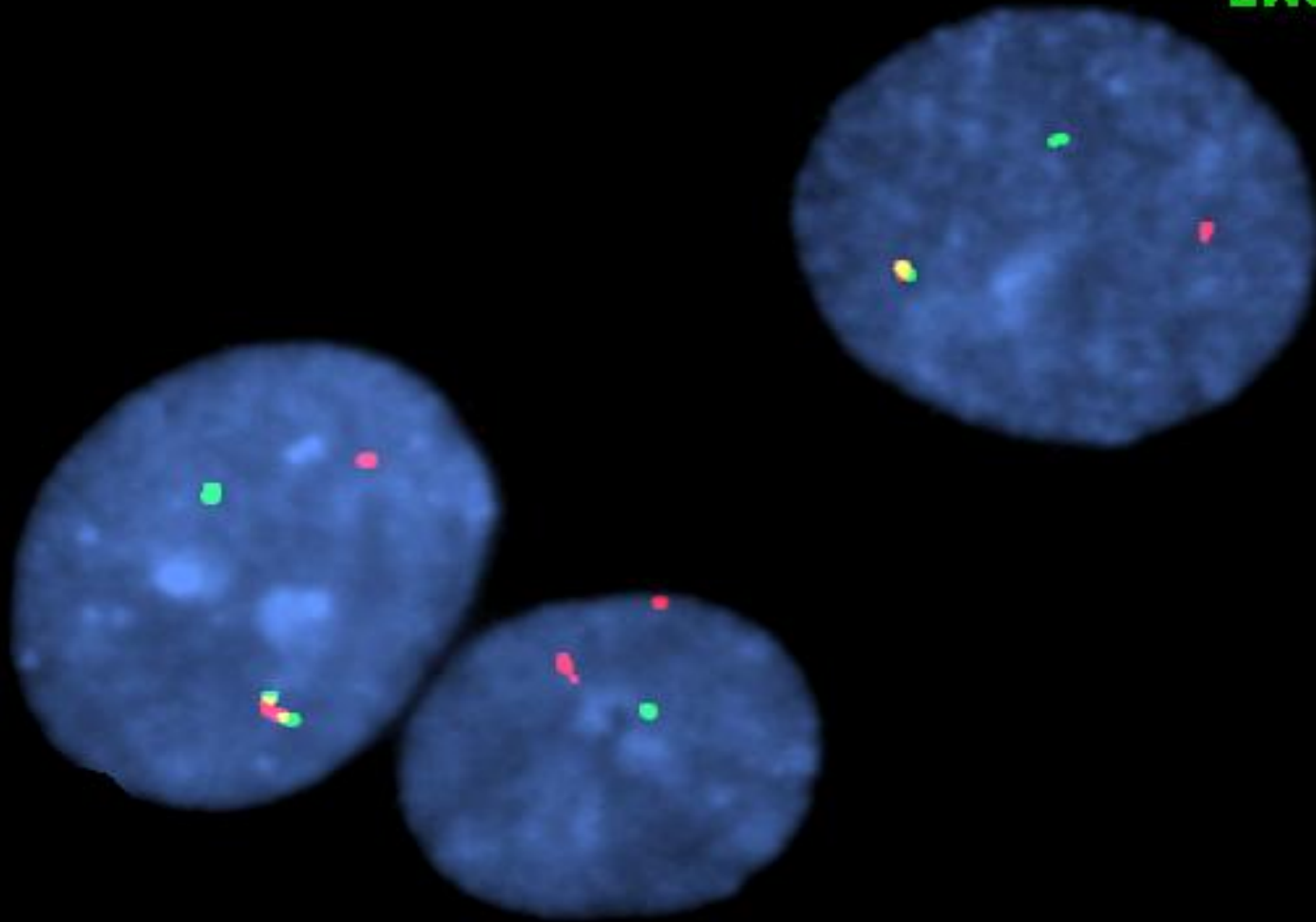


CD99



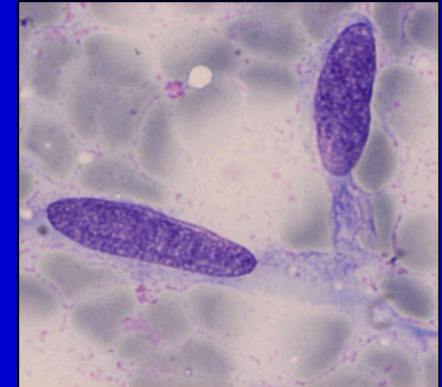Dual color break apart probe (BAP)  
specific for the *EWSR1* gene in 22q12

**EWS3'**  
**EWS5'**



FISH on interphase nuclei shows a split signal for  
one of the two *EWSR1* loci in 309 of 335 nuclei

- Spindle cell tumours



## FNAC - specific problems

- Morphological overlap
- Occasionally similar clinical presentation
- Difficulty in distinguishing benign from locally aggressive and malignant

- Spindle cell tumors

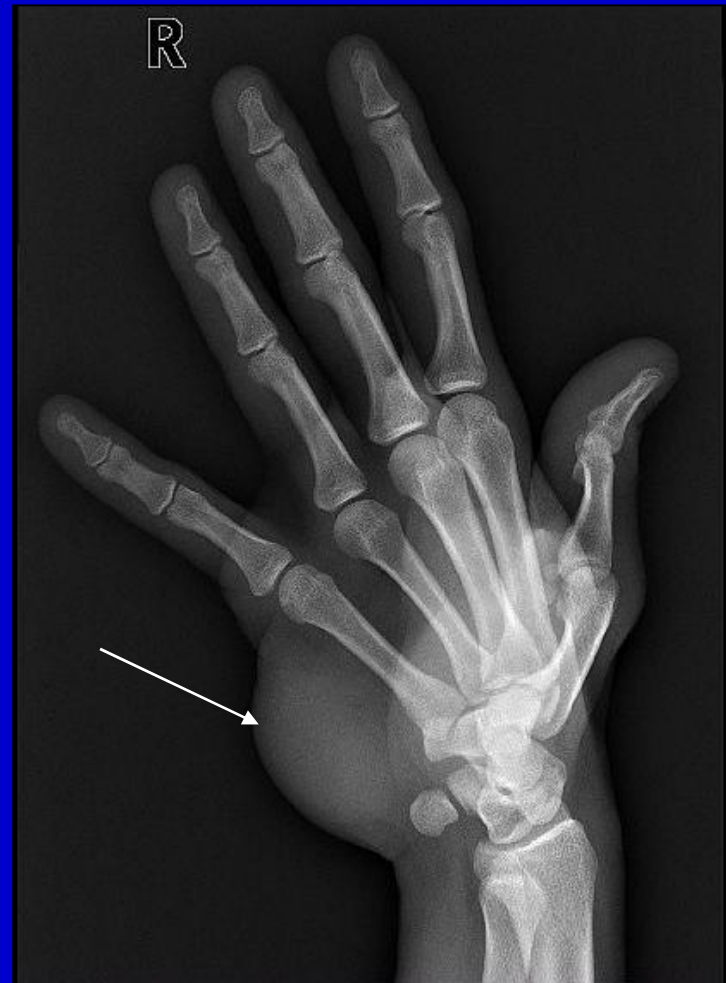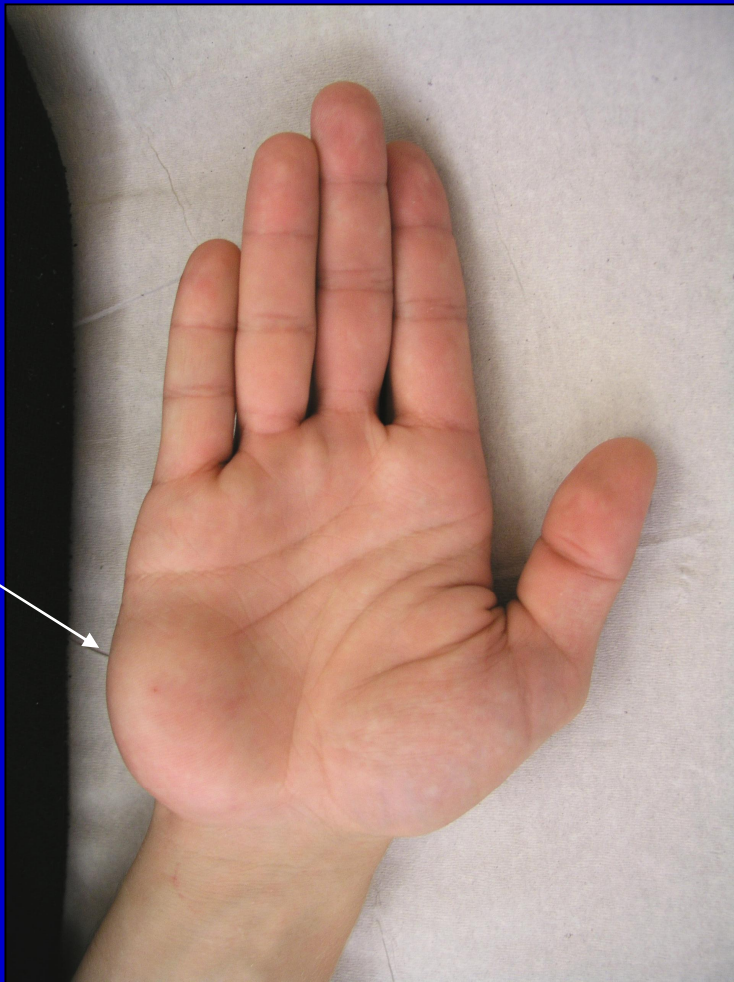
## Example:

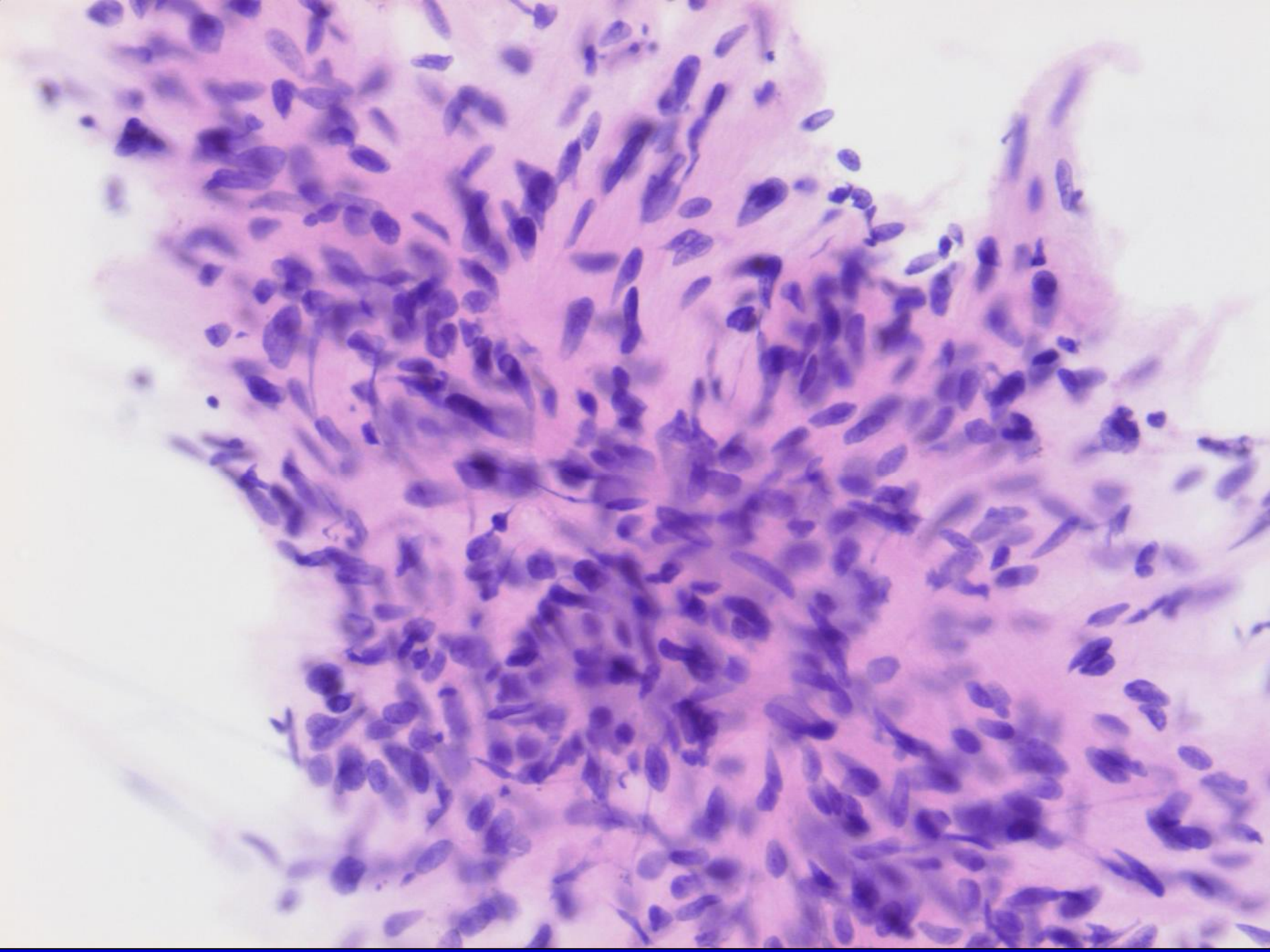
- Schwannoma
- Elastofibroma dorsi
- Desmoid / Fibromatosis
- Dermatofibrosarcoma protuberans
- Leiomyosarcoma
- Monophasic synovial sarcoma



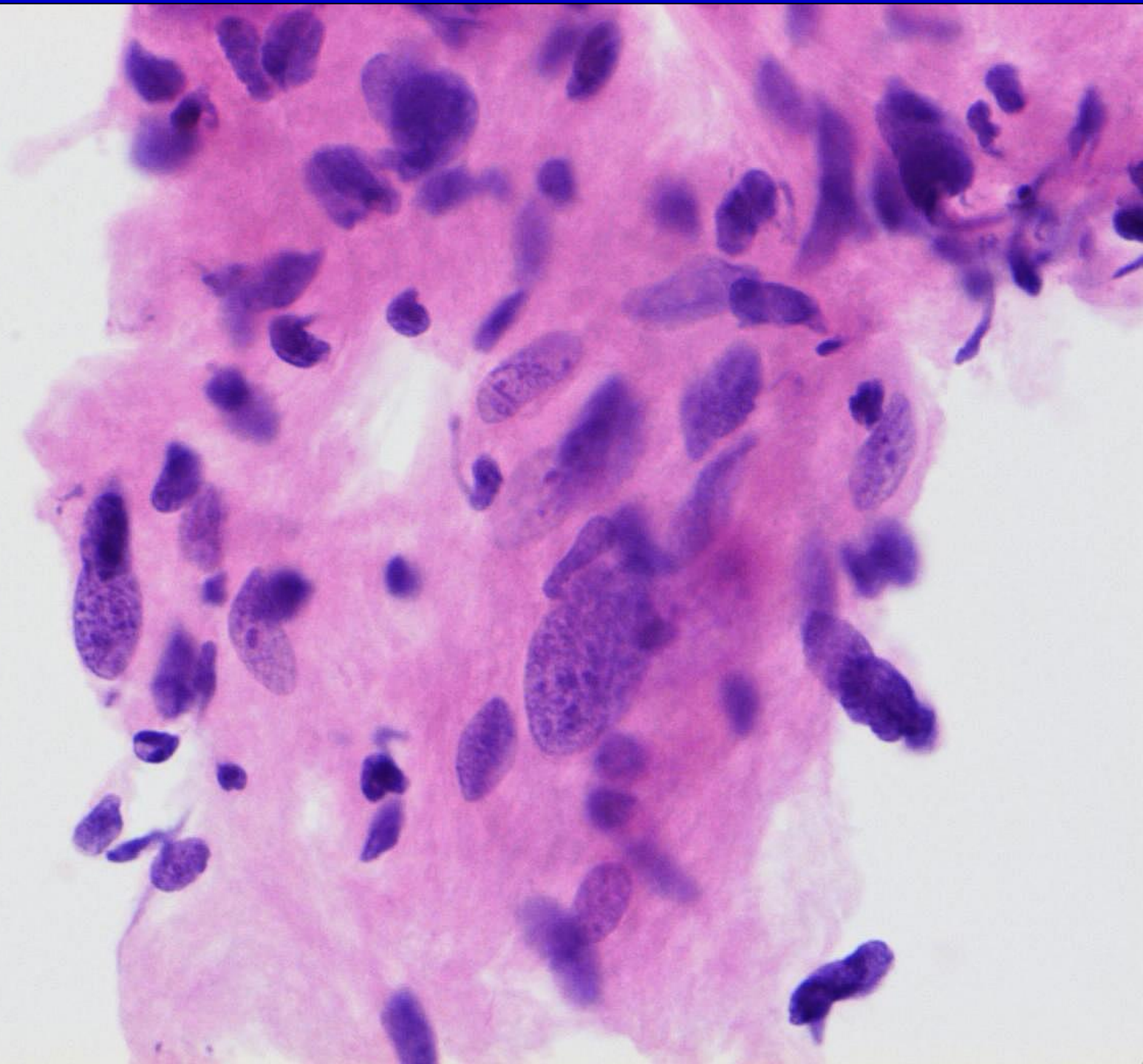
# Clinical History

- 25-year-old man presented with a slowly growing mass in the right hand; Clinical diagnosis: Cyst

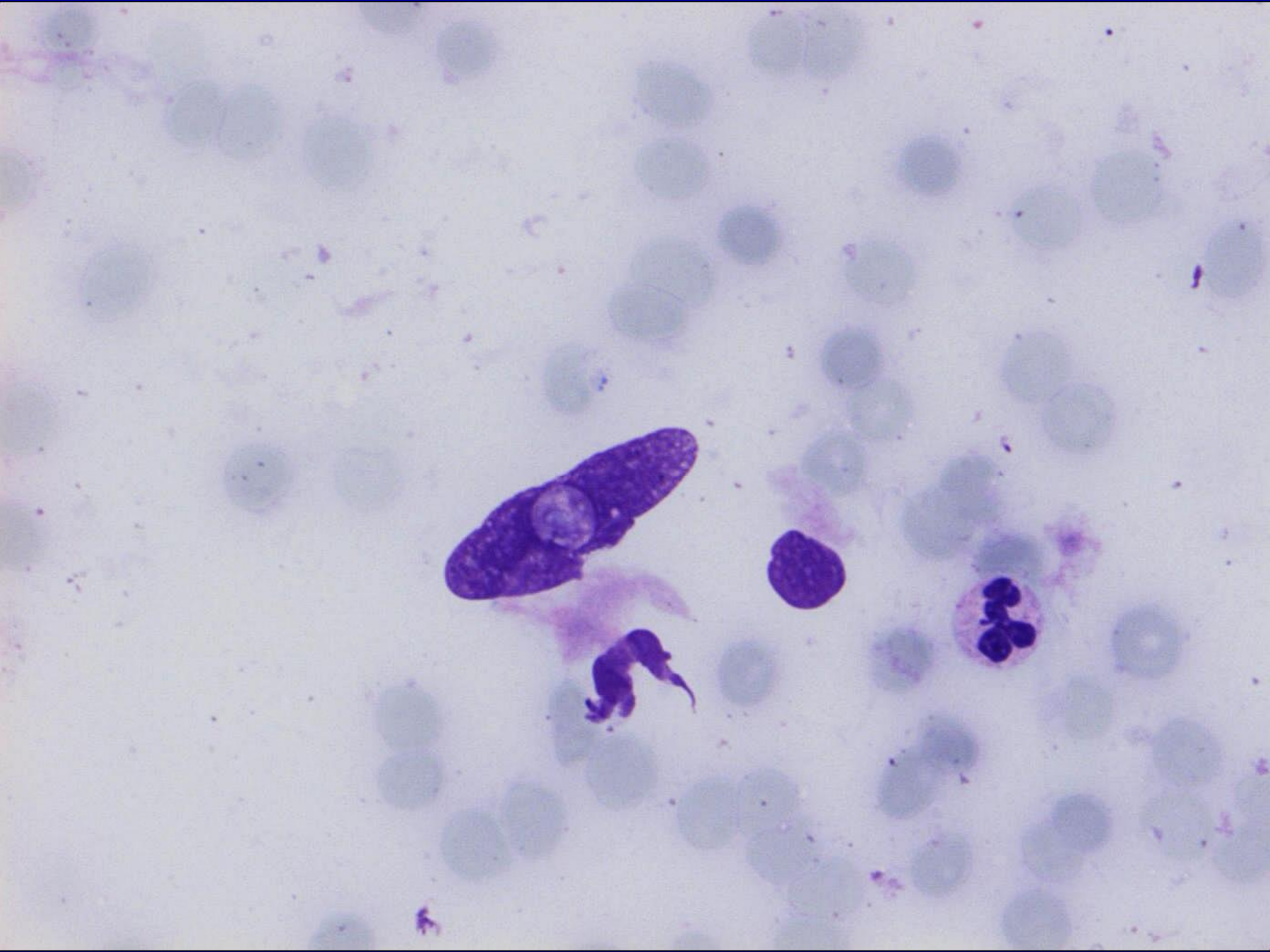


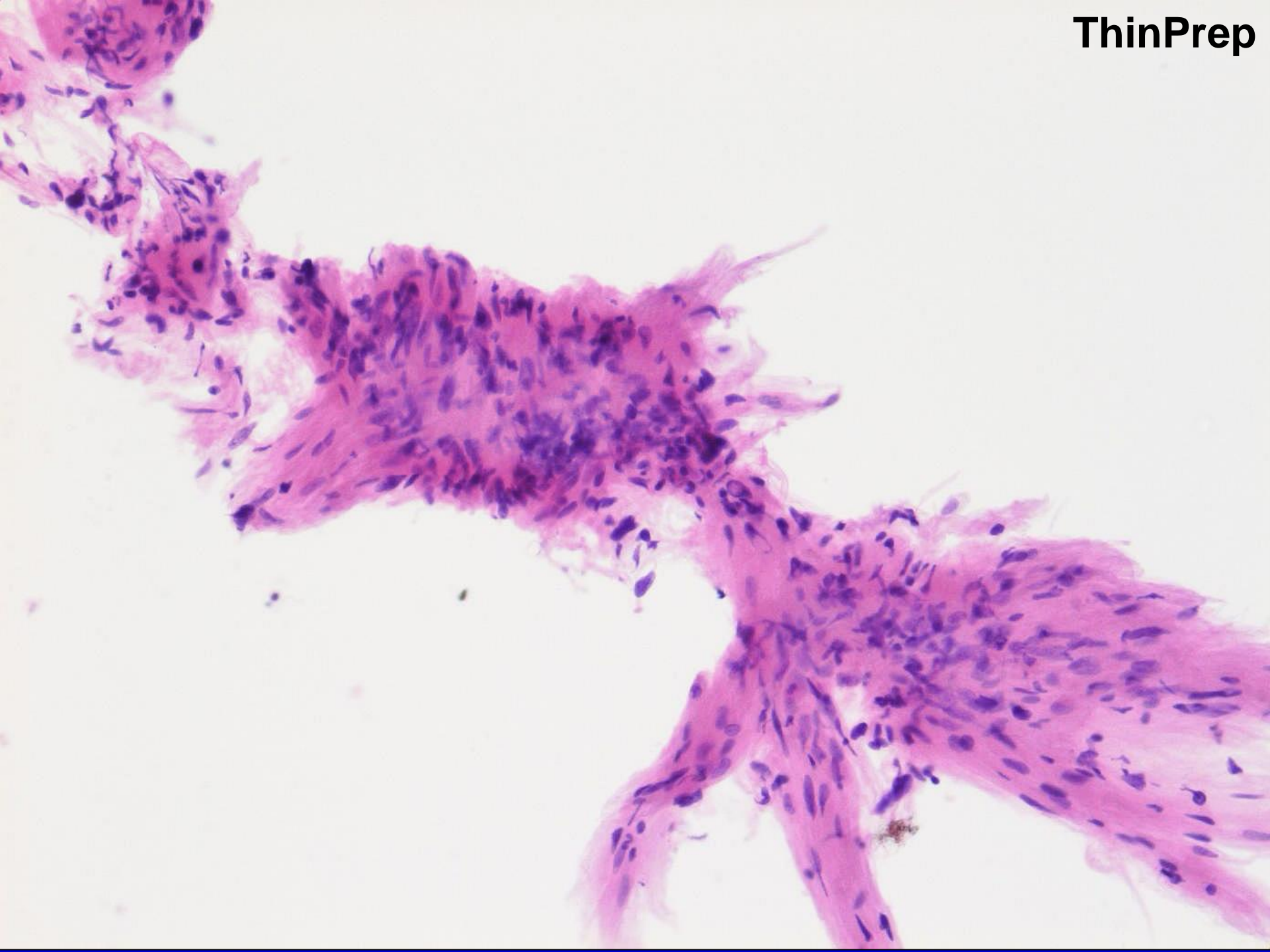


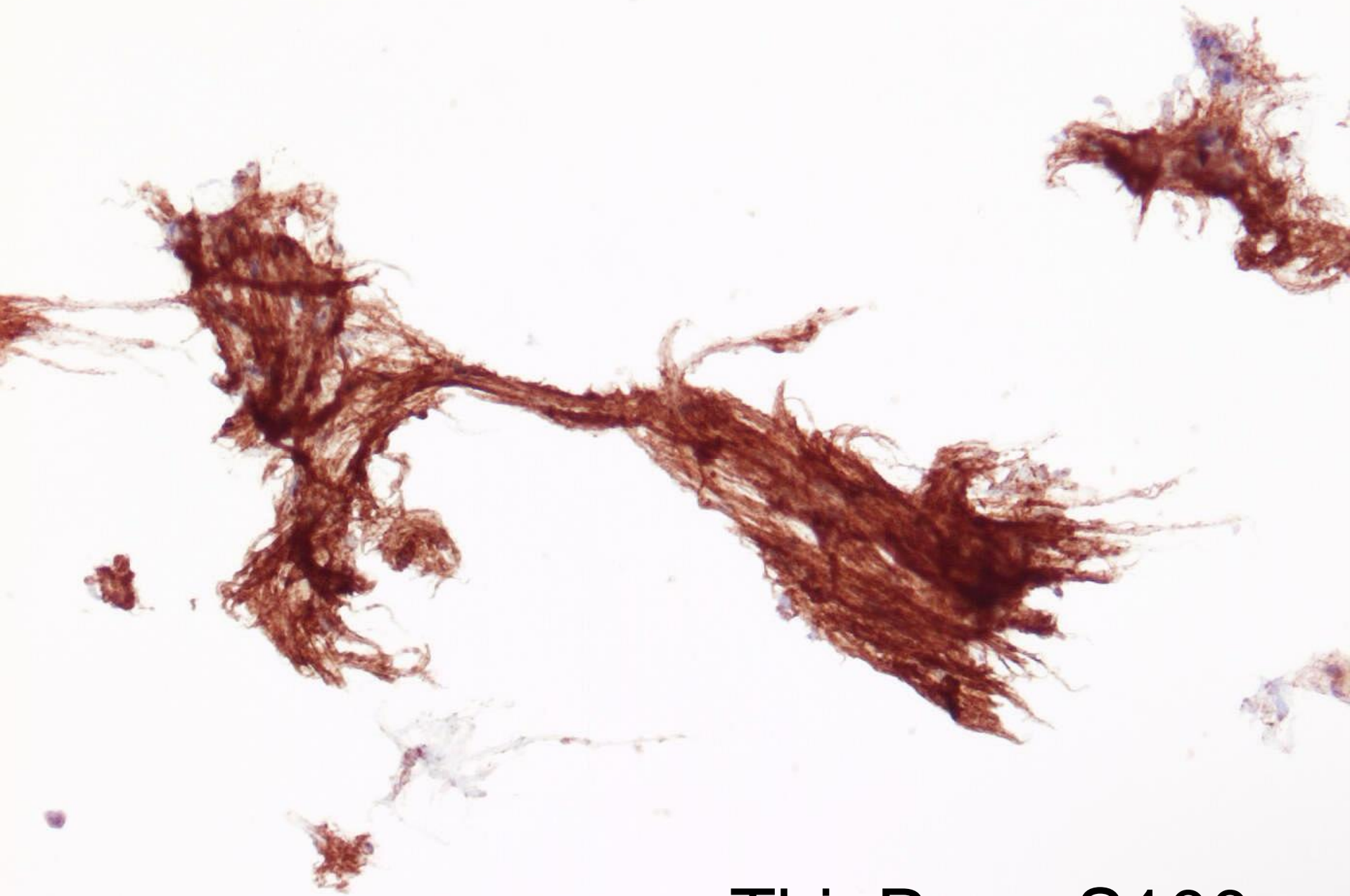












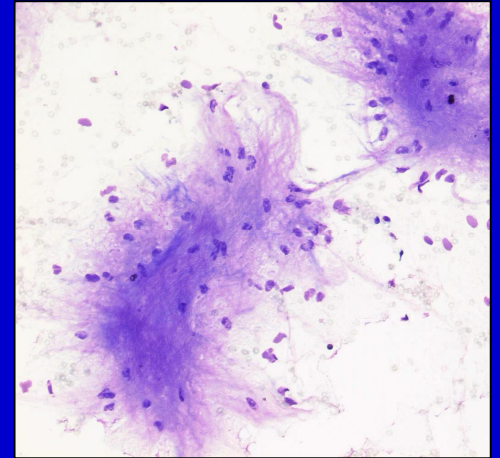
ThinPrep: S100+



- Myxoid tumors

Examples:

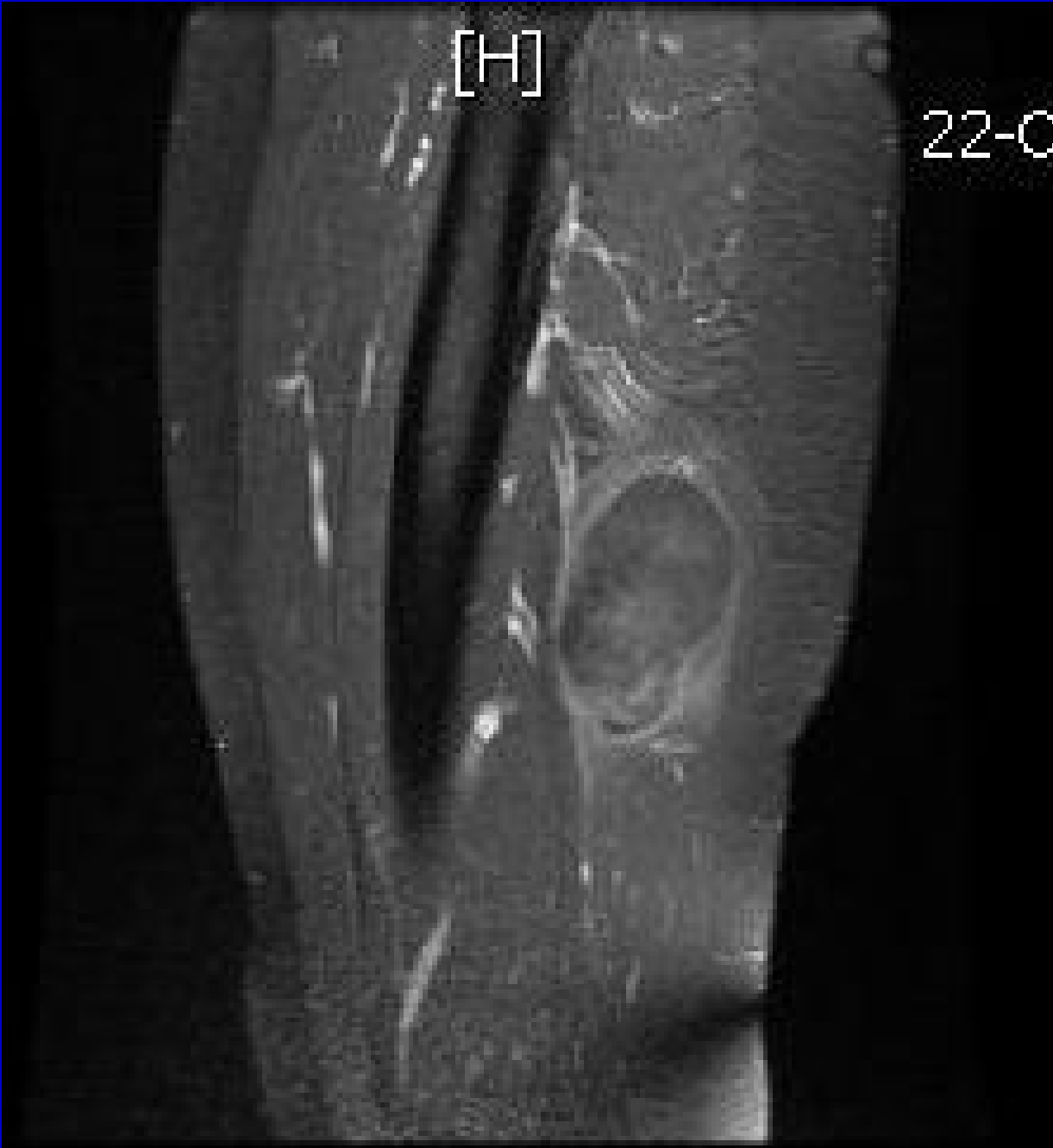- Intramuscular myxoma
- Myxoid or round cell liposarcoma
- Myxofibrosarcoma
- Lipoblastoma
- Extraskeletal myxoid chondrosarcoma

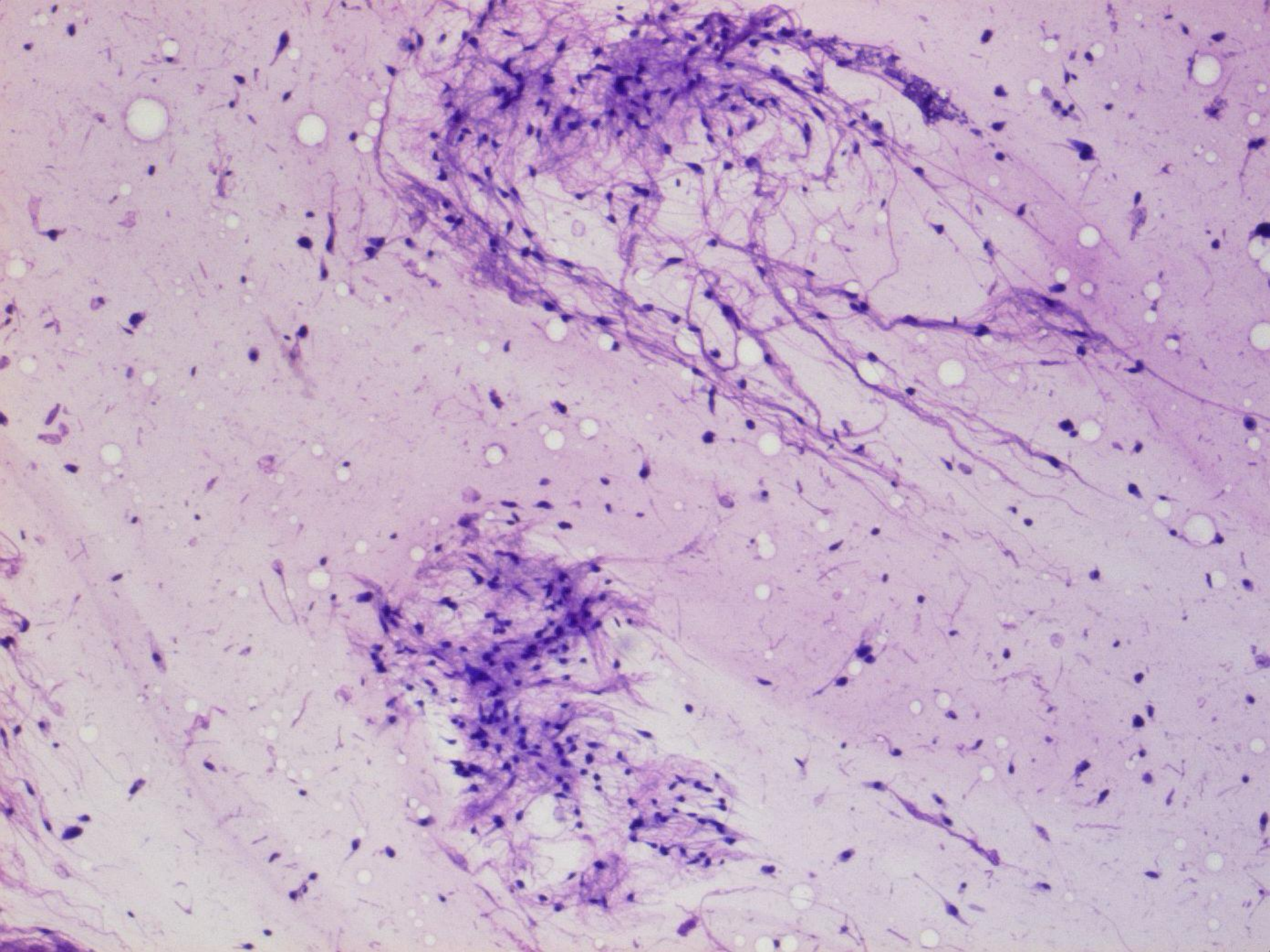


[H]

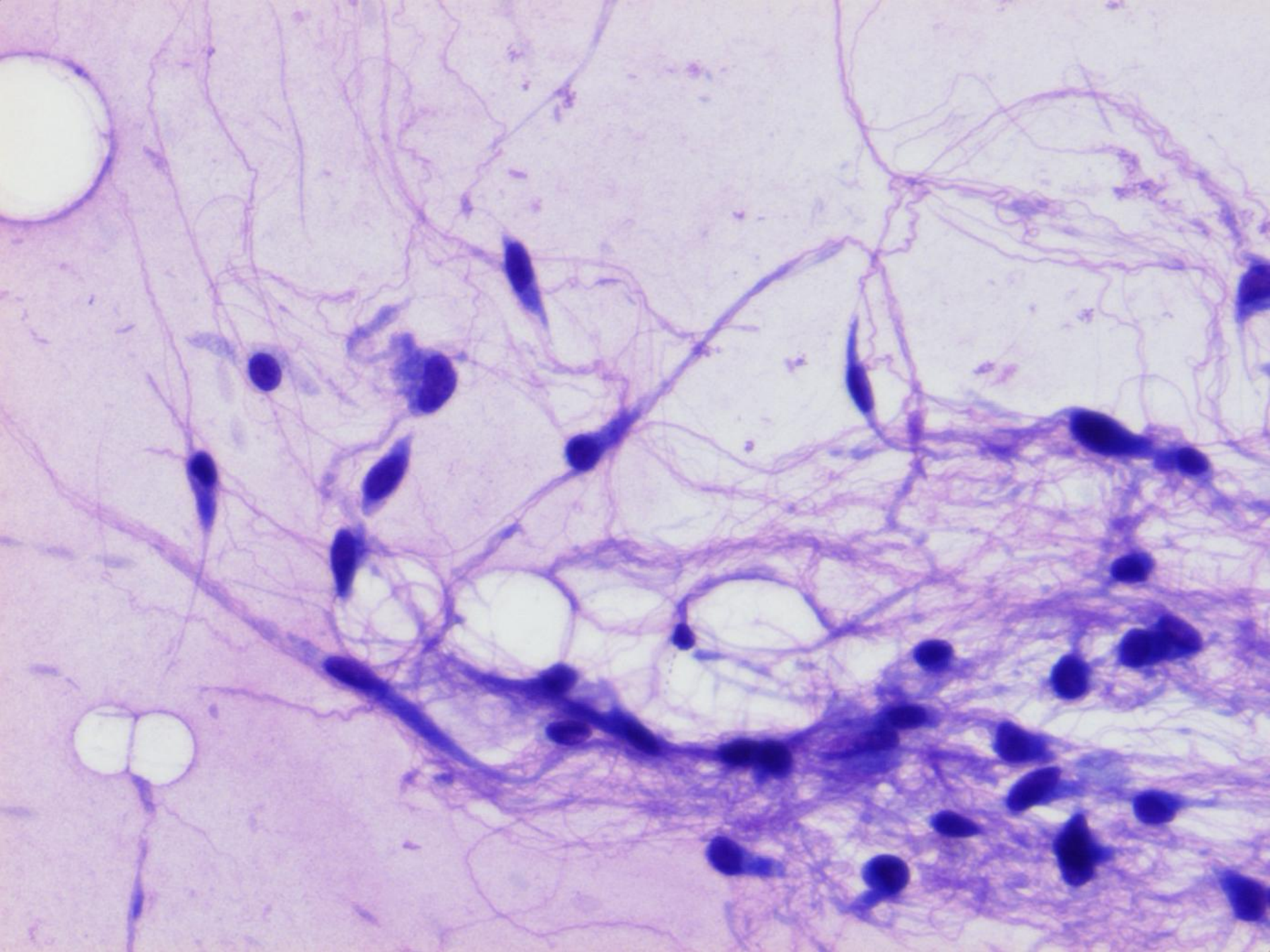
22-C

- 46-year-old woman presented with a slowly growing mass in the right thigh
- Clinical diagnosis: Myxoma

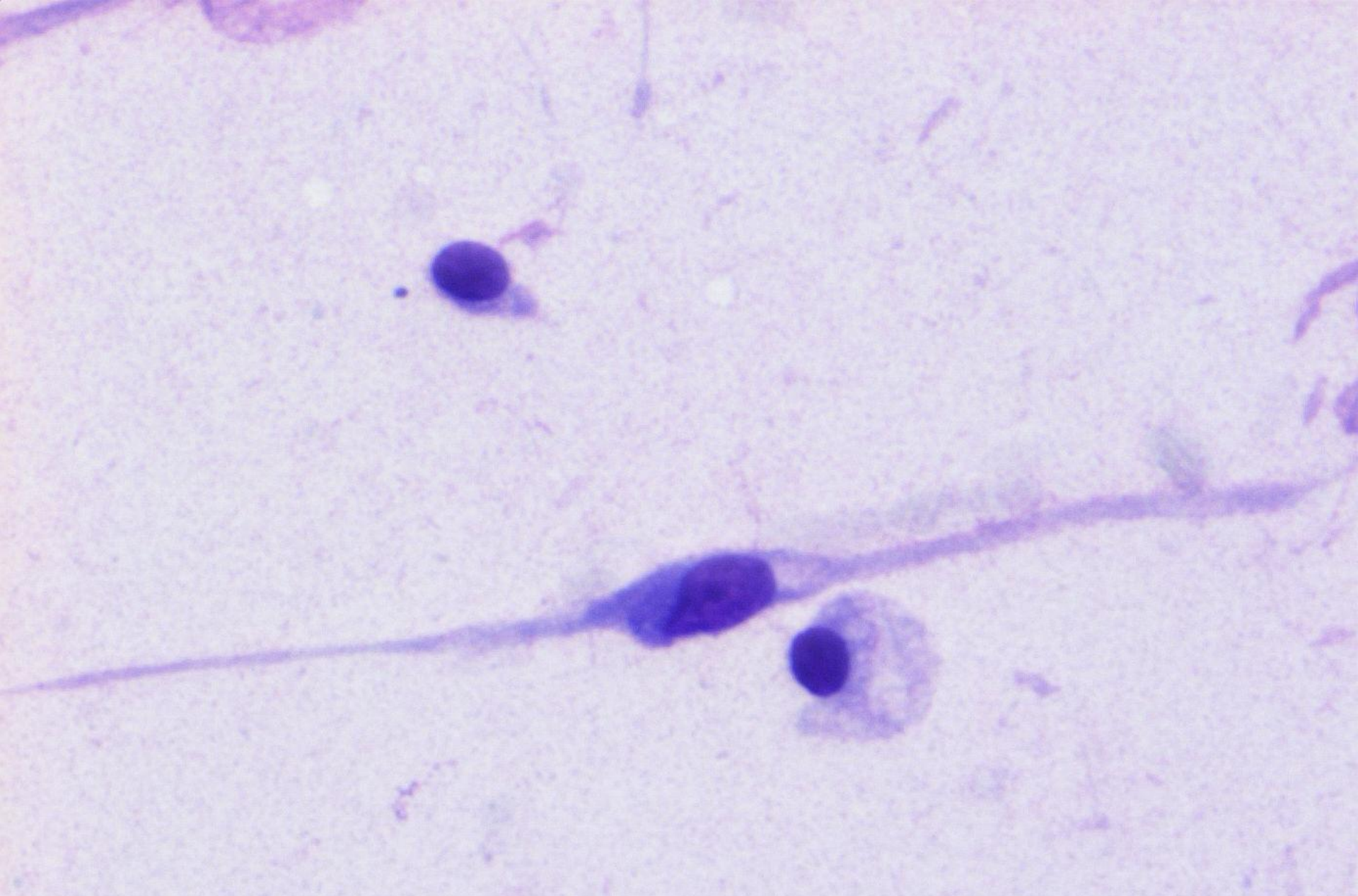










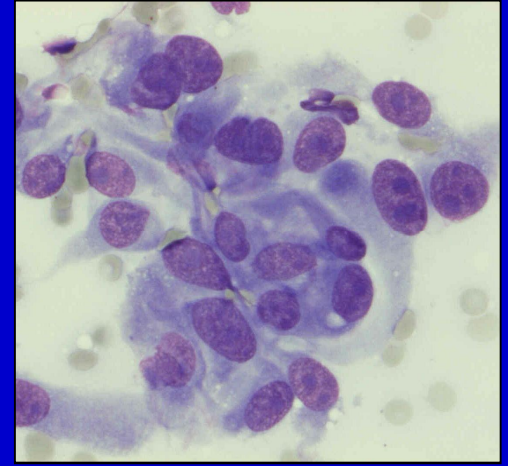


Myxoma

- Epithelioid/Polygonal cells tumours

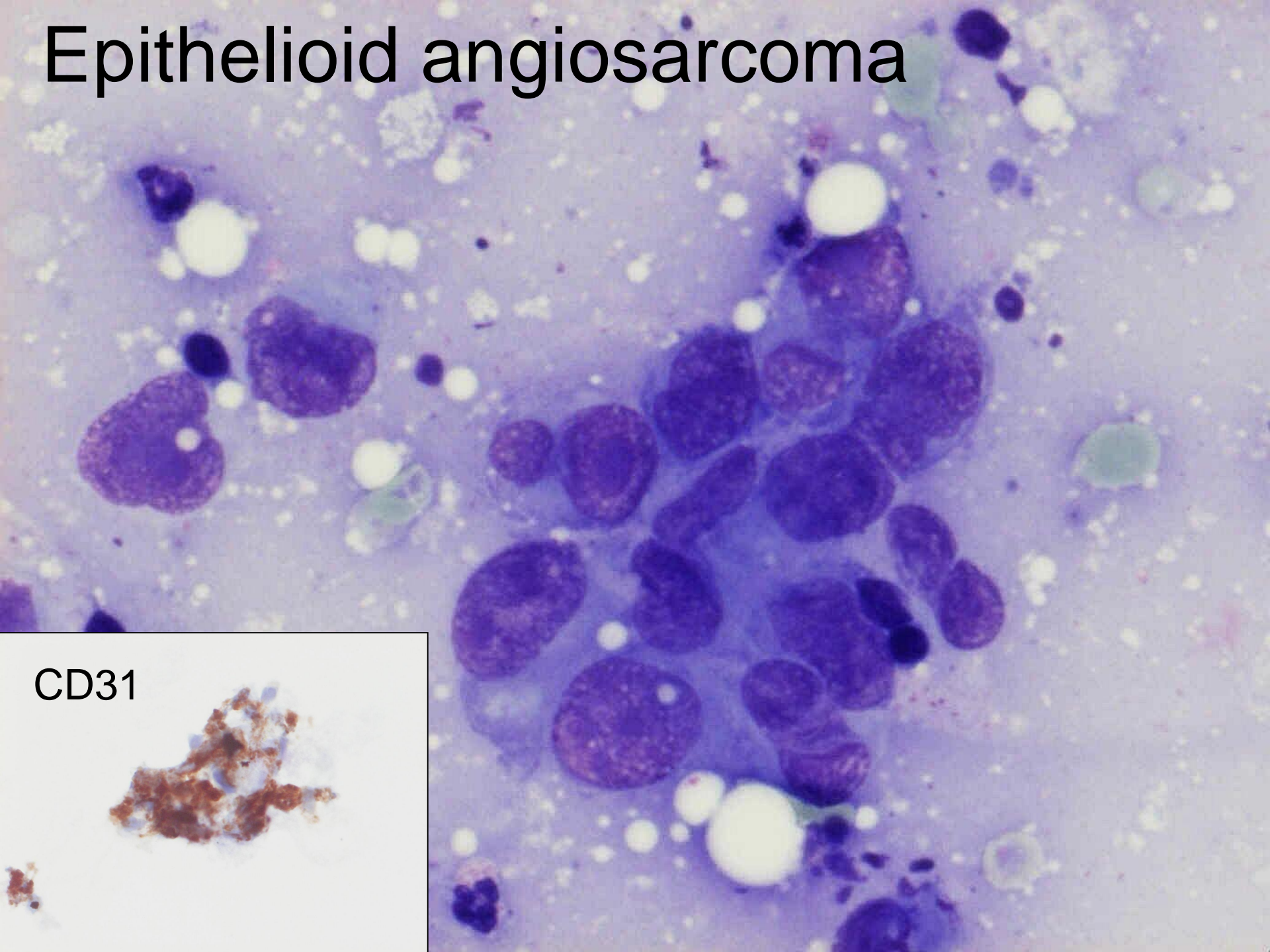
Examples:

- Epithelioid angiosarcoma
- Granular cell tumor
- Clear cell sarcoma
- Epithelioid hemangioendothelioma
- Alveolar soft parts sarcoma

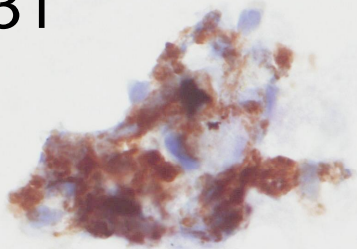




# Epithelioid angiosarcoma

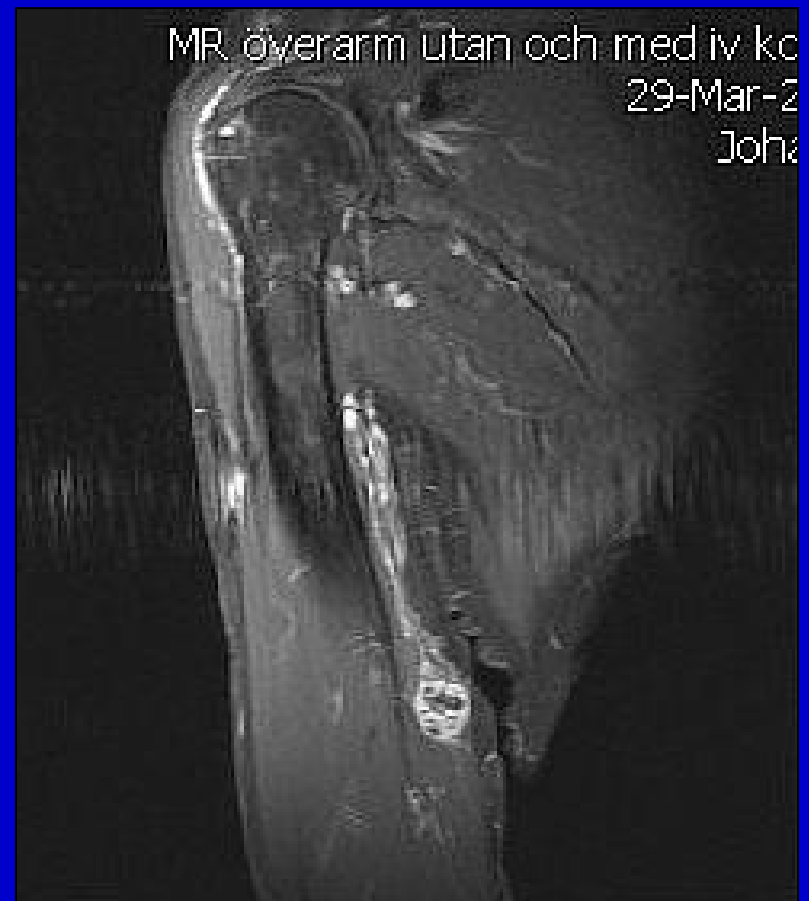
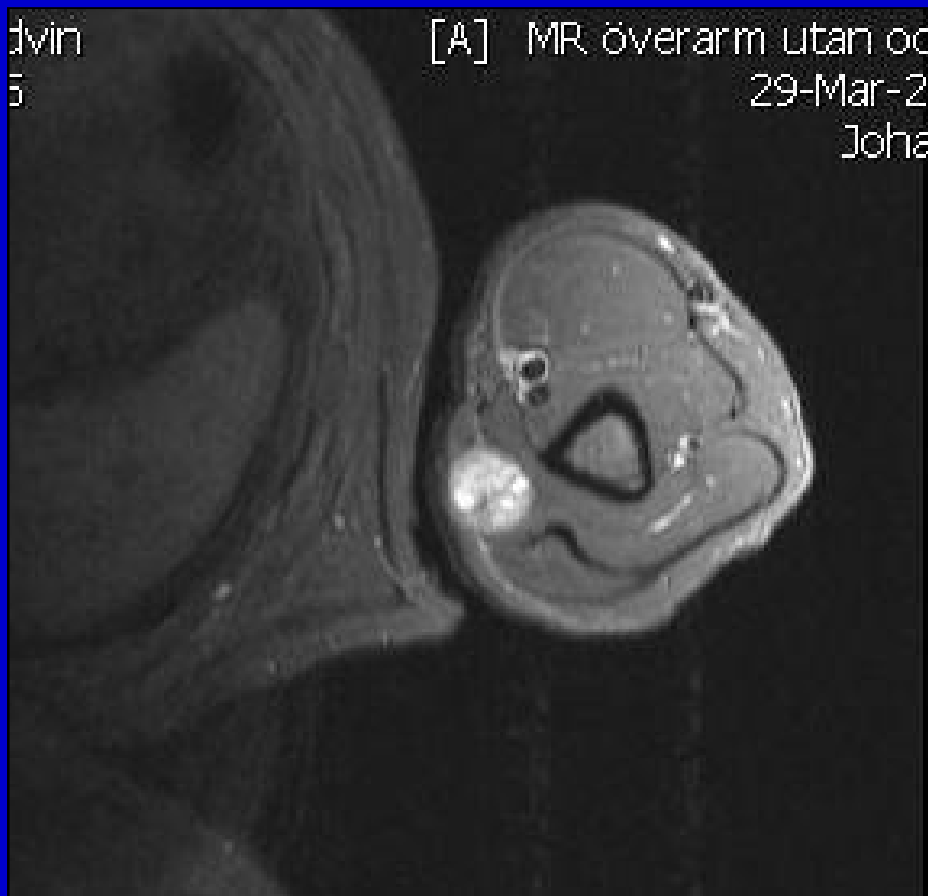
CD31

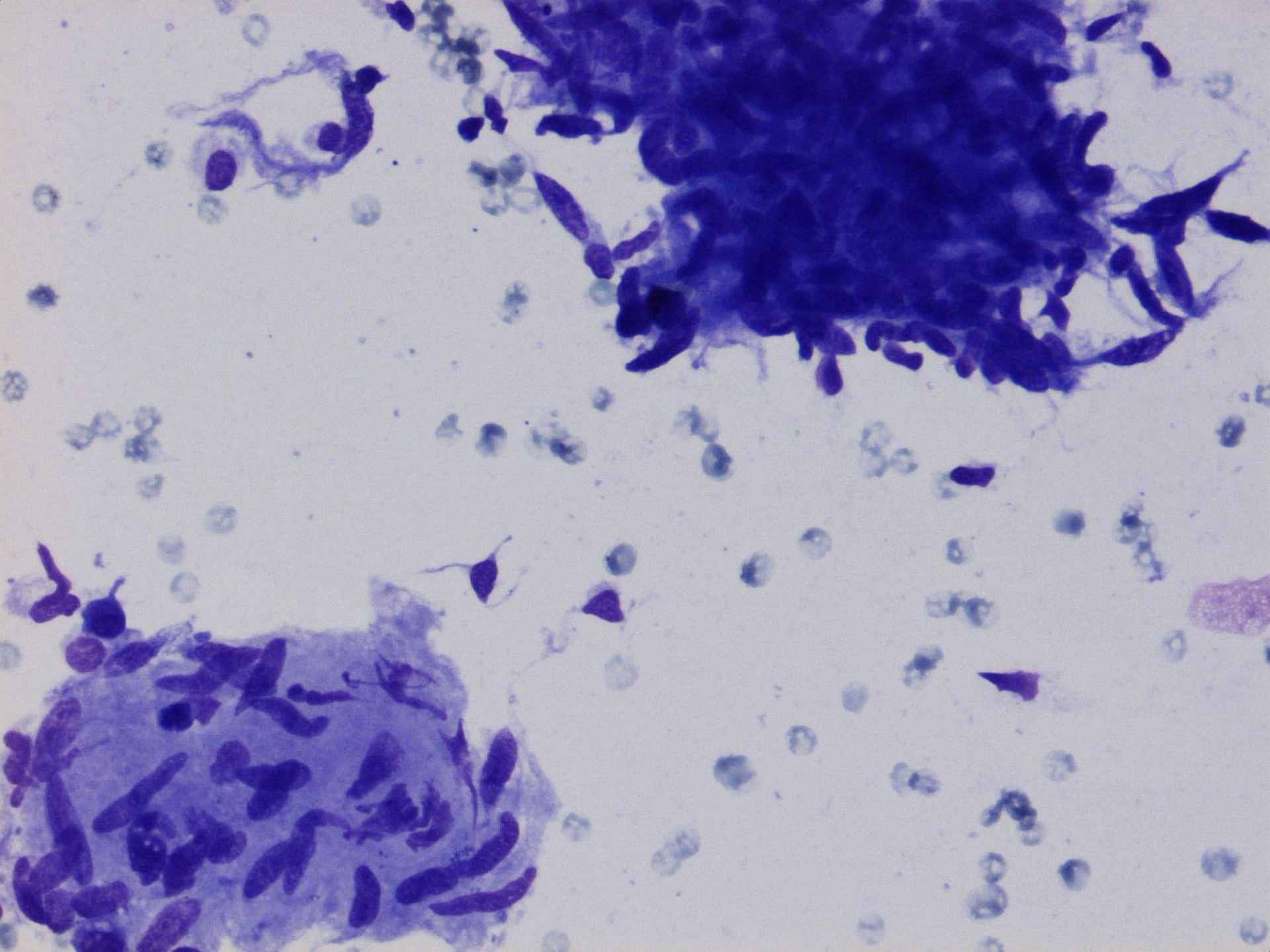


# Clinical history

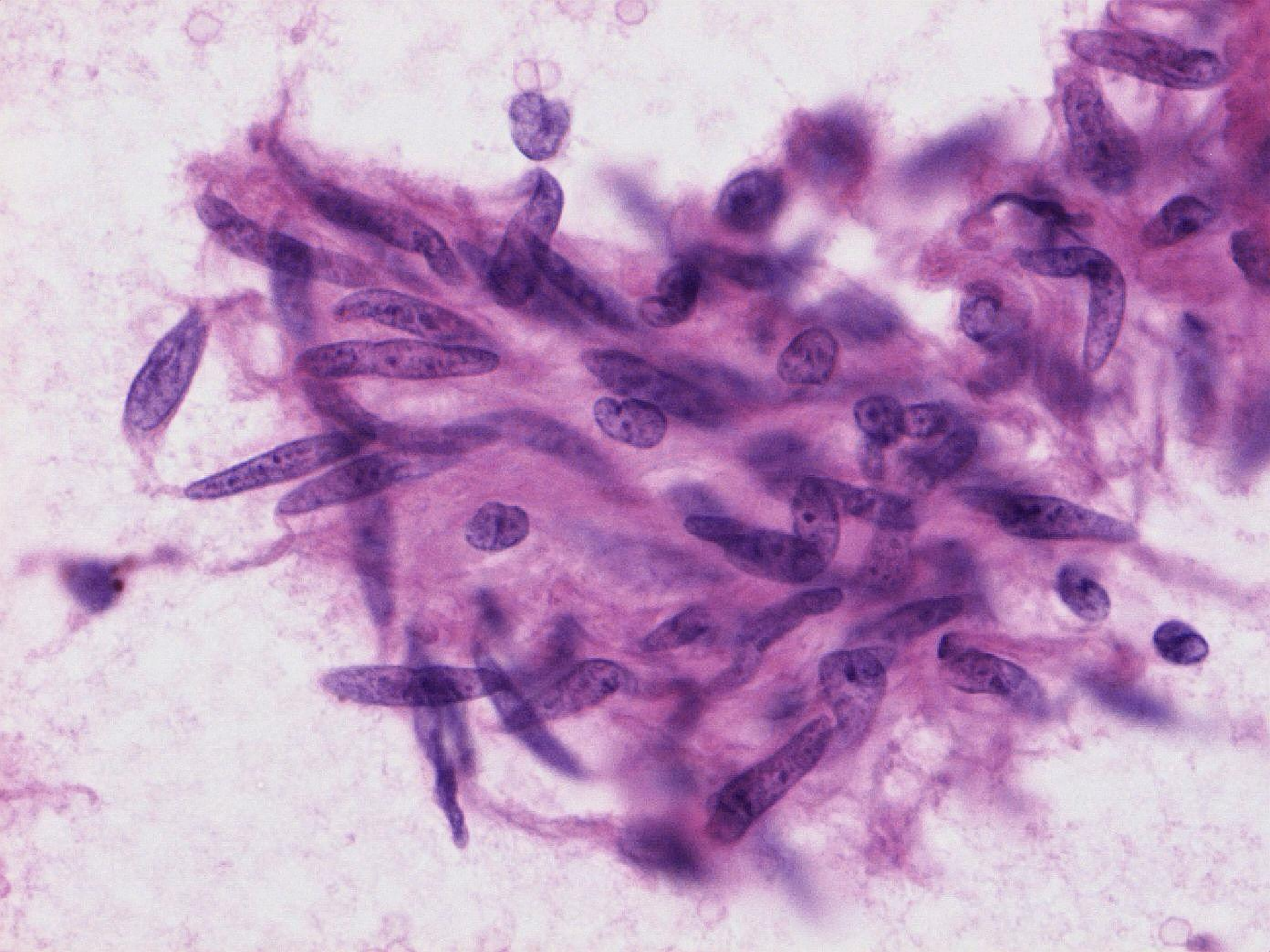
- 76-year-old man
- 3 cm tender deep mass in the right upper arm of 3 yr duration



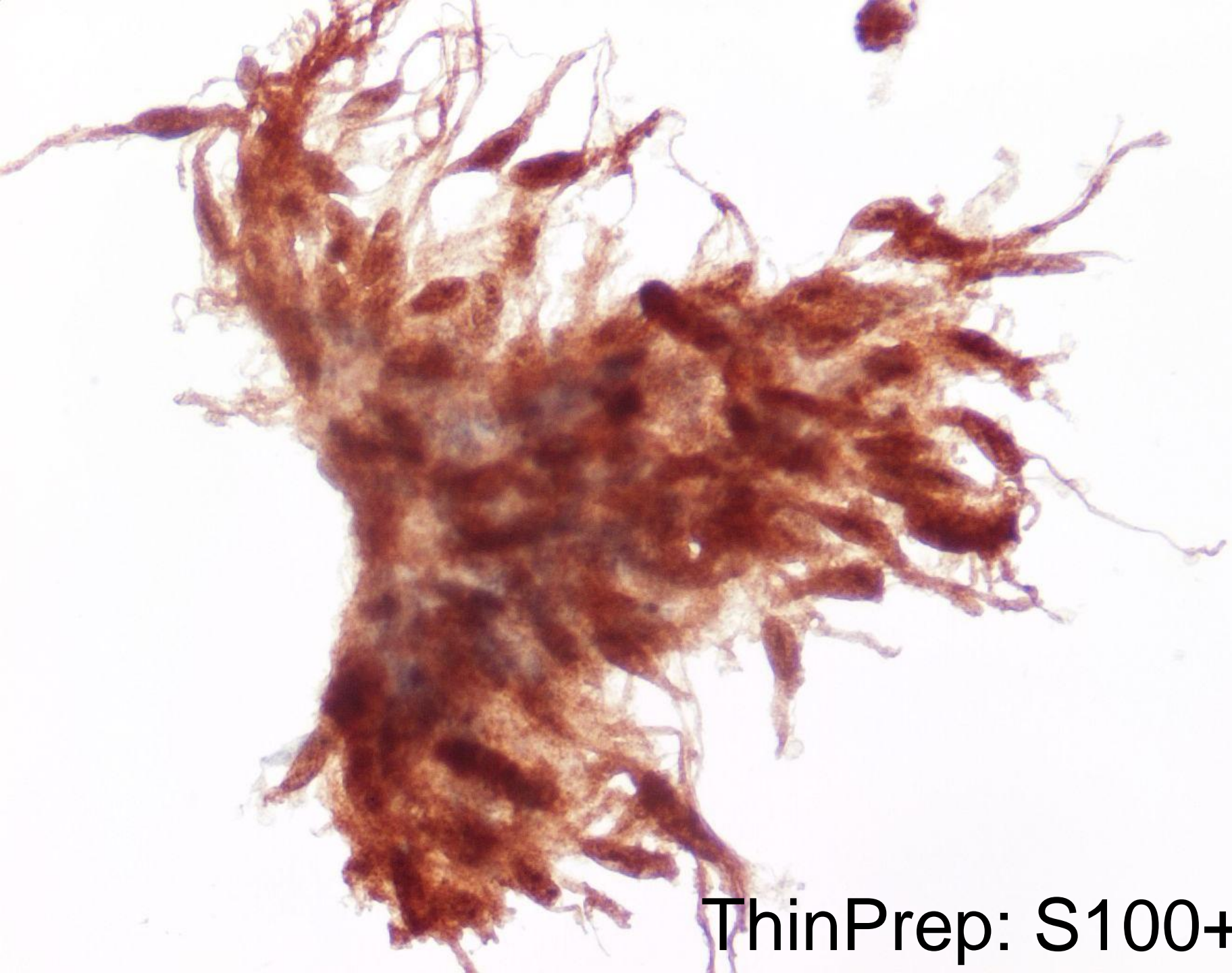










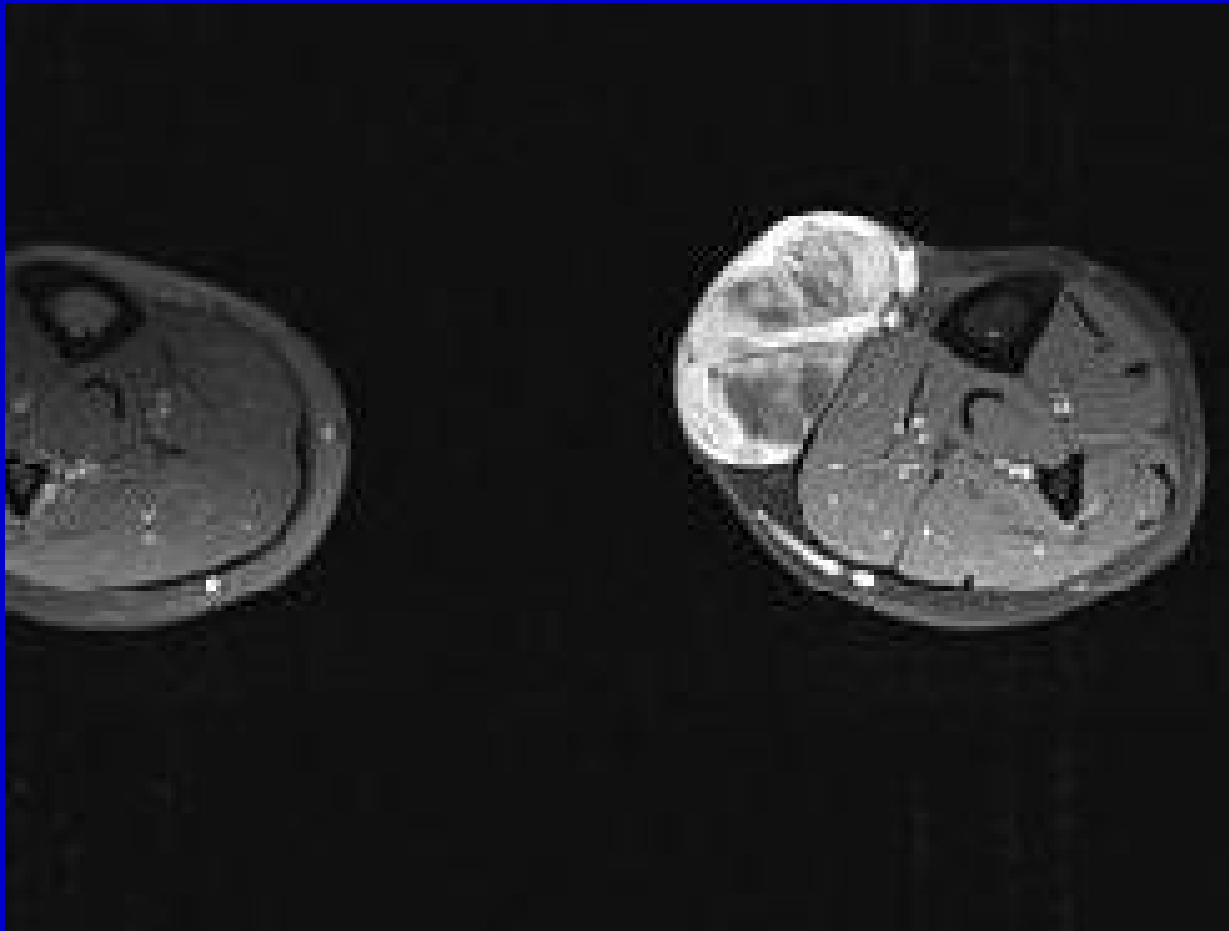


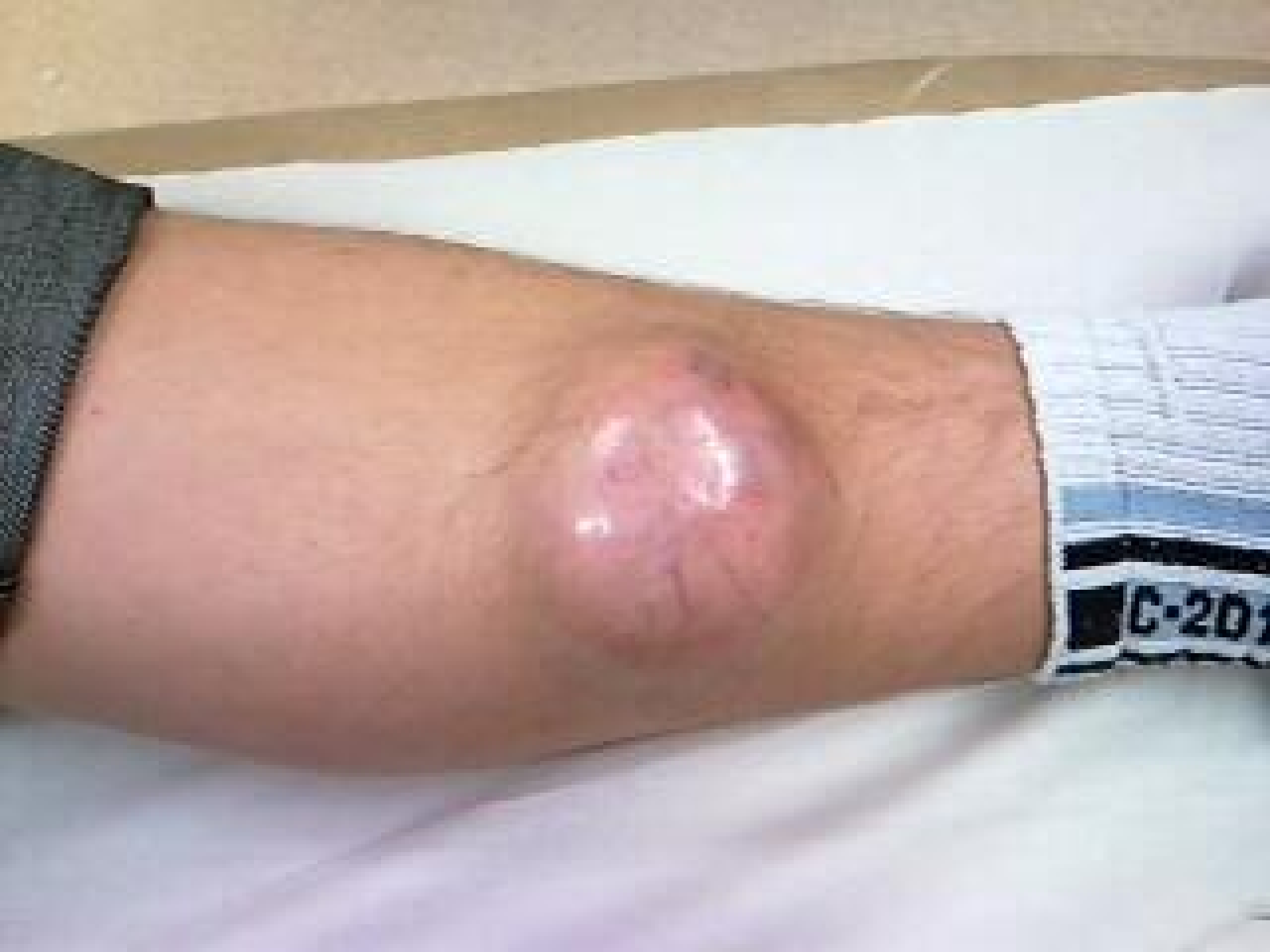ThinPrep: S100+



# Clinical history

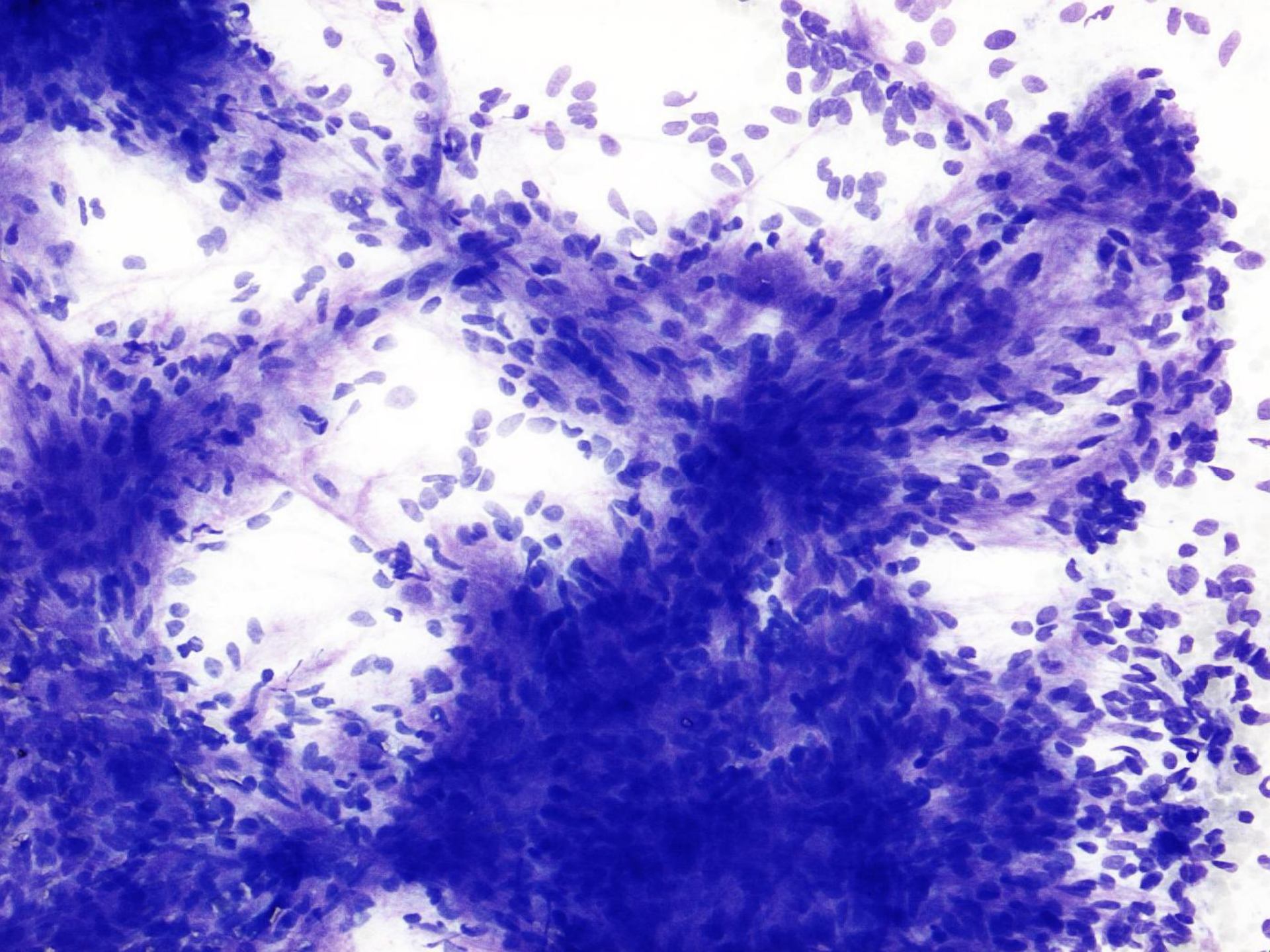
- 17-year-old boy
- 15 year (!) history of a slowly growing subcutaneous nodule in the left lower leg



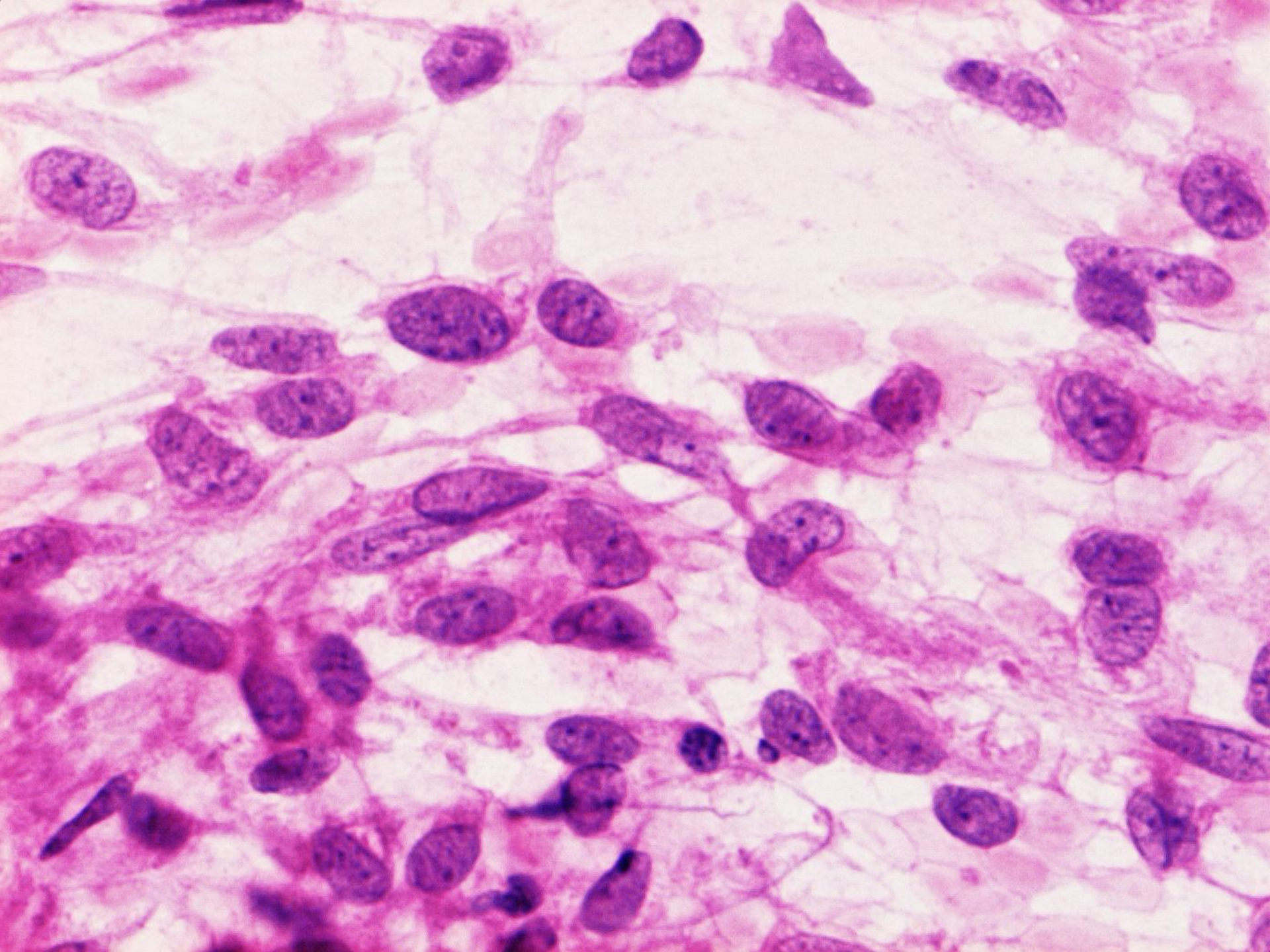


G-20



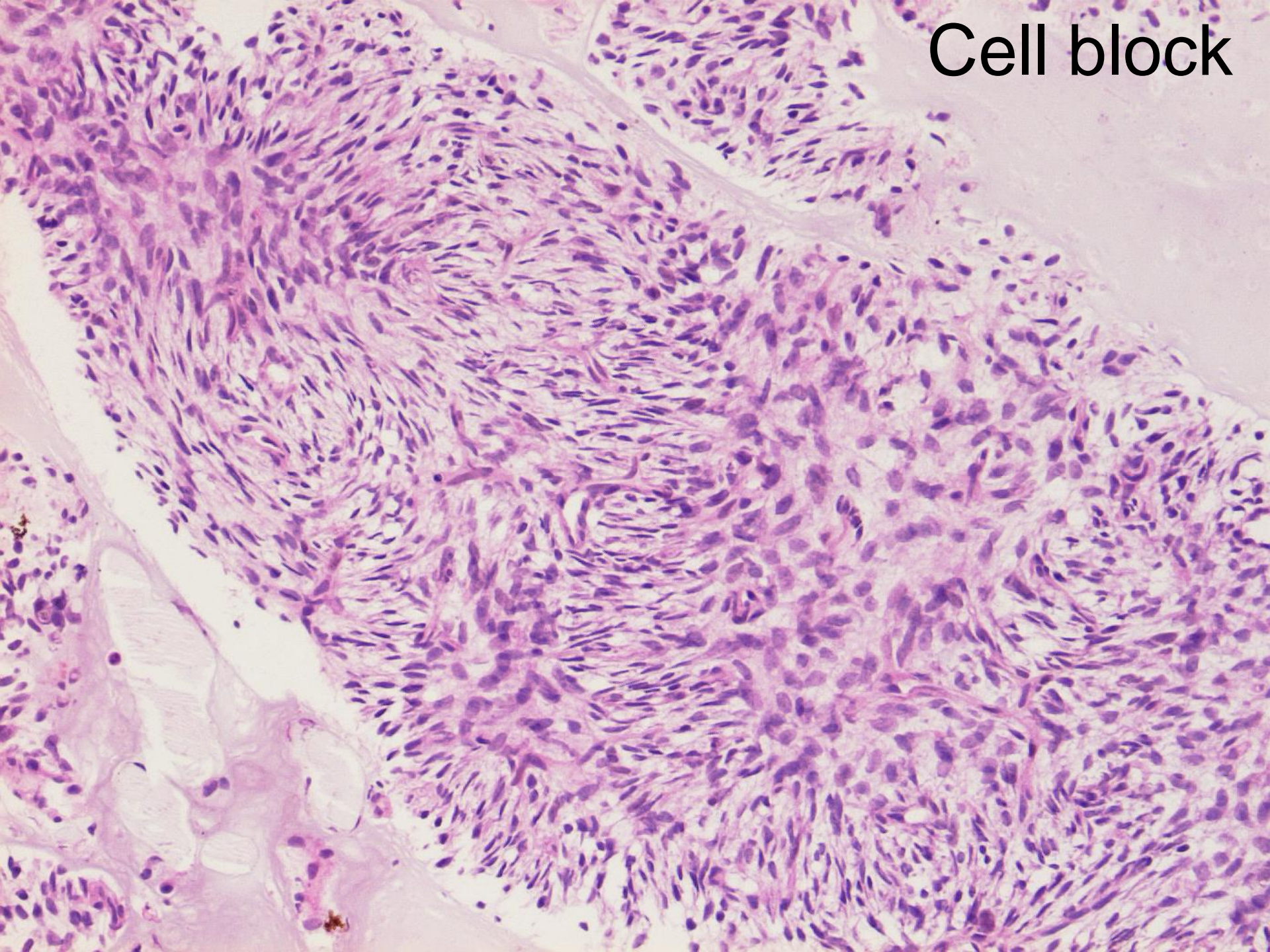




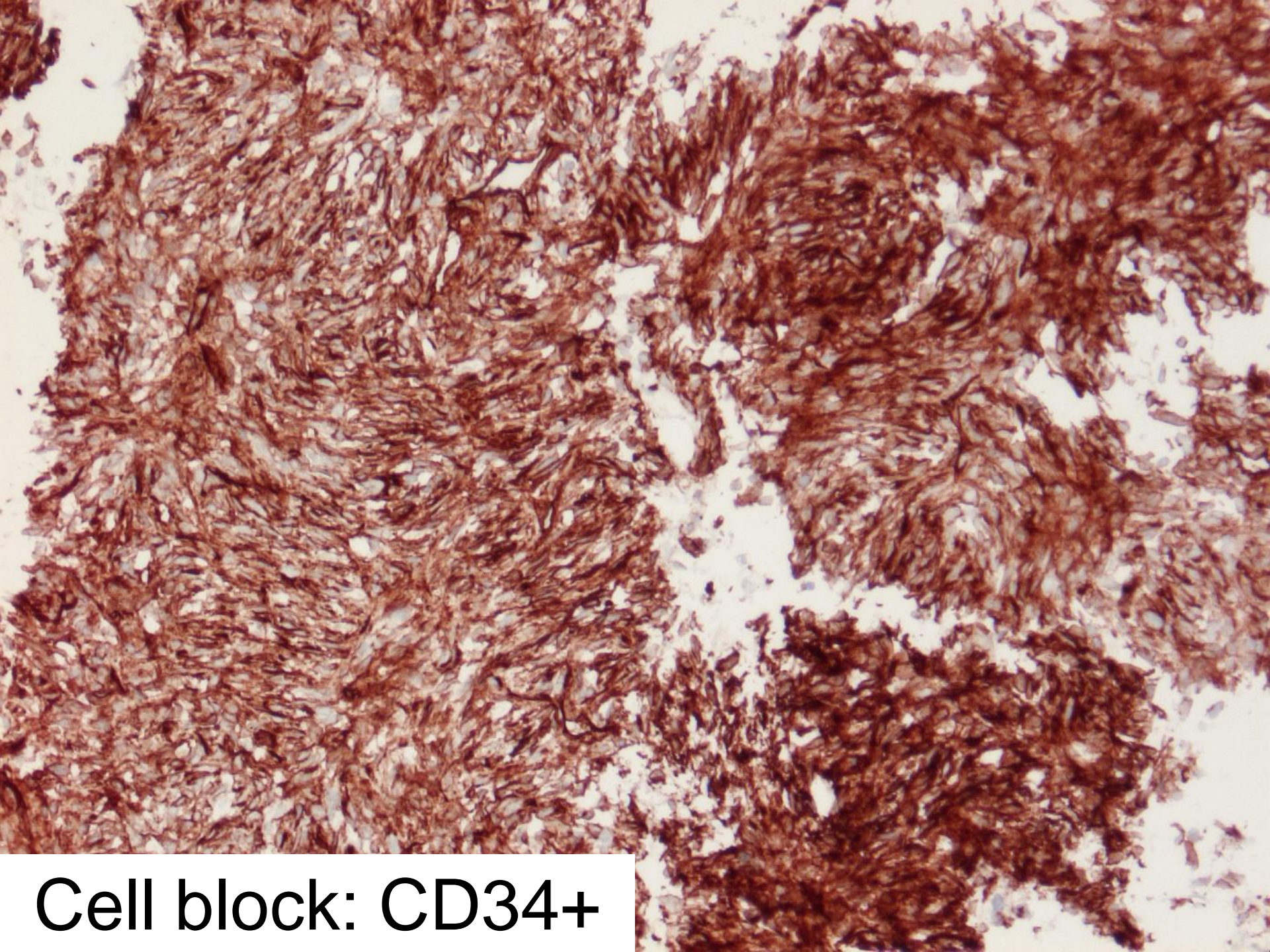




Cell block







Cell block: CD34+



# Complications

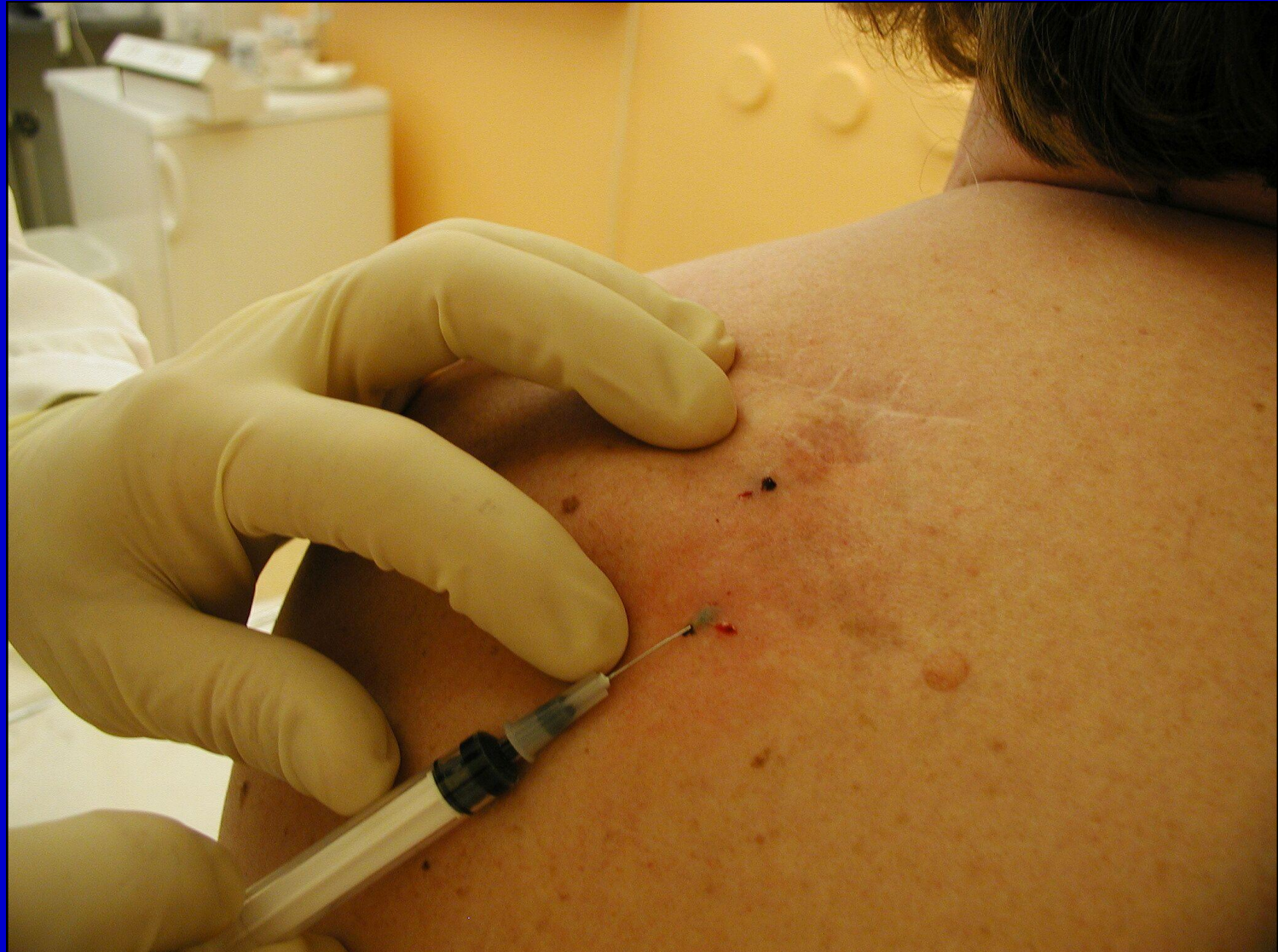- Bleeding- yes (minor)
- Infection
- Pneumothorax
- Tumor cell spread ???

# Tumor cell spread along needle track

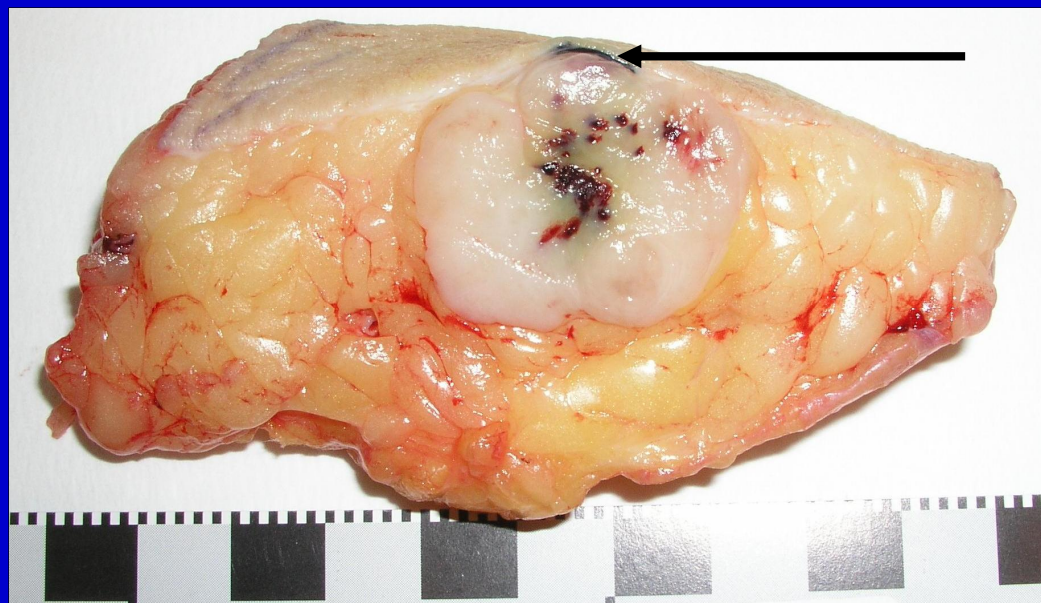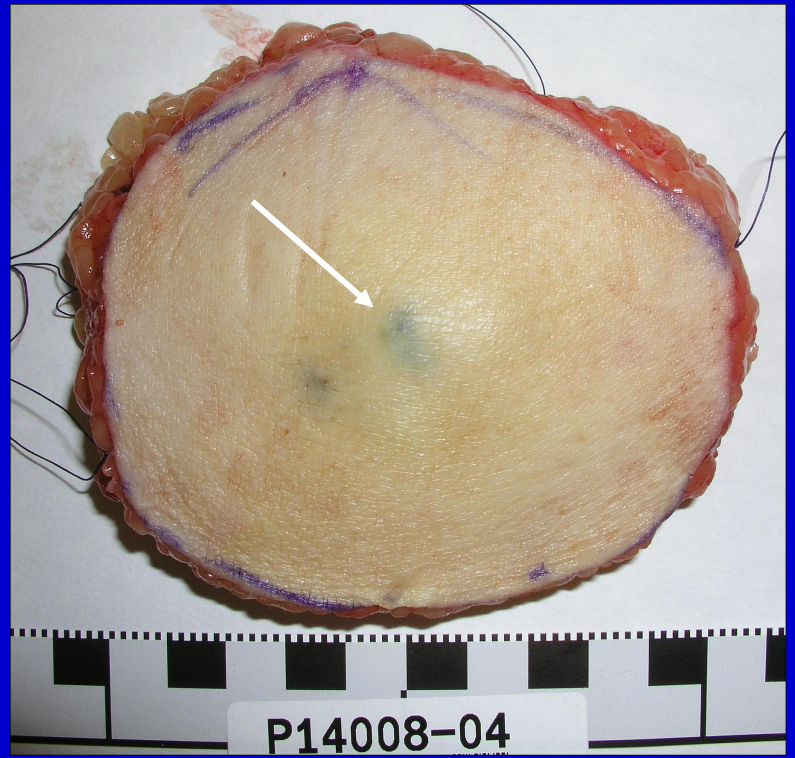
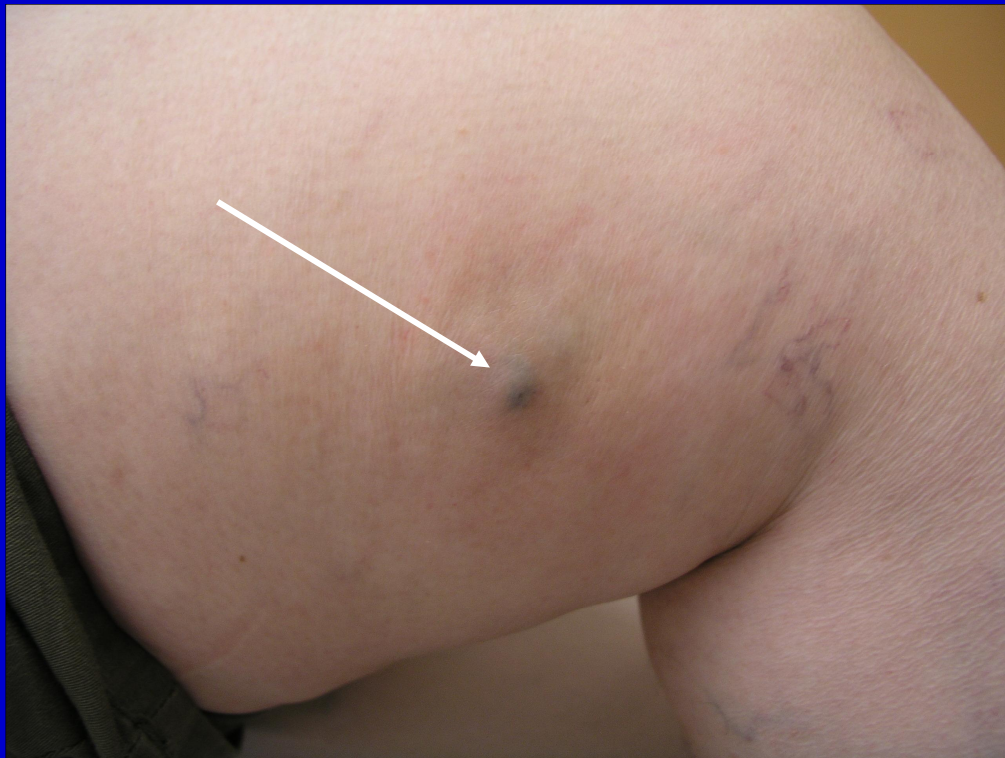- Few cases reported
- Relationship to the size of the needle and tumor type



Tattooing the puncture site helps the surgeon to remove needle track.









- Correct cytologic diagnosis of soft tissue tumors is facilitated when FNAC is used in the context of the clinical findings and when the cytological diagnosis is based on strict cytological criteria as well as ancillary techniques.
- Optimal diagnostic accuracy is reached when cases are discussed in a multidisciplinary team



THANK YOU