

Pathology of the Breast

APPROVED

Rex Bentley, M.D

Department of Pathology



Today's Goals:

By the end of the lecture you will be able to:

1. Describe the clinical presentation of common breast pathologies
2. Explain what "fibrocystic change" means and discuss several of the most common benign lesions of the breast
3. Recognize and describe the pathology associated with the common types of breast cancer
4. List and discuss the major prognostic factors in breast cancer
5. Explain why testing for expression of estrogen receptor and Her2/neu is an important part of breast cancer analysis

Structure of Lecture

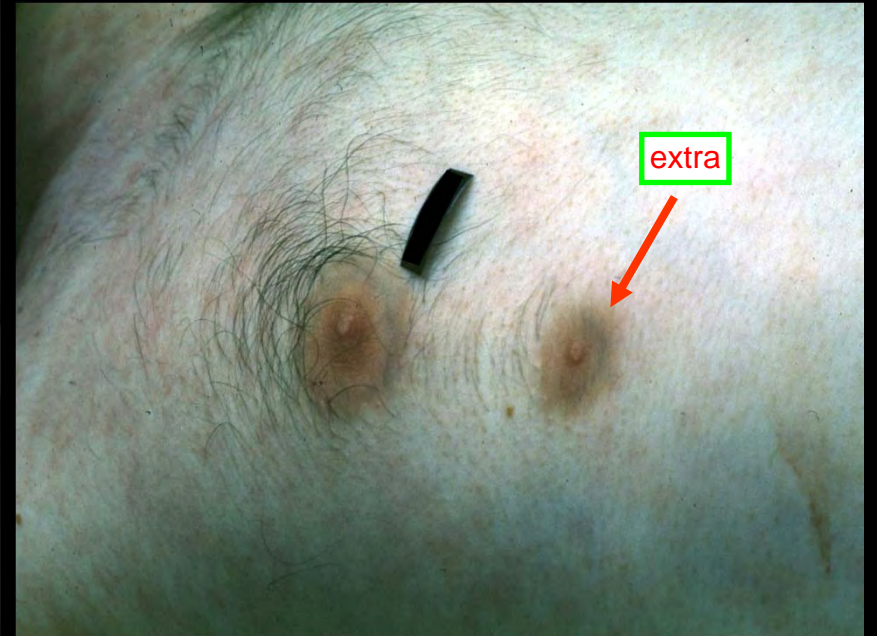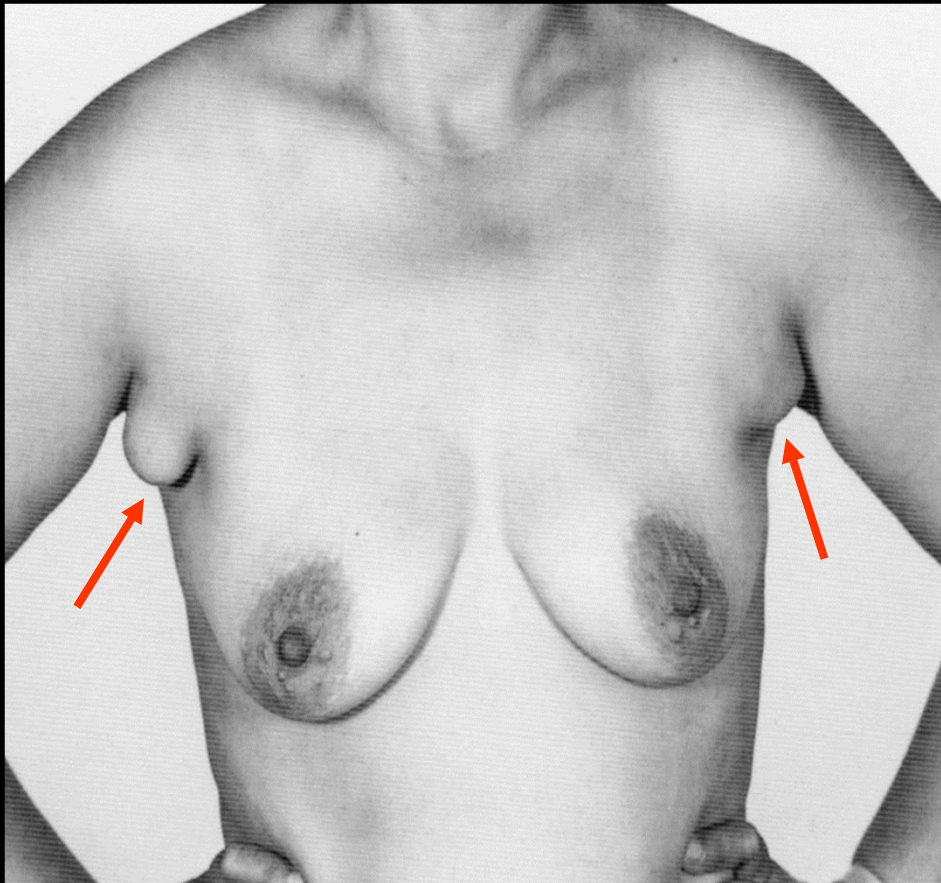
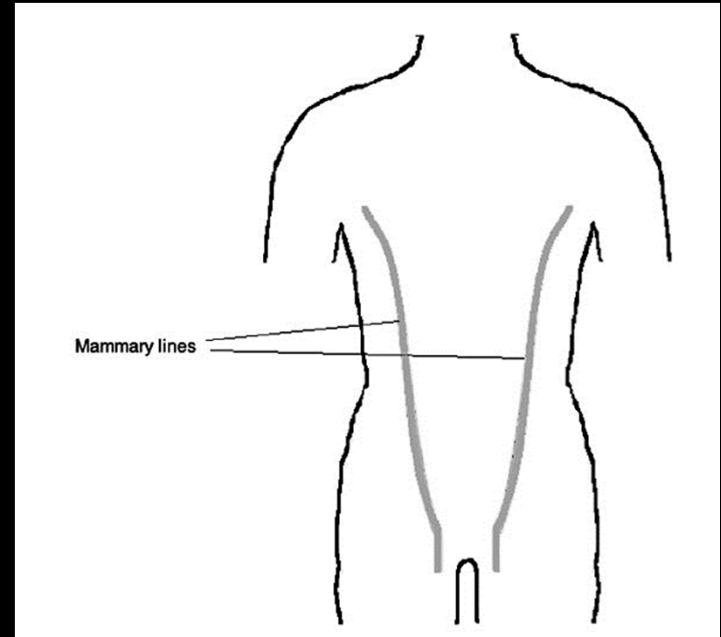
1. Review anatomy/histology
2. Clinical presentations of breast disease
3. Benign breast diseases
4. In-situ neoplasms
5. Malignancies
 - a. Classification
 - b. Prognosis/treatment
6. Additional topics (not covered in lecture)
 - a. Special presentations of breast cancer
 - b. Male breast

Embryology of the Breast

- Modified **sweat gland**
- **Mammary ridge** in embryo --multiple potential breasts multiple nipples in development--as for cats and dogs--but people usually only develop one on each half of the body
- Only **one on each side** develops normally
- Accessory breasts **1%** of population, male or female, **anywhere** on mammary ridge from **axilla to groin** you will see the mammary ridge on the next slide

usually just cosmetic addition, but anything that can occur in a normal breast can occur in an accessory breast (eg cancer)

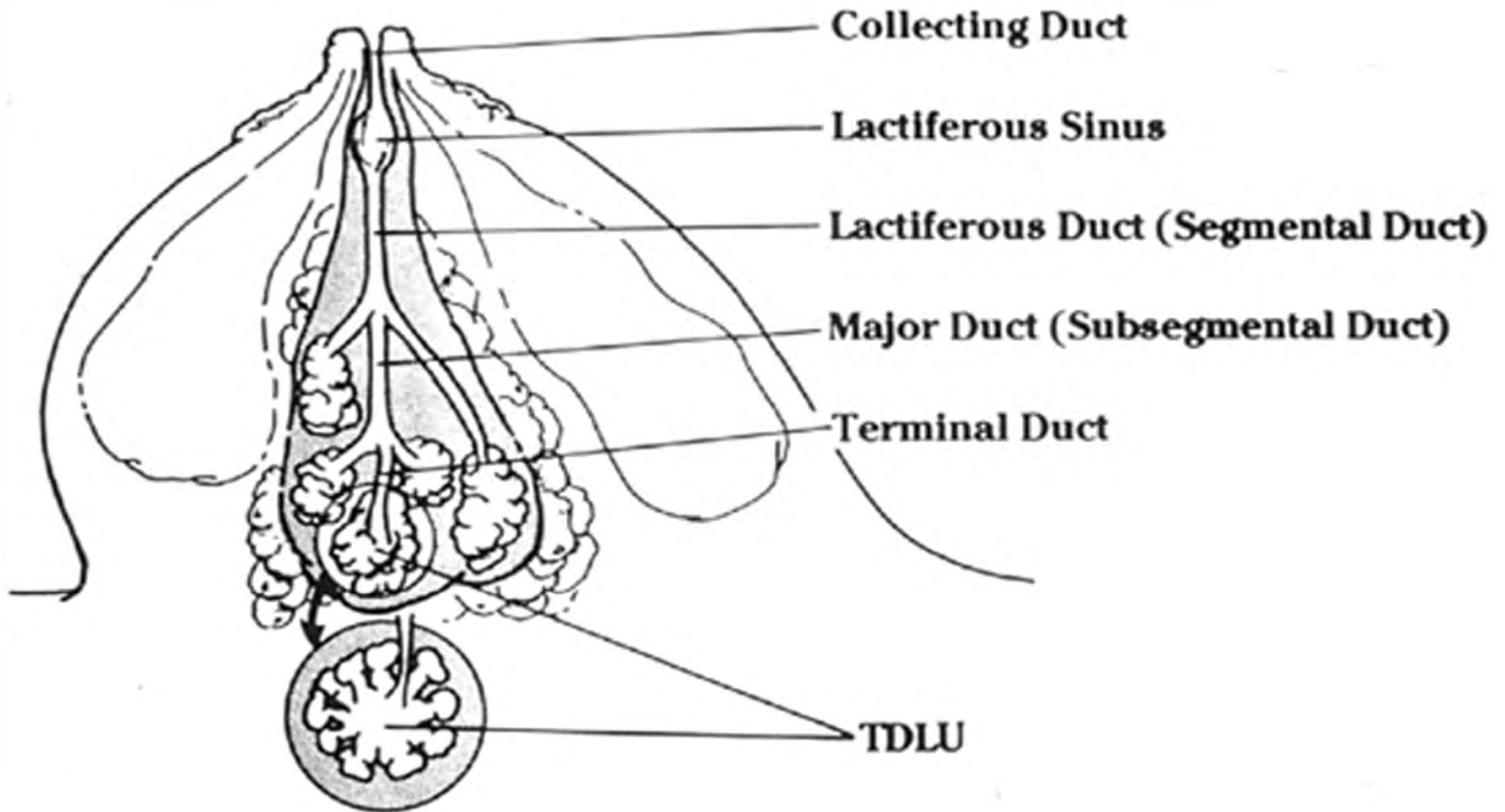

Accessory Breast



basically two components: ducts and lobules

what you see in the following slides is **NORMAL**

Breast, Anatomy

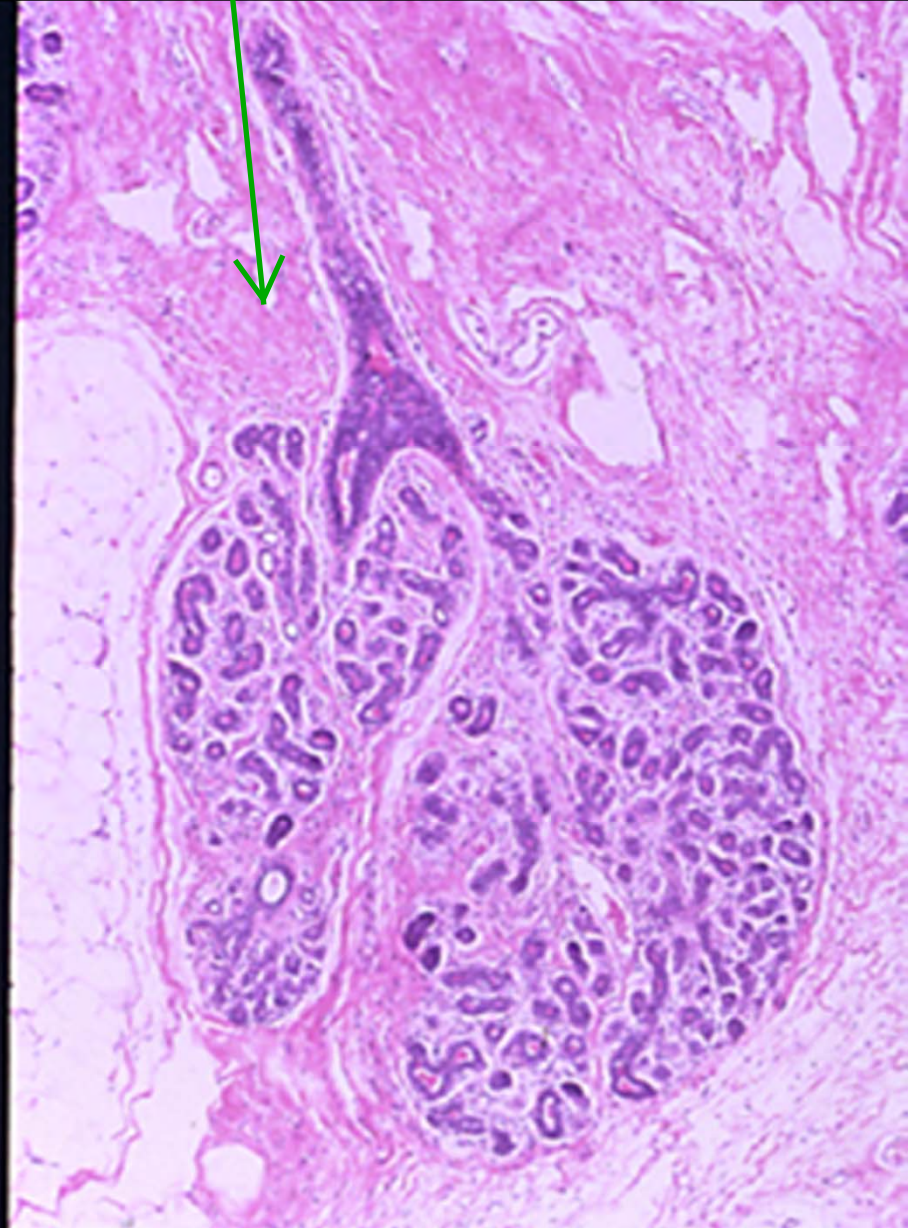
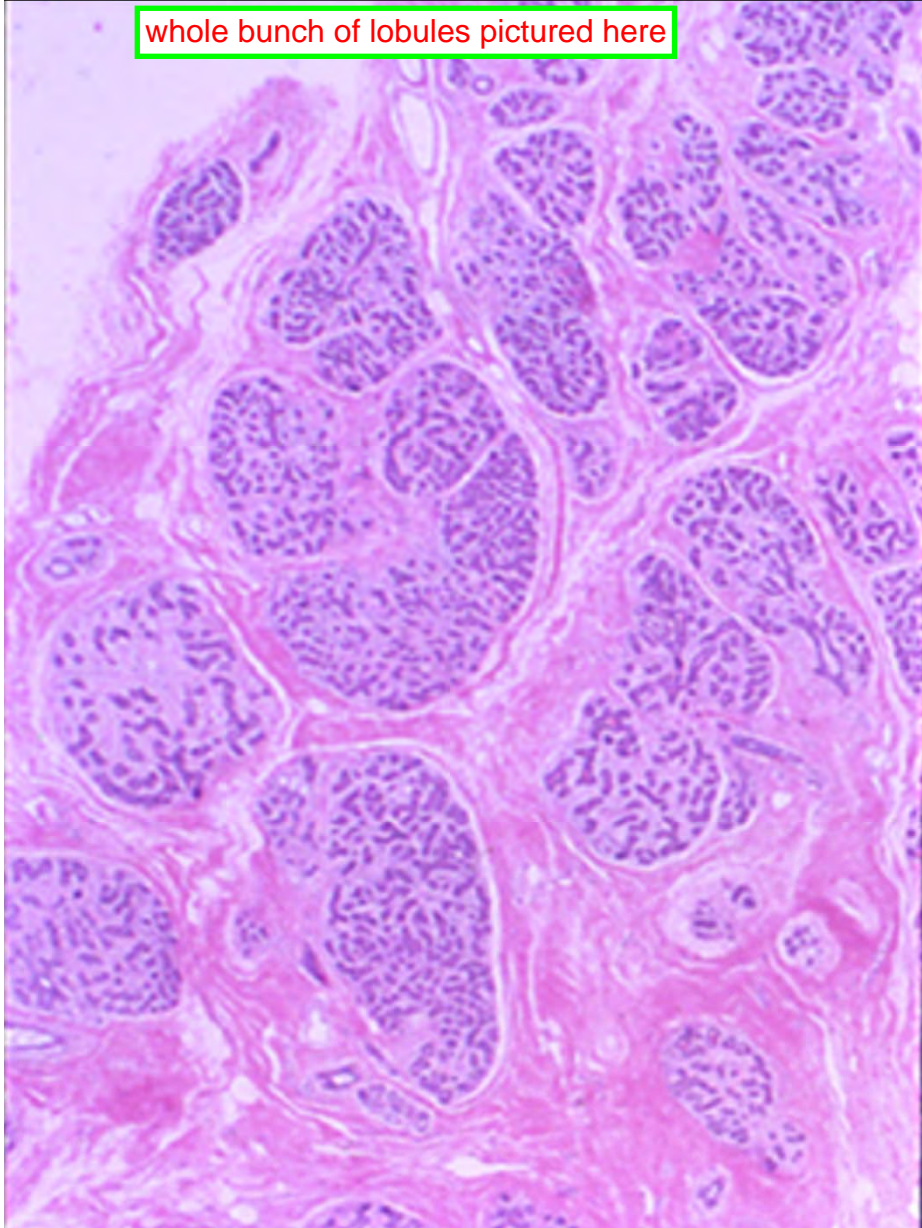


lobules (which aren't super distinct in the breast tissue) make milk that empty into ducts

Terminal duct lobular unit

Breast, Normal TDLU

whole bunch of lobules pictured here



TDLU

Terminal Duct Lobular Unit

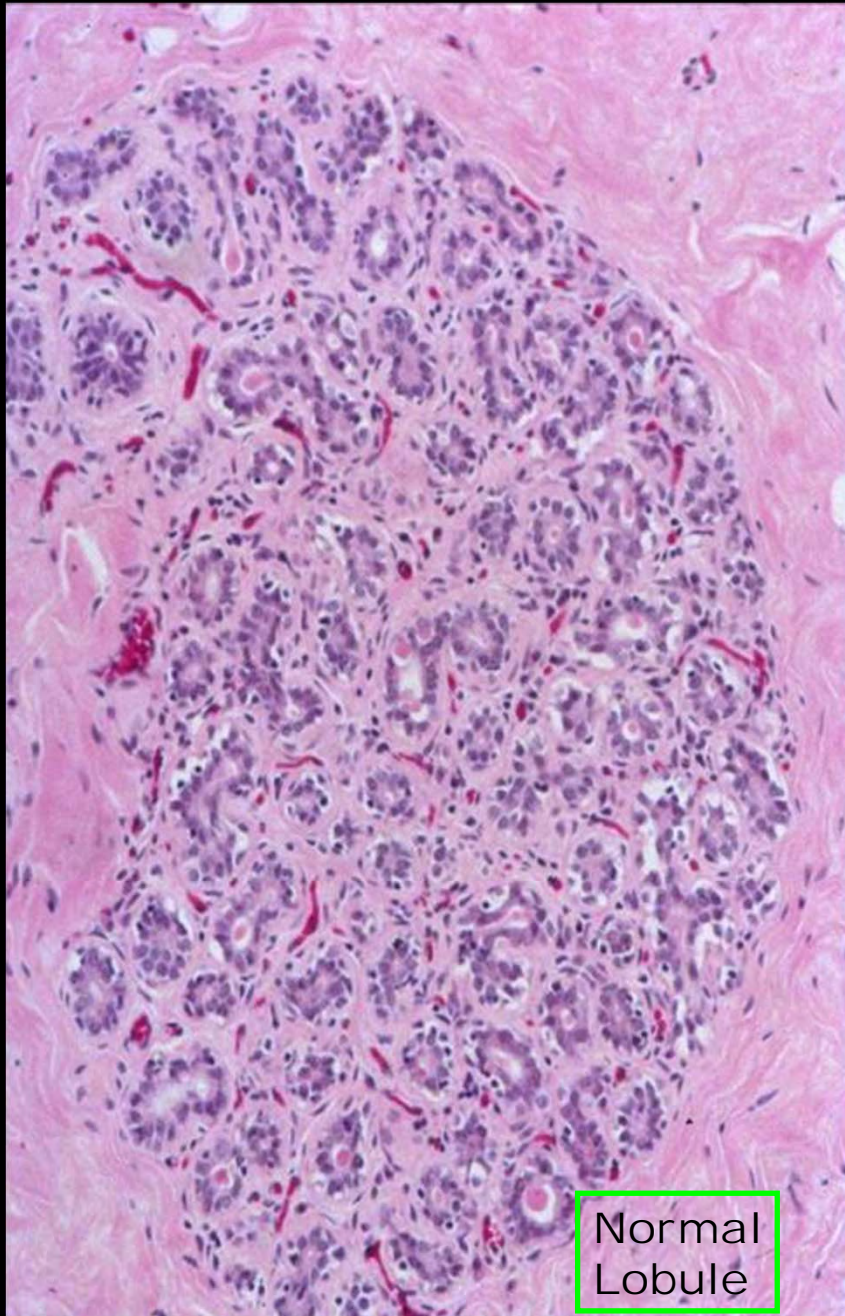
- **Lobule (acini)** composed of small glands
- Acini grow at **puberty; suppressed** by even low levels of **testosterone**
- Acini and duct lined by **2 cell layers**
 - **Myoepithelial** cells (outer cell layer)
 - Flattened cells, often clear cytoplasm
 - **Epithelial** cells (inner cell layer)--most cancers derived from this layer

in men (do not usually have these acini)

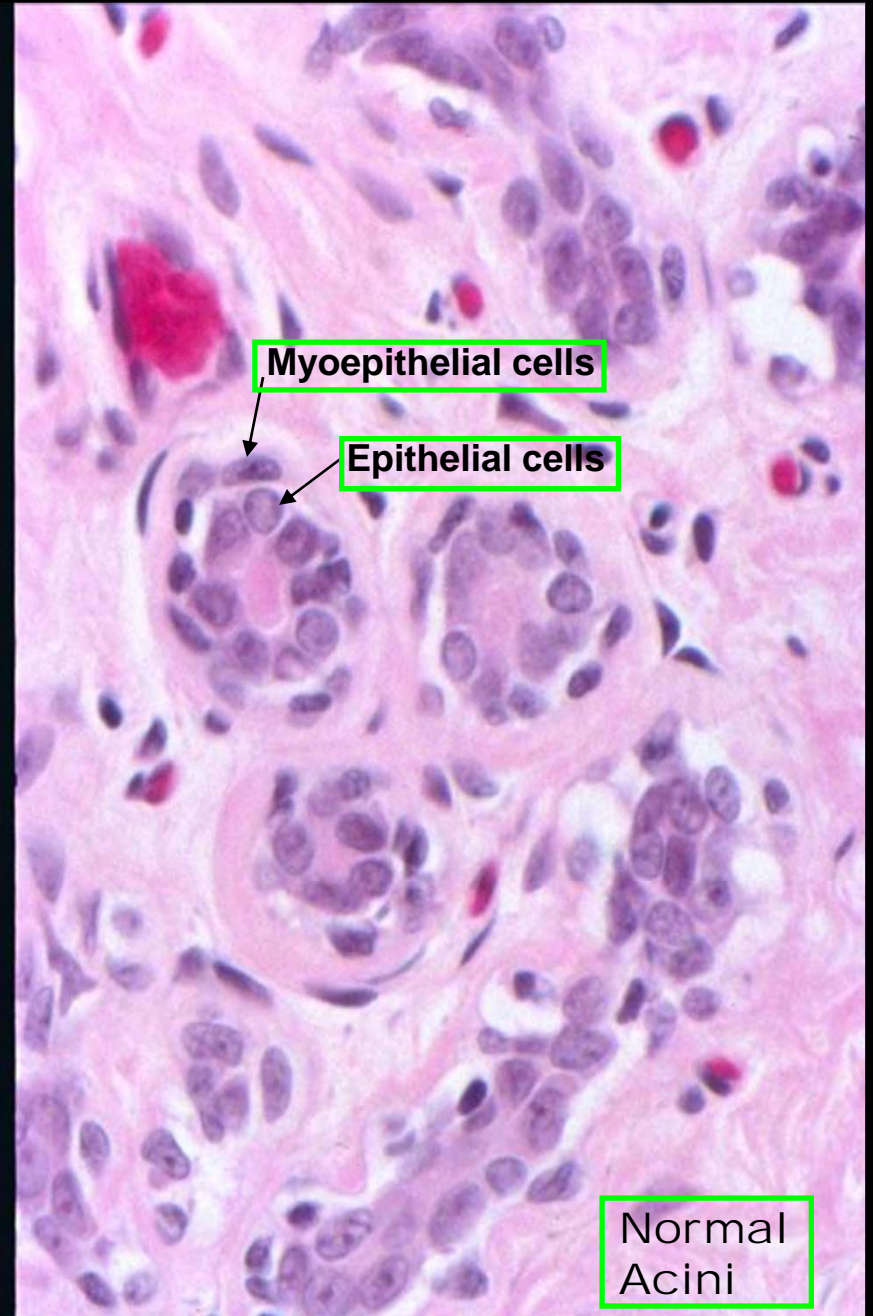
smooth muscle features; fairly inconspicuous histologically; pushes milk out

this layer makes most of the milk and most cancers are derived from this layer

Breast Anatomy



Normal Lobule



Myoepithelial cells

Epithelial cells

Normal Acini

Stroma

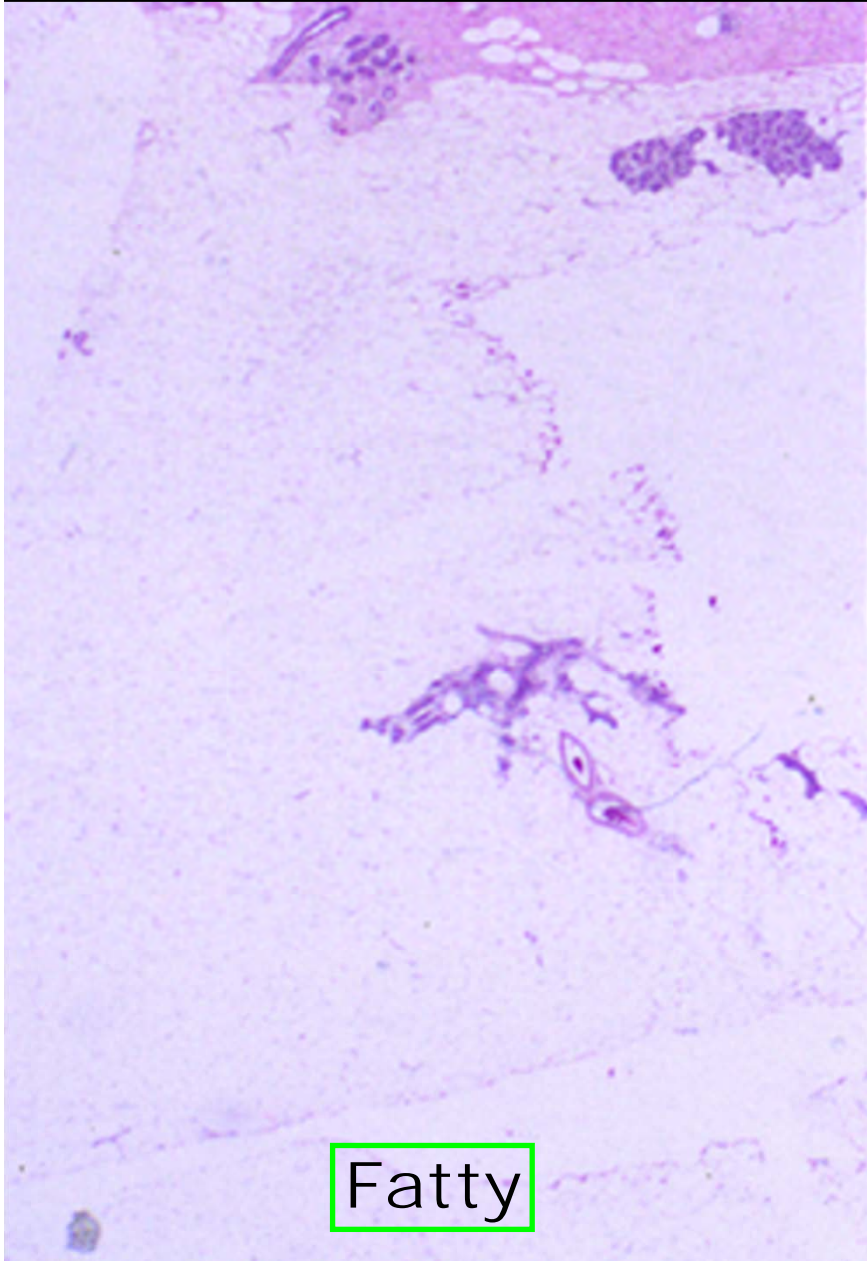
doesn't cause a lot of pathology, but there is a lot of variation between person-to-person (breast-to-breast)

uniqueness can create problems for mammographers

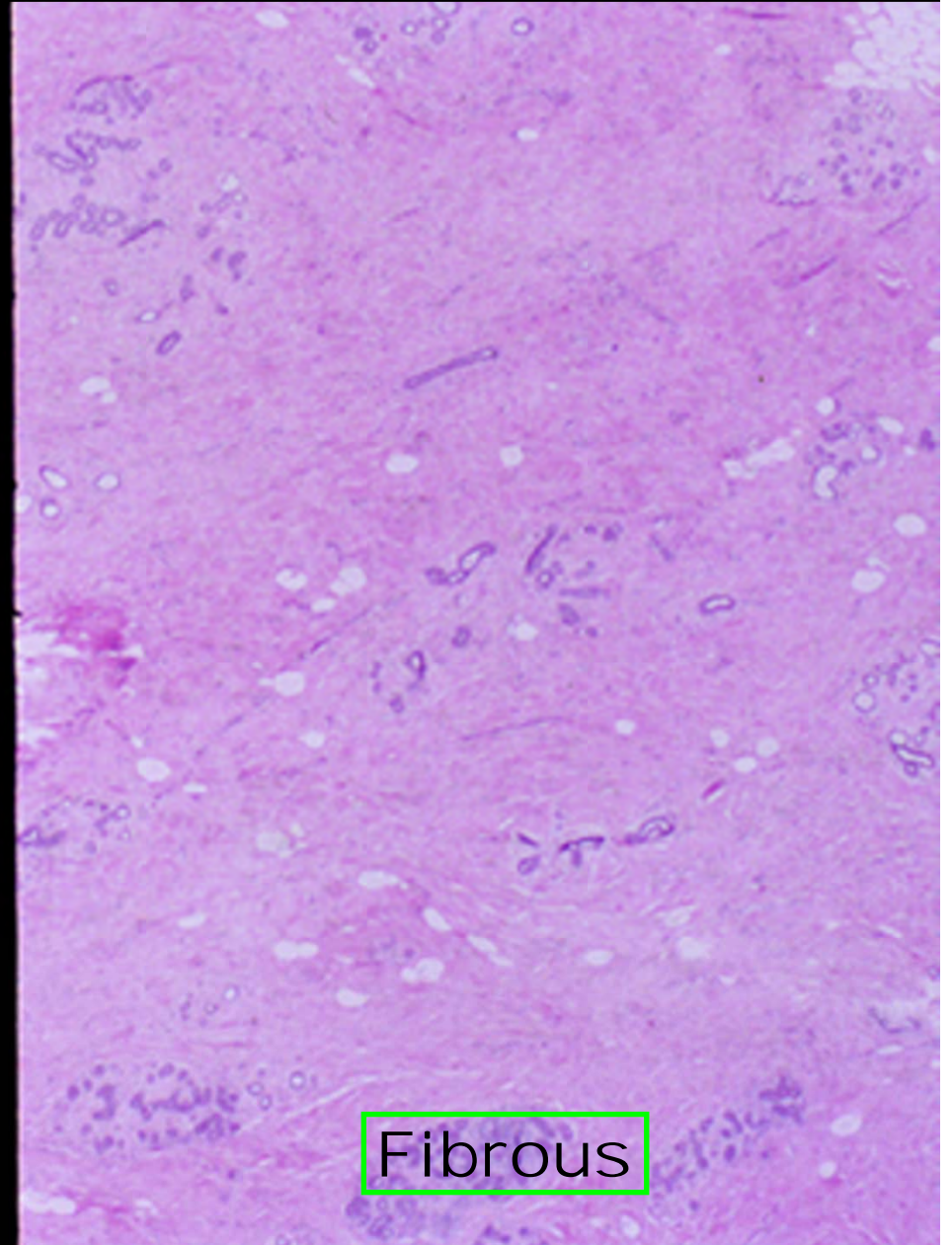
- Large **variation** in amount of fibrous stroma
- Varies **between individuals**, and with menopause/hormone status **within individual over time.**

both images are totally normal: fatty and fibrous

Normal Breast



Fatty



Fibrous

Variation in normal mammograms

Fatty--
radiolucent

"easier" to pick out cancer amidst dark background

Fibrous--
radiodense

very difficult to pick out cancer in this background

Mixed-
heterogenous

a lilbit harder to pick out cancer amidst background

Benign Breast Lesions

- **Non-neoplastic**
 - **Inflammatory**
 - **Fibrocystic changes**
 - **Proliferative breast changes**
 - **Proliferative breast disease with atypia**
- **Benign neoplasms**

Benign Breast Lesions

Why do we care?

- Many can mimic malignancy:
 - Lumps on physical exam
 - Microcalcifications or masses on mammograms
 - Bloody nipple discharge
- Some are risk factors for developing future breast cancer
- **Benign** lesions are much more common than cancers.

Breast Disease:

A **common reason** to see the Doctor!

- 16% of women in large group practice sought medical attention for breast symptoms over 10 year period
- **Only 4% of visits** for breast symptoms resulted in **dx of cancer**

Breast Disease:

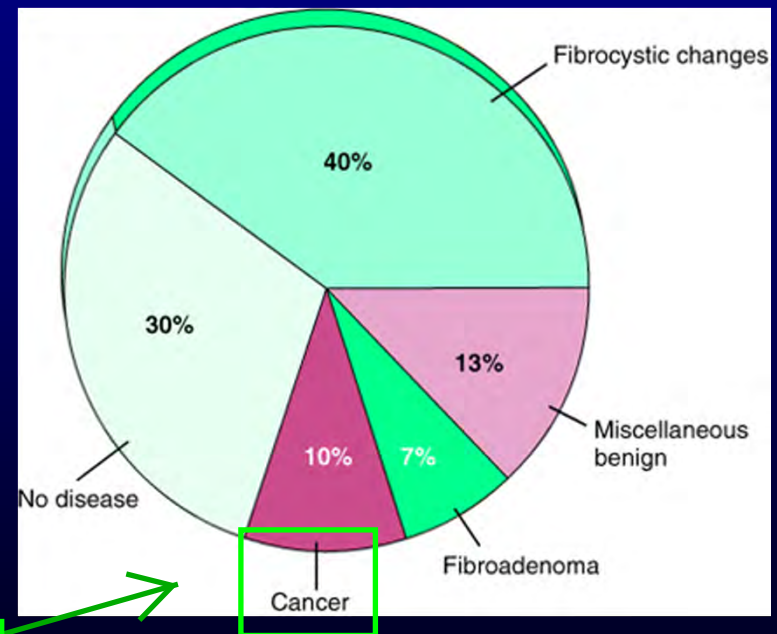
Most common clinical presentations

- **Pain**
 - Rarely is sole sign/symptom of CA
- **Palpable mass (“lump”)**
- **Bloody nipple discharge**
- **Mammographic Abnormalities**
 - Density (mass)
 - Microcalcifications.

again, most breast lesions are benign



Unlike medical school professors, most breast lesions are benign



not very much

Pathologic findings in women with "lump"

Inflammatory Conditions

Mastitis

- **Acute** mastitis: **Bacterial infection,** usually while **beginning nursing**
 - Red, hot, swollen, painful breast
 - Can develop abscess, extensive tissue destruction
- **Plasma cell** mastitis: **Non-bacterial,** chronic irritation from secretory products
 - Usually in **multiparous** woman, nursing

usually when skin breaks

Inflammatory Conditions

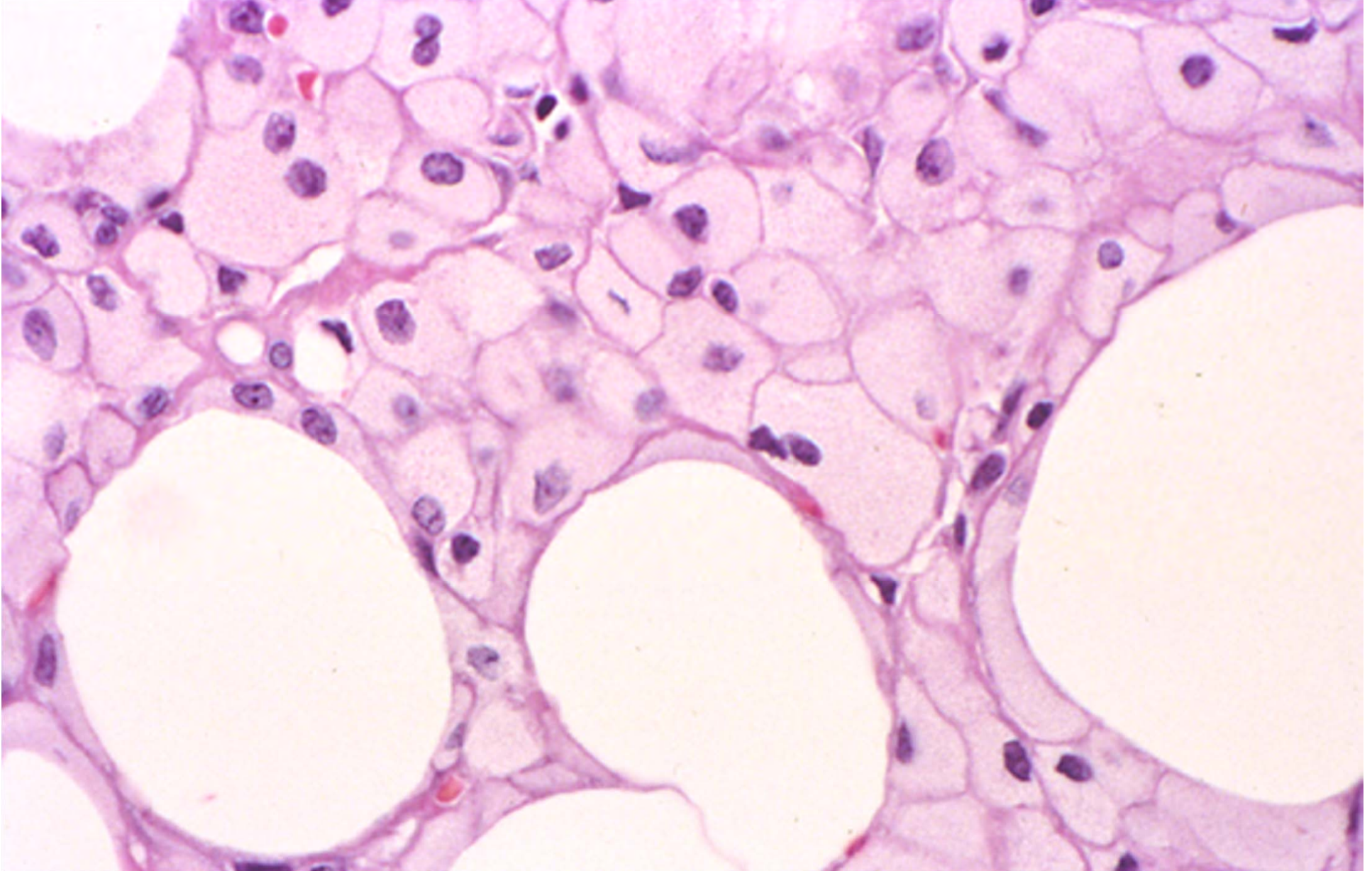
Fat Necrosis

the trauma doesn't have to be "that severe" for this to occur

- **Trauma to fat**, release of fatty acids with marked **inflammatory response**
- Heals by scarring
- **Excellent cancer mimic**
 - Rock hard, spiculated mass
 - Microcalcifications on mammogram

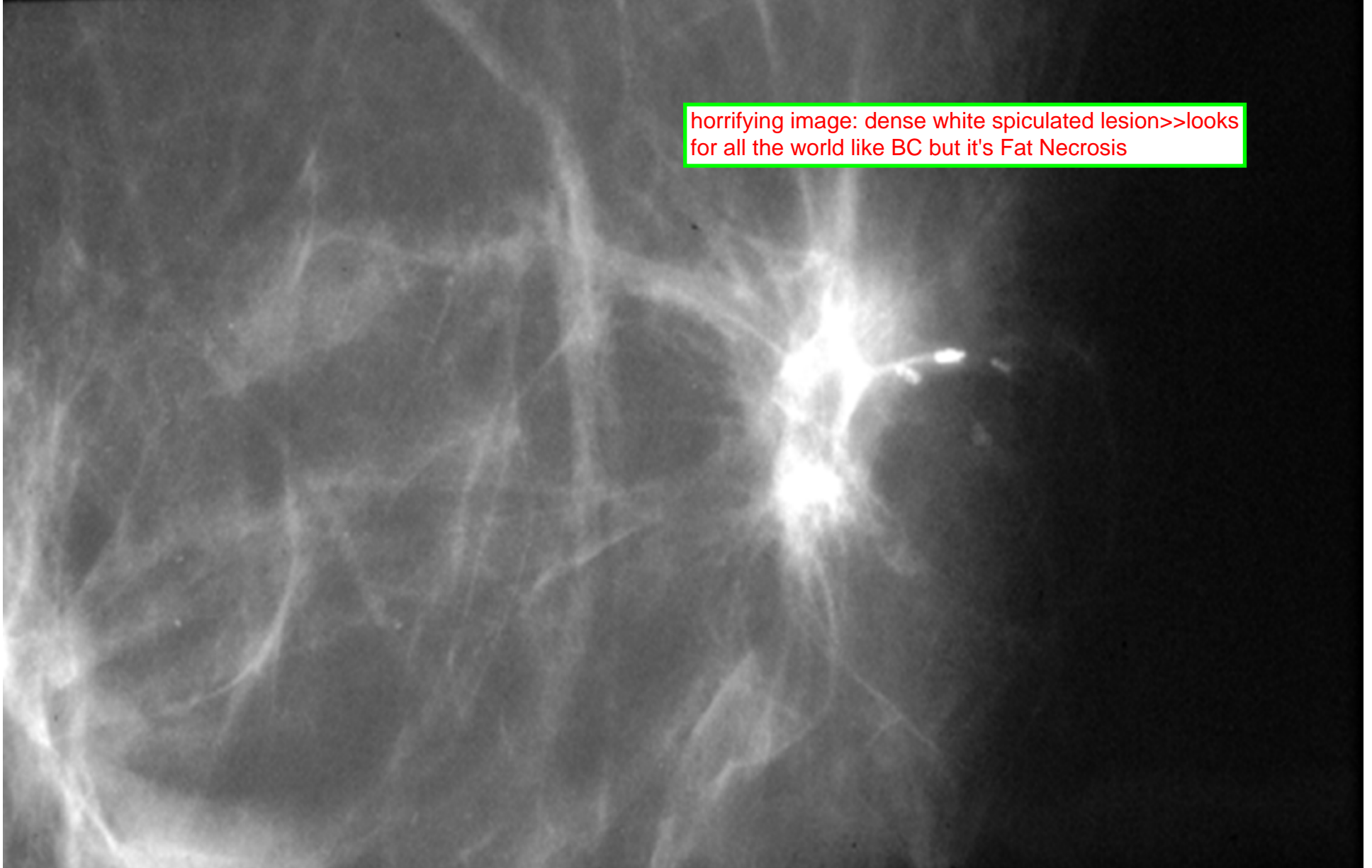
macrophages full of fat
help to distinguish Fat
Necrosis from Breast
Cancer--pew!

Histology of fat necrosis



Mammogram, fat necrosis

horrifying image: dense white spiculated lesion>>looks for all the world like BC but it's Fat Necrosis

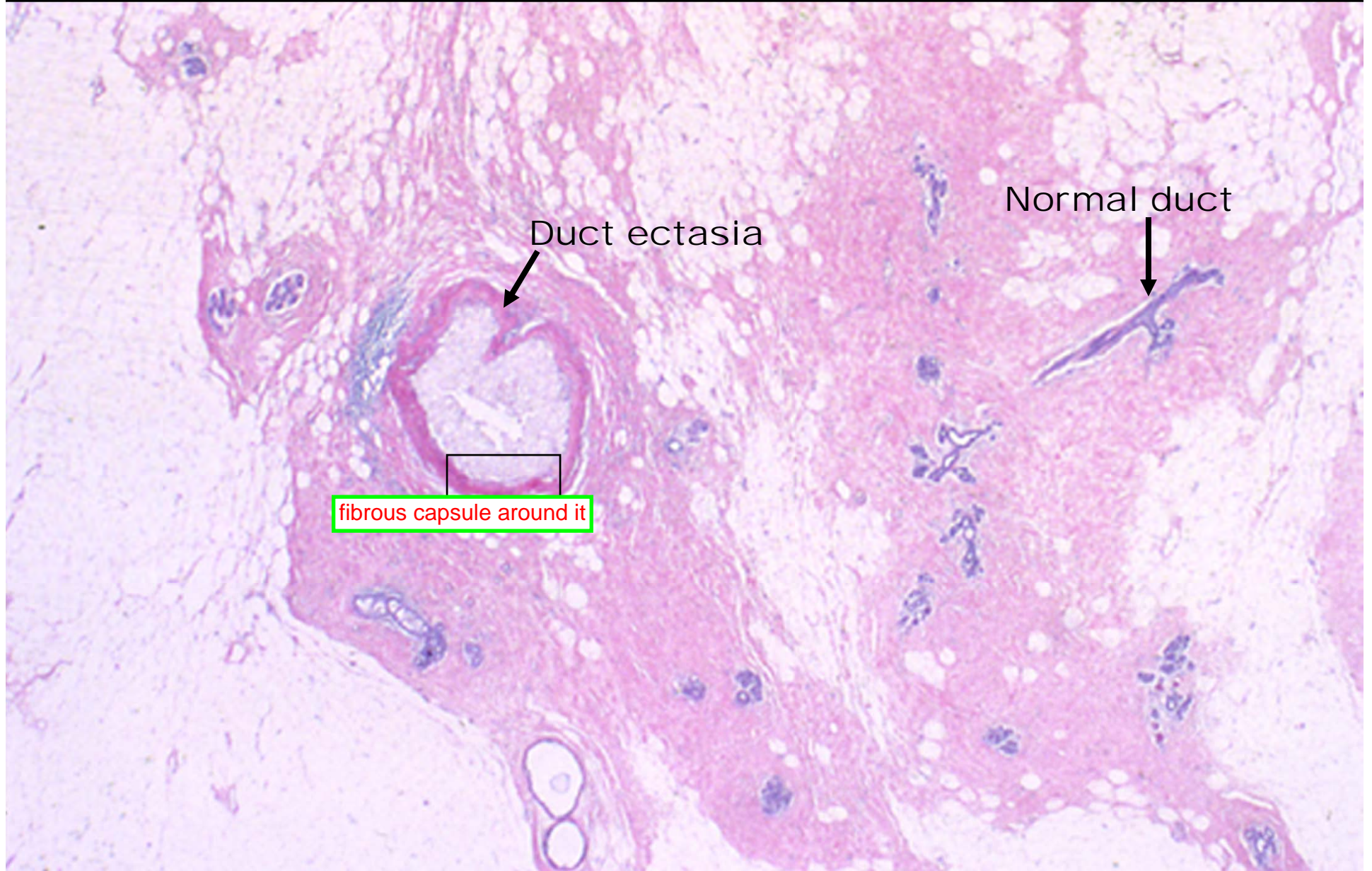


Inflammatory Conditions

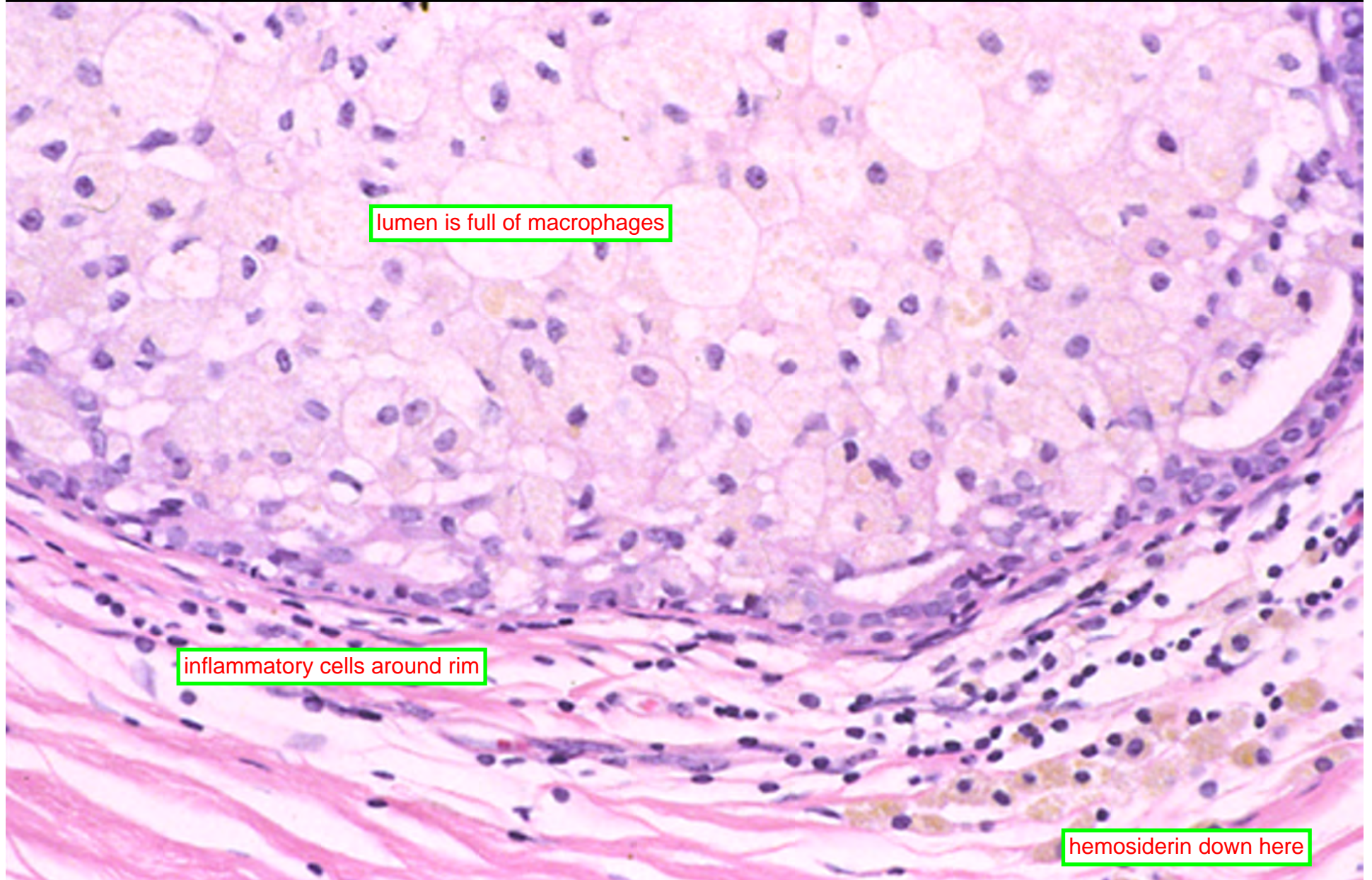
Duct Ectasia

- Inflammation **destroys duct wall**
- Common cause of nipple discharge
- Microcalcifications can mimic cancer

Duct Ectasia: low power



Duct Ectasia: high power



Benign Epithelial Lesions

- **Nonproliferative changes**
 - Fibrocystic change
 - Fibroadenoma
- **Proliferative breast disease**
 - Epithelial hyperplasia
 - Sclerosing Adenosis
 - Radial Scar
 - Intraductal papilloma

Fibrocystic Change

- **Not a disease!** normal change, doesn't hurt patient at all; starts 30s-40s in women
- A group of processes which are related only by the fact that they tend to occur together.
- Represents **exaggerated response** to hormonal stimulation
- **Present in most women (>80%)** common
- **No increased risk** for cancer

ABSOLUTELY NONE

Fibrocystic Change

aka Non-Proliferative Breast Changes

- **Fibrosis**
- **Cysts**
- **Metaplasia**
 - **Apocrine**
 - **Columnar**

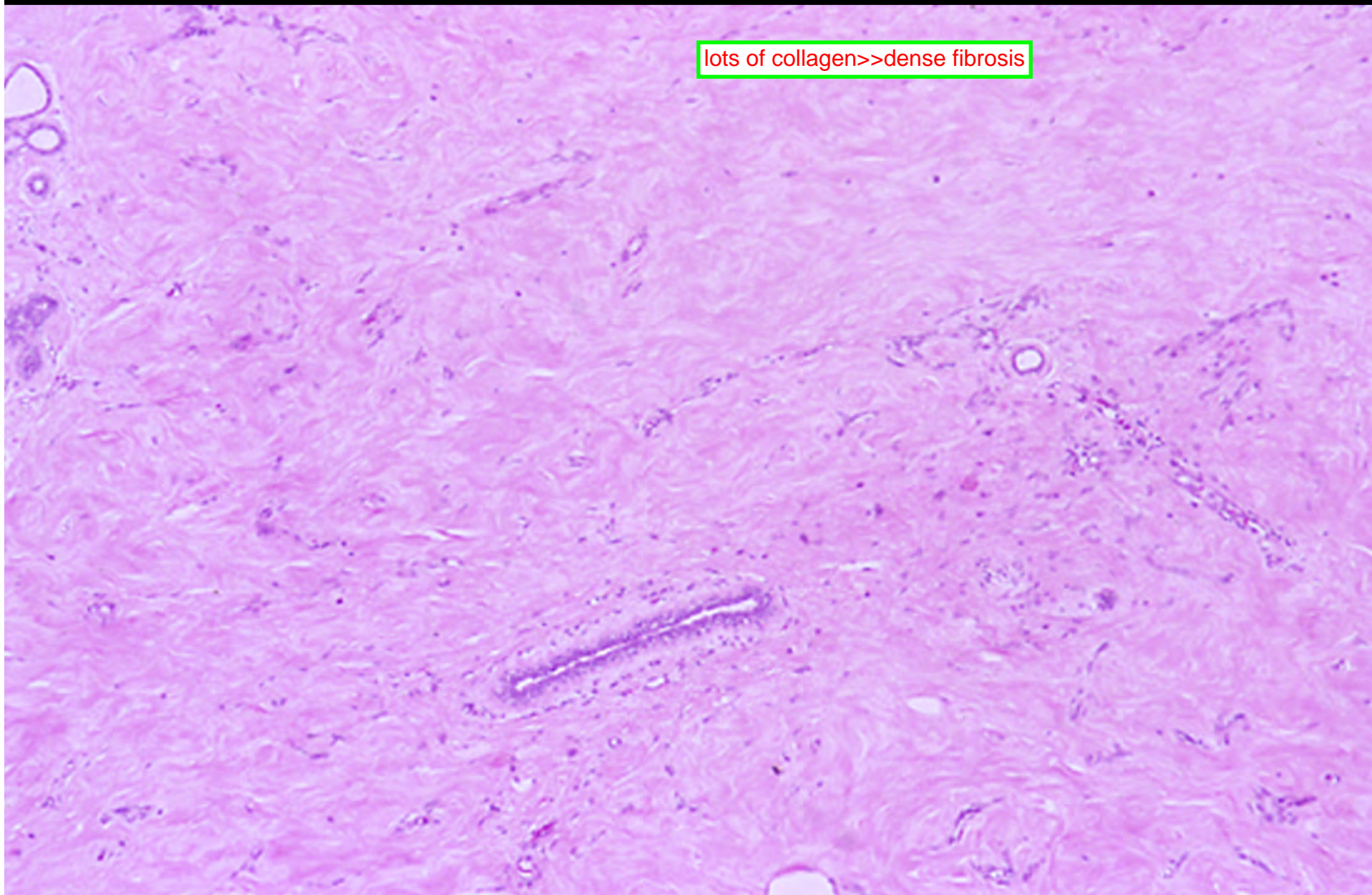
Fibrocystic Change

“Fibrosis” 1/3 parts of FCC

- Localized areas of fibrous tissue is common cause of **lump**
- This gets called “fibrosis” implying an **increase over normal...but it is just normal** breast tissue.
- Fibrous tissue in breast is **NORMAL**

Breast, fibrosis

lots of collagen>>dense fibrosis



Fibrocystic Change

Cysts

2/3 Parts of FCC

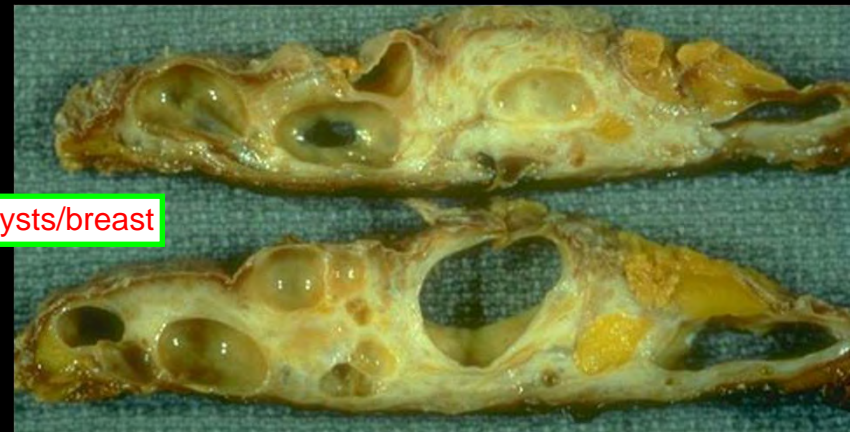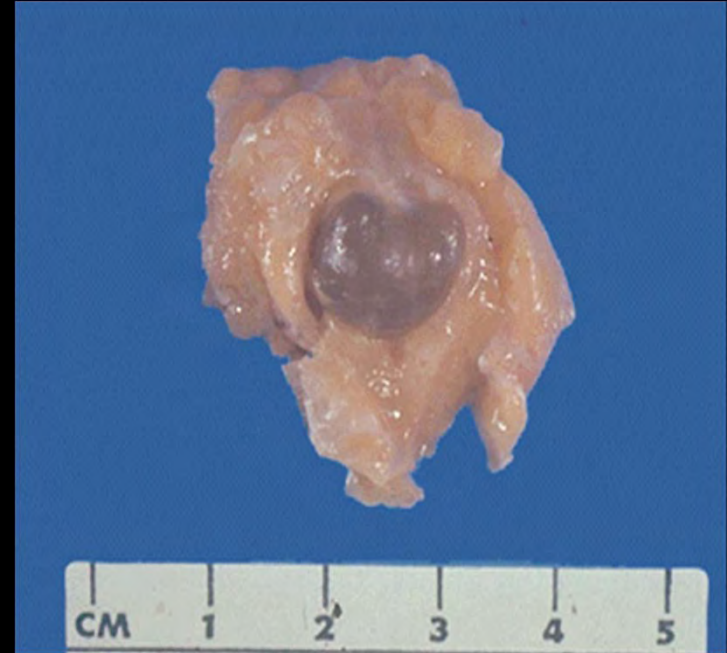- Cysts are extremely **common**
- Multiple, bilateral
- **Fluctuate** over time
- **Disappear** with fluid **aspiration**

cysts are generally bluish in color, are filled with clear fluid, and are lined by simple cuboidal epithelium

Fibrocystic Change

Cysts

- Translucent “**blue dome**” cysts
- **Clear colorless** fluid
- Lined by **simple cuboidal epithelium**



can be quite dramatic clinically--multiple cysts/breast

Fibrocystic Change

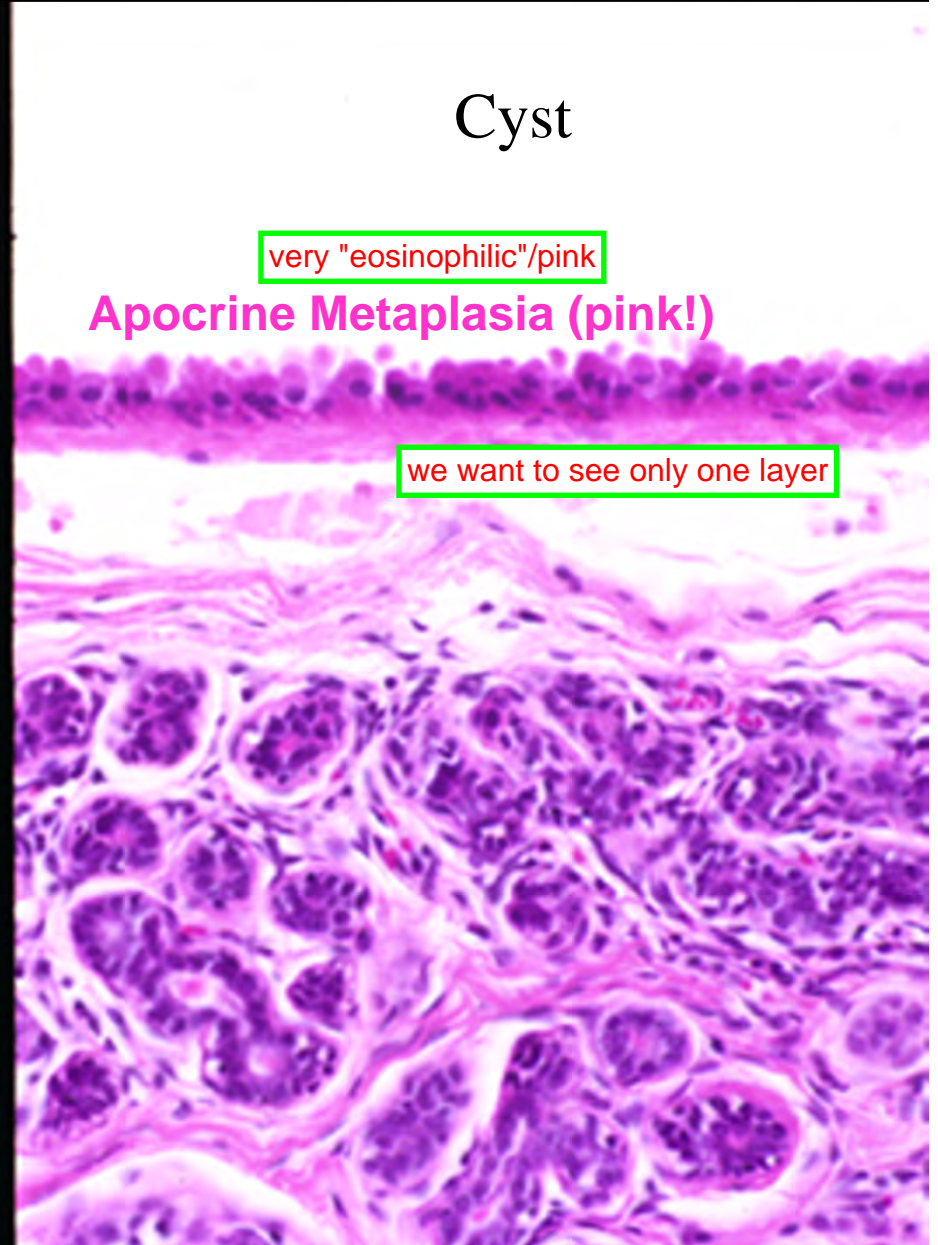
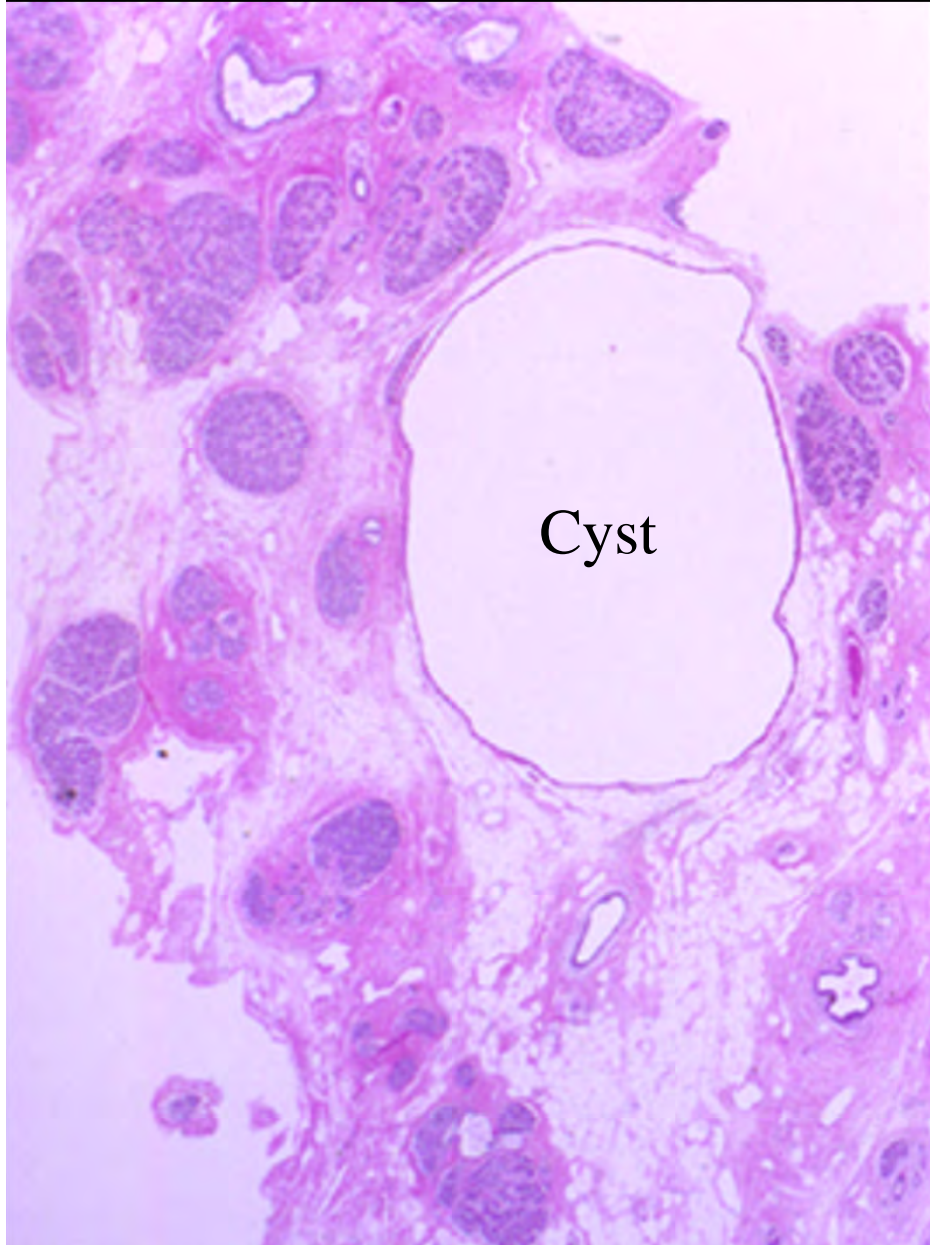
Apocrine Metaplasia

3/3 part of FCC

- **Replacement** of ducts or lobules with apocrine-type epithelium
 - Apocrine epithelium **normal in axillary and groin** sweat glands
 - **No clinical significance**
 - Often seen **in cysts**

apocrine metaplasia: very eosinophilic (pink)

Cyst with Apocrine Metaplasia



think "younger women"

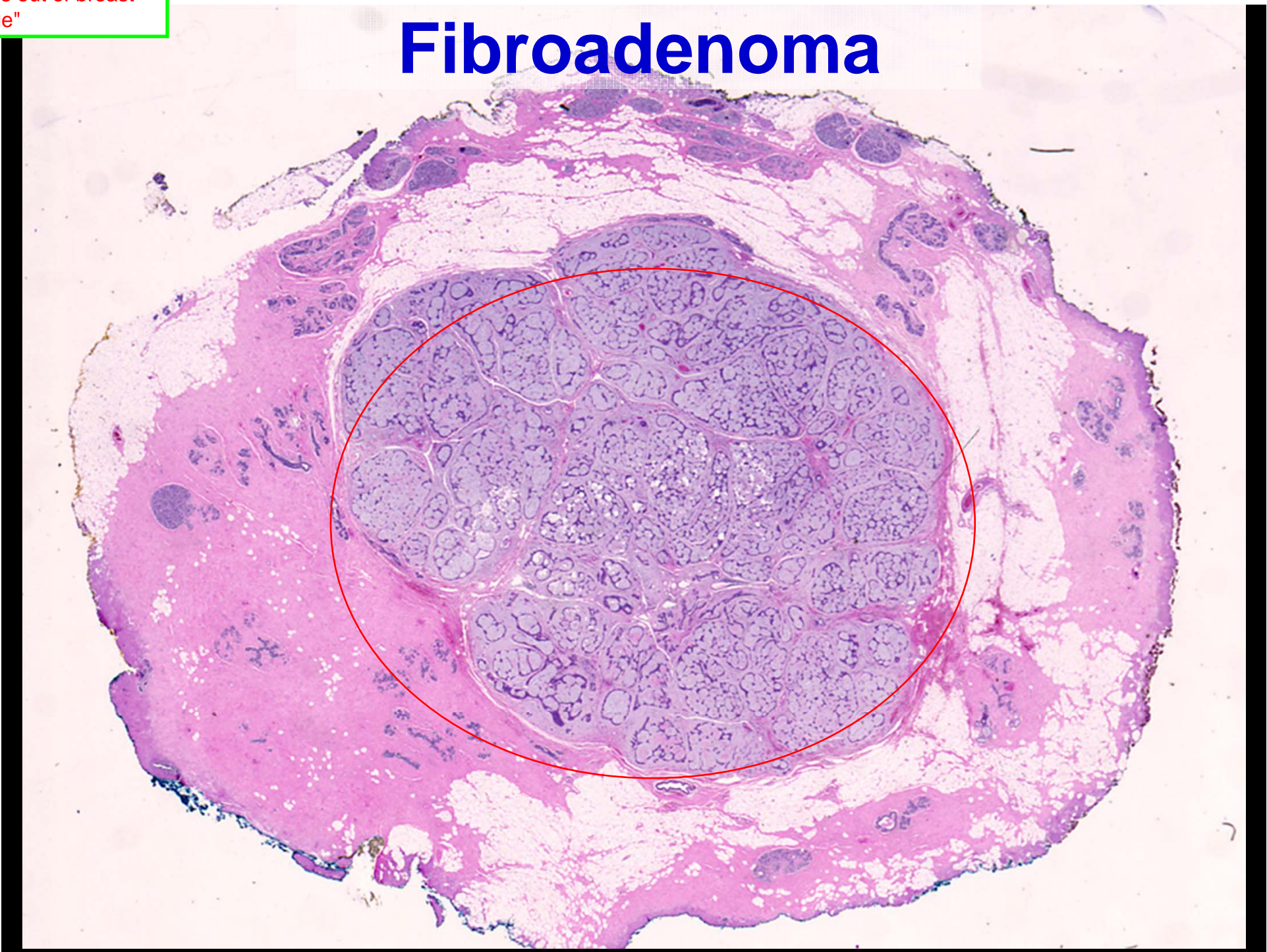
Fibroadenoma

- **Most common benign** neoplasm of the breast
- Most common in **teens** and **twenties**; second peak around **menopause**
- Proliferation of ducts AND stroma -- **"biphasic neoplasm"** together..leads to "biphasic" designation
- **Hard, round, well circumscribed** very characteristic characteristics nodule; can mimic cancer mobile, doesn't grow into other structures to get fixed
- Often **diagnosed clinically**, not biopsied left in breasts "if everybody is comfortable"



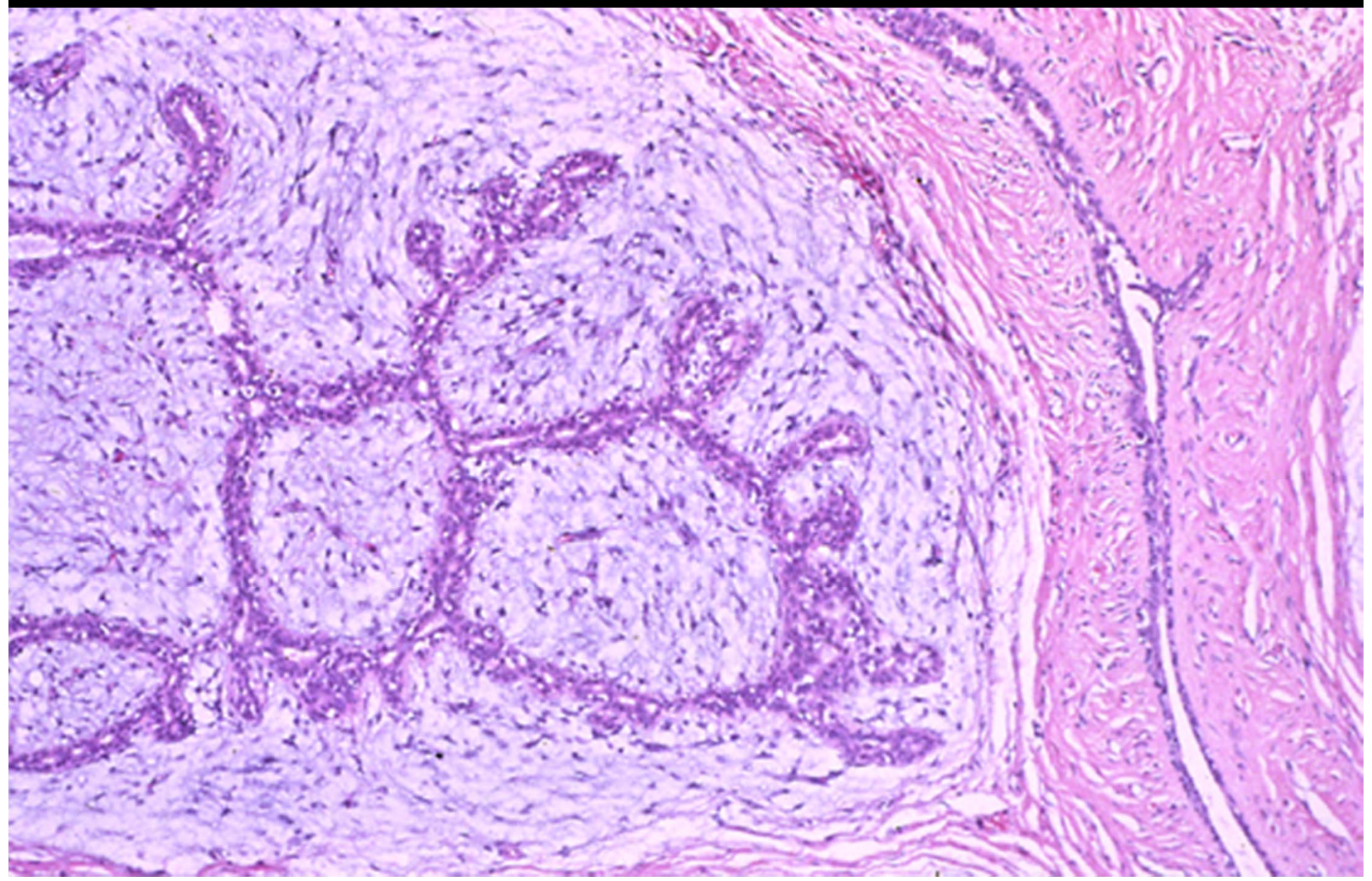
sharply circumscribed
"pops out of breast
tissue"

Fibroadenoma



proliferating DUCTS and STROMA
it is pushing things out of the way,
NOT invading
(these are classic features for a
"benign" neoplasm)

Fibroadenoma



Proliferative Breast Disease

A group of benign proliferative processes, distinct from non-proliferative change because they are markers for a slightly increased risk (1.5-2x) for breast cancer in the **future** not concurrently

these are findings that lead to increased RISK

- Moderate to florid epithelial hyperplasia
- Sclerosing adenosis
- Radial scar/complex sclerosing lesions
- Papilloma

Proliferative Breast Disease

Epithelial Hyperplasia

- Proliferation of epithelial cells within ducts and acini
- Classified as **ductal** (**usual type**) or **lobular**

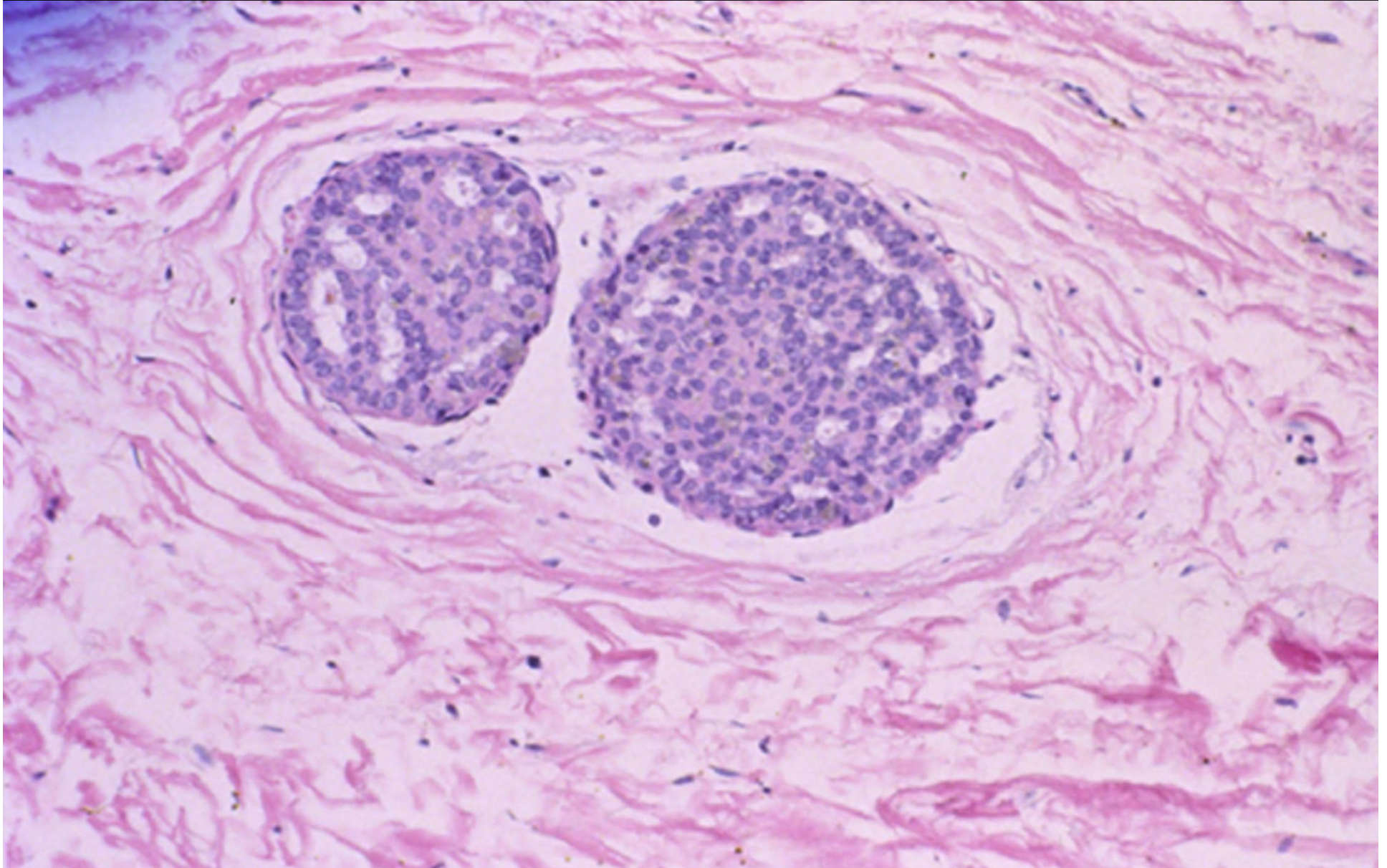
Proliferative Breast Disease

Epithelial Hyperplasia

- Always an **incidental** finding
- Does not make lump or microcalcifications
- Graded from mild to severe (florid)
- Important mostly as **risk factor**
 - Patients with moderate/florid hyperplasia have 1.5-2.0 relative risk for developing breast cancer over 20 year f/u.

increase in ductal epithelial cells

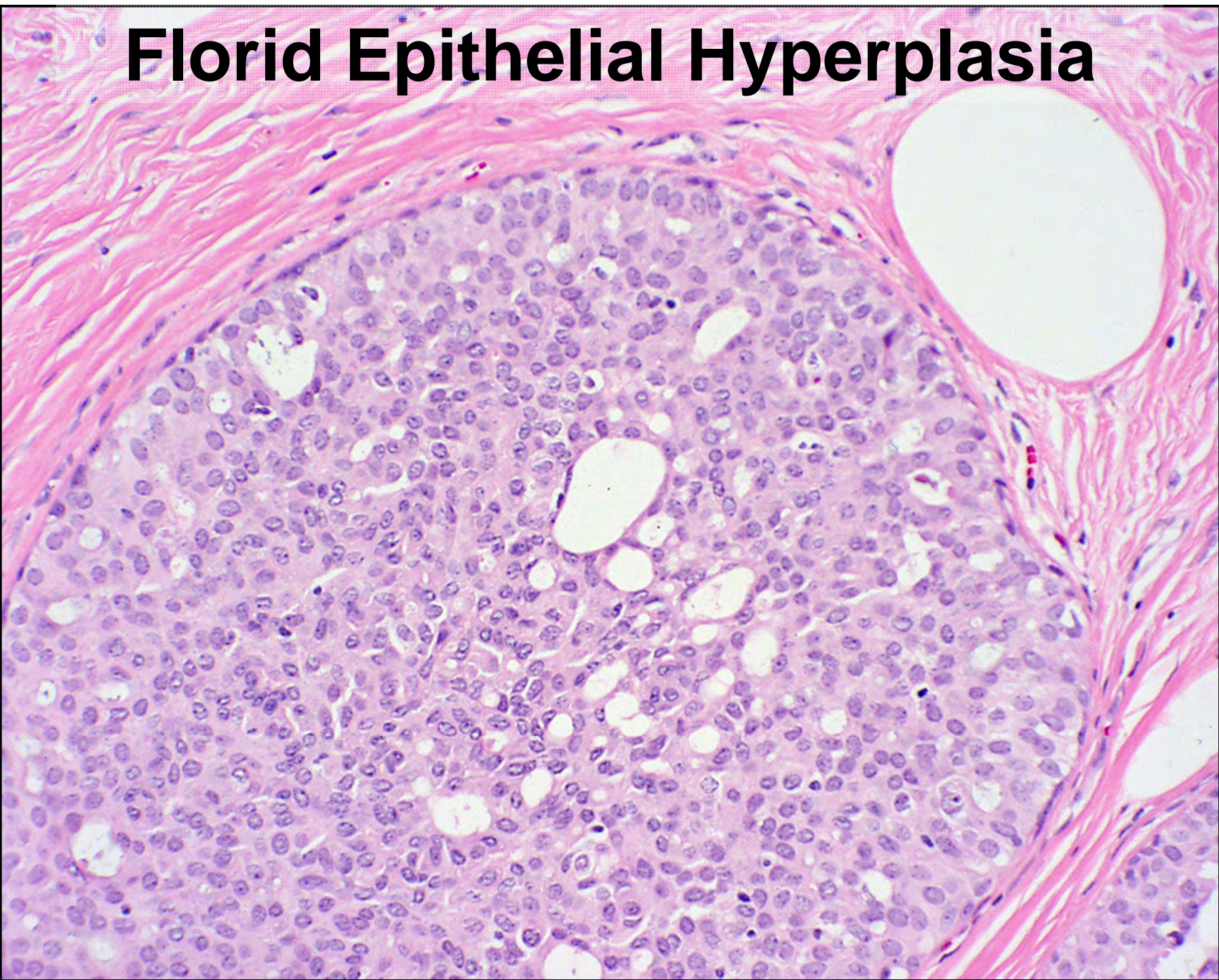
Mild Epithelial Hyperplasia



severe hyperplasia

remember, still "benign" only serves as a risk factor

Florid Epithelial Hyperplasia



SA: more ducts and fibrous tissue by definition; fairly common, can mimic cancer

Proliferative Breast Disease

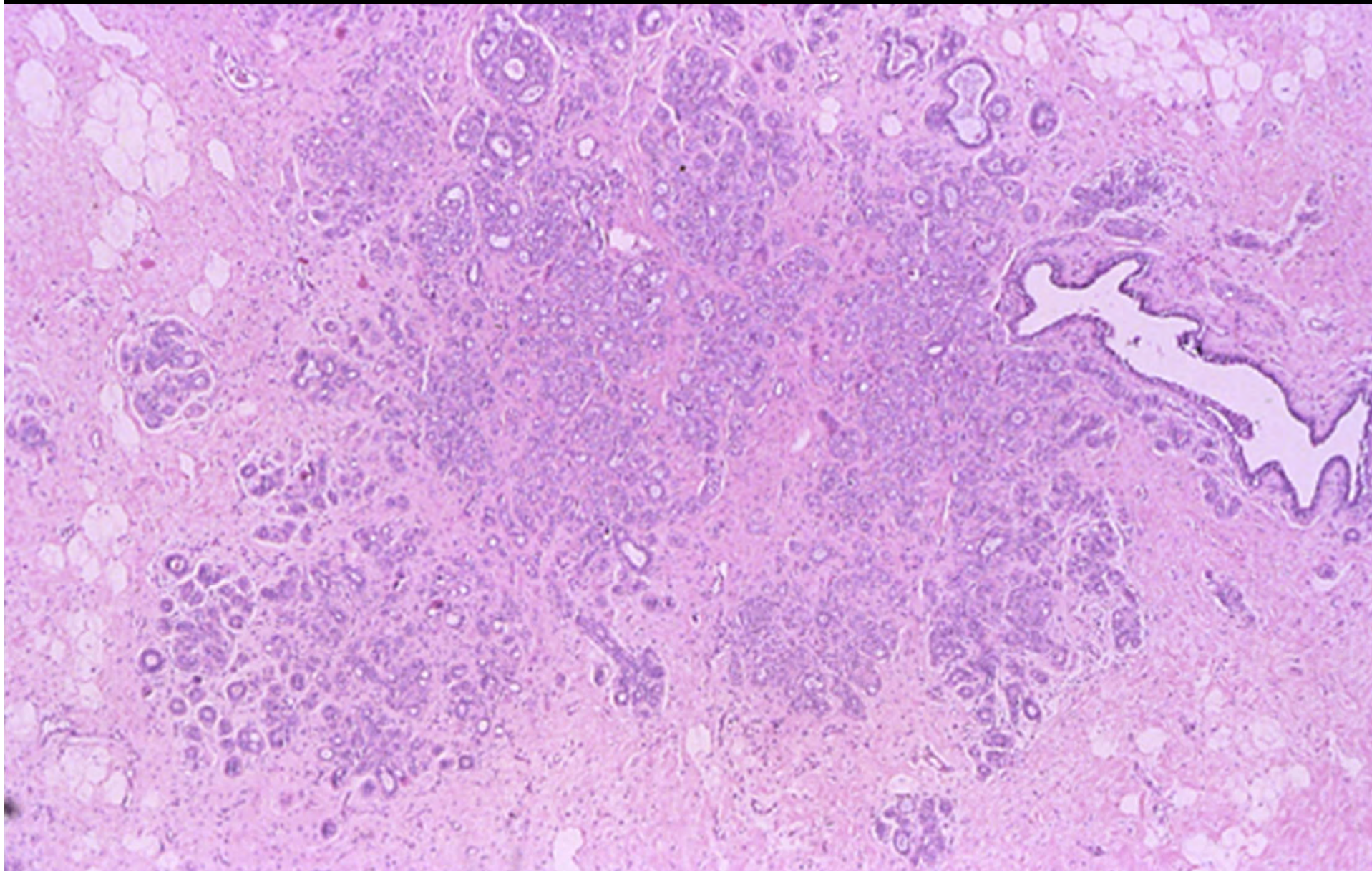
Sclerosing Adenosis

- **Adenosis** = Proliferation of small acini and terminal ducts
- **Sclerosing** Adenosis: Most common type
 - Adenosis with associated stromal fibrosis
 - Found in 12% of biopsies that's quite COMMON
 - Can **mimic cancer**, mass and microcalcifications

big lobule, expanded terminal duct
pink stuff is vast sclerosis
(fibrosis)

again, increased risk of breast cancer

Sclerosing Adenosis



Proliferative Breast Disease

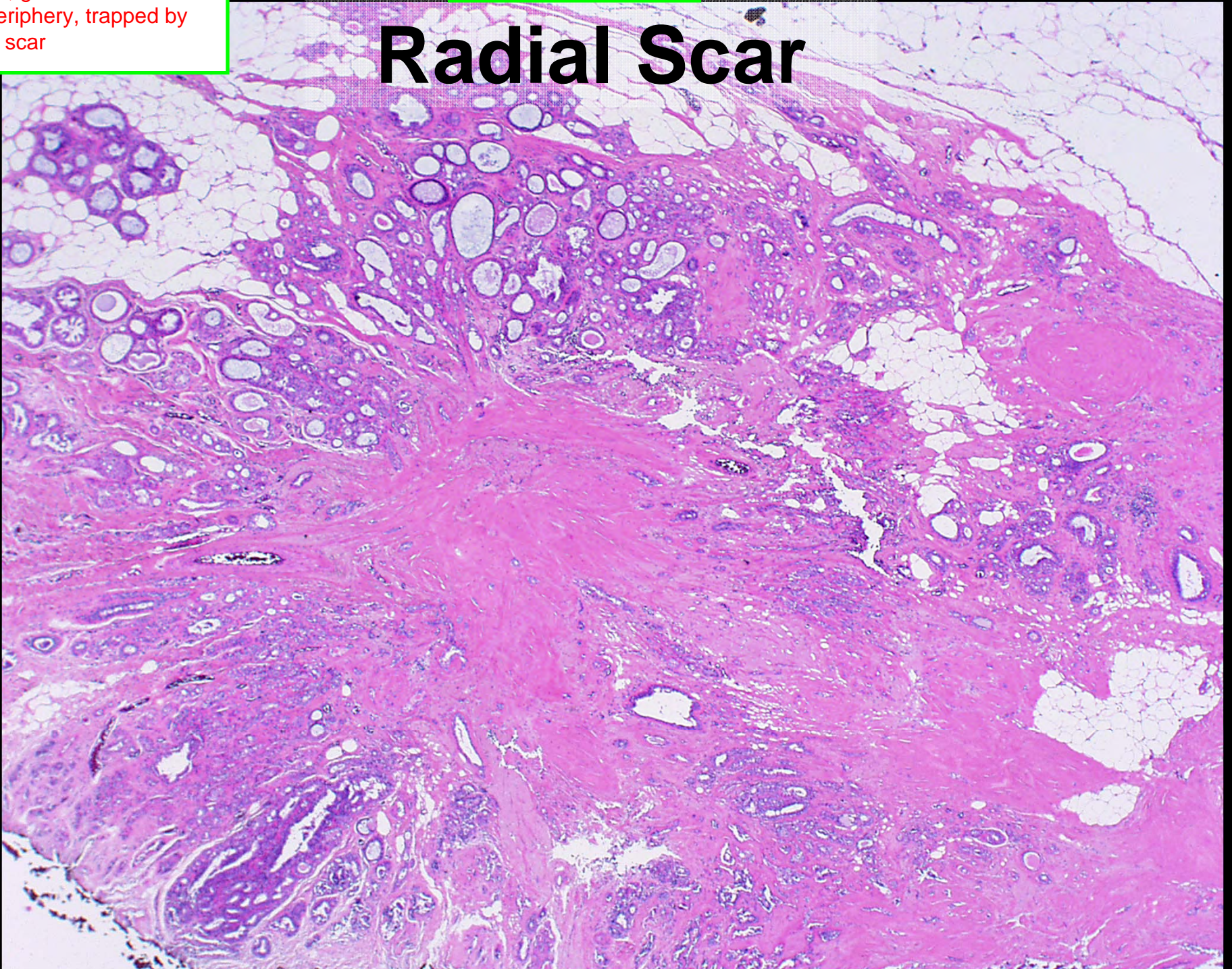
Radial Scar

- **Misnomer,** not related to trauma
- Stellate proliferation of ducts and acini around a central scar-like area of fibrous and elastic tissue.
- Often mimics cancer mammographically (spiculated mass with microcalcifications)

>scar-like, has "arms"
>epithelial, glandular stuff
around periphery, trapped by
the radial scar

not a scar in literal sense

Radial Scar



Intraductal Papilloma

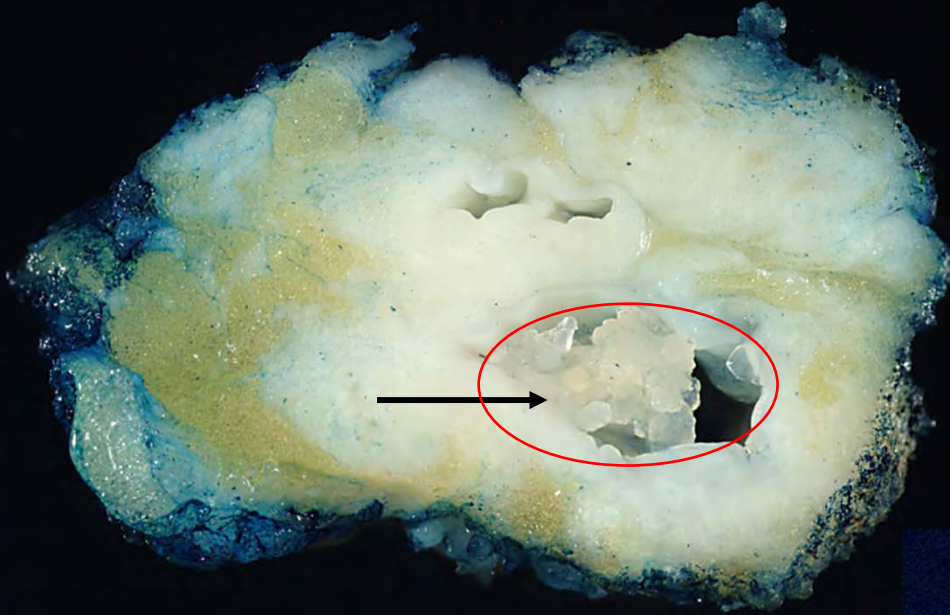
"cauliflower"

- Proliferation of papillary fronds within dilated duct
- Large ducts beneath nipple
- **Most common cause of bloody nipple discharge**

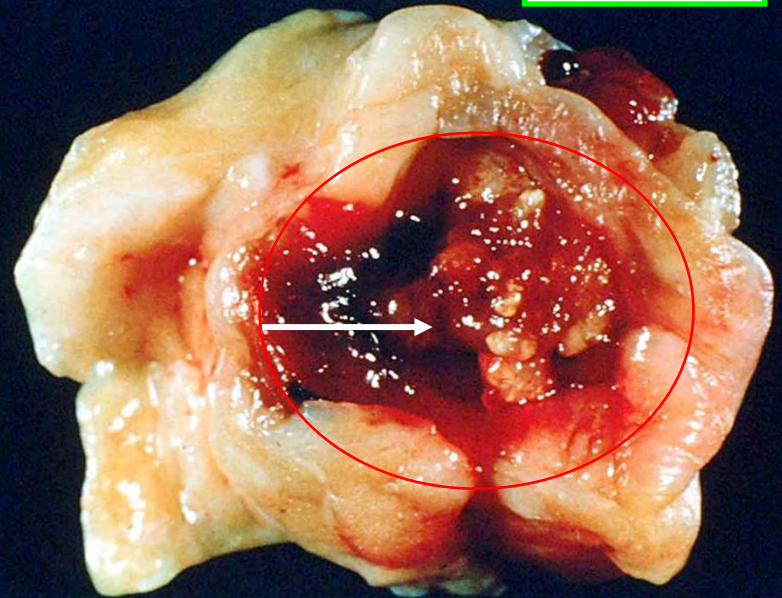
typically resected because bloody nipple discharge an often signify something terrible wrong

typically grows in large ducts

Intraductal Papillomas



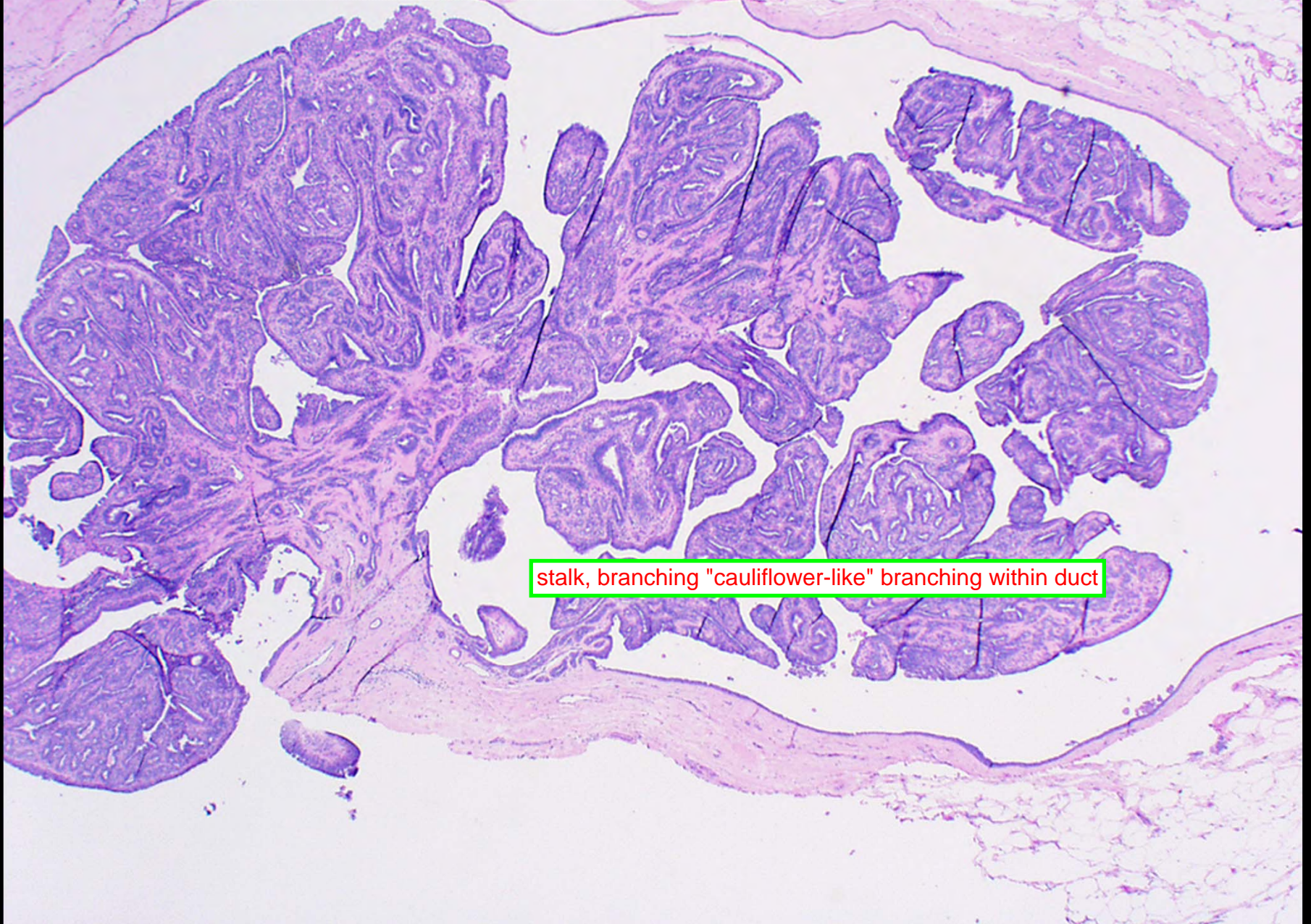bloody, necrotic



totally benign, but causes bloody nipple discharge

Intraductal Papilloma

stalk, branching "cauliflower-like" branching within duct



Proliferative Breast Disease With **Atypia**

A group of benign proliferative processes, distinct from fibrocystic change because they are markers of **high risk** (4-5x) for breast cancer in the future

- **Atypical** Ductal Hyperplasia
- **Atypical** Lobular Hyperplasia

ADH: probably a precursor for ISC;
detected for its microcalcifications

intermittent stage between hyperplasia and full on in-situ carcinoma

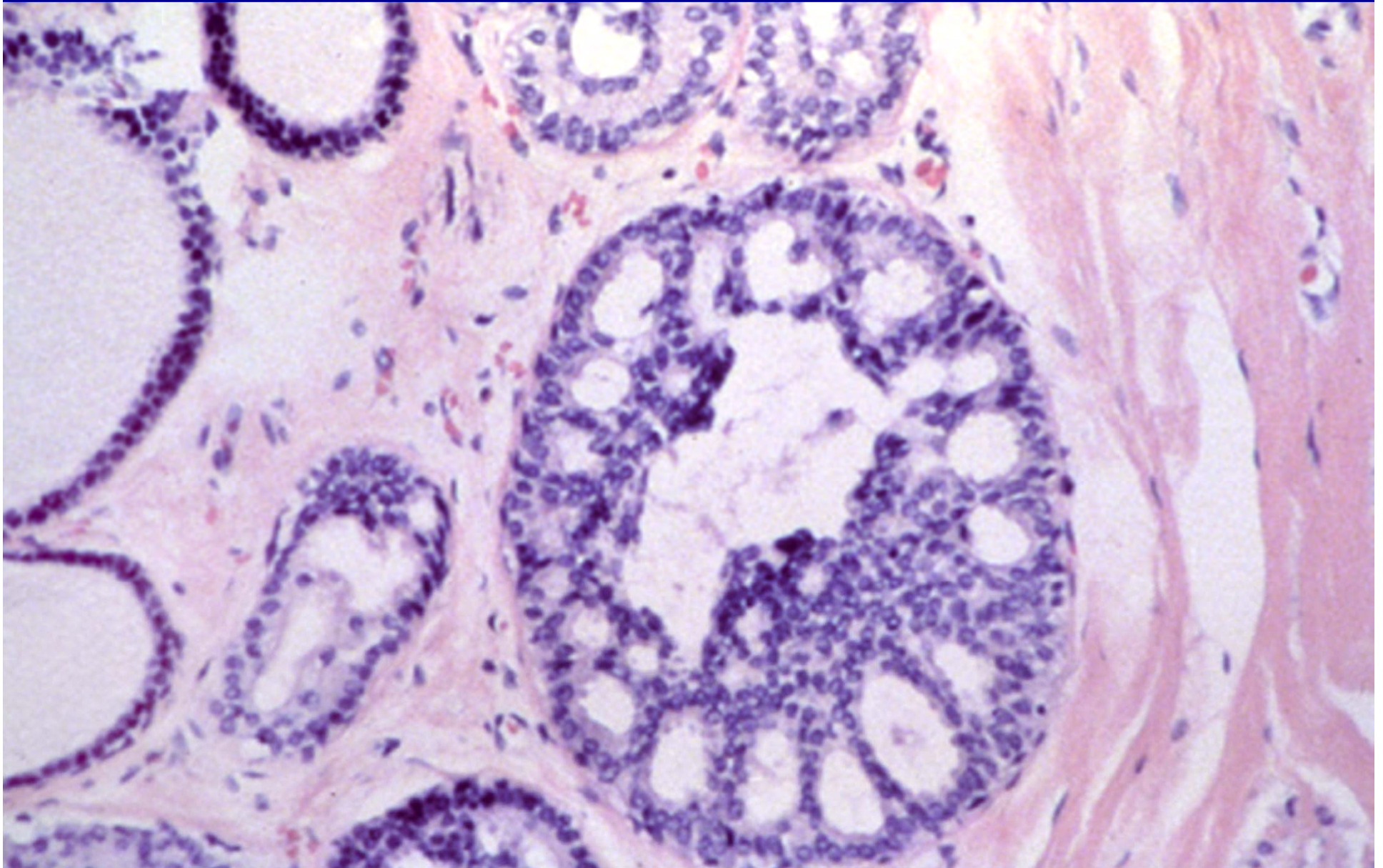
Proliferative Breast Disease With Atypia Atypical **Ductal** Hyperplasia

- Has **some but not all features** of in-situ carcinoma
 - **Probably precursor** to in-situ carcinoma, like dysplasia in cervix
- Usually detected because of **Ca++** calcifications
- Approximately **5%** of biopsies
- Moderate **increase in risk** for cancer

x4-5

atypical because the punched out lumen is pattern for in situ carcinoma

Atypical Hyperplasia



that's all for benign--they increase RISK



Malignant Neoplasms of the Breast

Breast Cancer

- Subject of intense scientific investigation
- Major advances in breast-conserving therapy and reconstruction
- Major focus of cancer screening (mammography, self-exam)
- Only recent years have seen a modest impact on mortality rate

Malignant Neoplasms

- **Basic epidemiology**
- **In-situ carcinoma**
 - Ductal carcinoma in-situ
 - Lobular carcinoma in-situ
- **Invasive carcinoma**
 - Ductal
 - Special ductal subtypes
 - Lobular
- **Prognostic and treatment factors**
 - ER/PR, Her2/neu, genomic
- **Special presentations of breast cancer**

Breast Cancer

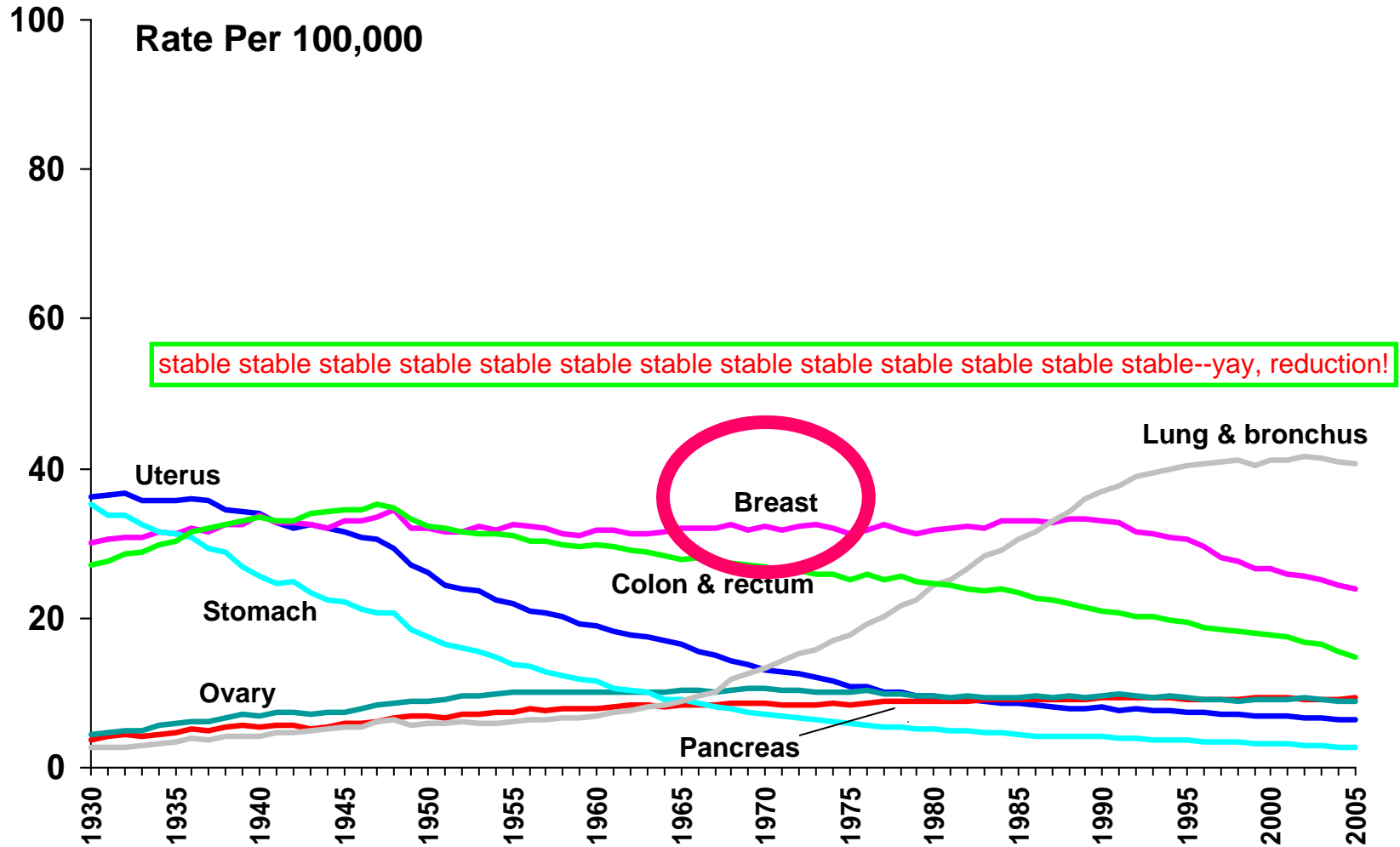
Fast Facts

- 192,370 est. new cases 2009
– 40,170 deaths
- **One in 8 women** will develop breast cancer
- **One in 35 women** will die from breast cancer
- **31%** of all cancers in women

excluding skin cancers, which are always excluded it seems

Death Rate--mostly stable but now have downward trend

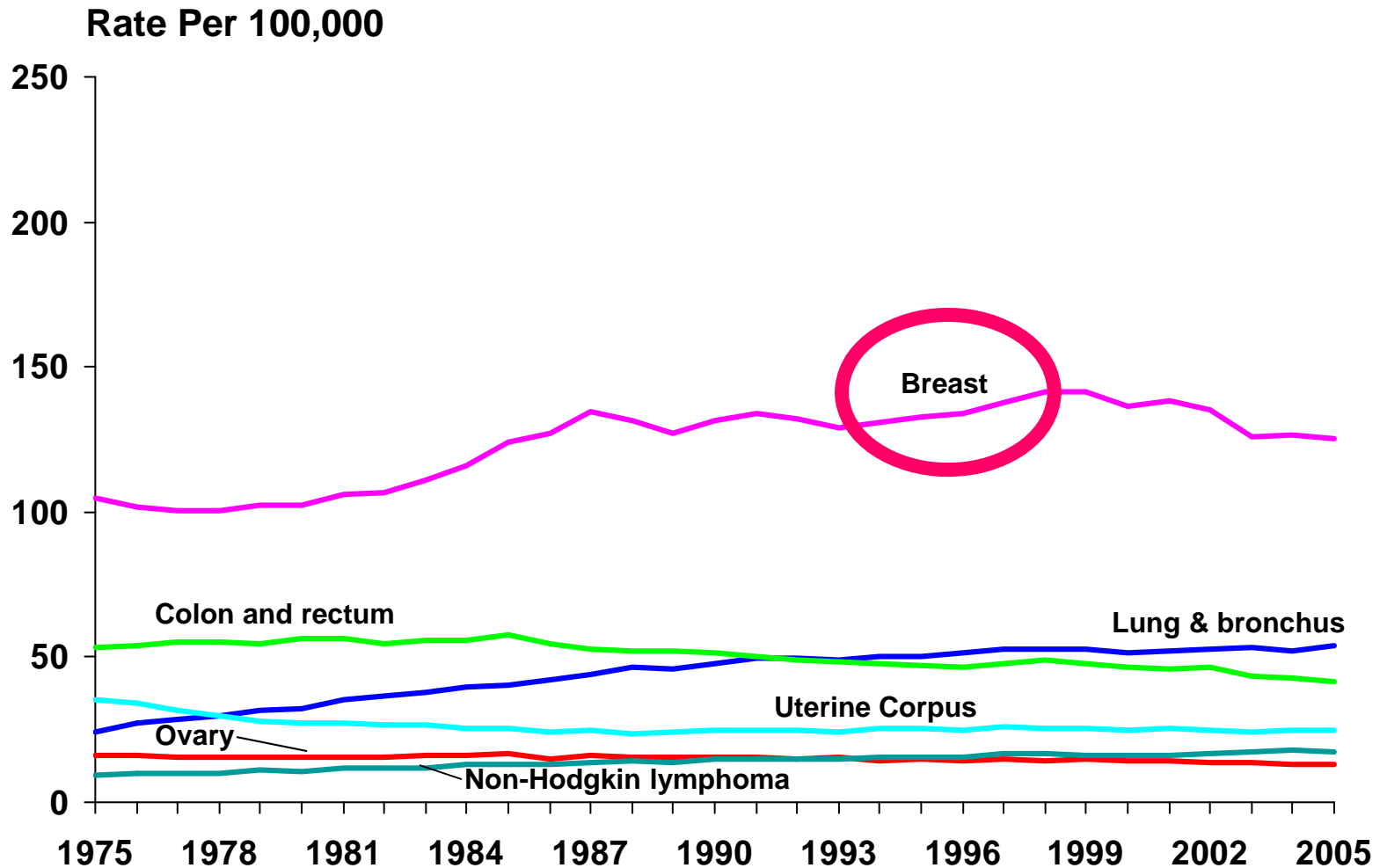
Cancer Death Rates* Among Women, US, 1930-2005



*Age-adjusted to the 2000 US standard population.
Source: US Mortality Data 1960-2005, US Mortality Volumes 1930-1959, National Center for Health Statistics, Centers for Disease Control and Prevention, 2008.

by far the most common
cancer in women

Cancer Incidence Rates* Among Women, US, 1975-2005



*Age-adjusted to the 2000 US standard population and adjusted for delays in reporting.
Source: Surveillance, Epidemiology, and End Results Program, Delay-adjusted Incidence database:
SEER Incidence Delay-adjusted Rates, 9 Registries, 1975-2005, National Cancer Institute, 2008.

Risk Factors for Breast Cancer

- Age
- Family history
- Specific gene mutations: **BRCA1, BRCA2, p53**
 - very high risks (50-80%) for affected families, but uncommon causes of breast cancer overall
 - also have increased risk of other cancers (ovary, other)

most breast cancer is SPORADIC--the above mutations are relatively rare and contained intrafamilially

breastfeeding DECREASES the risk for BC

Risk Factors...

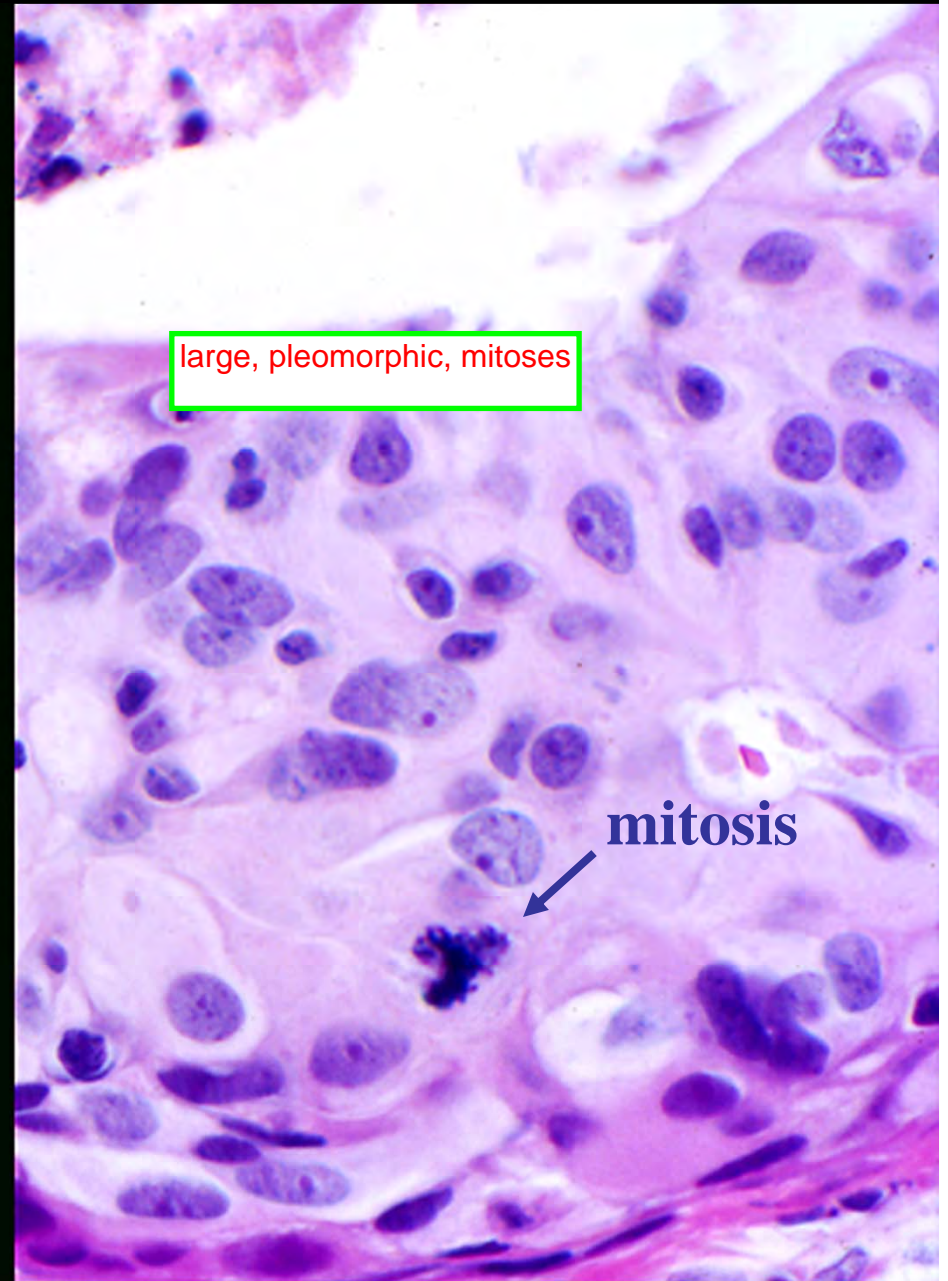
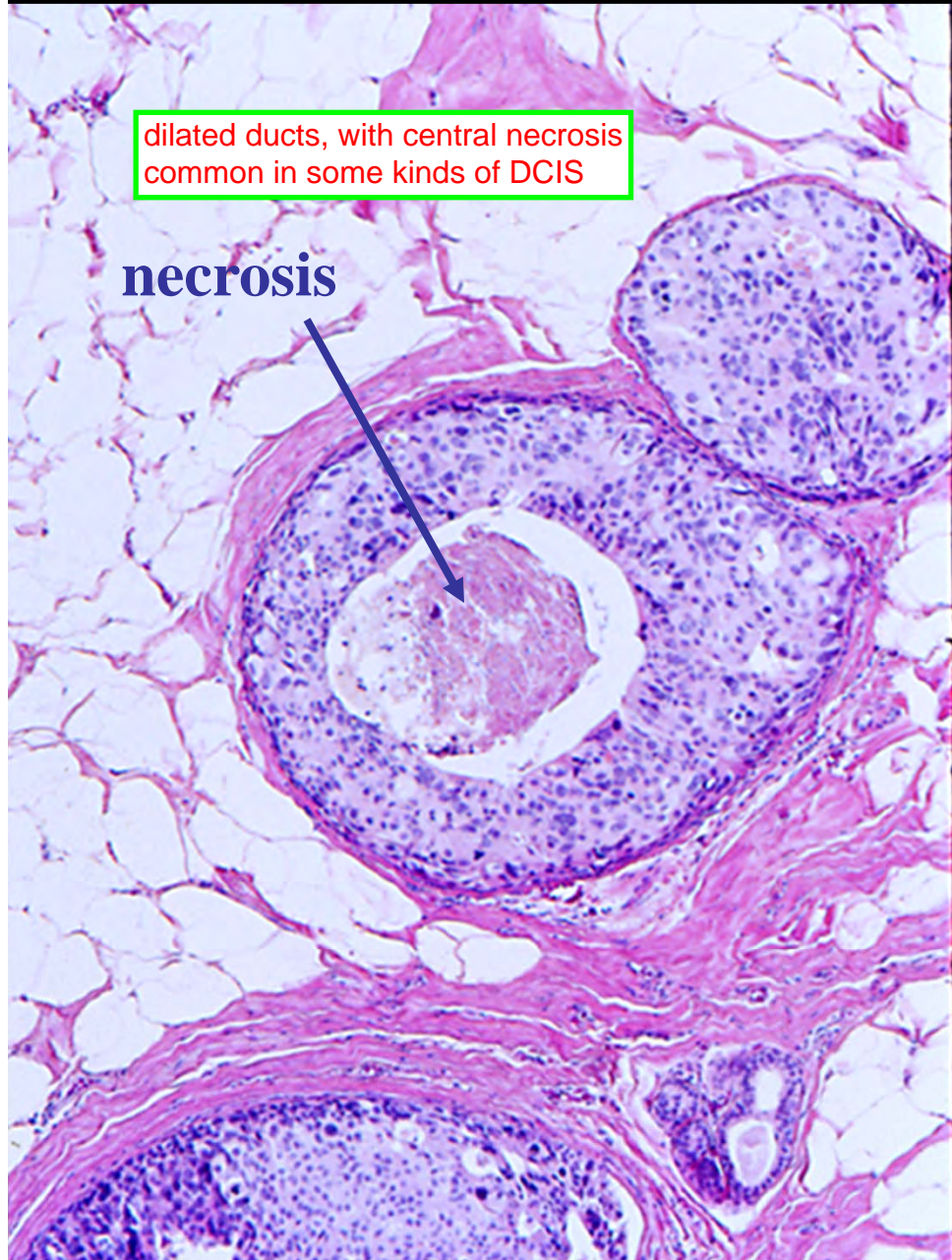
- Prolonged **estrogen** exposure
 - early menarche, late menopause, birth control pills
- **Late or no** pregnancy lactation is protective
- High risk **findings** in previous breast biopsy
- **Radiation,** esp. as teenager or young adult
- Breast feeding is **protective**

Pre-invasive Malignancy

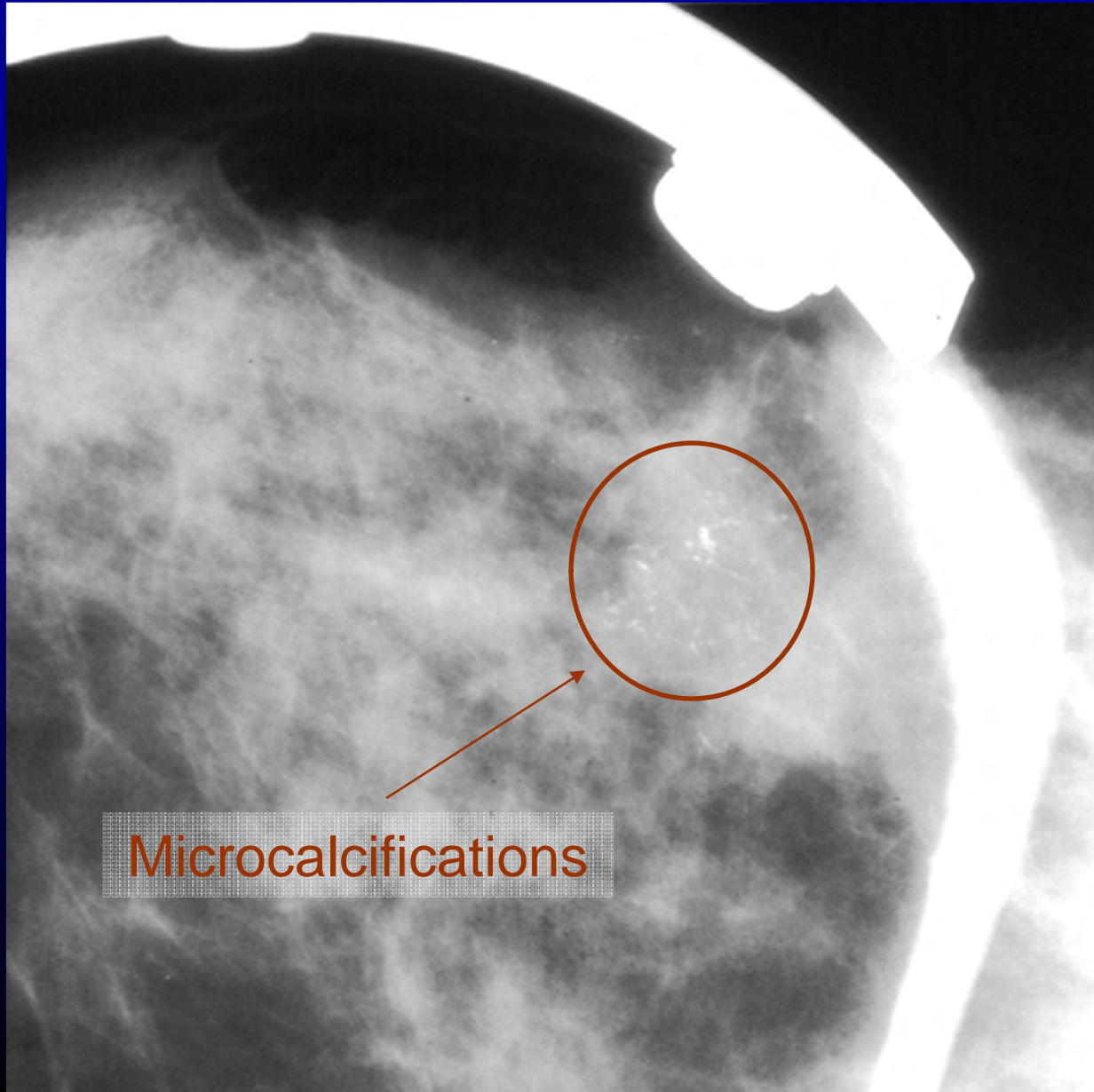
- Ductal Carcinoma in Situ (**DCIS**)
 - Synonym: Intraductal Carcinoma
 - **Direct precursor** to invasive carcinoma.
 - Malignant cells proliferating within duct, **no invasion** through basement membrane (no metastatic potential)
 - Spread within **duct system; can involve very large area** duct system acts like HIGHWAY system
 - Microcalcifications on mammogram

typically spot these by MCs on mammogram, not by mass lesion

Ductal Carcinoma In Situ



Mammogram, DCIS



Microcalcifications

Pre-invasive Malignancy...

- **Lobular** Carcinoma in Situ (LCIS)
 - Proliferation of **small** bland cells within lobule small and uniform, grows in lobule as opposed to duct
 - Probably not direct precursor
 - patients have high risk of developing invasive cancer (10x), but risk is **bilateral**, not at site of LCIS
 - **Not really carcinoma in situ --just marker of risk**
 - **Treated differently** than DCIS

do not treat lobular carcinoma in situ as direct precursor lesion as you would DCIS (which you would remove)--it can occur in other breast! Treated very differently clinically

Invasive Neoplasms

Invasive Adenocarcinoma Classification

- Invasive **Ductal** adenocarcinoma
 - No special type (**NST**, NOS)
 - **Special** subtypes -- better prognosis
 - Medullary
 - Mucinous unique clinical presentation or behavior
 - Tubular
- Invasive **Lobular** adenocarcinoma

Invasive Ductal Adenocarcinoma

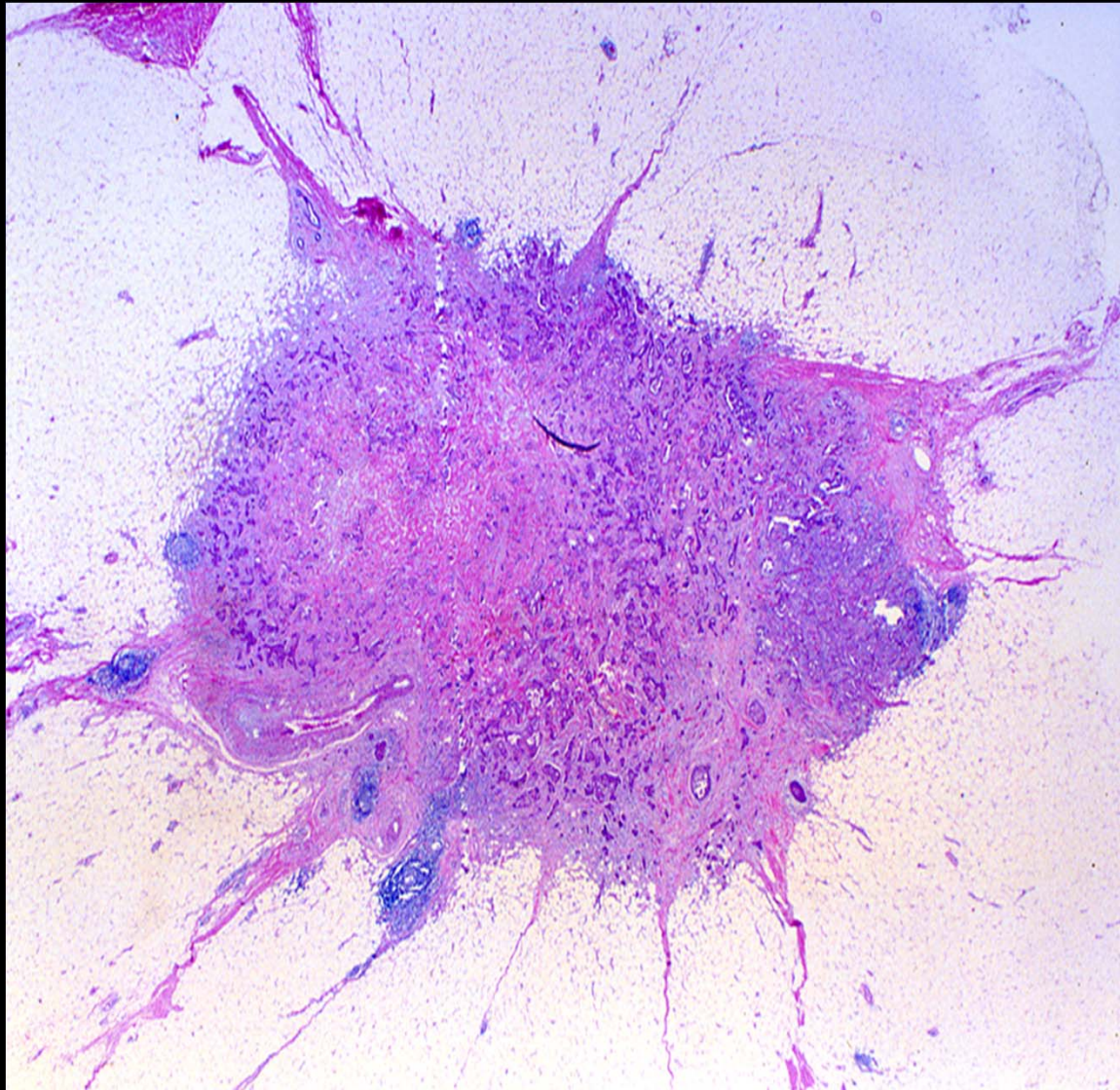
- **Most common**, 70% of breast cancers
- Incites prominent fibrous reaction (“**desmoplasia**”) -- accounts for clinical presentation
 - **Rock hard, “scirrhous” or chalk-like**, spiculated mass this is the typical pattern we think of for breast cancer
 - **Grows into** surrounding tissue--skin dimpling, nipple retraction
- **Poorest prognosis**

IDA-spiculated mass

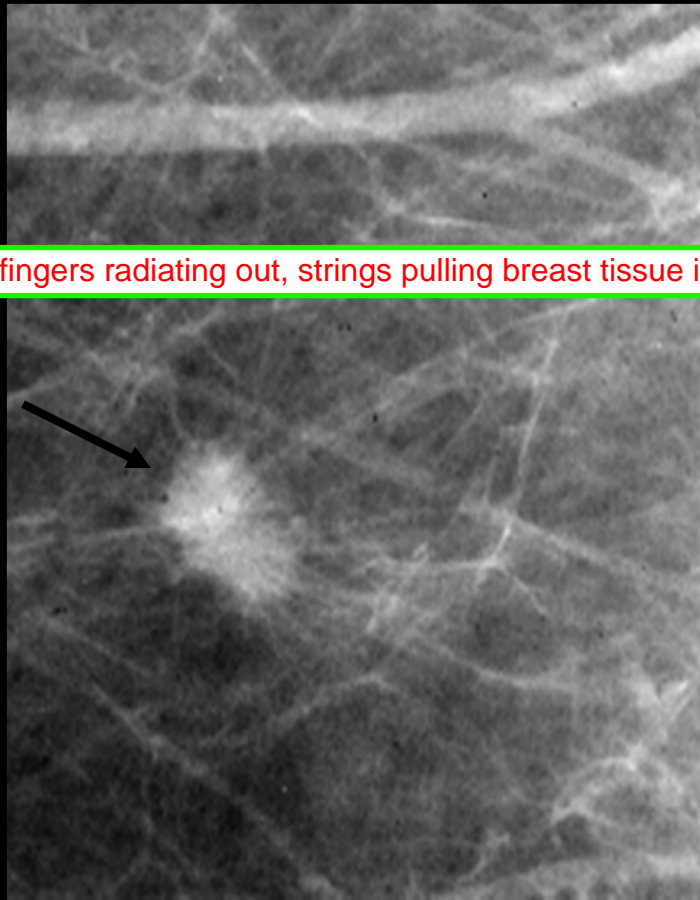
spreads out and pulls surrounding breast tissue into the lesion

Invasive Ductal Adenocarcinoma

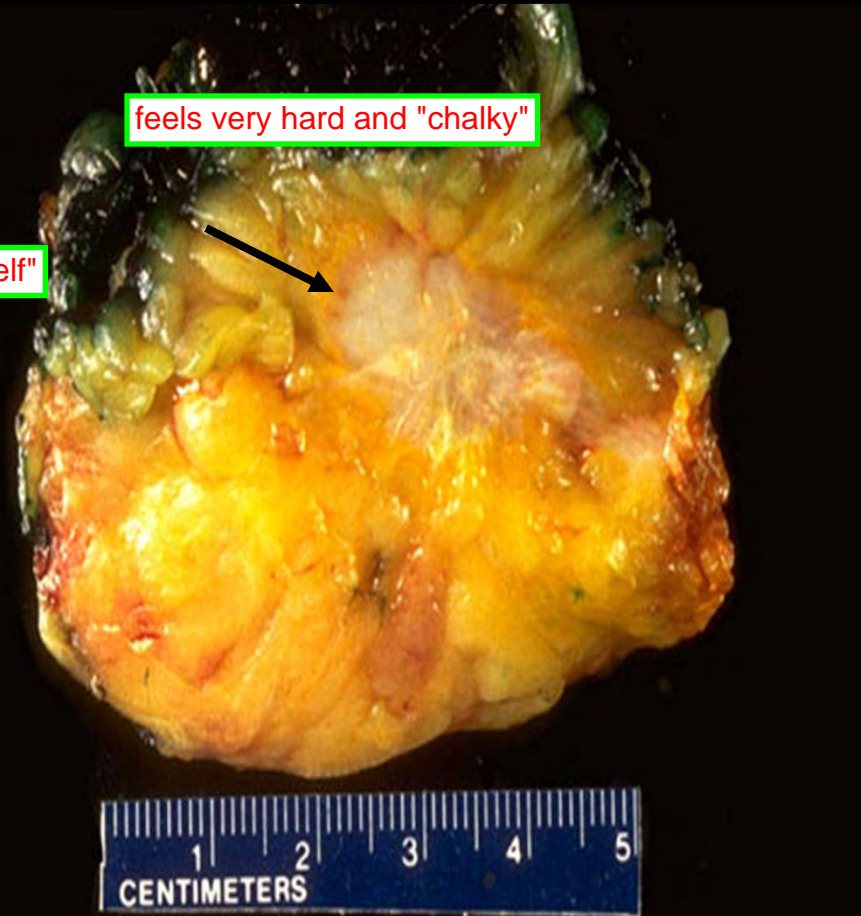
Spiculated Mass



Invasive ductal adenocarcinoma



"fingers radiating out, strings pulling breast tissue into itself"



feels very hard and "chalky"

Mammogram

Invasive Ductal Adenocarcinoma

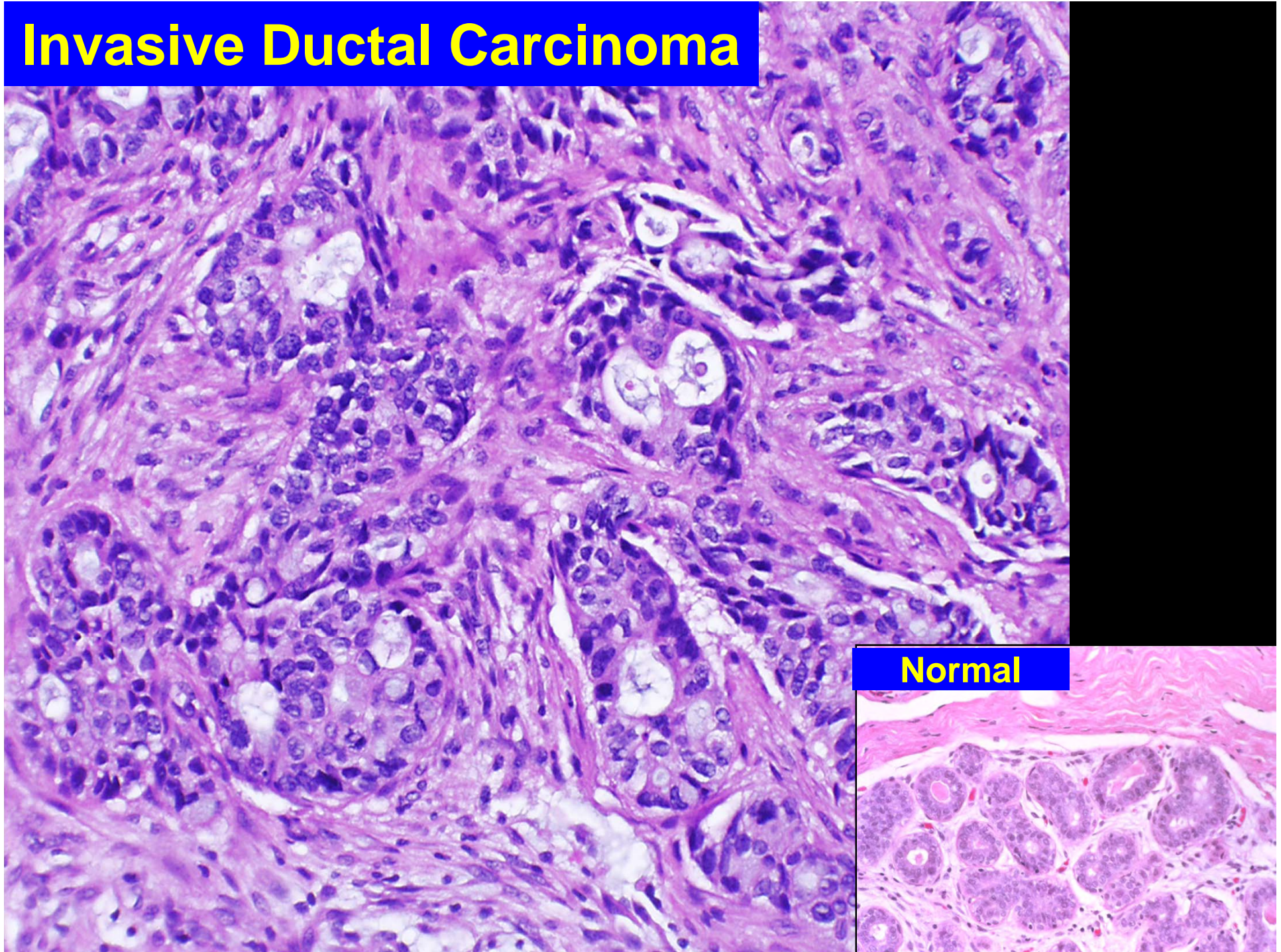
- **Irregular and complex** duct or gland-like structures
- **Malignant** epithelial cells
 - nuclear enlargement, pleomorphism
 - prominent nucleoli
 - frequent mitoses
 - no myoepithelial cell layer

also for prostate

irregular branching glands going thru surrounding stroma

"adeno"carcinoma

Invasive Ductal Carcinoma

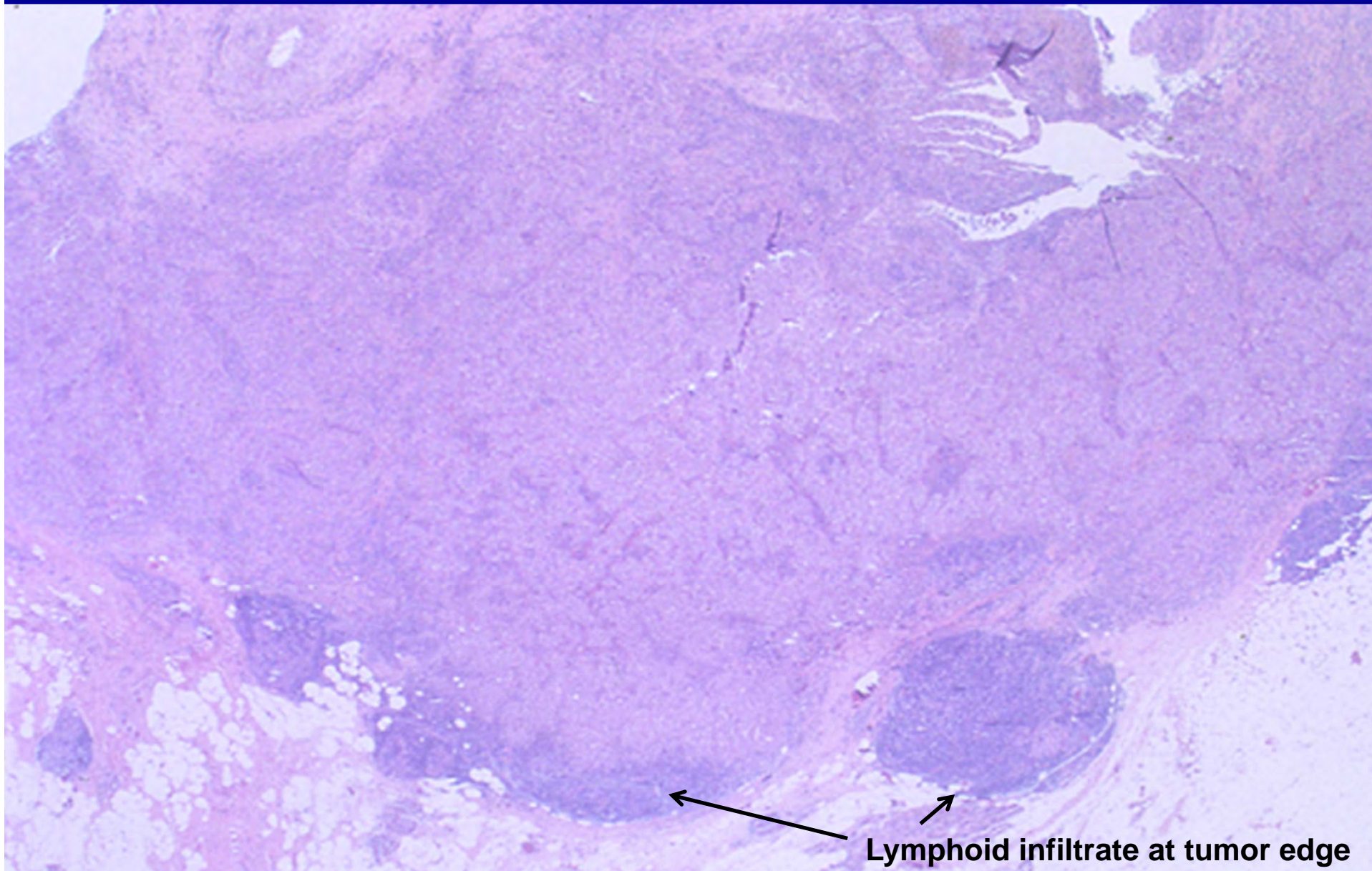


Special Types...

- **Medullary carcinoma** special 1/3
 - **Well circumscribed, soft**
 - Prominent **lymphoid** infiltrate
 - **Paradoxically,** despite relatively **good prognosis,** **most anaplastic tumor cells** of any type.
 - No ducts or glands
 - High grade nuclei
 - **Rare,** less than 1% of breast cancers

note that it is well-circumscribed

Medullary Carcinoma



Mucinous: well-circumscribed,
soft--can fool clinically--full of
mucin with tumor islands
floating within

Special Types...

- **Mucinous Carcinoma**

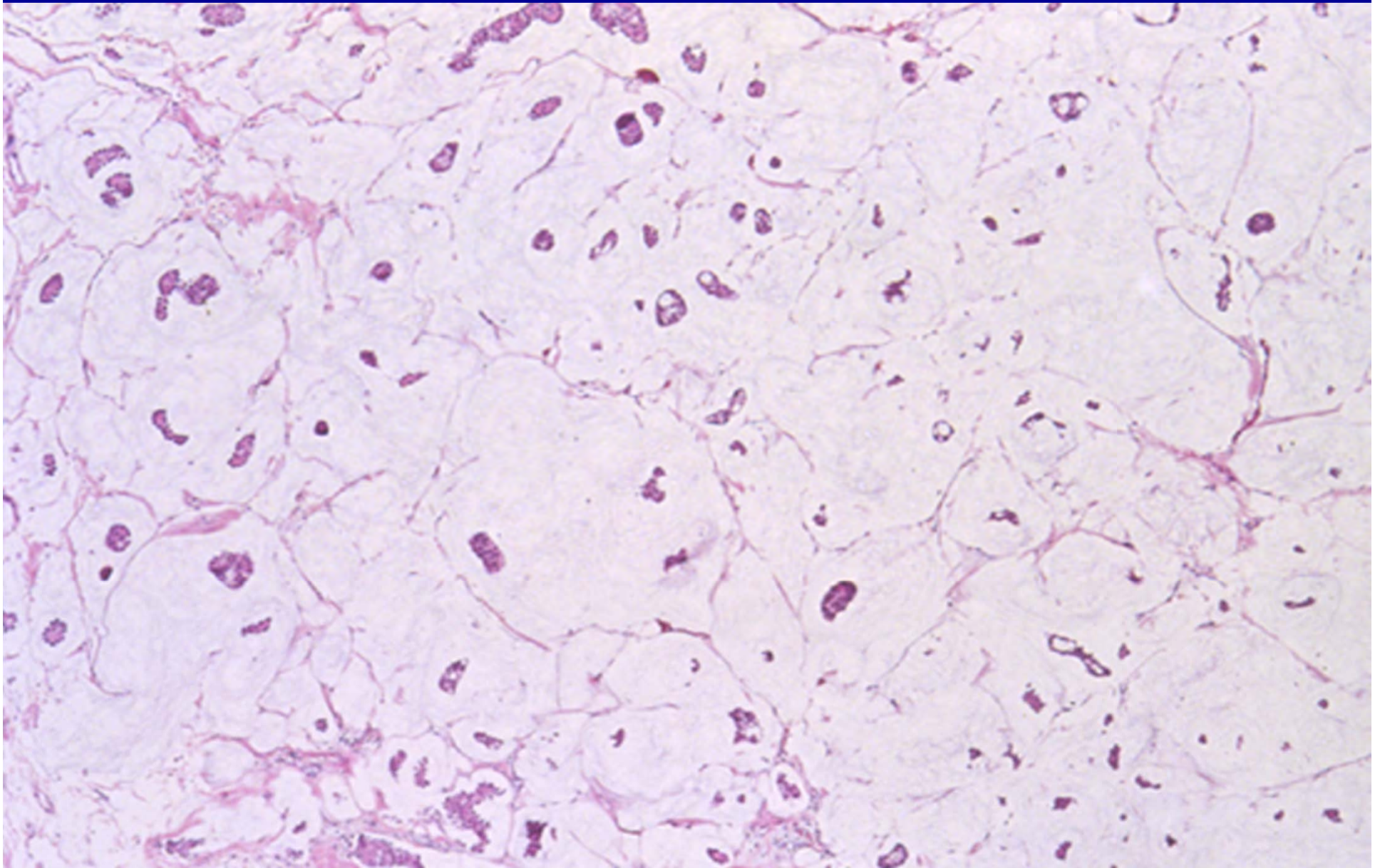
- Synonym: Colloid carcinoma
- **Well circumscribed, mucinous** consistency
- “**Islands** of tumor floating in a sea of mucin”
- Approximately 1-5% of breast cancers

decently common

islands of tumor (blue) in mucin (white)

nice soft, mushy, circumscribed lump on exam

Mucinous Carcinoma



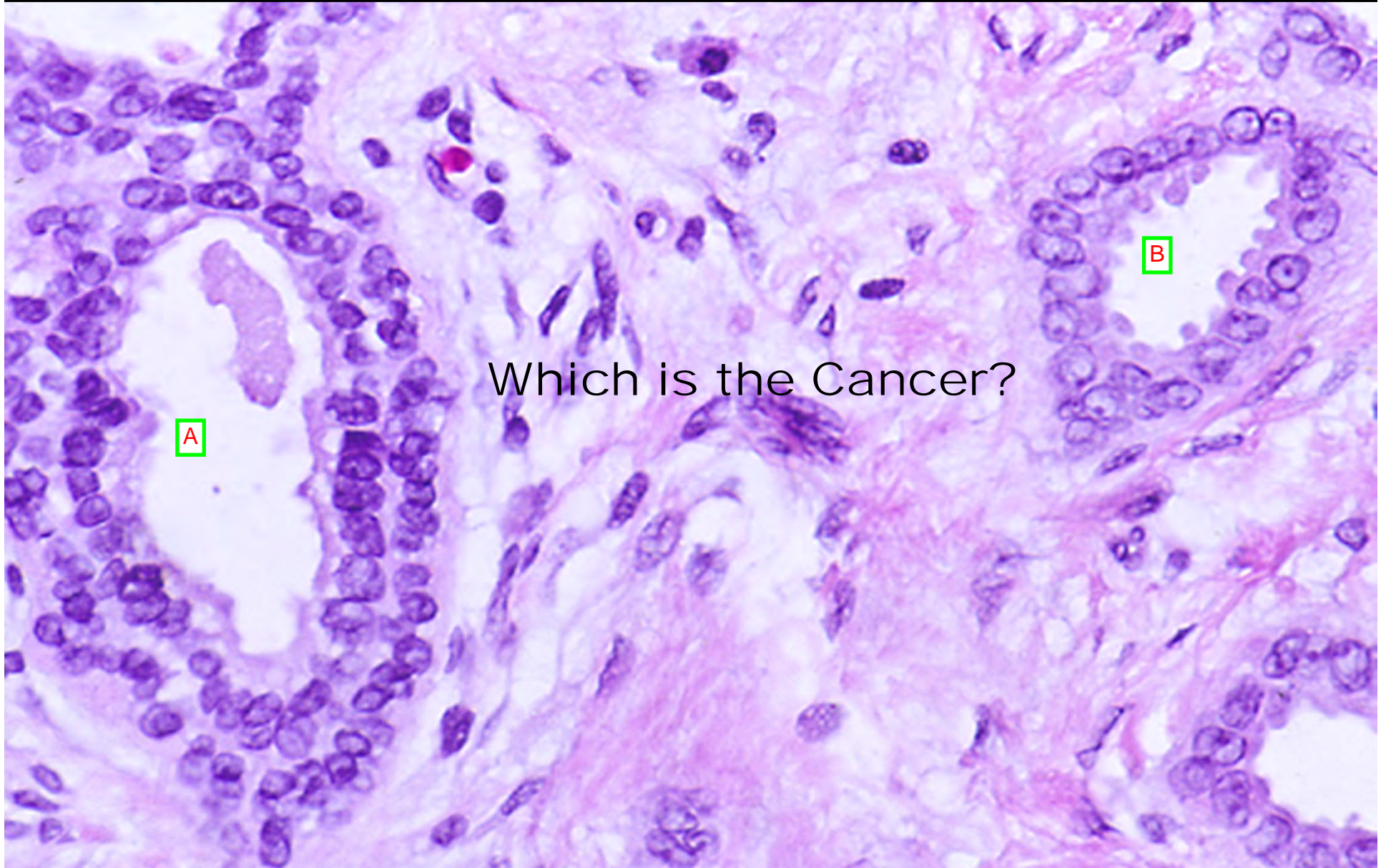
Special Types...

- **Tubular Carcinoma**

- **Extremely well differentiated** ductal carcinoma
- Composed entirely of **simple tubules** lined by **single layer** of cells
- **Can be confused** with benign lesions (radial scar)
 - No myoepithelial cell layer
- Extremely **good prognosis**; no deaths reported when <1cm
- 5% of breast cancers

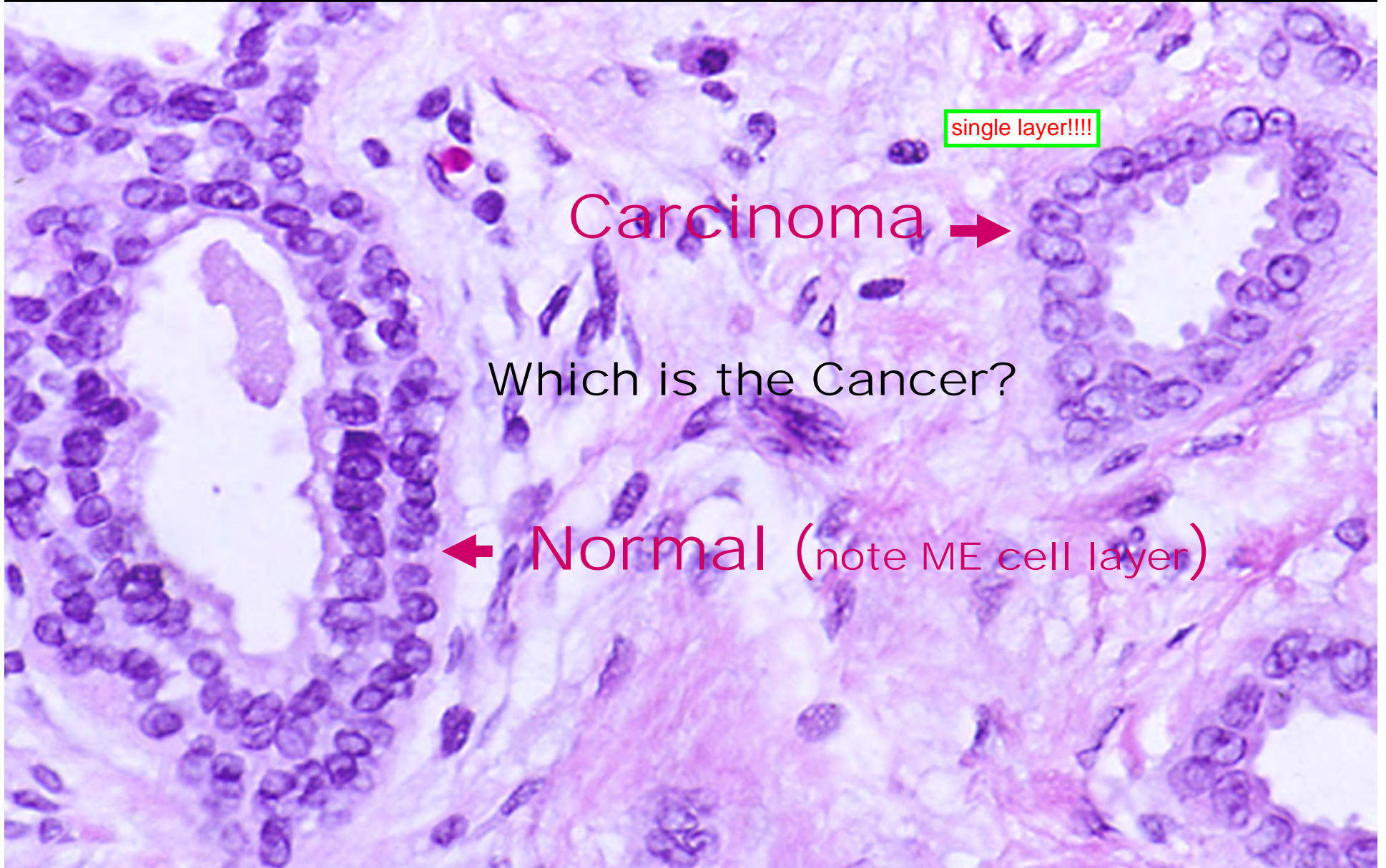
can be treated less aggressively; excision, and patients survive ~100%

Tubular Carcinoma



Which is the Cancer?

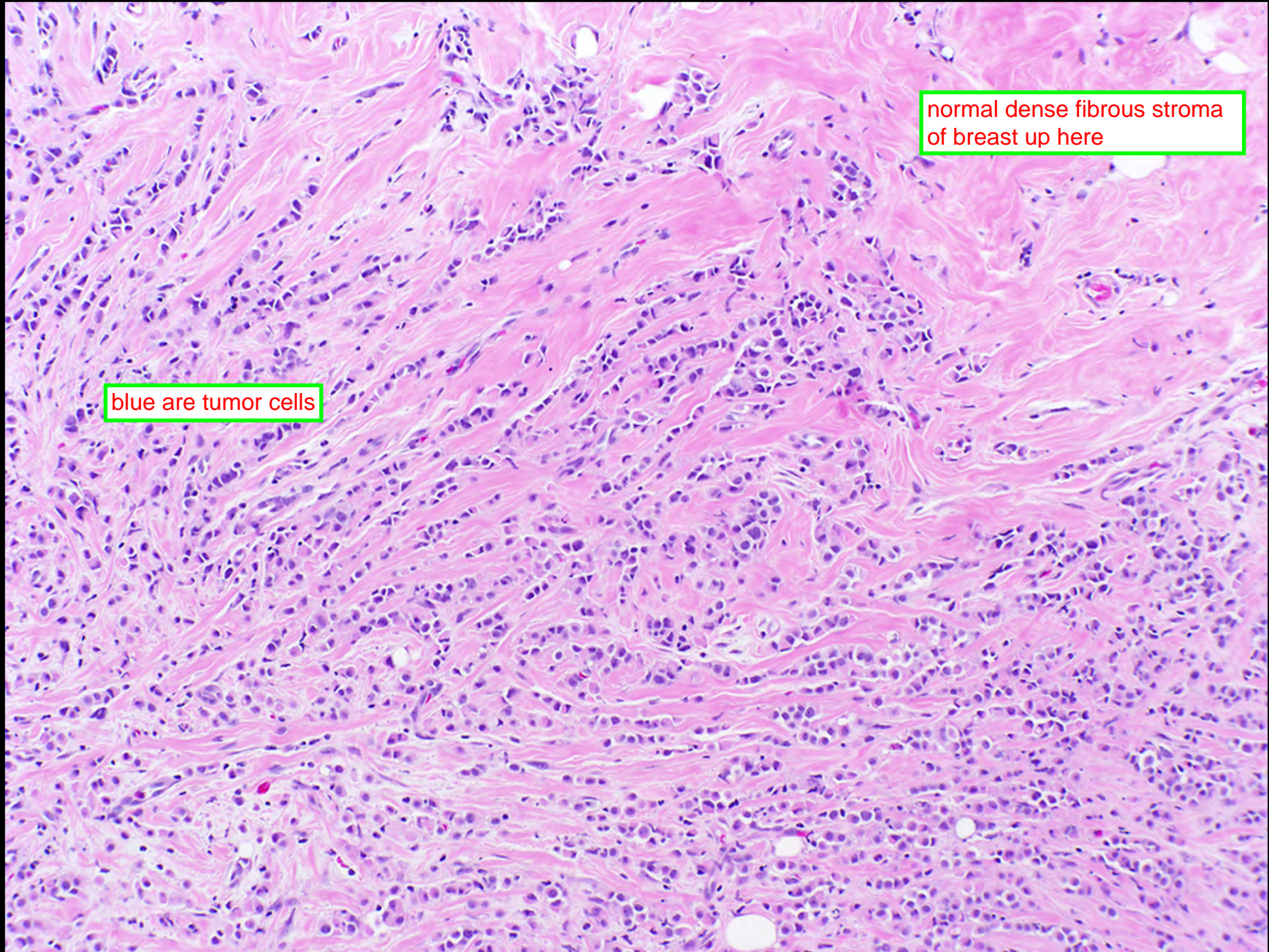
Tubular Carcinoma



Invasive Lobular Carcinoma

- **5-10%** of breast cancers
- Originates in **TDLU**, same cell type as ductal
 - **often mixed** with ductal carcinoma on a spectrum together
- **Does not incite fibrous response**; may be difficult to detect maybe no mass lesion
 - **Single file pattern of spread-** **“Indian file”**
- Prognosis similar to ductal carcinoma, NST

Invasive Lobular Carcinoma

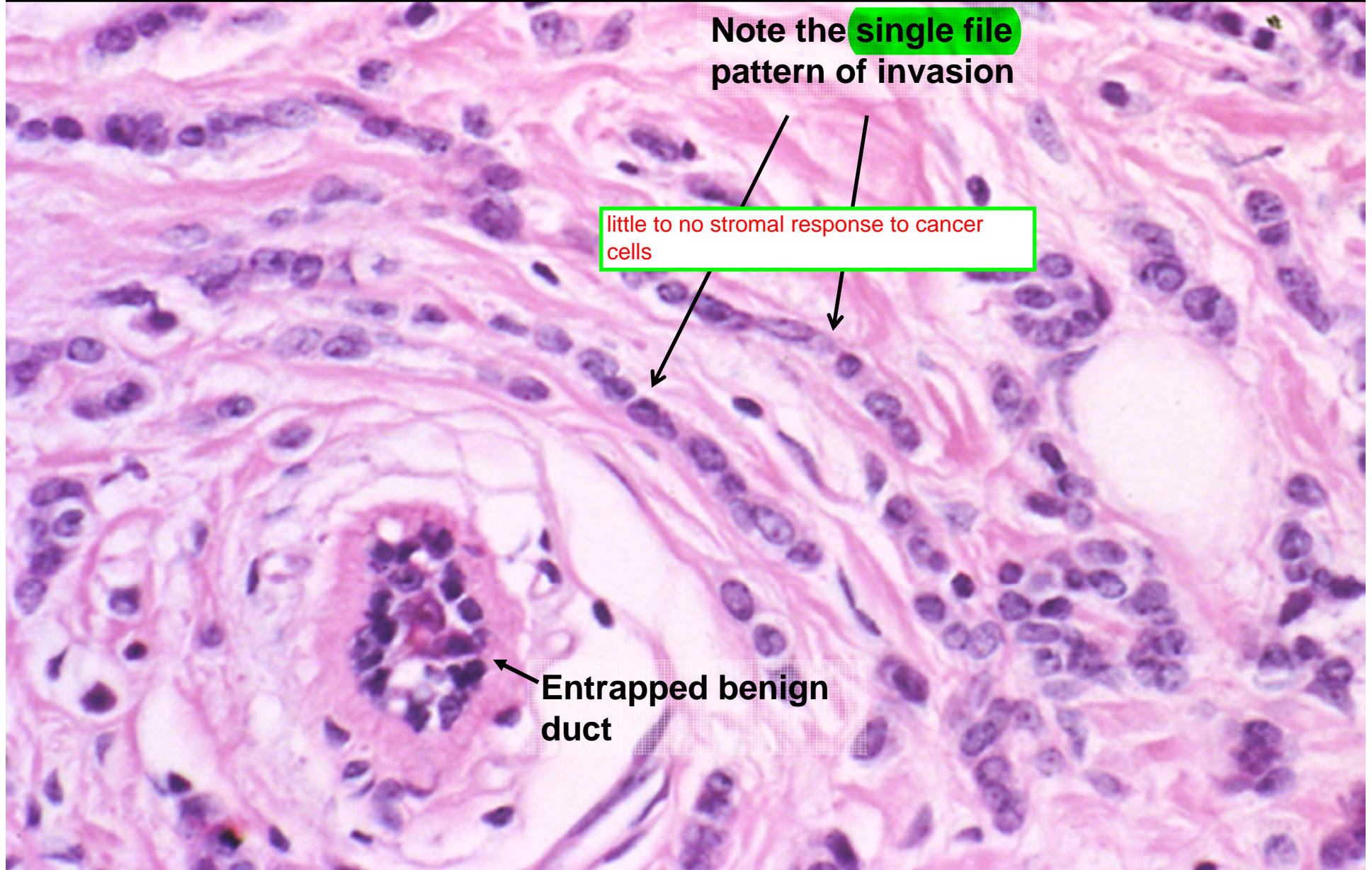


blue are tumor cells

normal dense fibrous stroma
of breast up here

single file invasion, no stromal response

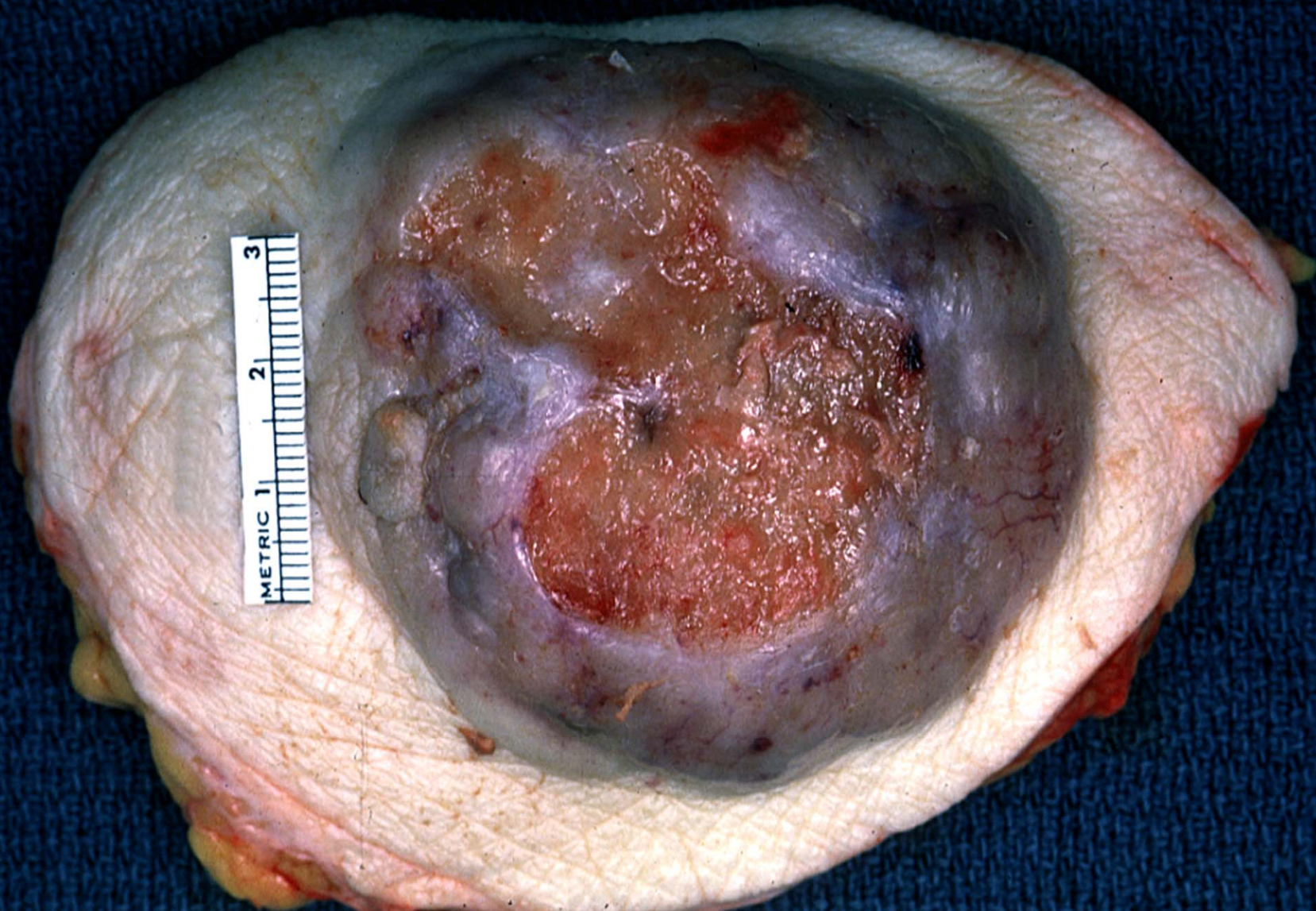Invasive Lobular Carcinoma



Behavior of Breast Carcinoma

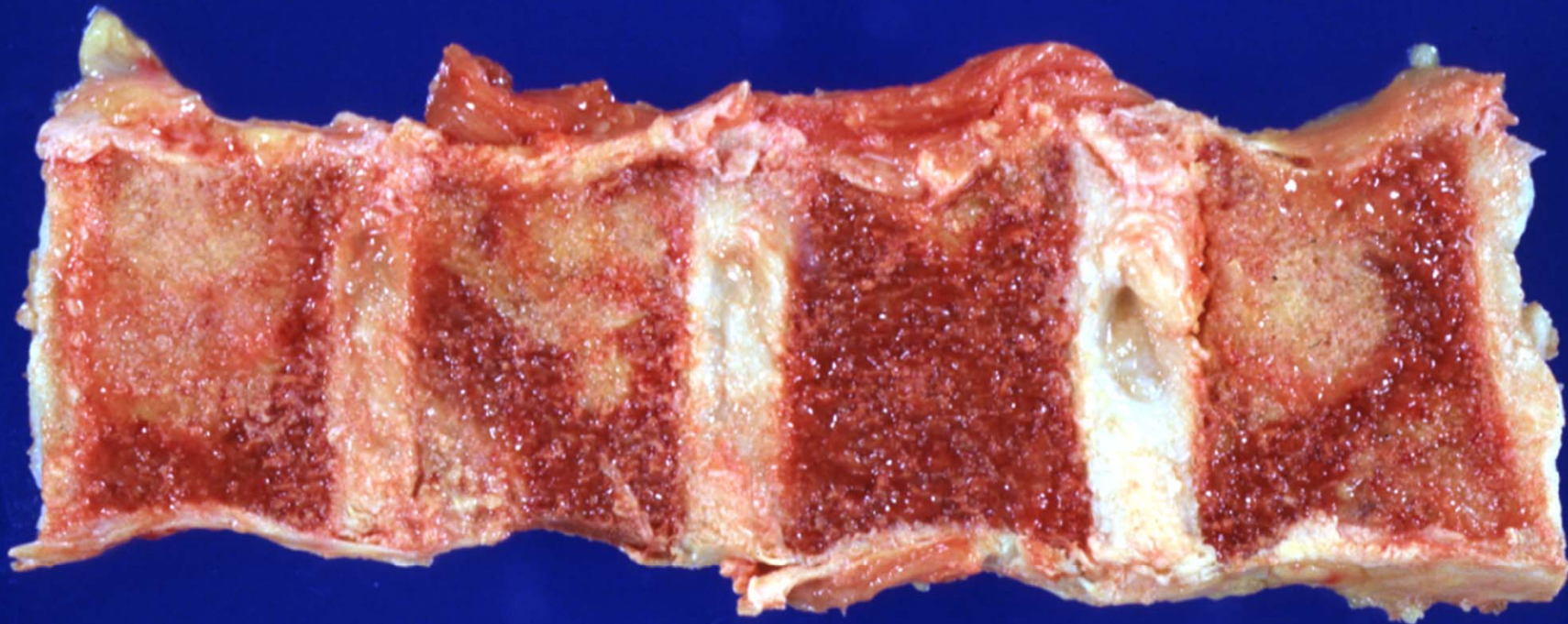
- **Local** recurrence into or out from body
 - Can **ulcerate through** skin, **invade** chest wall
- **Lymphatic/hematogenous** metastases
 - local metastases to **axillary nodes** (most common); internal mammary nodes, supraclavicular nodes less common
 - distant metastases to **lung, liver, bone, brain** common sites

Breast Cancer-Local recurrence



Breast cancer ulcerating through skin

Distant Metastases



Breast cancer metastases in vertebra

this bridge no longer exists!



Key Prognostic Factors

(Tumor, Node, Metastasis)

single most important!!! Remember for your own lives in the future.

- **Stage** of disease
 - Tumor size
 - **Axillary node status** -- single most important prognostic feature, predicts distant metastases
- Tumor **grade**: well differentiated vs. poorly differentiated
- **Margins** of resection: local recurrence likely if tumor in margins

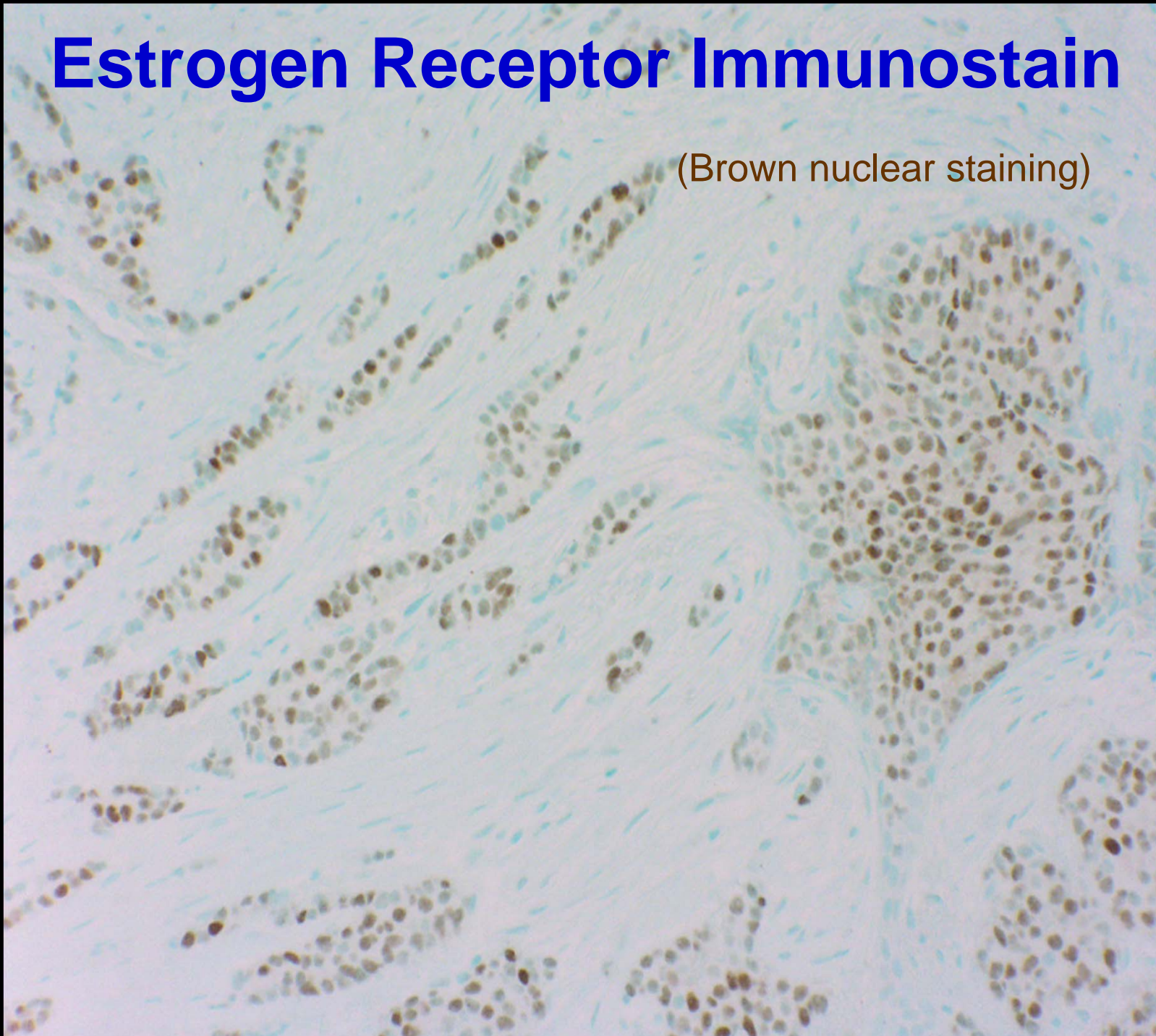
Estrogen/Progesterone Receptors

Important for both prognosis AND treatment

- ER/PR negative tumors have worse prognosis
- ER/PR positive tumors respond to anti-estrogen agents (e.g. tamoxifen, raloxifene, aromatase inhibitors)

Estrogen Receptor Immunostain

(Brown nuclear staining)



good treatment option

Her2/neu

- Aka c-erb-B2, **human epidermal growth factor receptor 2**
- Gene is amplified in **25%** of breast cancers, with associated **protein overexpression**
- Her2 amplified tumors respond to treatment with anti-Her2 antibody (**Herceptin**)

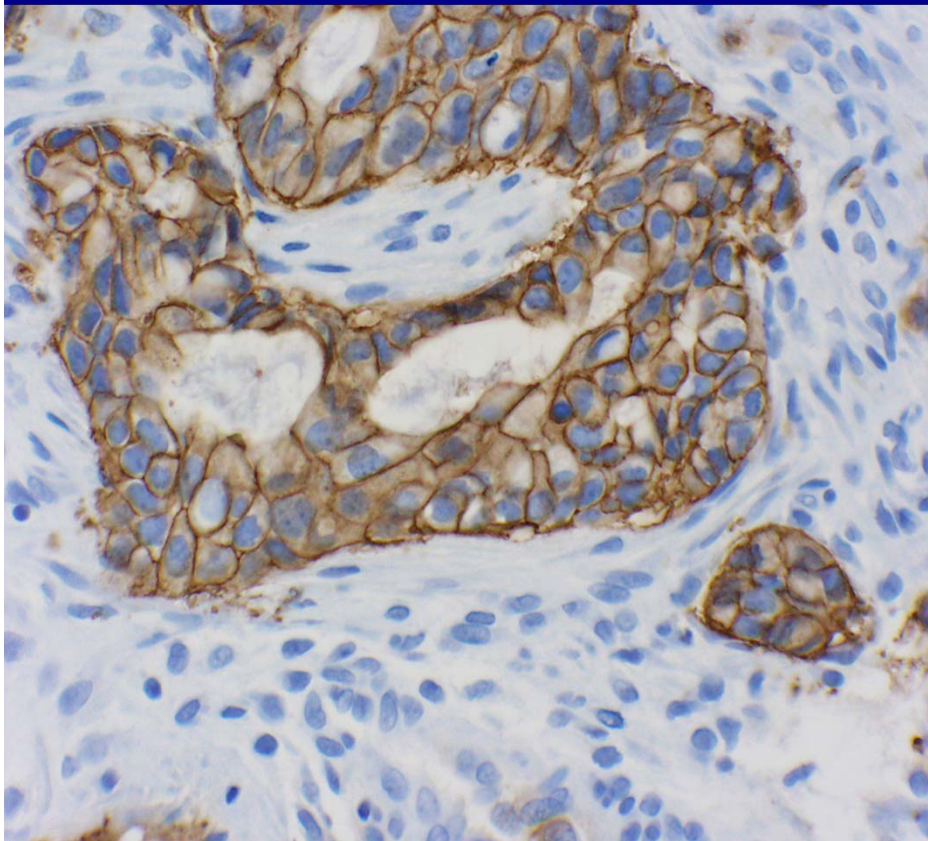
and other small molecules--good treatment options

staining--chicken wire on membrane

her2 amplification

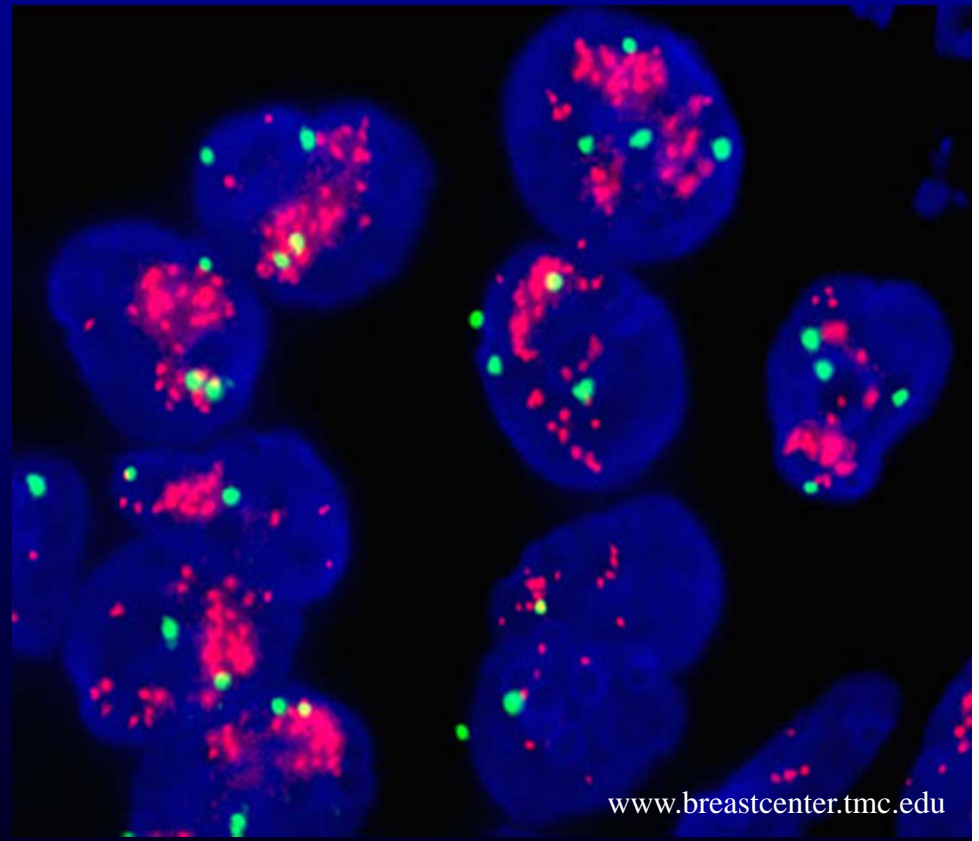
Her2 in Breast Cancer

Immunohistochemistry



Strong **membrane** staining

FISH- Her2 amplified



Her2 signal >> Centromere 17 signal

Molecular Studies

- **Oncotype Dx** first generation of these molecular tests that predict survival and various responses to chemo agents
- **21 gene rtPCR molecular test**
- **First of many likely molecular tests for breast cancer**
 - **Prognostic:** Predicts 10 year disease free survival in ER positive tumors
 - **Predictive:** Likelihood of response to chemotherapy.

Summary

- Described the clinical presentation of common breast pathologies
- Explained what "fibrocystic change" means and described several of the most common benign breast lesions.
- Described the common types of breast cancer
- Discussed major prognostic factors in breast cancer
- Explained why testing for expression of estrogen receptor and Her2/neu is an important part of breast cancer analysis

Contact information:

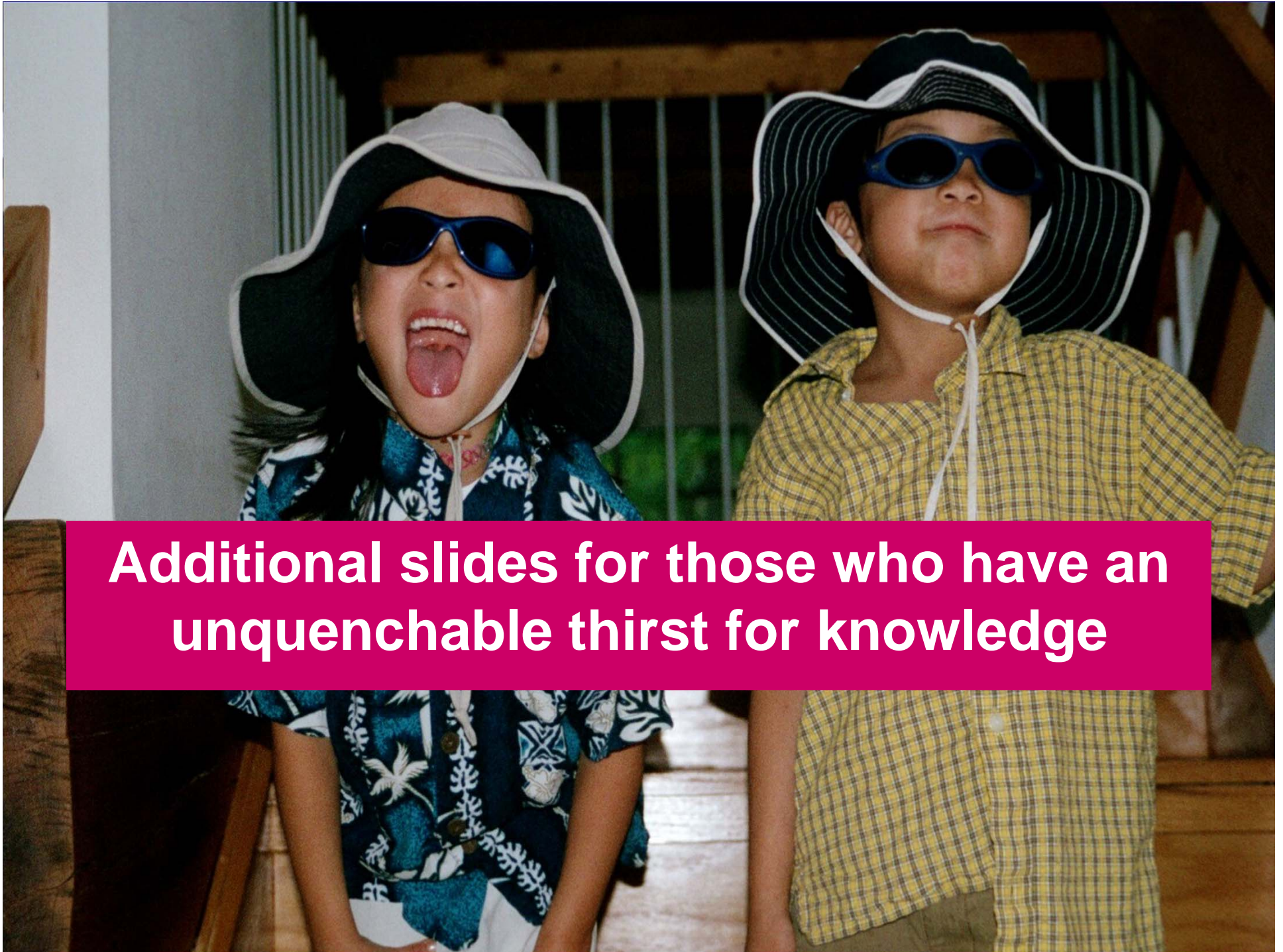Rex Bentley

M216A Duke South Green Zone

684-6423

Rex.Bentley@duke.edu

**For more details Pathology 448C—Practical
Surgical Pathology (4th year elective)**



Additional slides for those who have an unquenchable thirst for knowledge

Unique Manifestations of Breast Cancer

Or two things to know
about that will help you
avoid unpleasant
encounters with
malpractice lawyers!



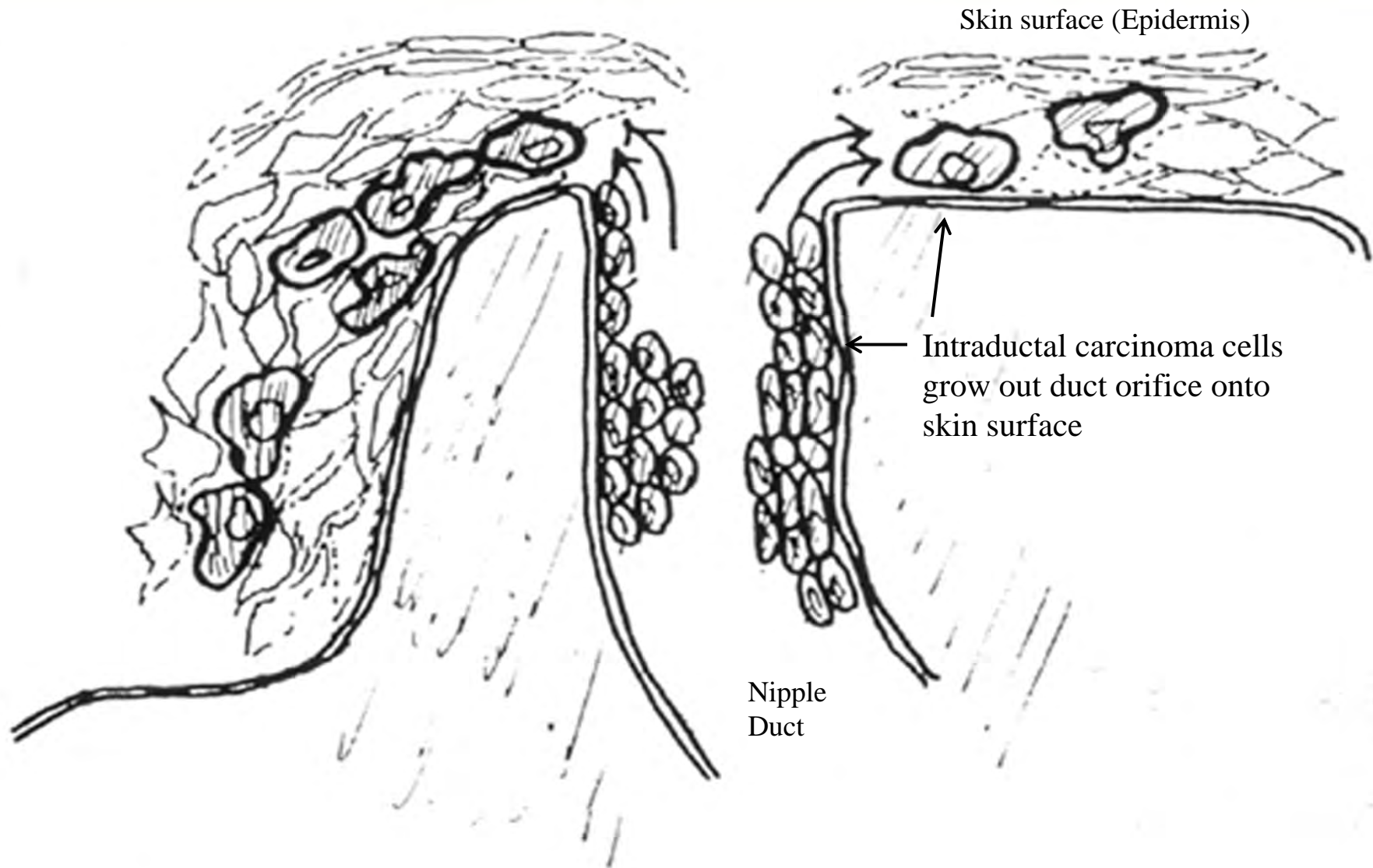
Paget's Disease

- **Eczematous, scaly, red rash around nipple**
- **Represents ductal carcinoma in-situ invading epidermis of nipple**
- **Frequently not recognized clinically—
diagnosis of breast cancer delayed**

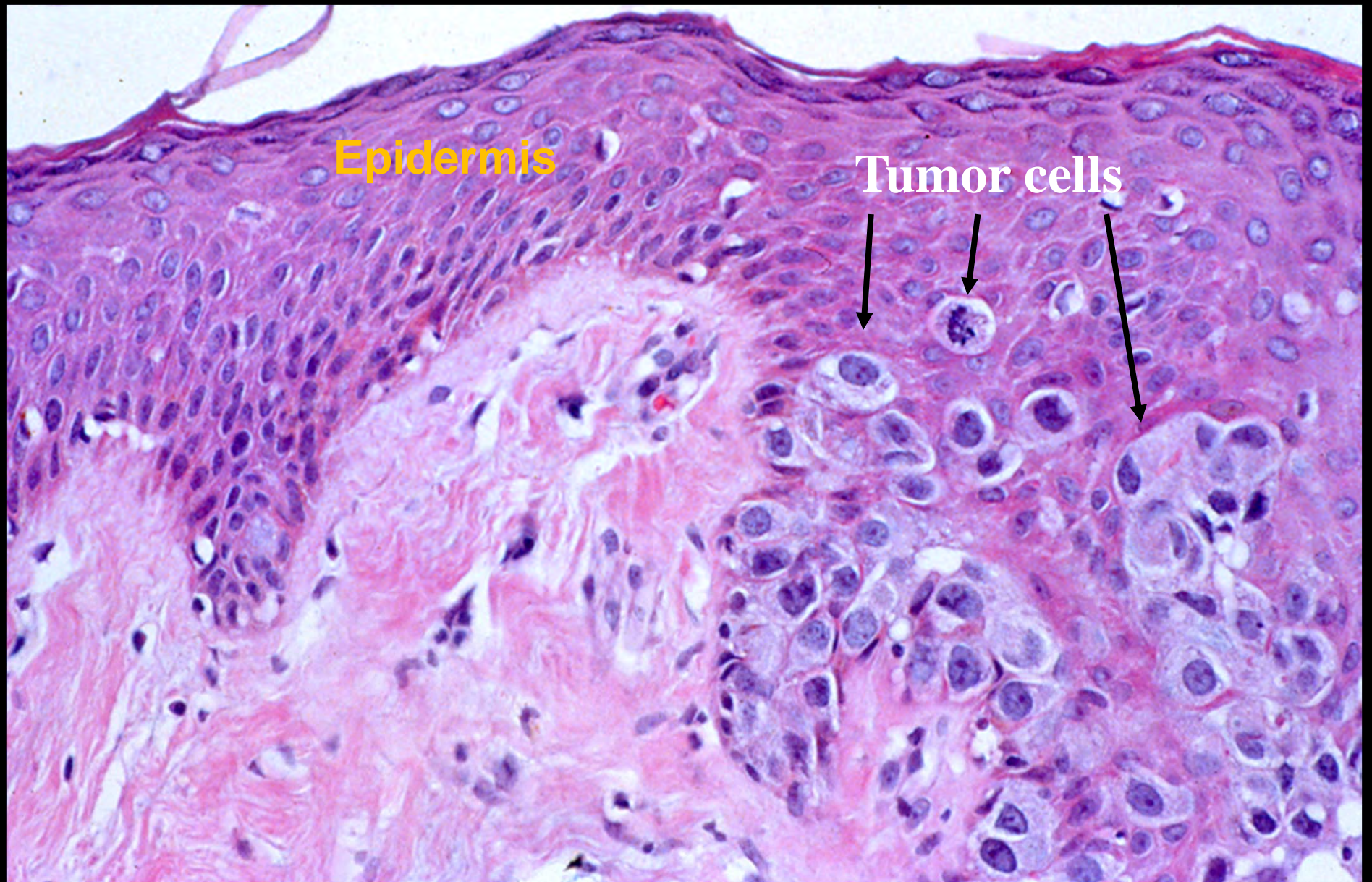
Paget's Disease

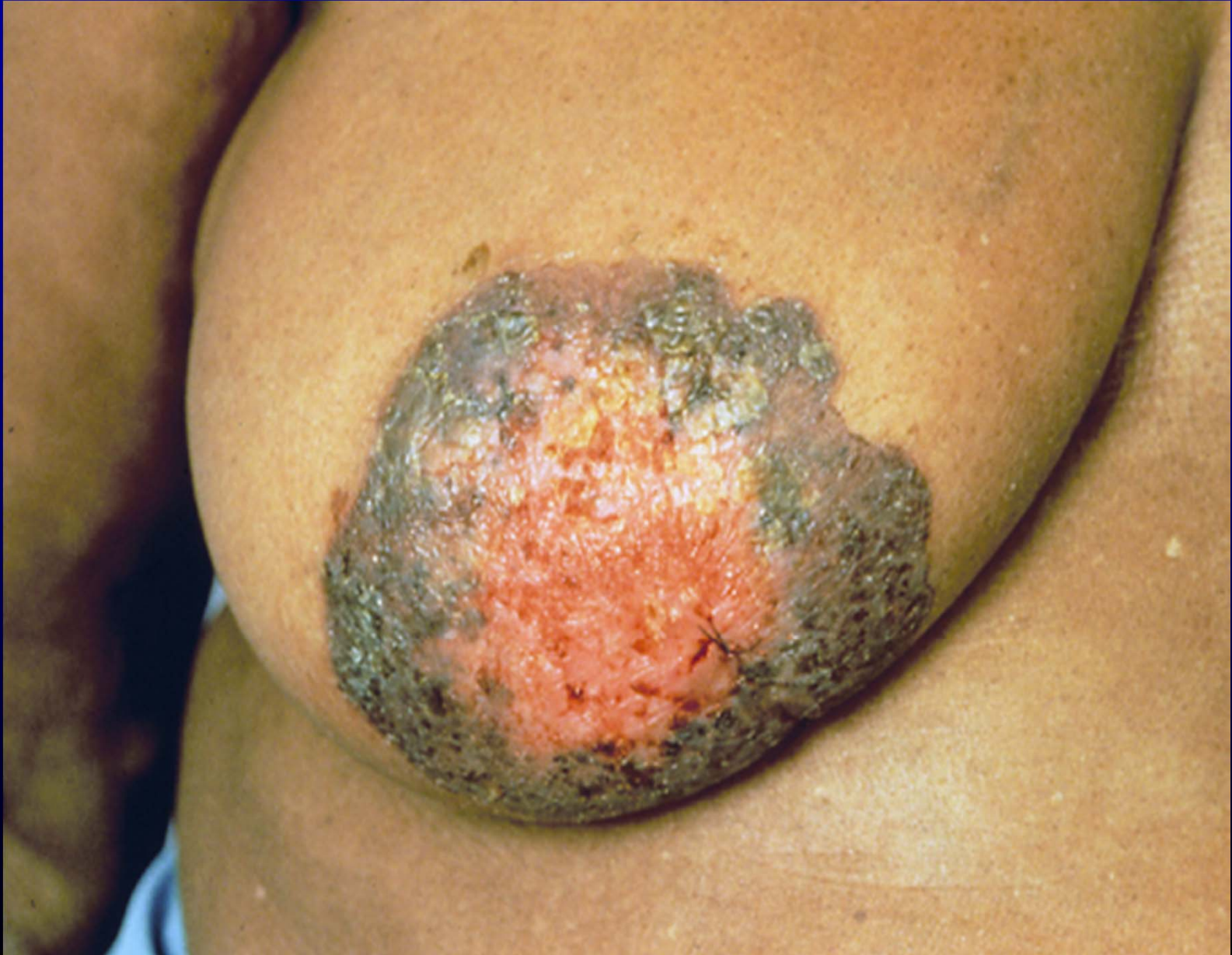

Diagram of Paget's



Paget's Disease of the Nipple



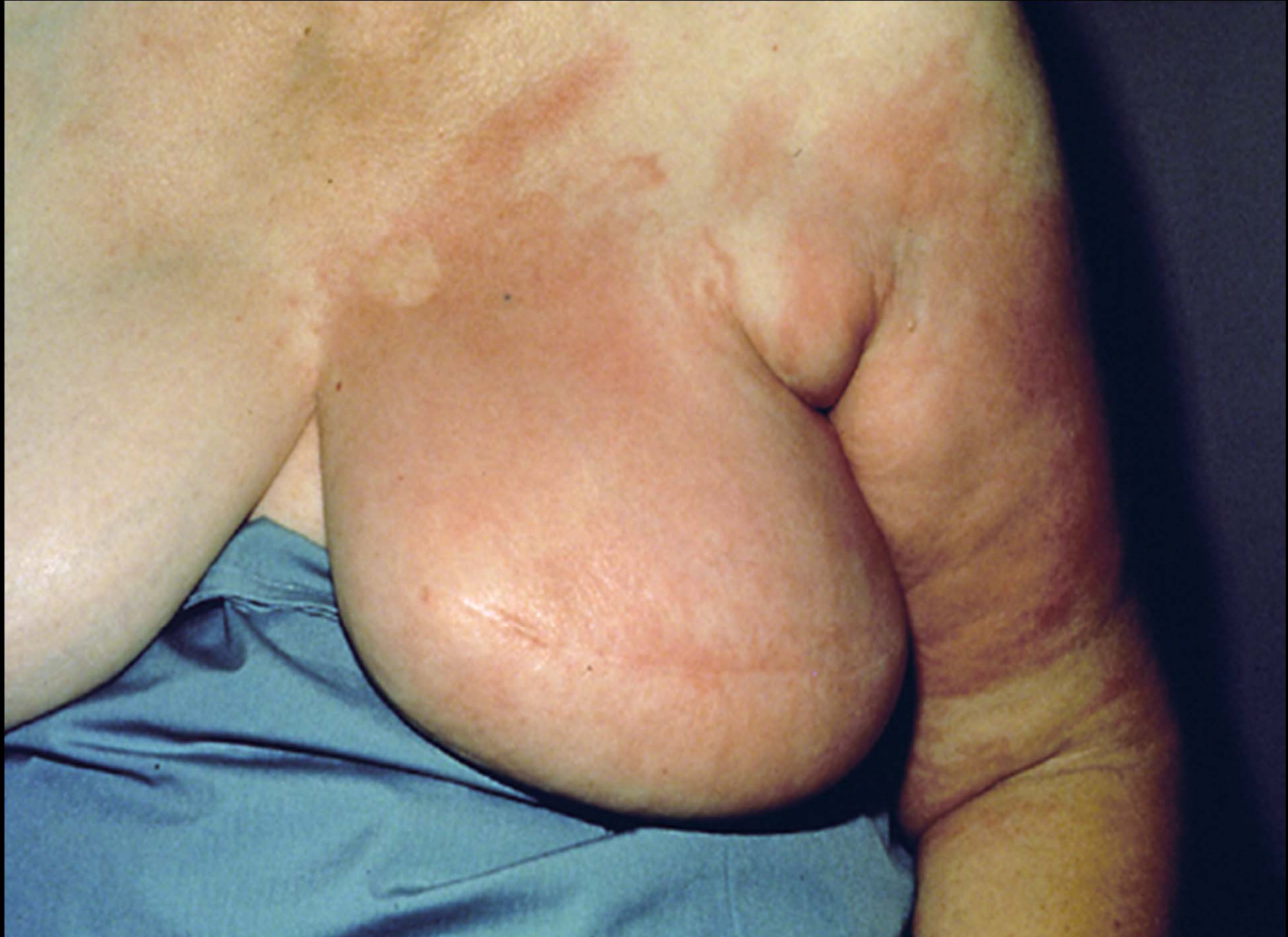Remember...

- 1. Rashes around the nipple can represent breast cancer.**
- 2. When your patient discovers that you've been treating her breast cancer with topical steroids, she will not be pleased!**

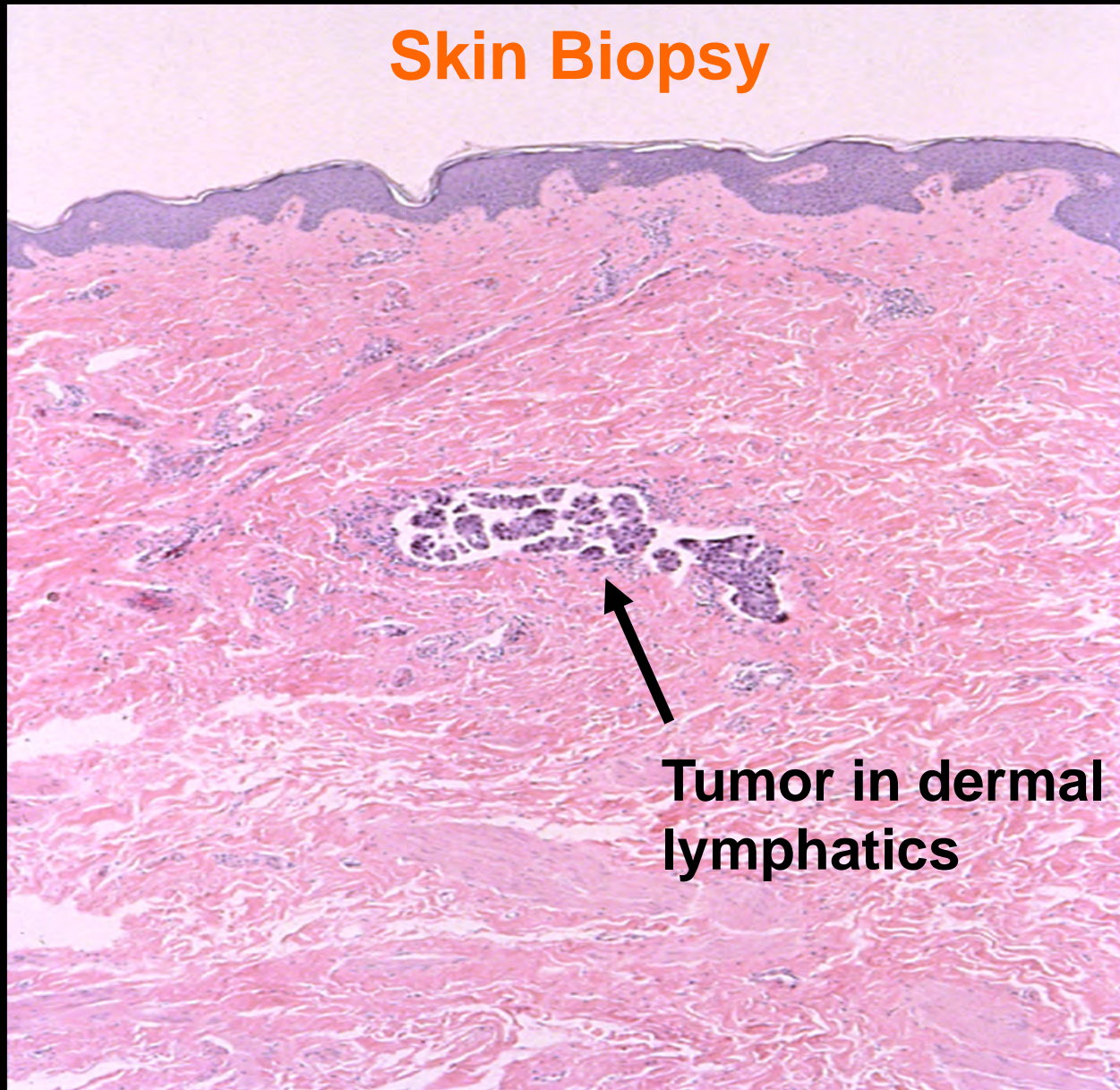
Inflammatory Carcinoma

- Diffusely red, swollen, hot breast
- Associated with very poor prognosis (considered T4 disease)
- Skin biopsies show plugging of dermal lymphatics by tumor cells
- Closely mimics infection (cellulitis) but does not respond to antibiotics; often not recognized clinically—diagnosis delayed

Inflammatory Carcinoma



Inflammatory Carcinoma



Remember...

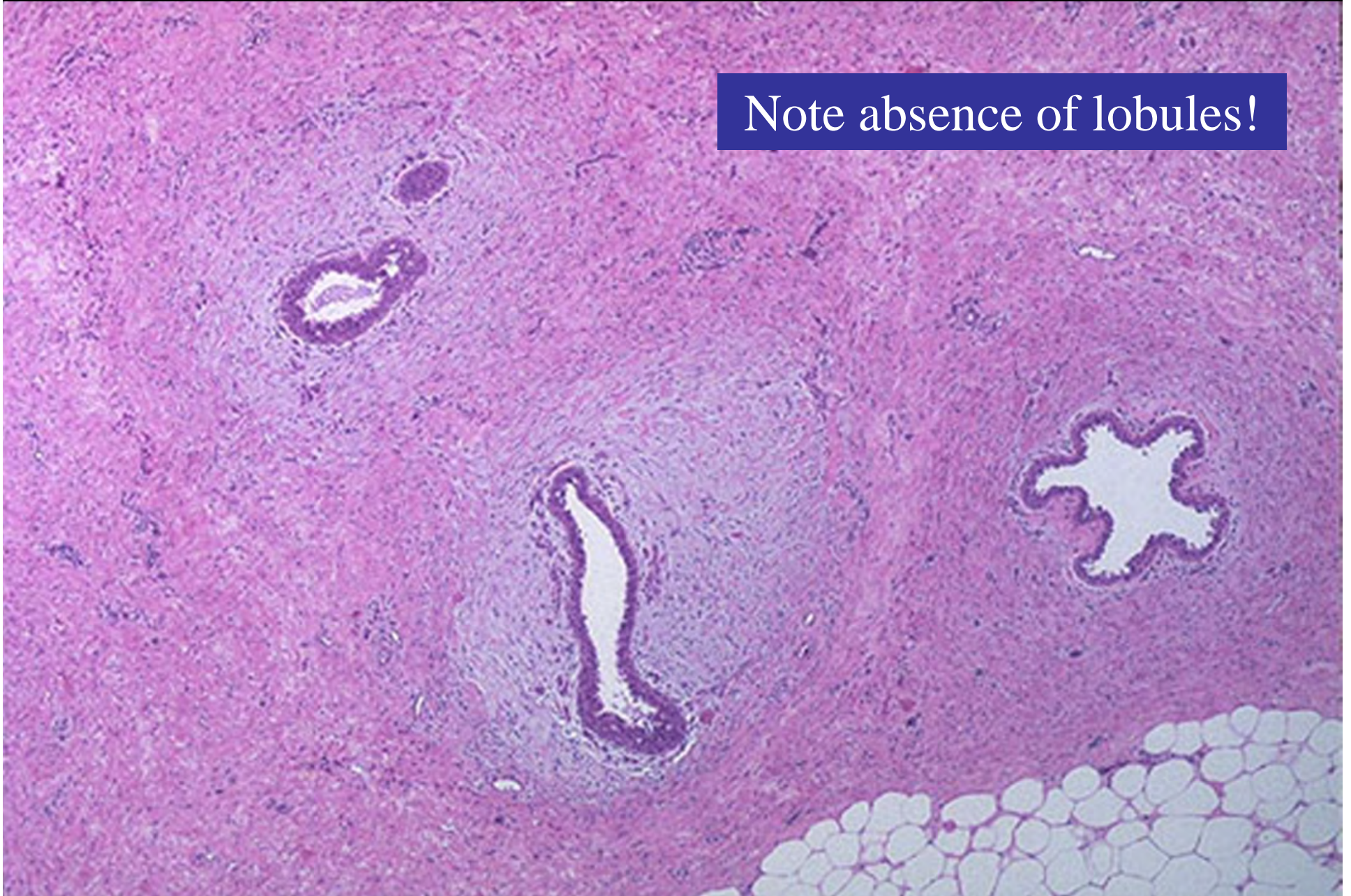
1. **“Cellulitis” in the breast can represent breast cancer**
2. **Six weeks of antibiotics will not cure breast cancer!**

Male Breast

- **Gynecomastia**
 - Enlargement of male breast
 - Relative estrogen excess: puberty, old age, cirrhosis, estrogen secreting tumors.
- **Carcinoma -- rare**
 - <1% of breast cancer occurs in men
 - Strong association with BRCA2
- **Other pathology rare**

Gynecomastia

Note absence of lobules!



A photograph of a modern university campus. In the background, a large, multi-story building with a prominent cylindrical glass tower is visible. The foreground features a landscaped garden area with various green plants, including a large bush with pink flowers and a smaller bush with yellow and white flowers. A paved road or walkway is visible on the left side of the image. The text "The End (Really!)" is overlaid in white, bold font across the center of the image.

The End (Really!)