

Simplified approach to cutaneous adnexal tumors

Chandra Smart, MD
Associate Clinical Professor
UCLA Department of Pathology

Introduction:

- Cutaneous adnexal neoplasms (CANs) are a diverse group of tumors that derive from either the folliculo-sebaceous/apocrine unit or the eccrine glands
 - Occasionally, these neoplasms display more than one line of differentiation
- Correct histopathologic diagnosis of these lesions is important as they might be markers of different syndromes associated with internal malignancy
- The majority of CANs are benign and conservative complete excision of these lesions is curative
 - Malignant counterparts, although rare, have been described for the majority of these tumors

Introduction:

- Classification of cutaneous sweat gland lesions is very complex
- Pathogenesis and exact origin of many of these lesions is not clear
- Issue is complicated by the many different terms used to describe the same tumors
 - Never-ending "splitters"

Sweat gland neoplasms

- | | |
|-------------------------------|---|
| • Hidrocystoma | Apocrine/eccrine hidrocystoma, cystadenoma |
| • Poroma | Hidroacanthoma simplex (intraepidermal poroma), eccrine poroma, dermal duct tumor |
| • Hidradenoma | Nodular hidradenoma, solid-cystic hidradenoma, clear cell hidradenoma, clear cell acrospiroma, eccrine acrospiroma |
| • Tubulopapillary hidradenoma | Papillary eccrine adenoma, tubular apocrine adenoma, papillary apocrine fibroadenoma |
| • SCAP | Papillary syringoadenoma |
| • Hidradenoma papilliferum | Papillary hidradenoma |
| • Microcystic adnexal CA | Sclerosing sweat duct carcinoma |
| • Chondroid syringoma | Mixed tumor of the skin |
| • Syringofibroadenoma | Acrosyringal adenomatosis, acrosyringal nevus |
| • Digital papillary adenoCA | Aggressive digital papillary tumor, aggressive digital papillary adenoma/carcinoma, aggressive digital papillary adenoma |
| • Sweat gland ductal CA | Syringoid eccrine carcinoma, eccrine ductal carcinoma |
| • Porocarcinoma | Malignant "eccrine" poroma |
| • Hidradenocarcinoma | Malignant nodular/clear cell hidradenoma, malignant acrospiroma, malignant clear cell acrospiroma, clear cell eccrine carcinoma, primary mucoepidermoid cutaneous carcinoma |
| • Apocrine carcinoma | Tubular apocrine carcinoma, malignant hidradenoma papilliferum |

Introduction:

- Tumors of the pilosebaceous unit:
 - Pilar sheath acanthoma
 - Tumor of the follicular infundibulum
 - Trichoadenoma
 - Trichilemmoma
 - Desmoplastic trichilemmoma
 - Trichofolliculoma
 - Trichoepithelioma
 - Desmoplastic trichoepithelioma
 - Trichoblastoma
 - Cutaneous lymphadenoma
 - Sebaceous adenoma
 - Sebaceoma
 - Sebaceous carcinoma
 - Trichilemmal carcinoma
- Tumors of the sweat glands:
 - Syringocystadenoma papilliferum
 - Hidradenoma papilliferum
 - Tubular apocrine adenoma
 - Poroma
 - Mixed tumor (chondroid syringoma)
 - Myoepithelioma
 - Hidroacanthoma simplex
 - Dermal duct tumor/hidradenoma
 - Syringoma
 - Cylindroma
 - Spiradenoma
 - Microcystic adnexal carcinoma
 - Adenoid cystic carcinoma
 - Primary mucinous carcinoma
 - Endocrine mucin-producing sweat gland carcinoma
 - Aggressive digital papillary adenocarcinoma

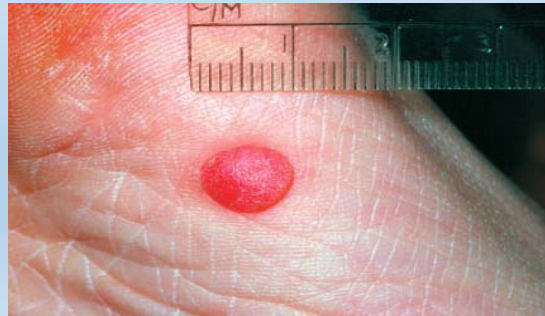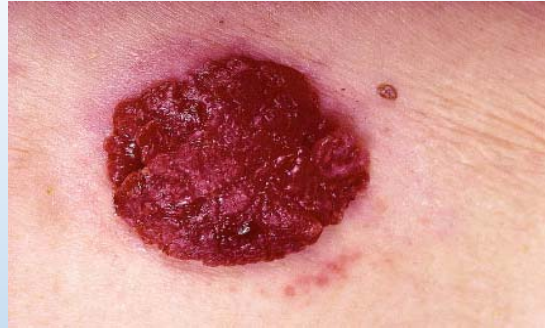Features of malignancy

- A malignant counterpart for most benign lesions has been described
 - Asymmetry of lesion
 - Jagged/infiltrative borders
 - Irregular arrangement of neoplastic cells
 - Cytologic atypia
 - Increased mitotic activity
 - Including atypical forms

Poroma

- **Clinical:**

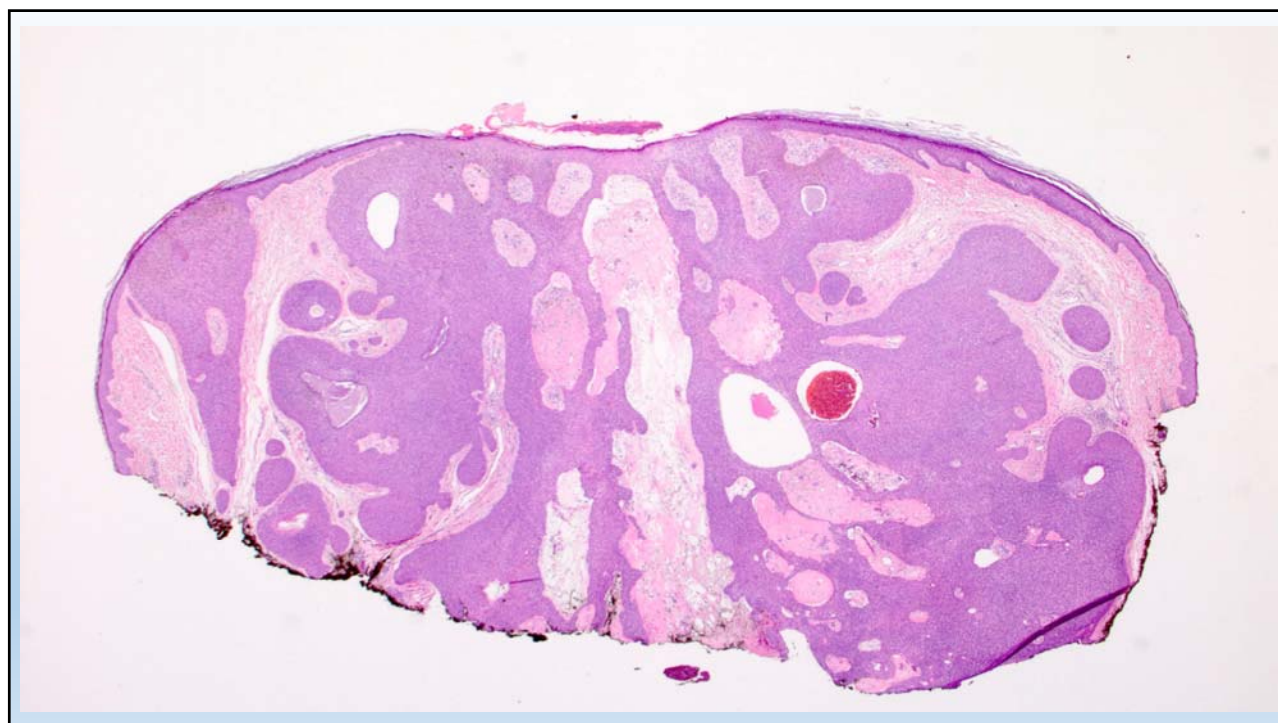
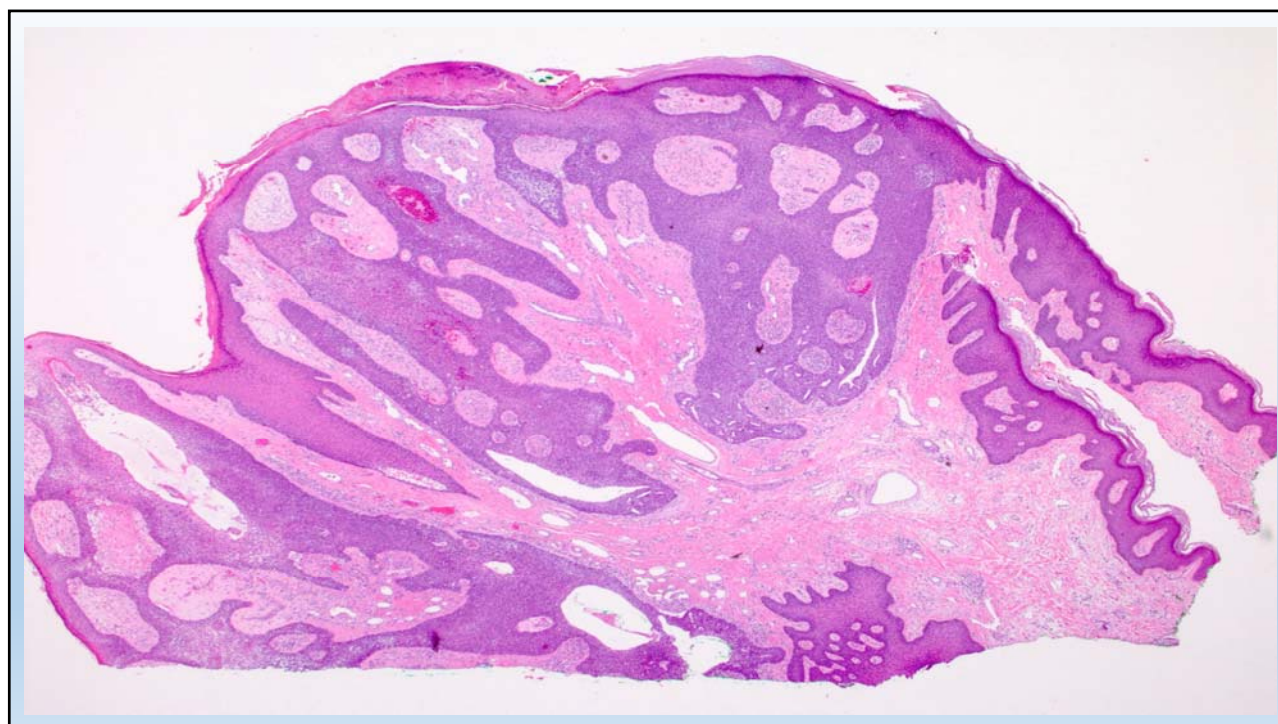
- Solitary, sessile, skin-colored to red, slightly scaly nodule
- Usually occur in adults, males=females
- Most often on sole or sides of foot
- May bleed after mild trauma
- May be mistaken for melanoma clinically

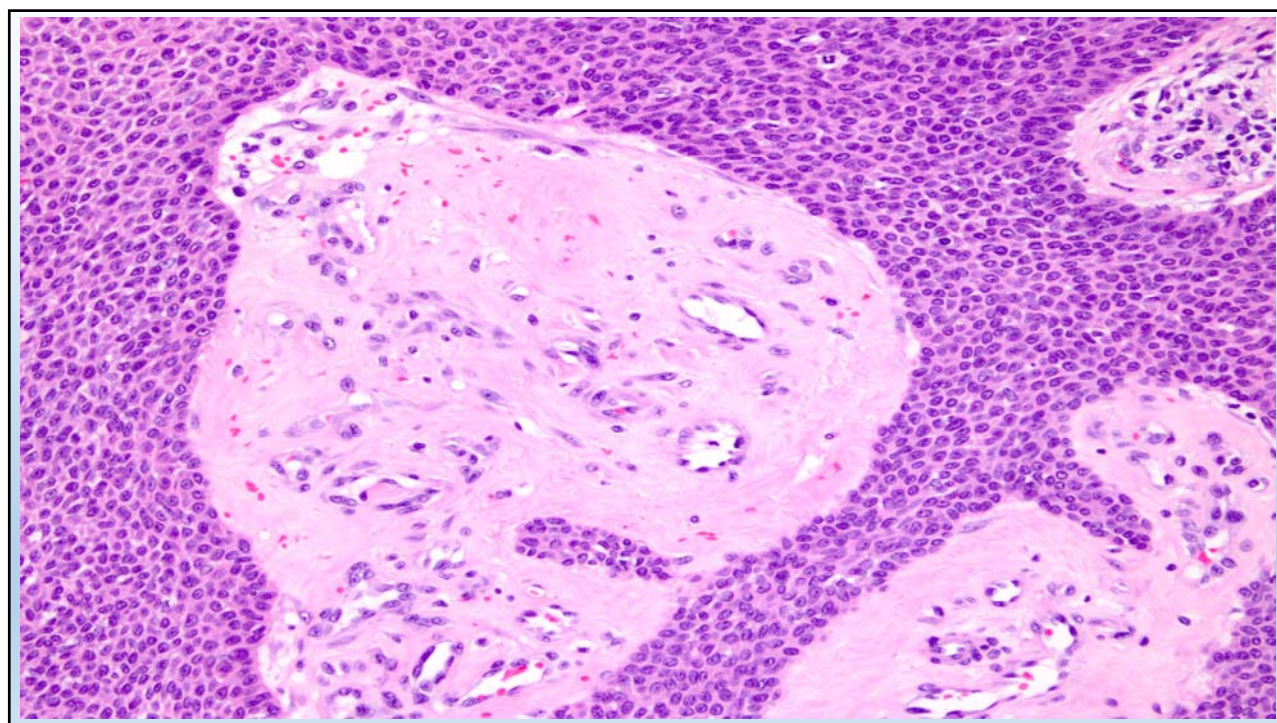
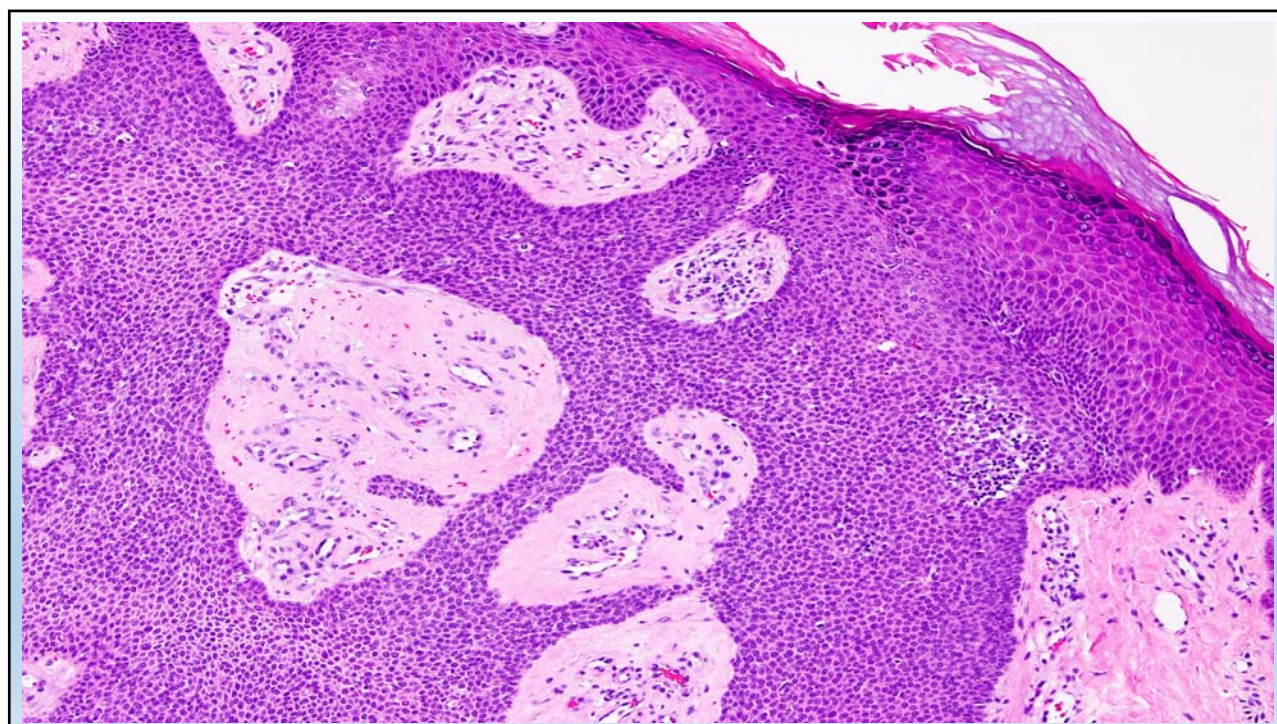


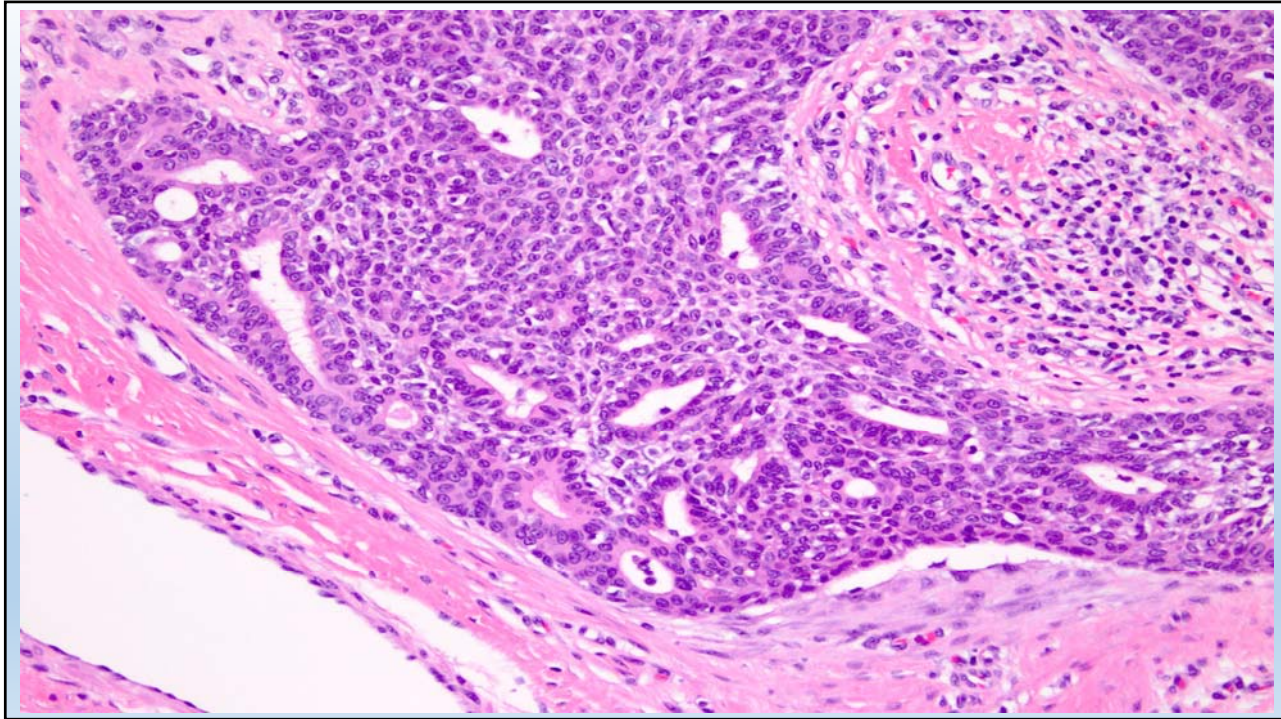
Poroma

- **Histologic features:**

- Arises from the epidermis and grows into the dermis in broad anastomosing bands
- Solid sheets and nodules of intermediate sized basaloid cells
- Sharply delineated from adjacent keratinocytes
- Characteristic "poroma stroma"
- Ductal structures
- DDx: Seborrheic keratosis

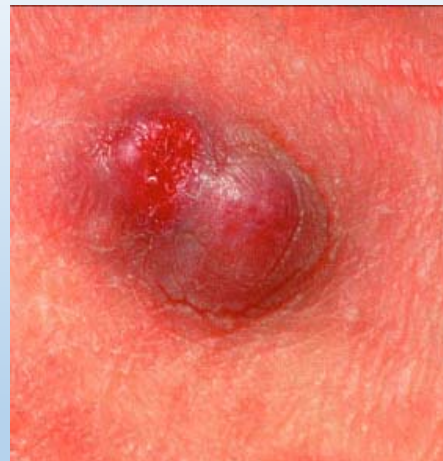






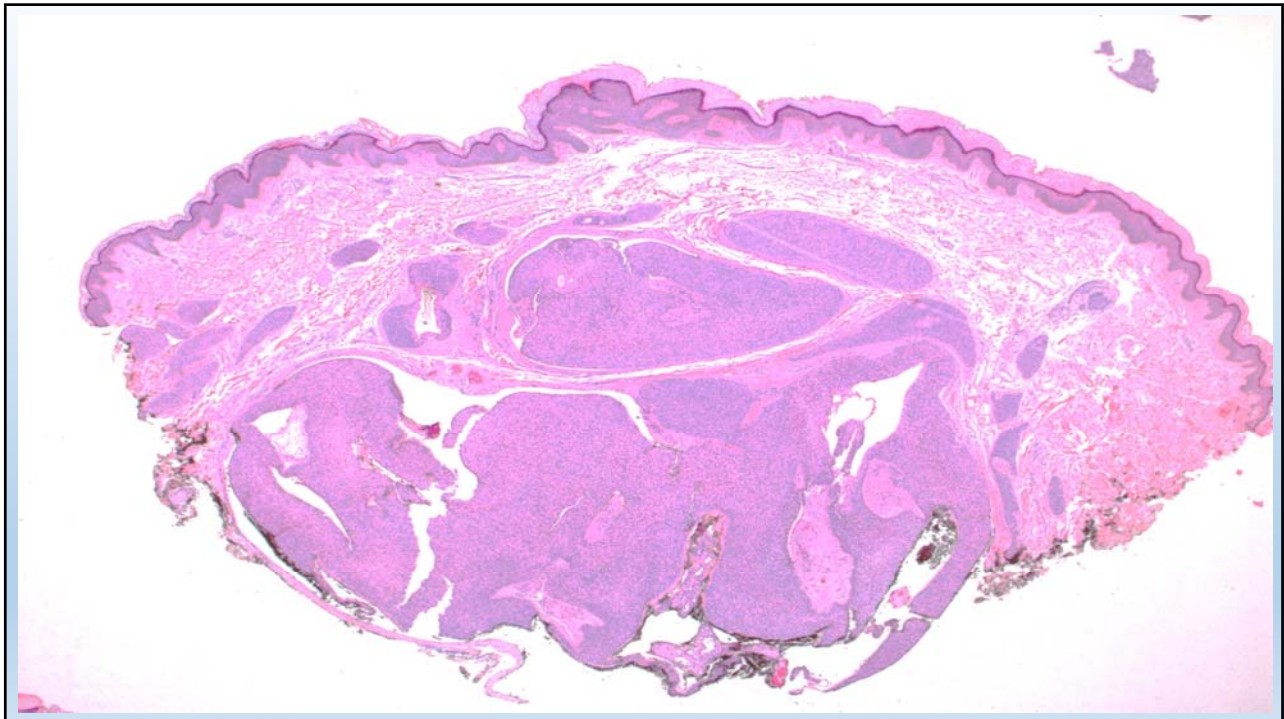
Hidradenoma

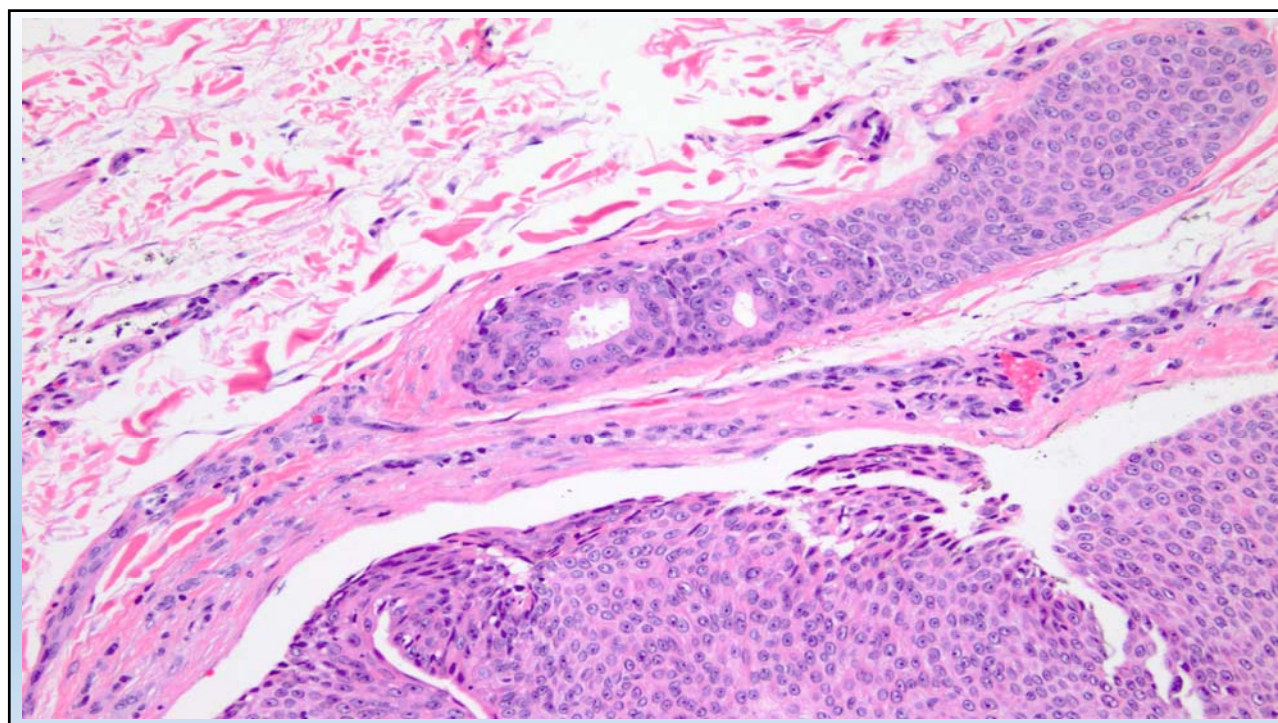
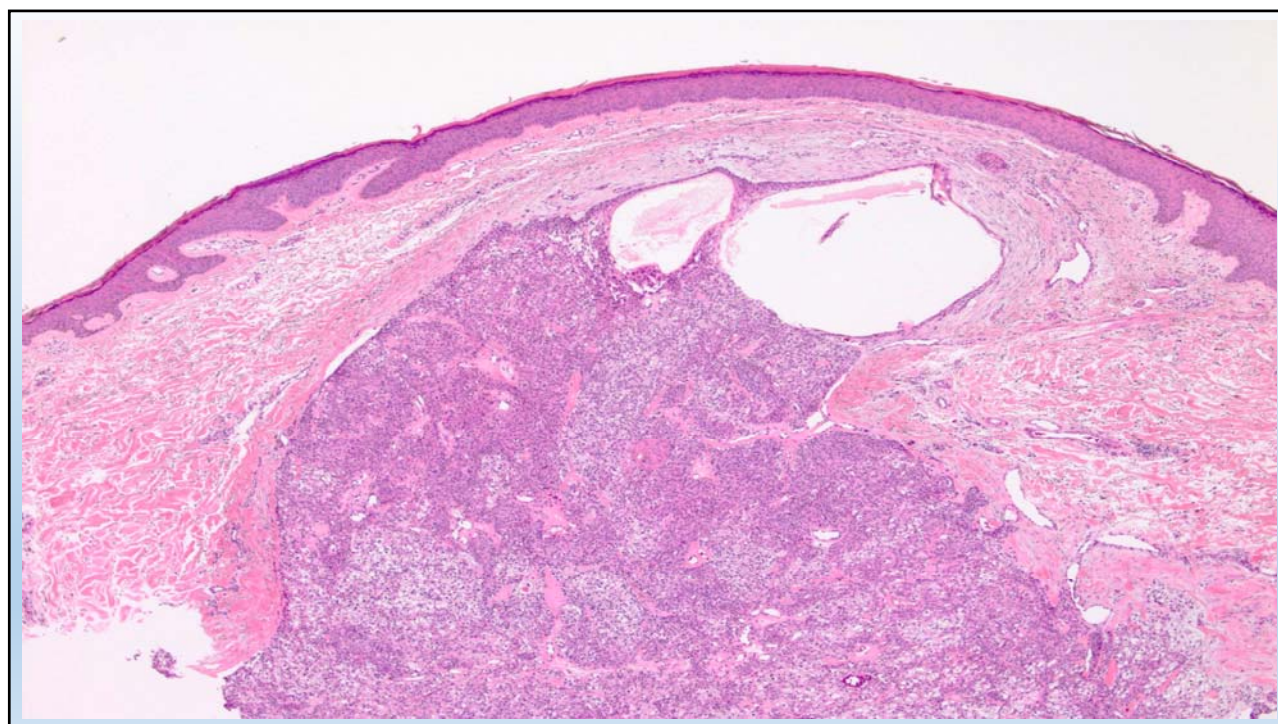
- Clinical:
 - Presents as a solitary, slowly growing, solid or cystic nodule on head/neck or limbs
 - Middle aged adults or elderly, females>males
 - Tumors may be symptomatic with oozing, hemorrhage, tenderness, pruritus, and burning

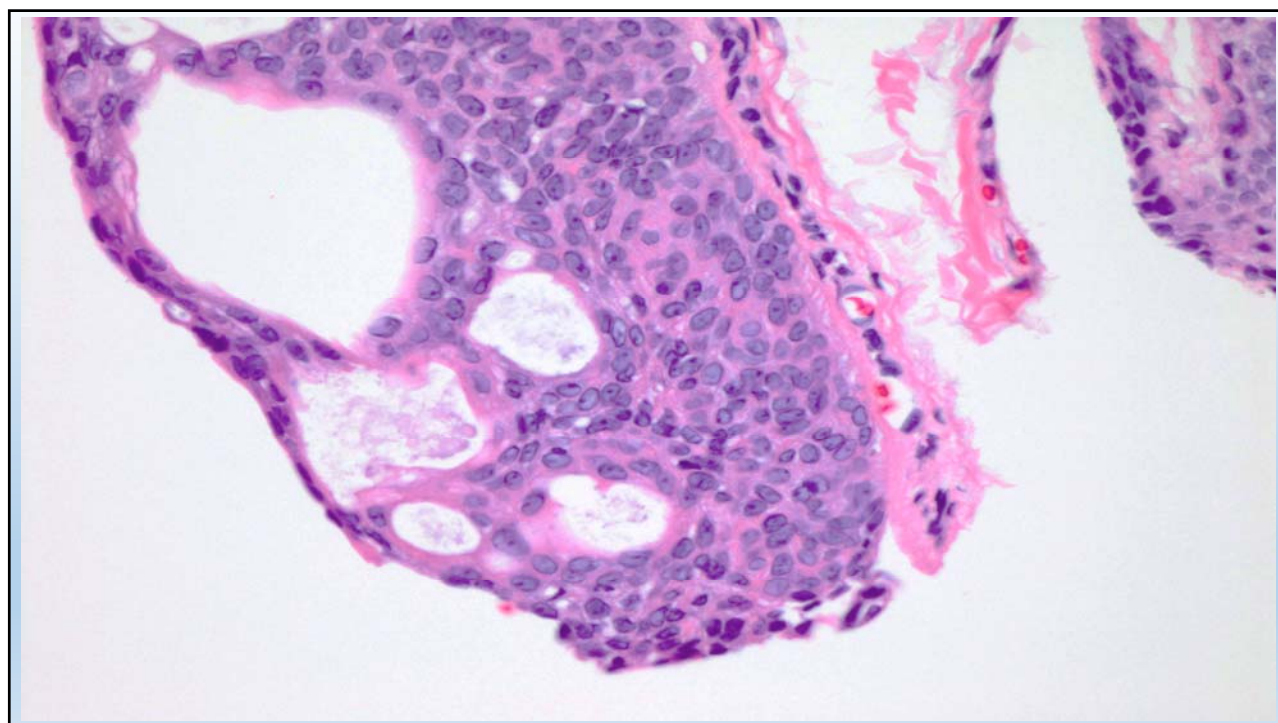
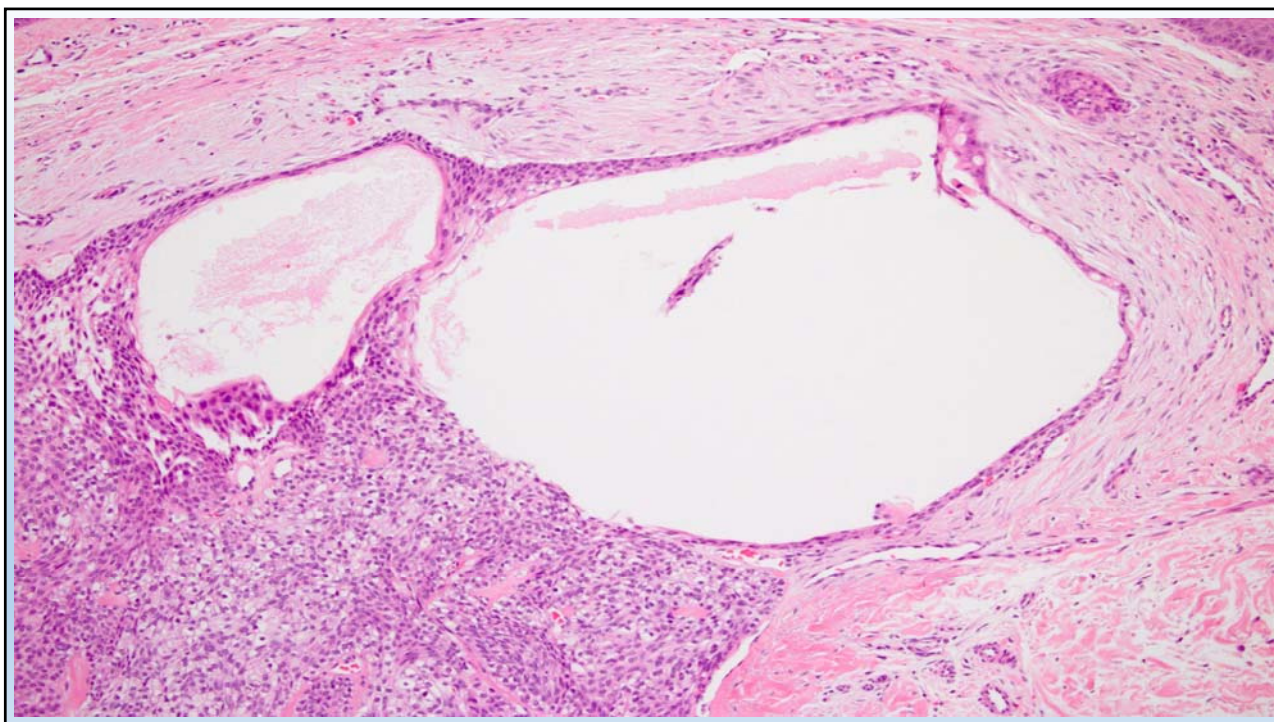


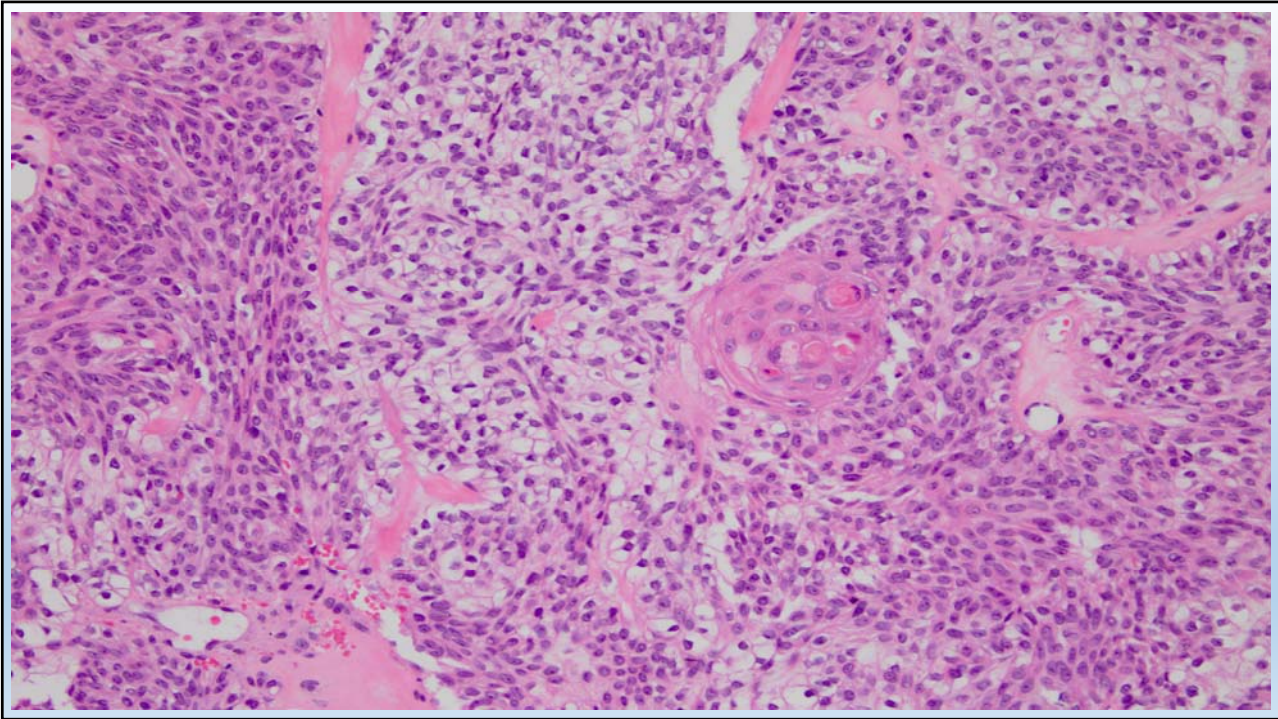
Hidradenoma

- **Histologic features:**
 - Circumscribed but unencapsulated, dermal based neoplasm
 - Can be solid or cystic
 - Variably sized nests and nodules
 - Biphasic cellular population
 - Polygonal cells with eosinophilic cytoplasm and clear cells
 - Small ductular lumens
 - Squamous metaplasia may be present
 - Tumor lobules are surrounded by fibrovascular, collagenous, or hyalinized stroma
 - DDx: Squamous cell carcinoma, metastatic renal cell carcinoma



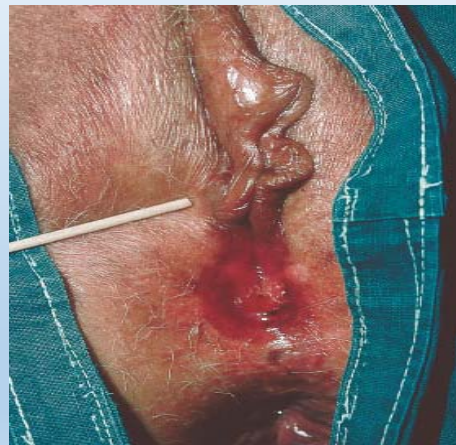





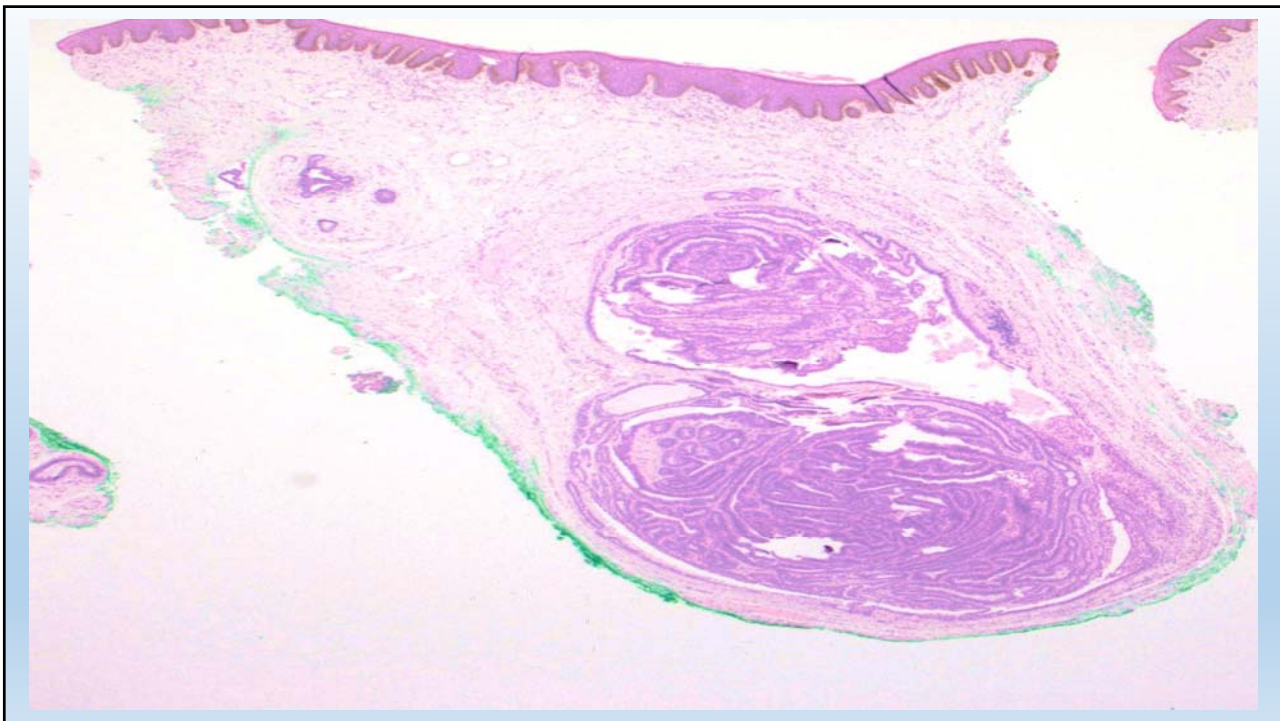
Hidradenoma papilliferum

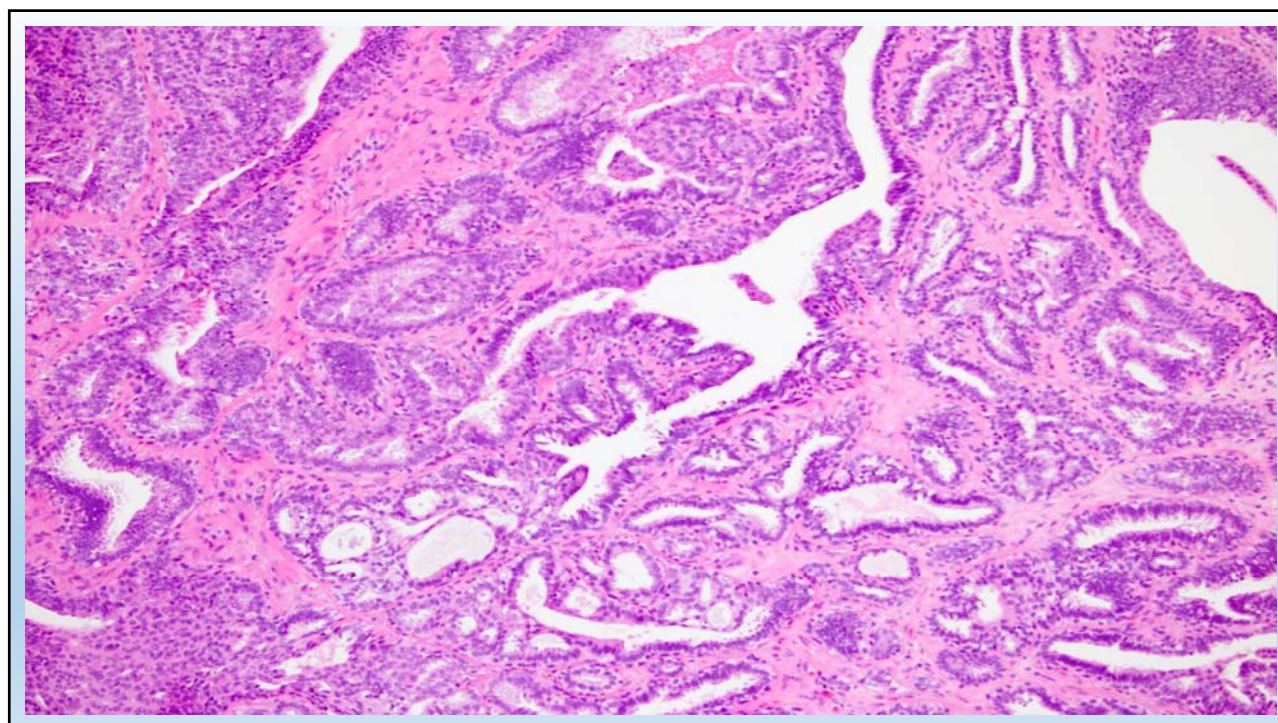
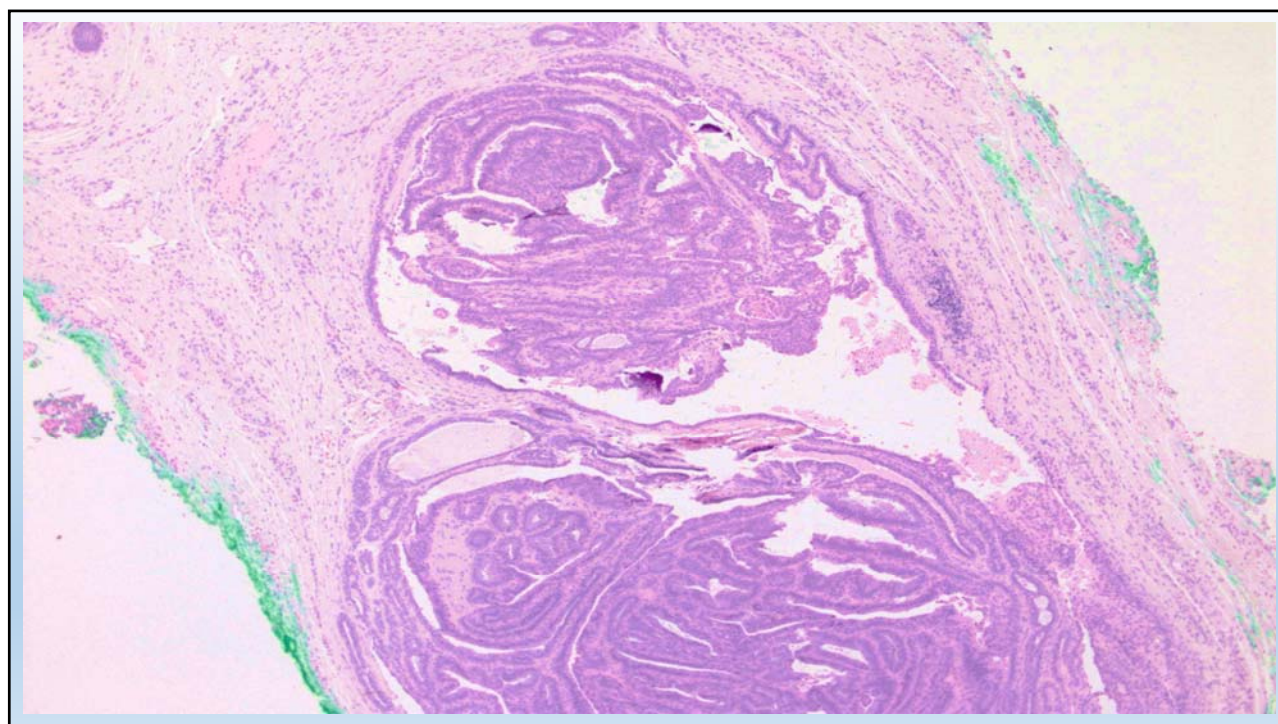
- Clinical:
 - Usually solitary, small and asymptomatic
 - Occasionally can be a large and elevated, reddish-brown mass that may ulcerate
 - Occurs almost exclusively in young to middle-aged females
 - Predilection for the vulva and peri-anal region

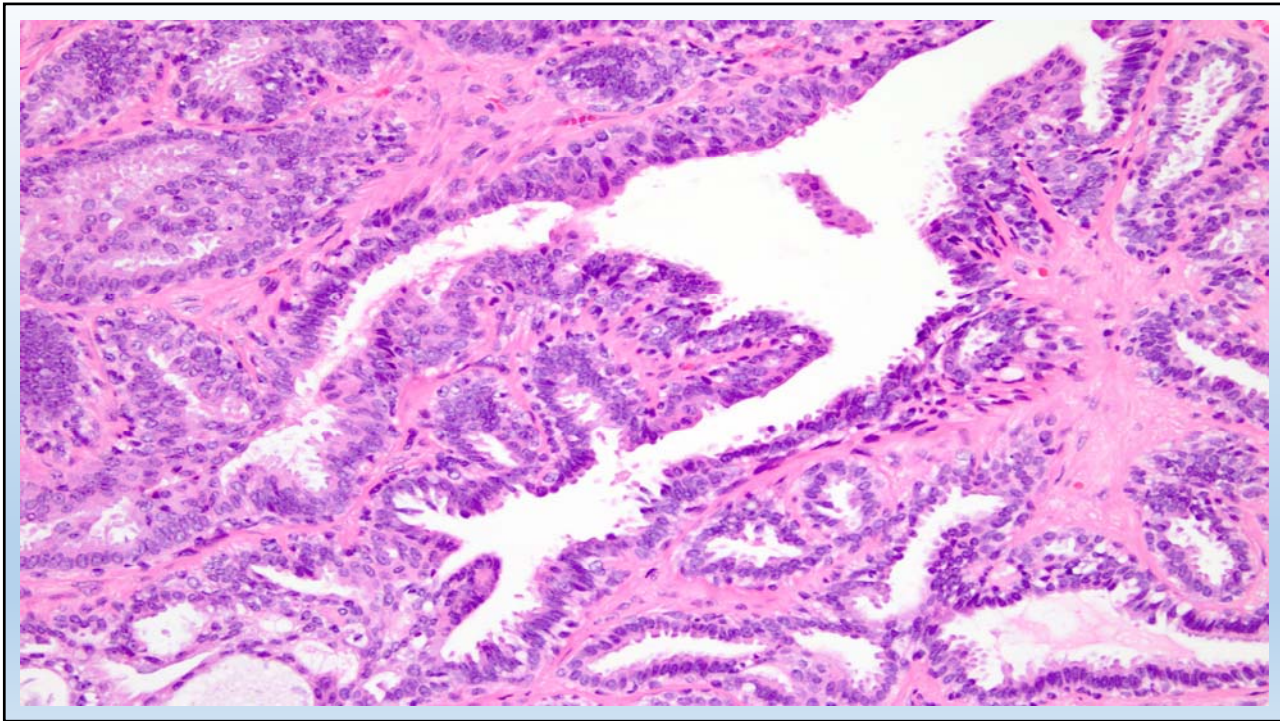


Hidradenoma papilliferum

- Histologic features:
 - Well-circumscribed solid/cystic nodule
 - Normally without an epidermal connection
 - Frond-like papillae and tubulo-papillary structures that project into cystic spaces
 - Epithelial lining is double-layered
 - Myoepithelial cells
 - Tall columnar cells
 - Very little inflammation

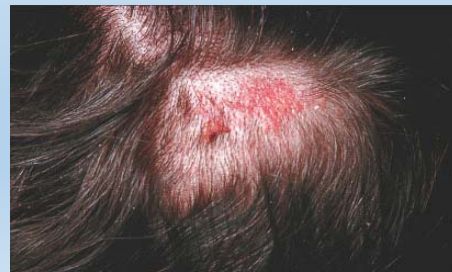
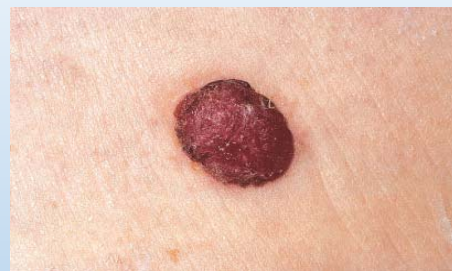




Syringocystadenoma papilliferum

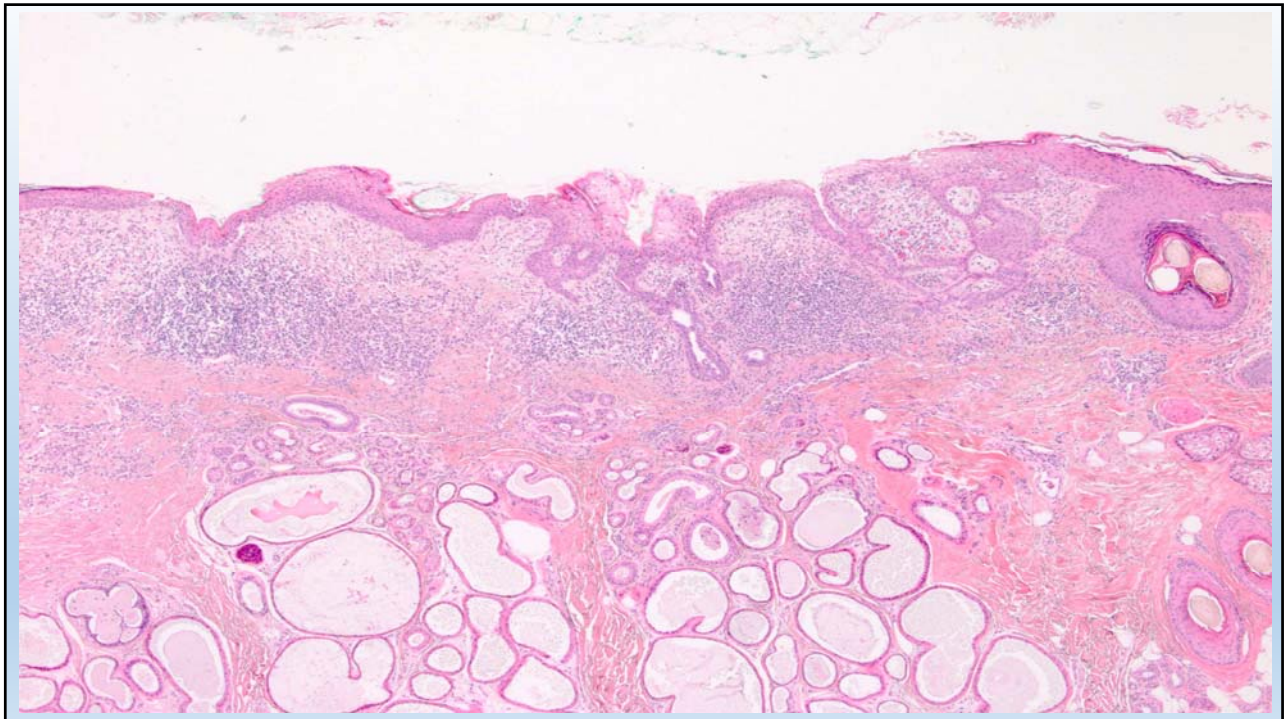
- **Clinical:**
 - Solitary, verrucous-like plaque or nodule, often moist or oozing surface
 - Arises on the face and scalp
 - Frequently congenital and associated with a nevus sebaceous (5-19%)

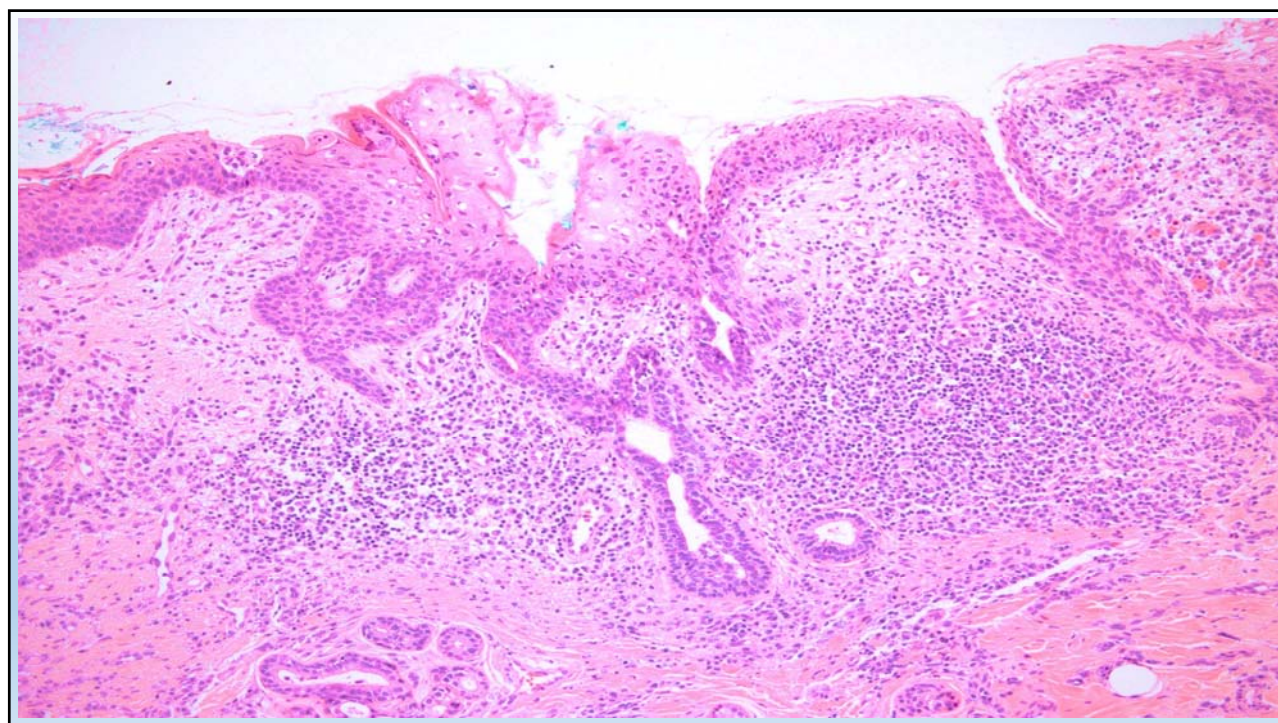
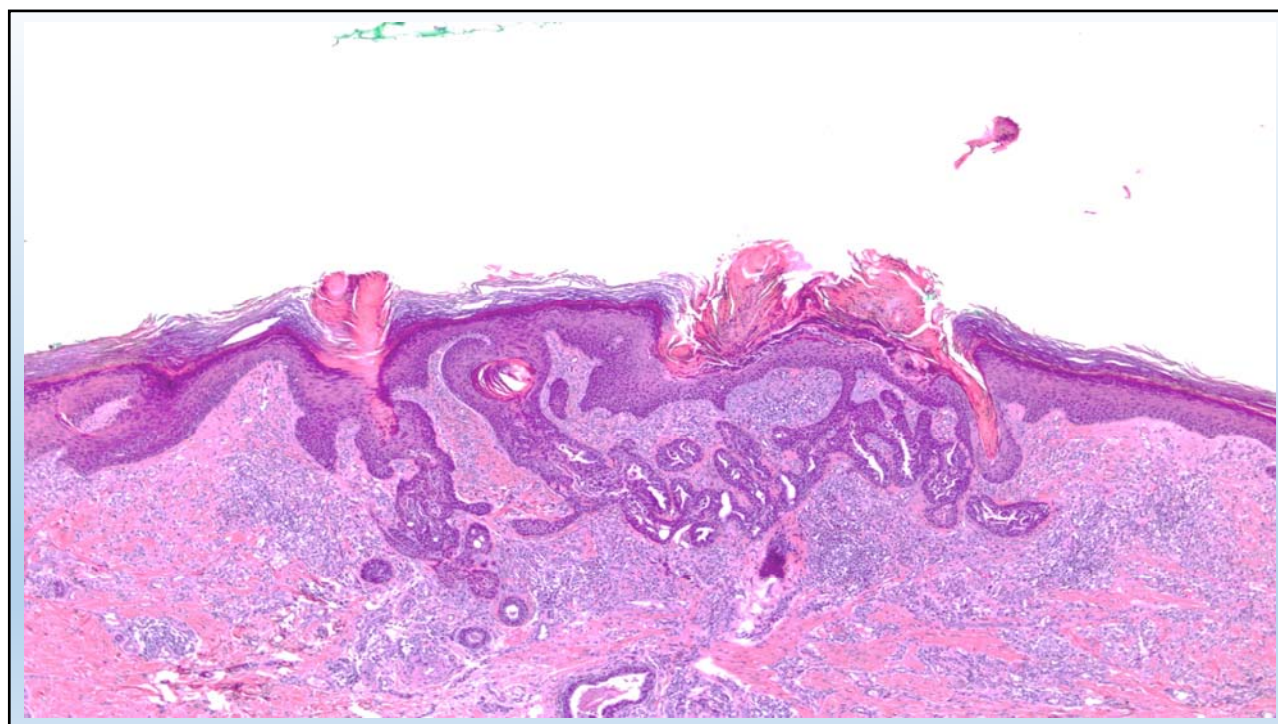


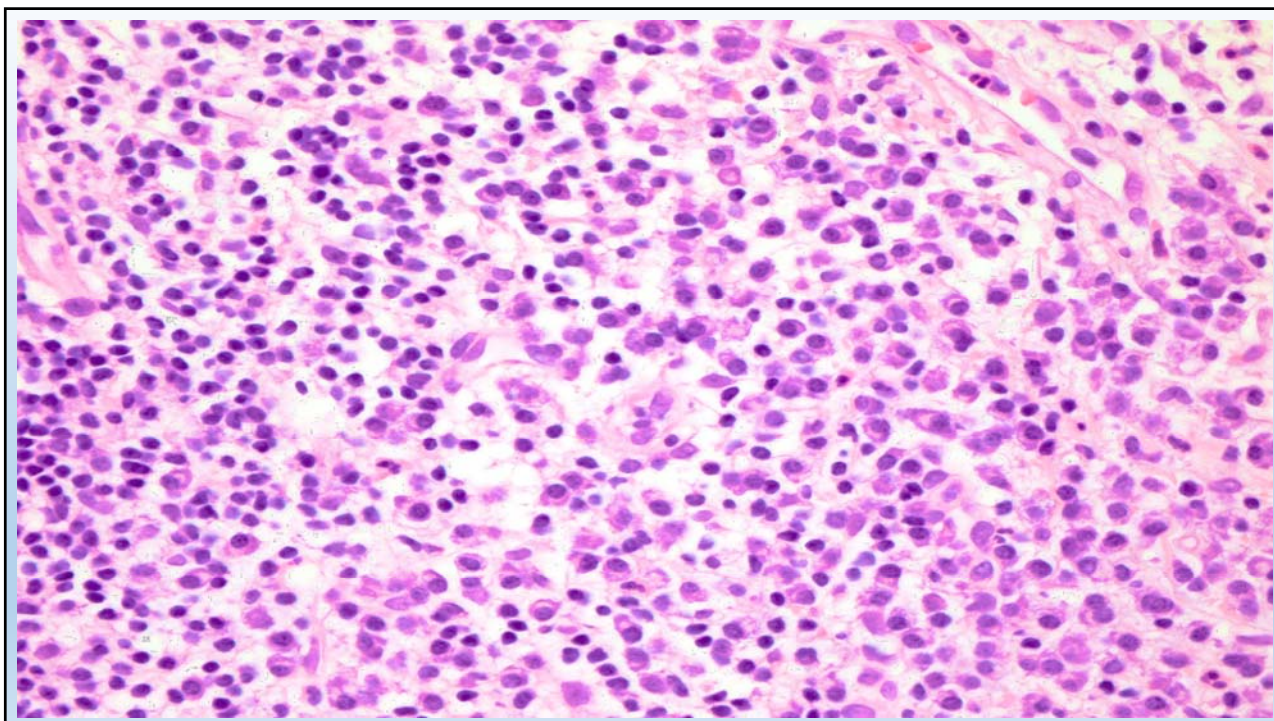
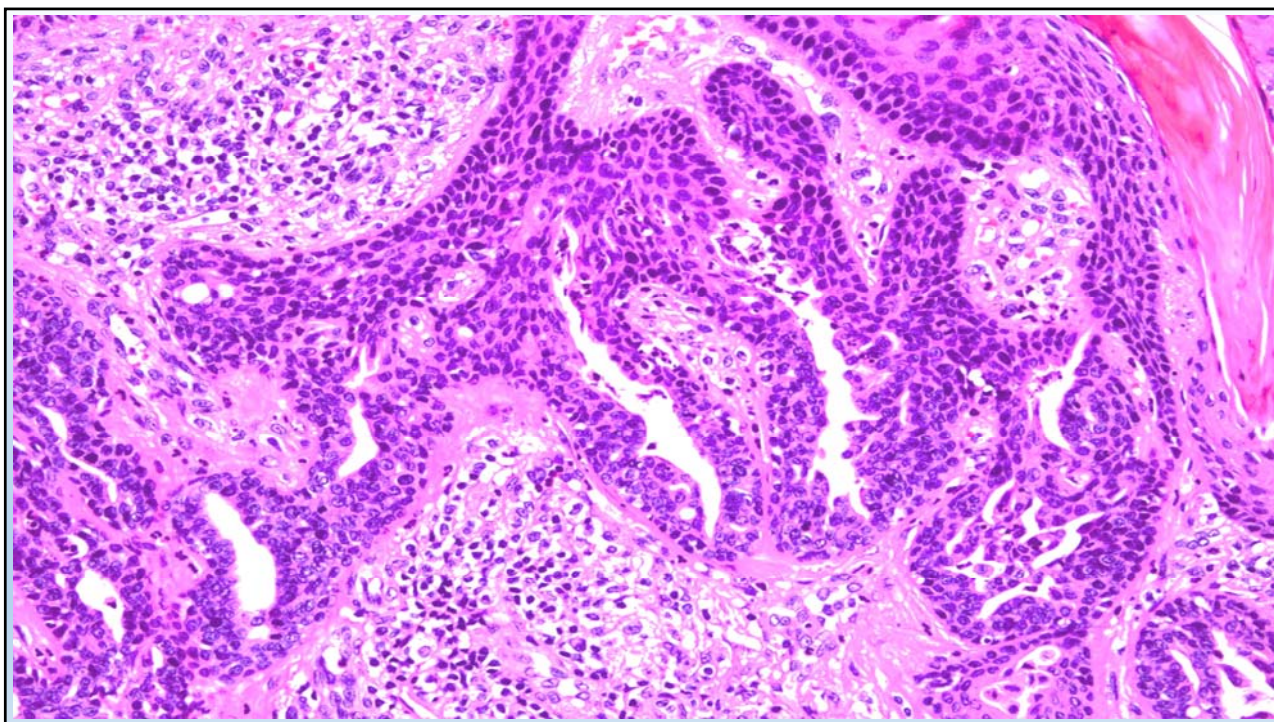
Syringocystadenoma papilliferum

- **Histologic features:**

- Verrucous epidermal surface
- Multiple epidermal invaginations extending into the dermis
- Cystic invagination contains numerous papillae lined by two layers of epithelial cells
- Also may see glandular structures
- Many plasma cells within fibrovascular cores



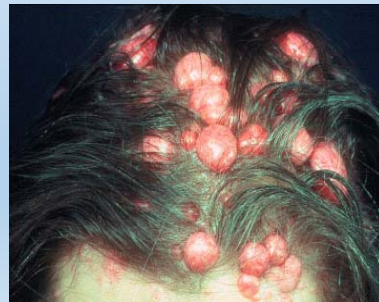
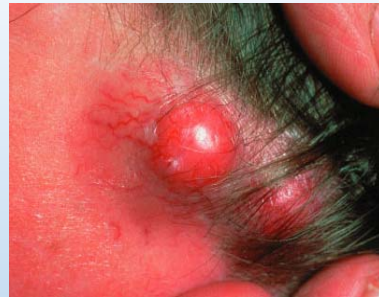


Cylindroma

- **Clinical:**

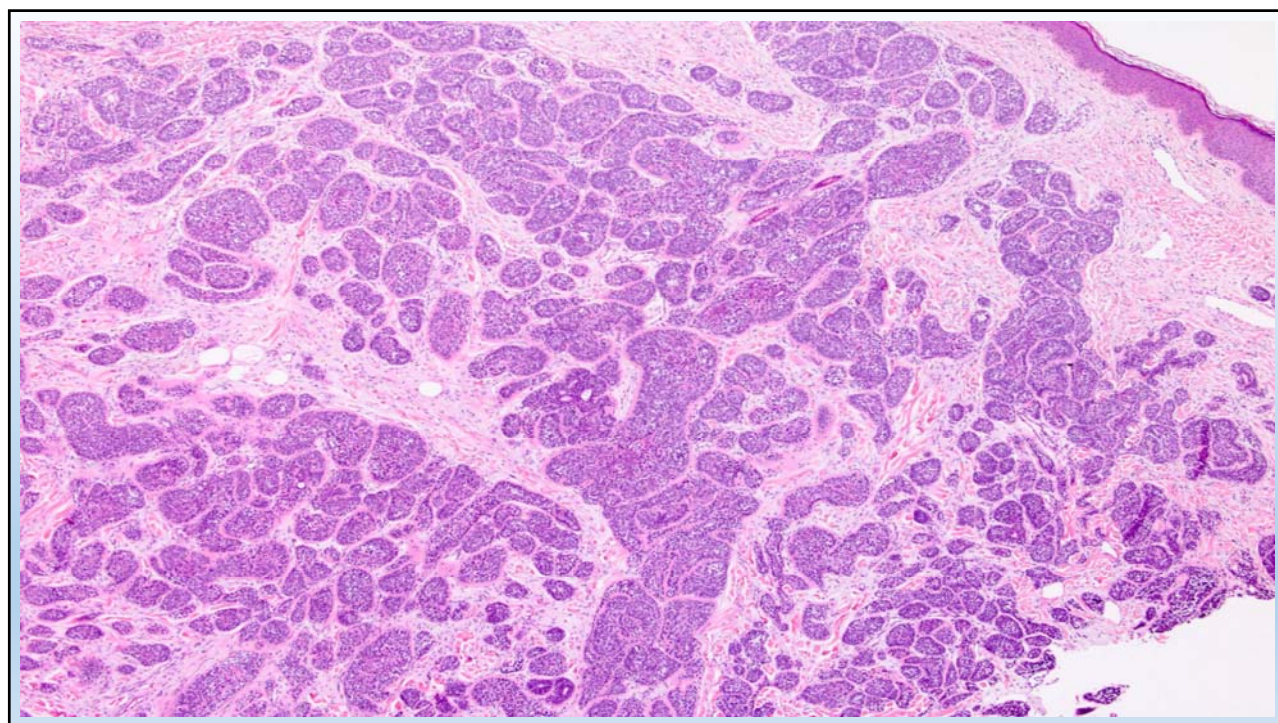
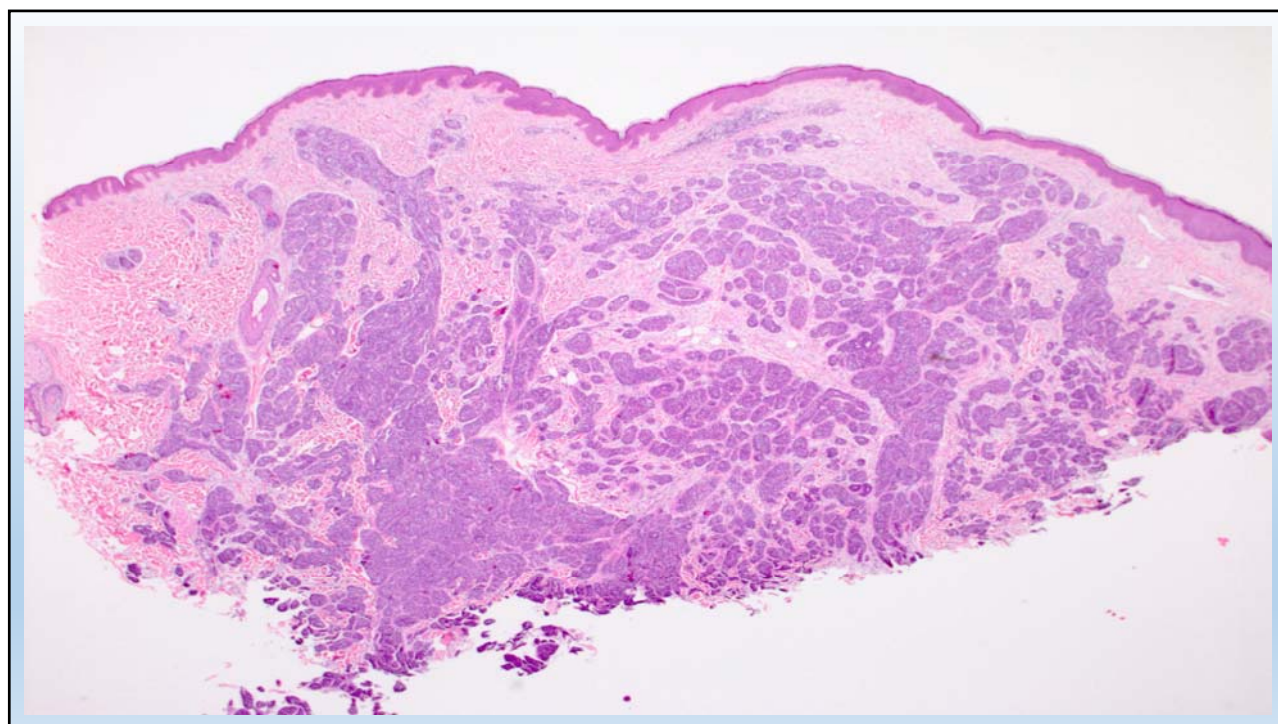
- Sporadic, solitary, nodular, red to tan lesion
- Most patients in 2nd-4th decade, females>males
- 90% occur in head and neck region
- Multiple lesions associated with Brooke-Spiegler syndrome (AD)
 - CYLD1 gene on chromosome 16q12-13

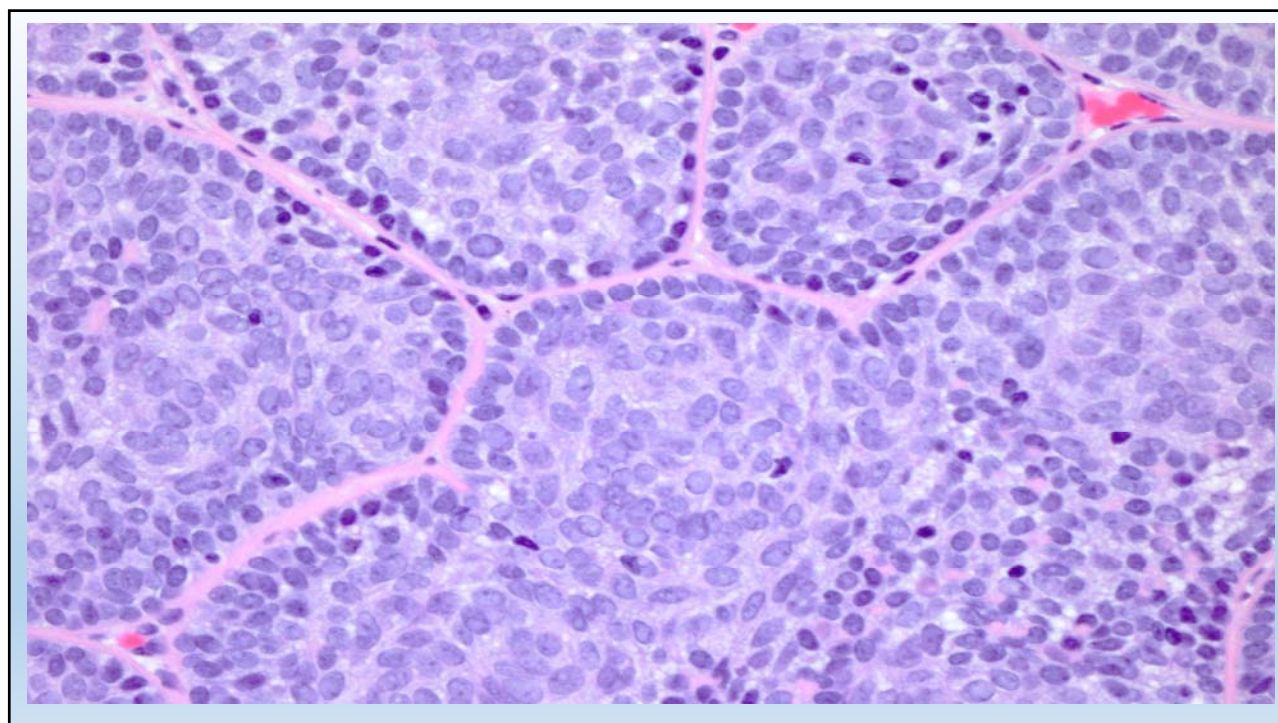
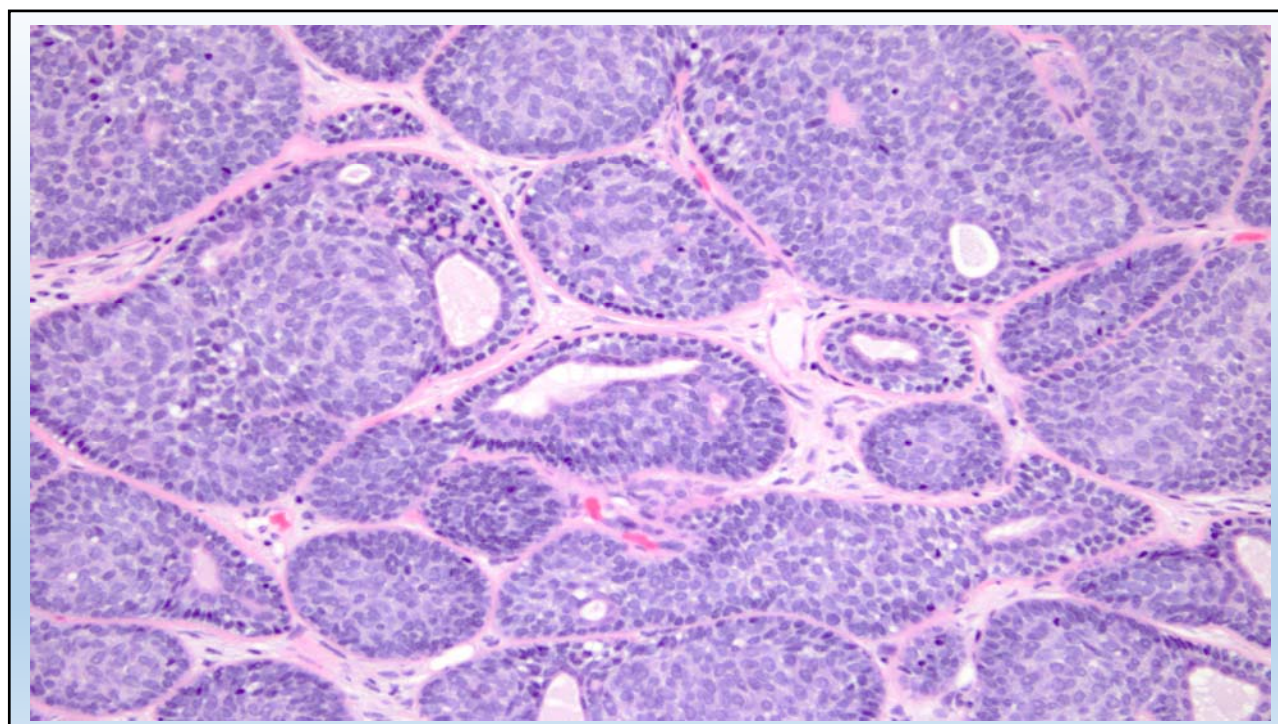


Cylindroma

- **Histologic features:**

- Well-defined, non-encapsulated islands and nodules of epithelial cells
 - "Jigsaw puzzle"
- Individual islands surrounded by thick PAS positive BM material
- Two cell types present
- Ducts are generally identified
- DDx: Spiradenoma, BCC

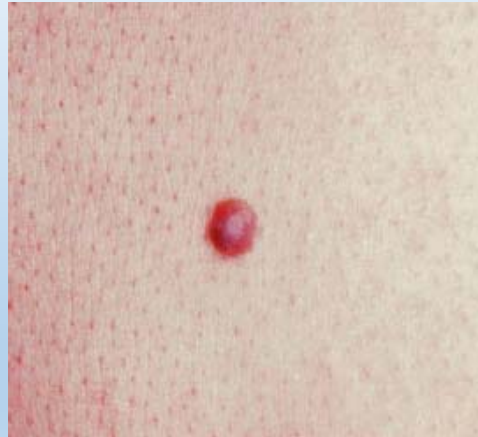



Spiradenoma

- **Clinical:**

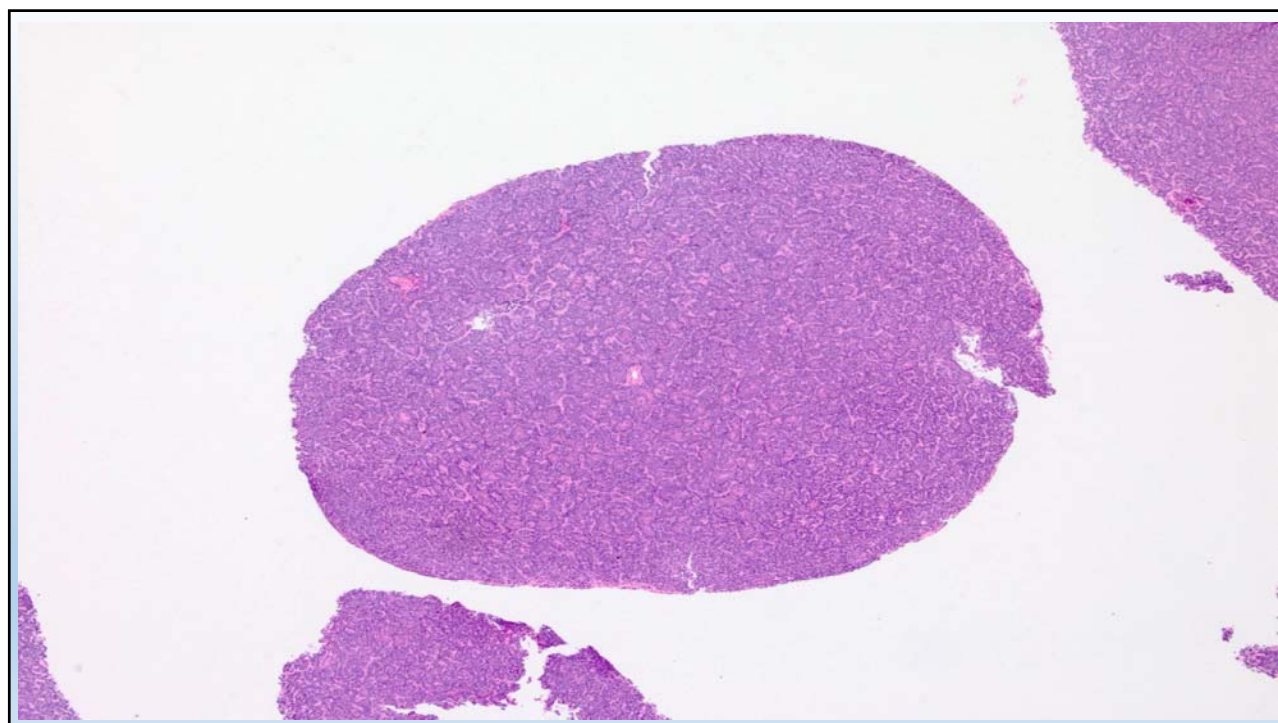
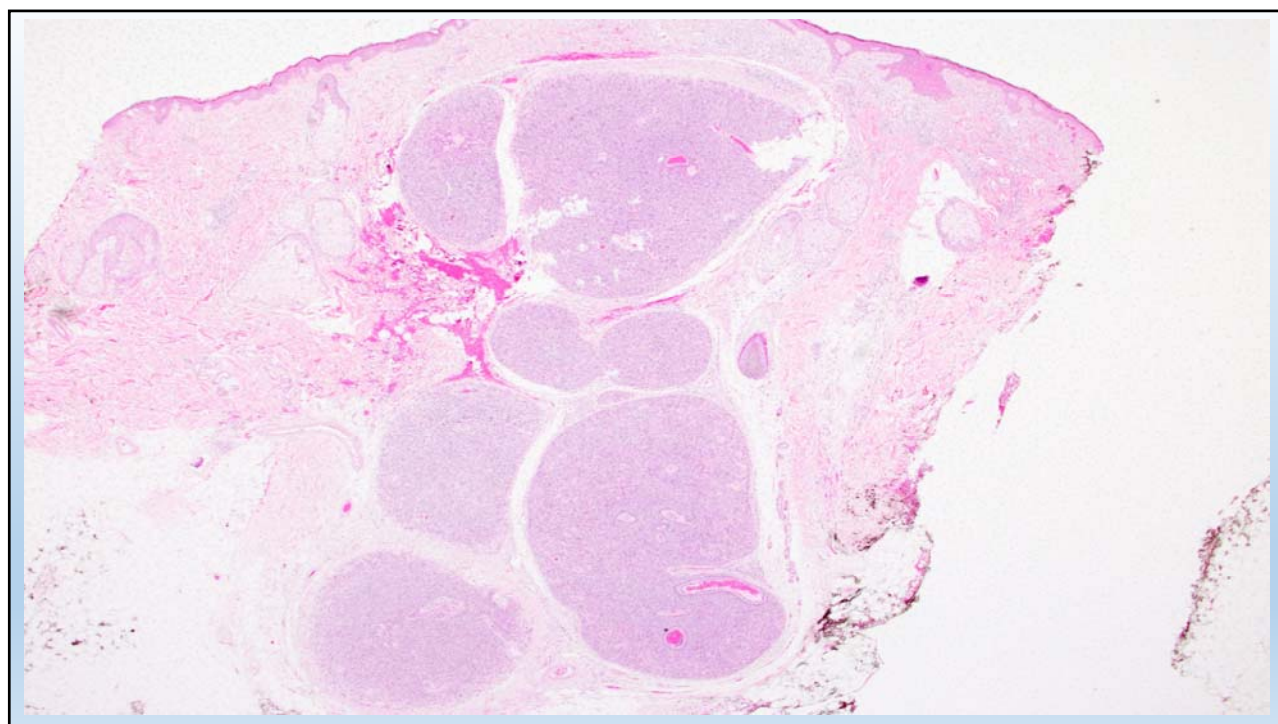
- Solitary, painful nodule
- Most patients in 2nd to 4th decade
- Most tumors measure 0.3-5.0 cm in diameter
- Trunk and upper extremities
- Associated with Brooke-Spiegler syndrome (AD)

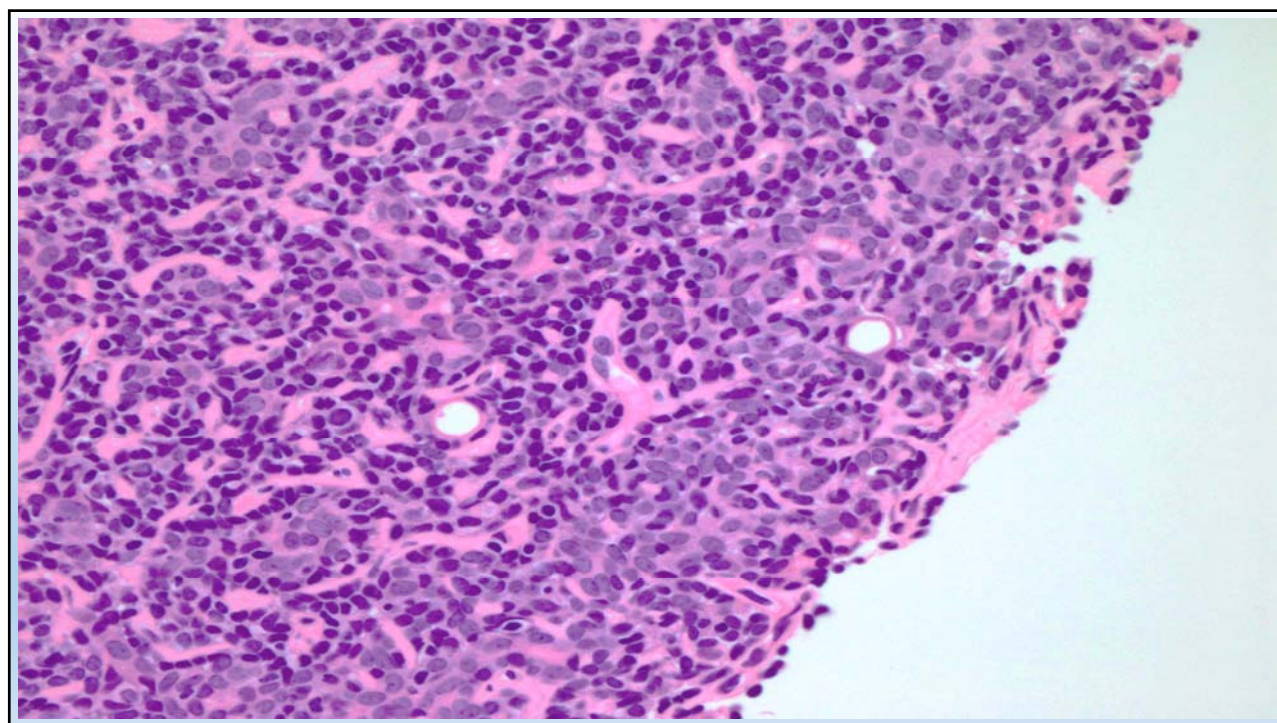
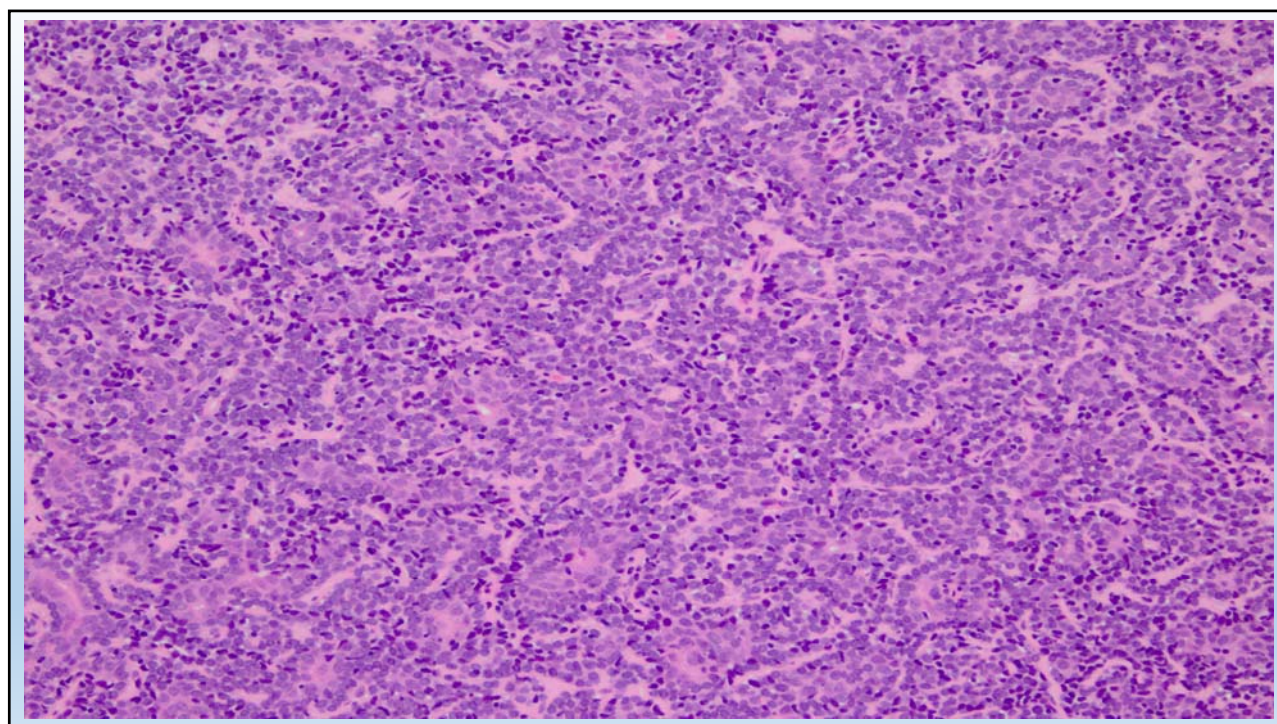


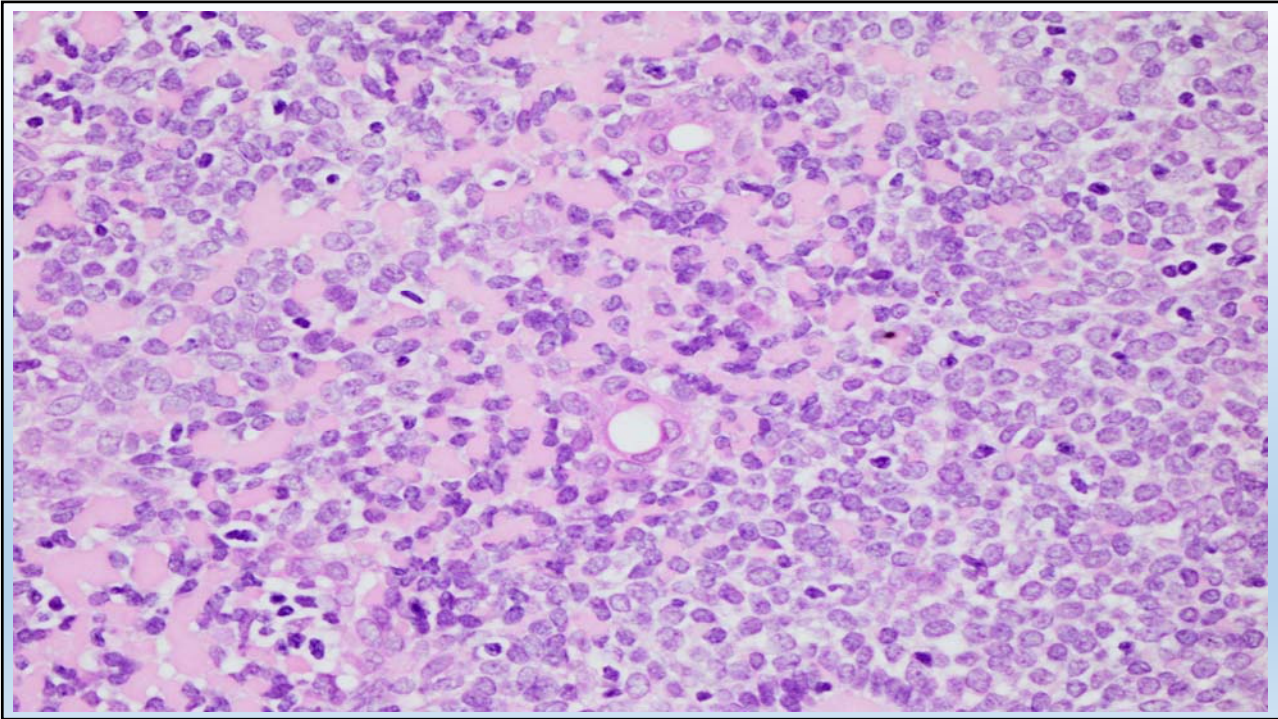
Spiradenoma

- **Histologic features:**

- Usually encapsulated, well-circumscribed, nodular tumor in dermis and SQ
- Nodules are solid
 - Two populations of cells
- Stroma is richly vascular
- Lymphocytes scattered in the background
- PAS positive deposits of BM material throughout tumor
- DDx: Cylindroma, glomus tumor, and BCC

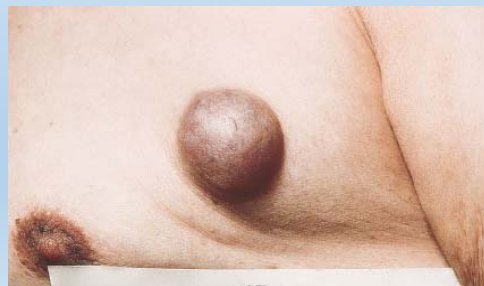
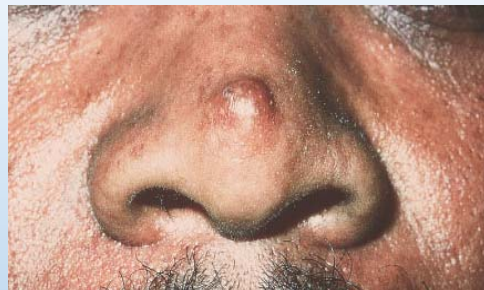




Cutaneous mixed tumor

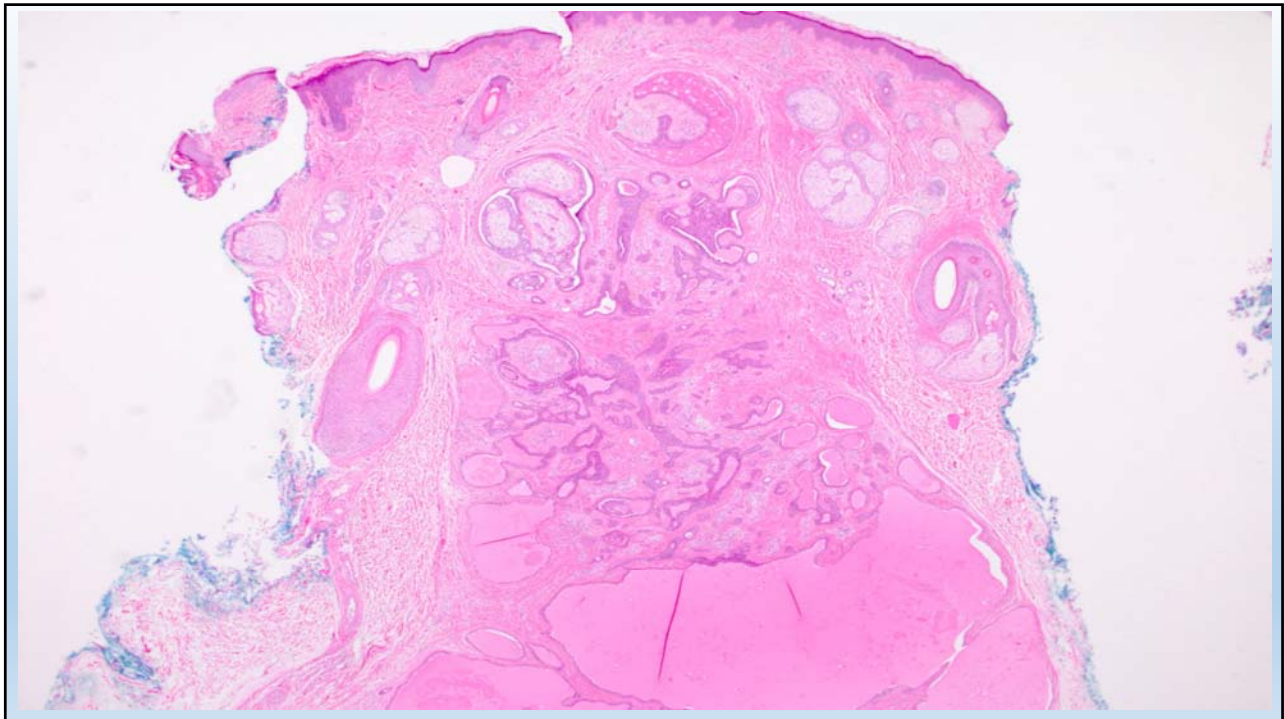
- Clinical:
 - Slow growing, painless, firm nodule
 - Middle-aged and elderly
 - Males > females
 - Commonly occur on the head and neck

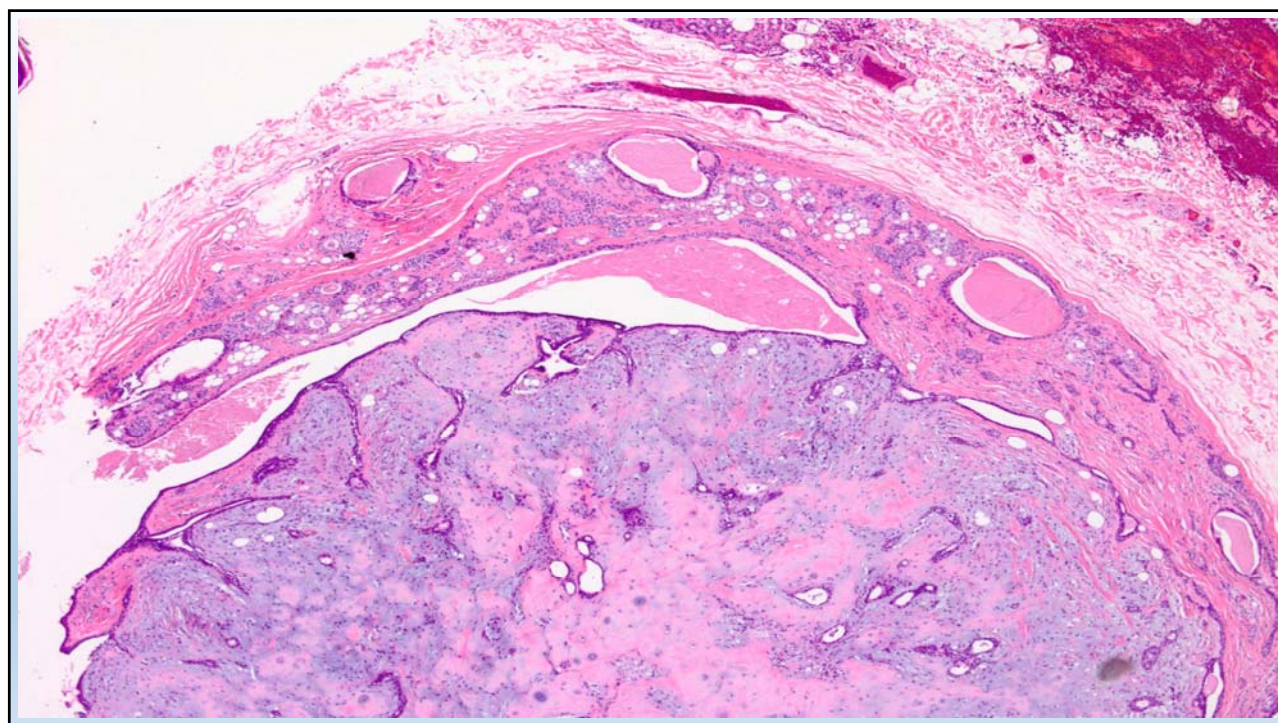
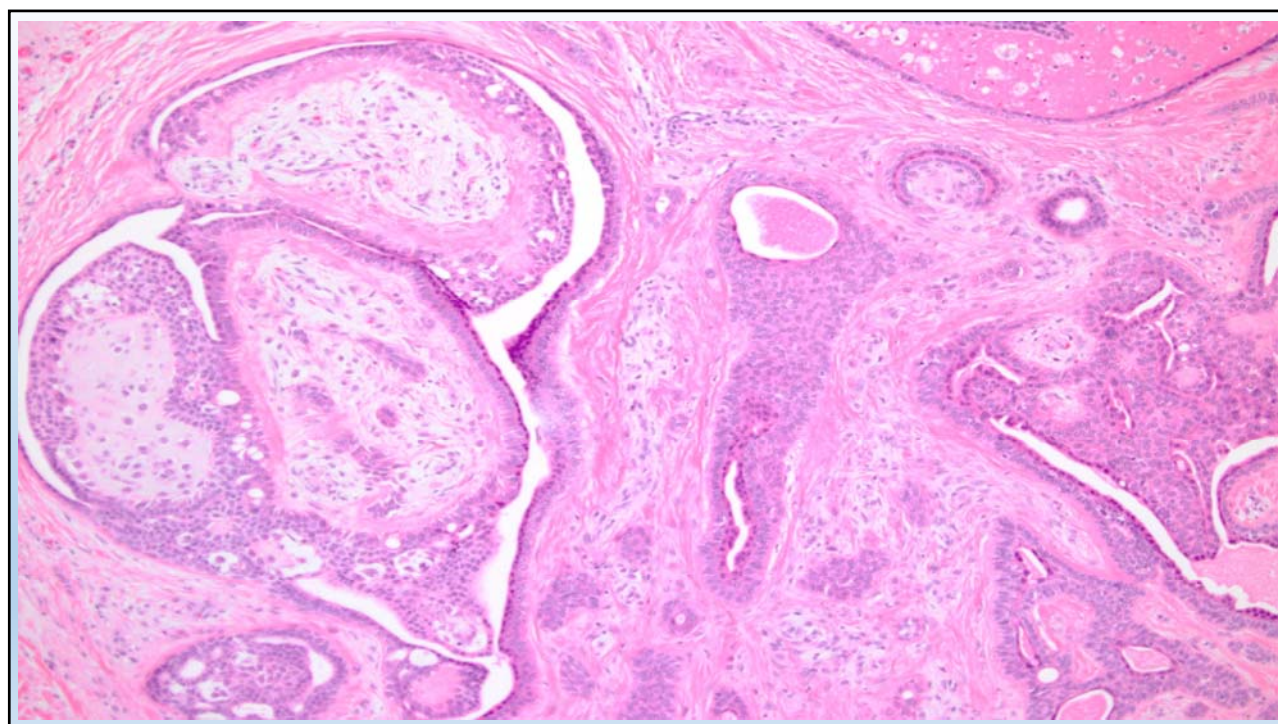


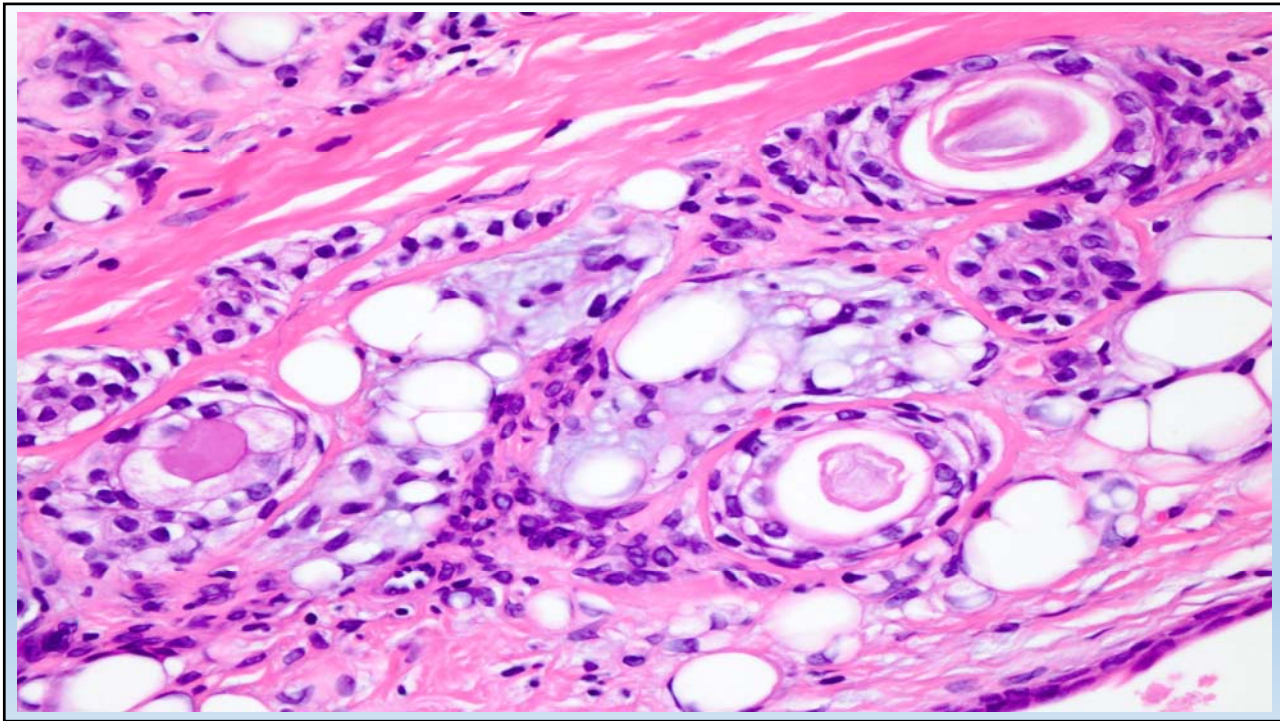
Cutaneous mixed tumor

- **Histologic features:**

- Circumscribed, multi-nodular, dermal based neoplasm
- Epithelial and mesenchymal components
 - Bland epithelial cells arranged in cords, ducts, and tubules
 - Stromal component is most often myxoid-cartilaginous, fibrous, fatty, or osteoid
- May see sebaceous differentiation and abortive hair matrix formation



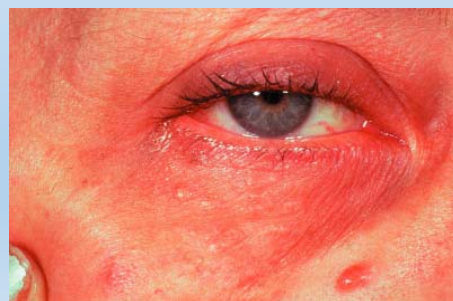
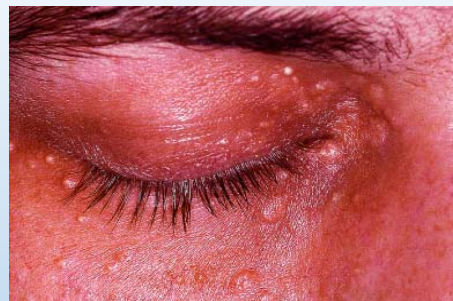


Syringoma

- **Clinical:**

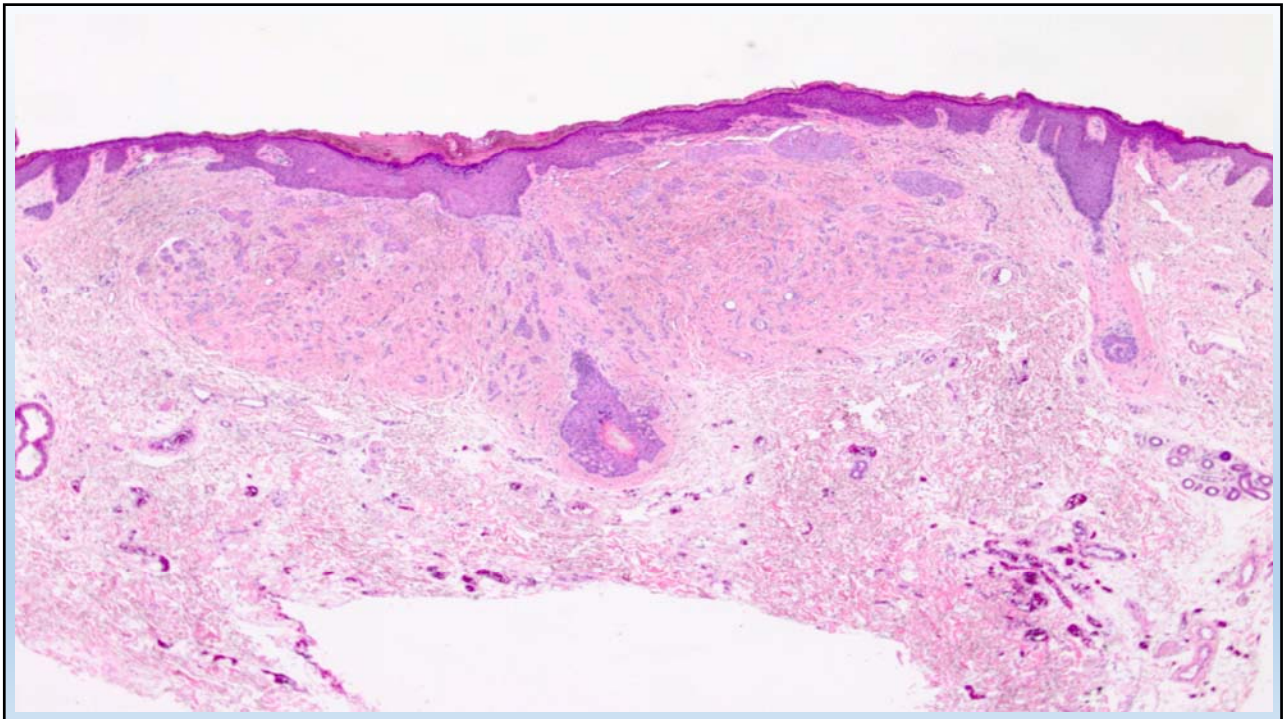
- Present often as multiple, symmetrically distributed, small papules on eyelids and cheeks, 1-4 mm in diameter
- Appear in puberty or in early adult life, females > males
- Variant—eruptive syringoma
 - Successive crops of papules appear on the anterior surfaces of young people
 - Down's syndrome

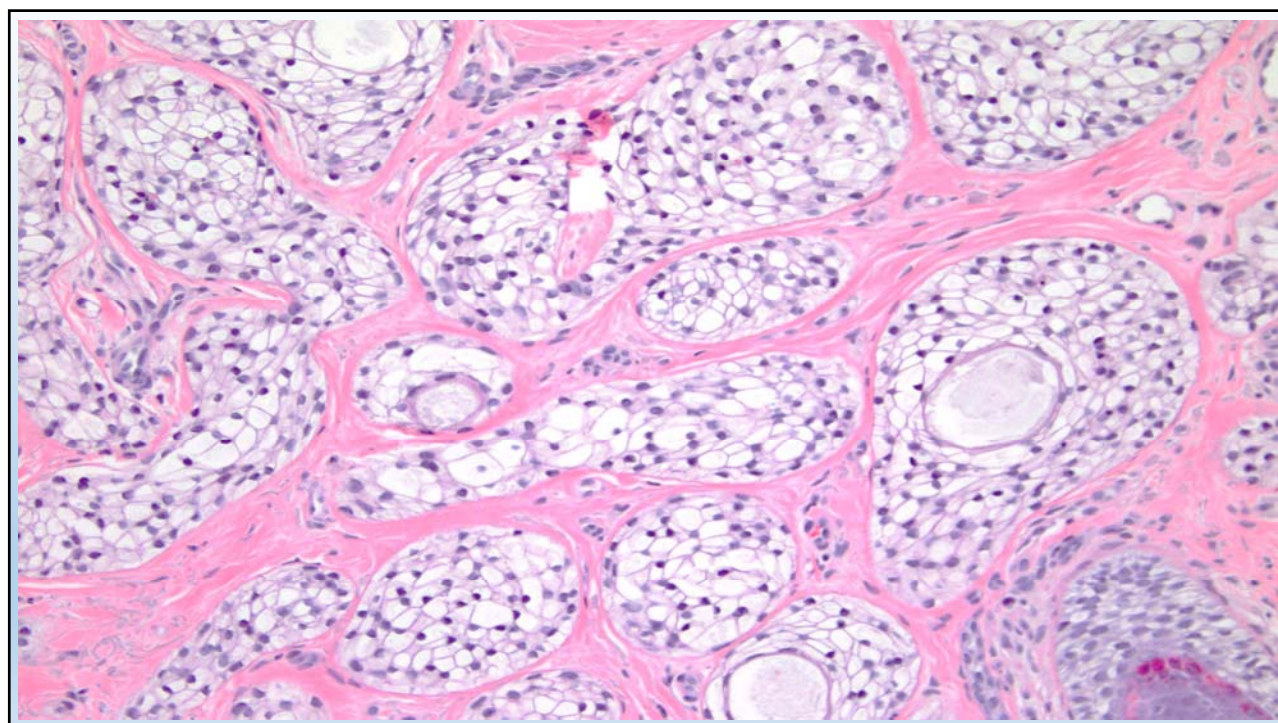
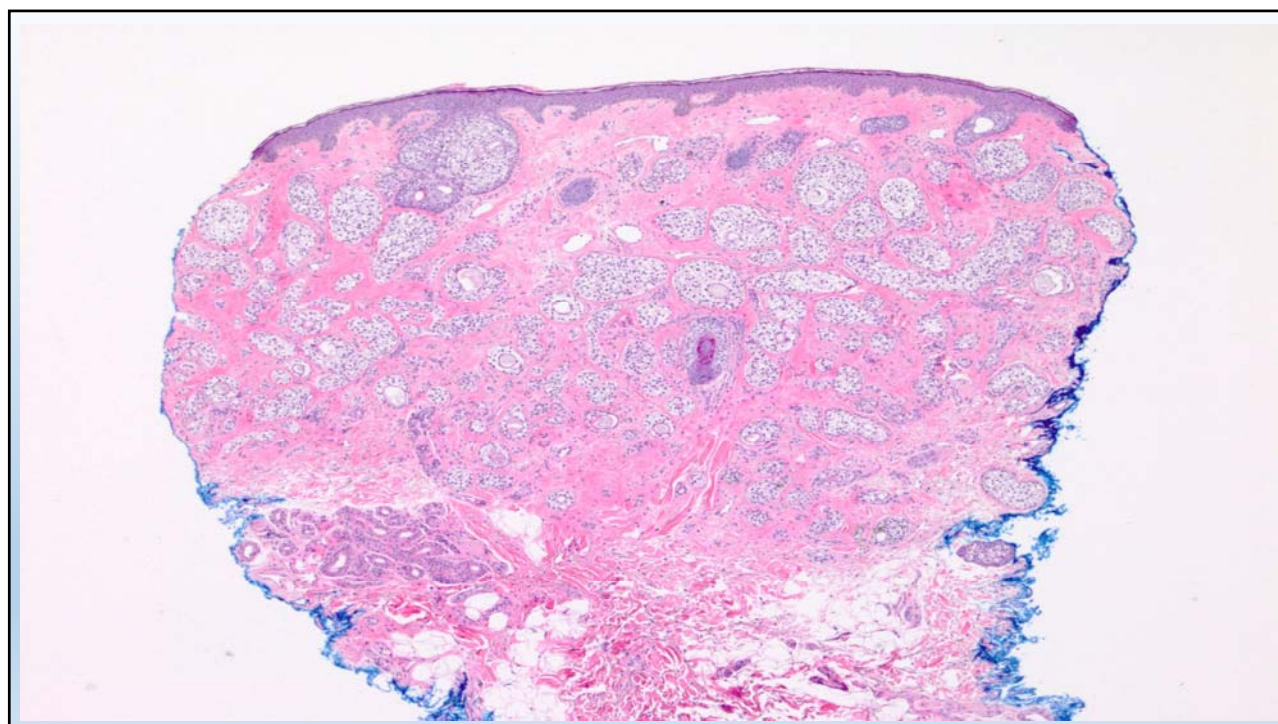


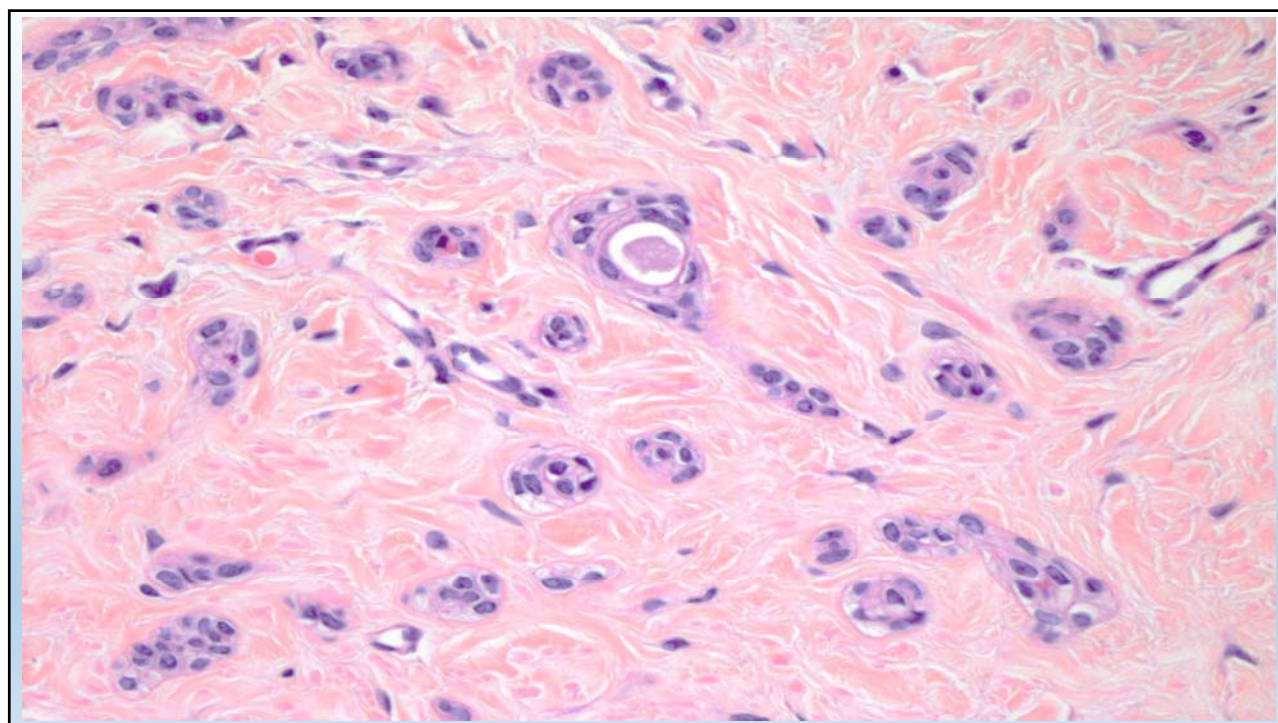
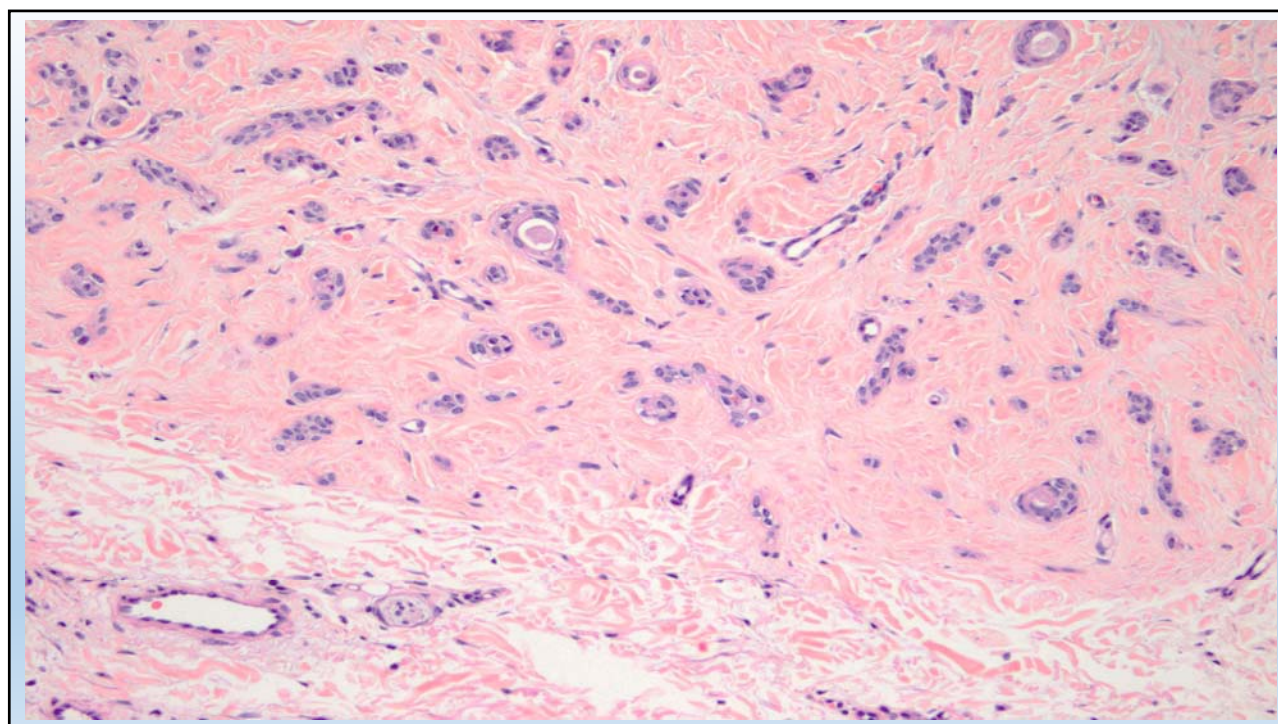
Syringoma

- **Histologic features:**

- Symmetric, well-circumscribed
- Confined to upper dermis
- No connection to the overlying epidermis
- Epithelial cells arranged in nests, cords, and ducts lined by two layers of cells
- Fibrous stroma
- DDx: Desmoplastic trichoepithelioma and microcystic adnexal carcinoma



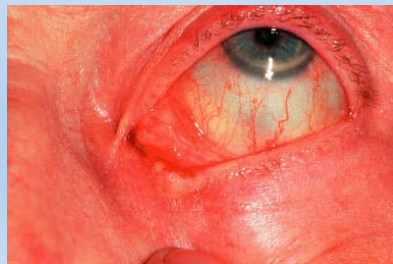
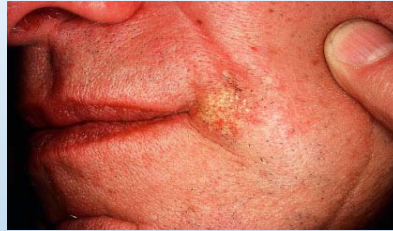


Microcystic adnexal carcinoma (MAC)

- **Clinical:**

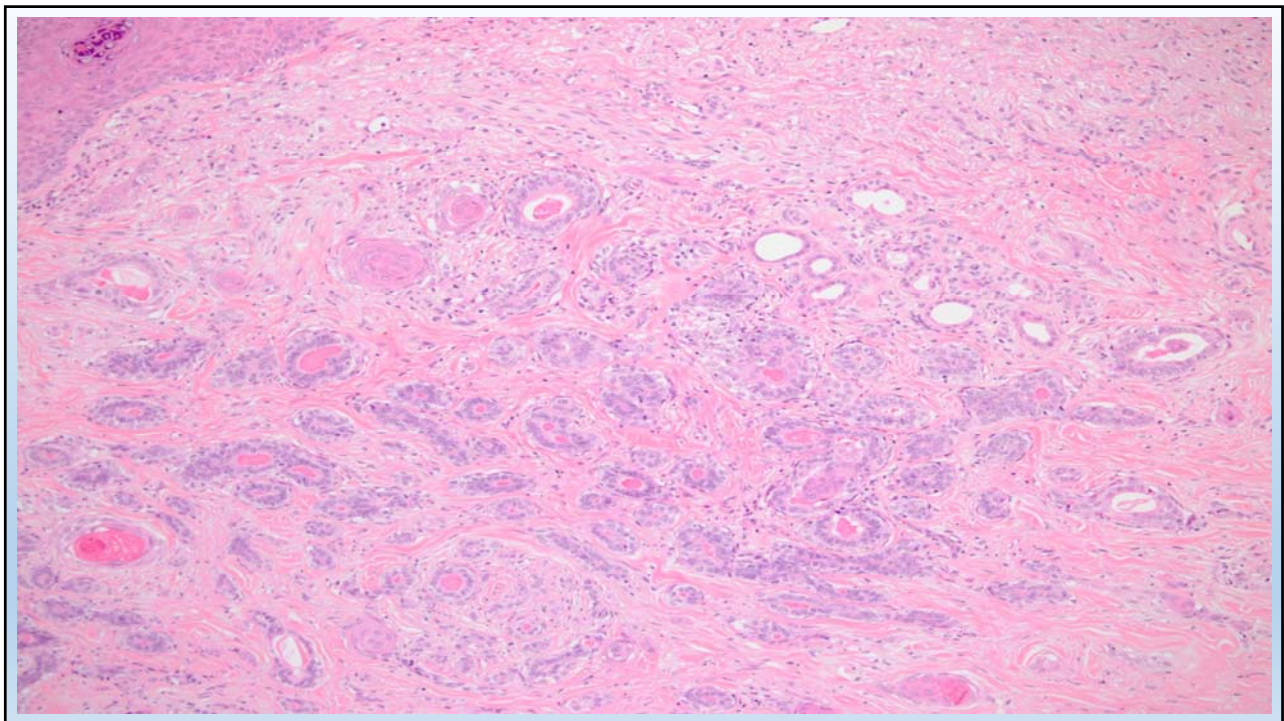
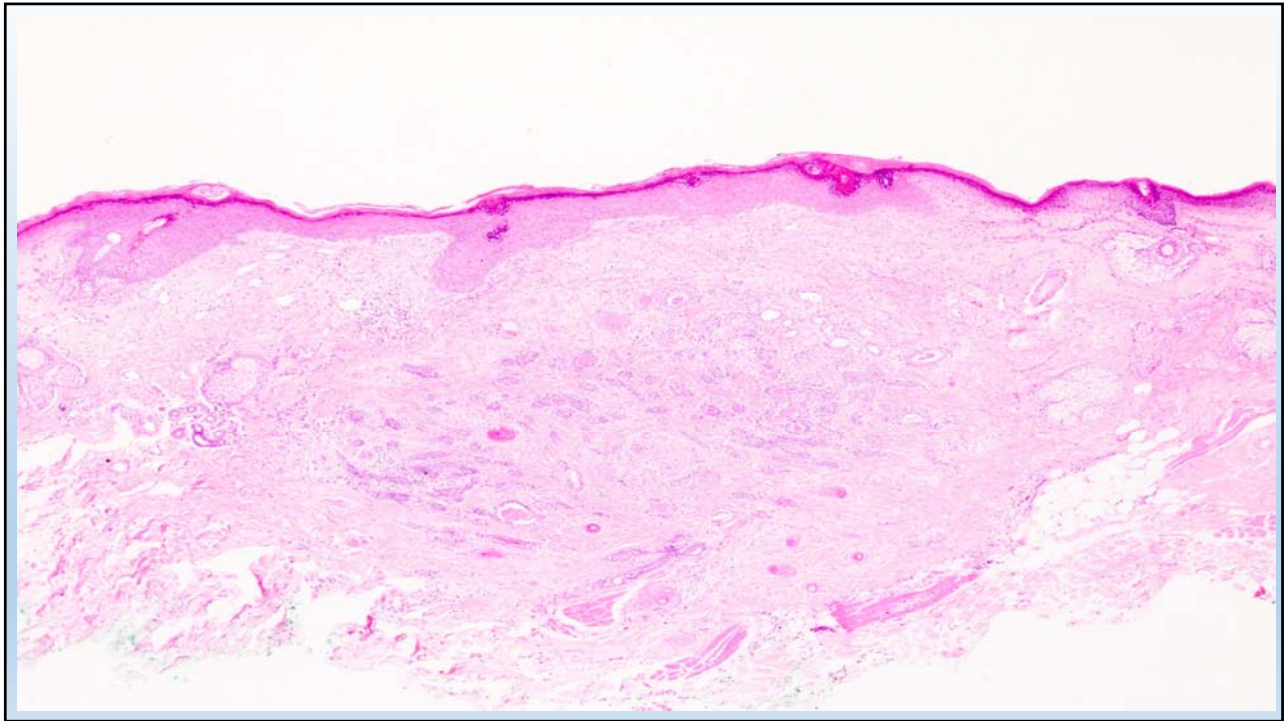
- Solitary, indurated, slow-growing, ill-defined plaque
- Middle-aged adults, women>men
- Occur on the face with a predilection for the upper and lower lip
- Risk factors—previous radiation therapy and immunosuppression
- Rate of local recurrence approaches 50%, metastasis is very rare

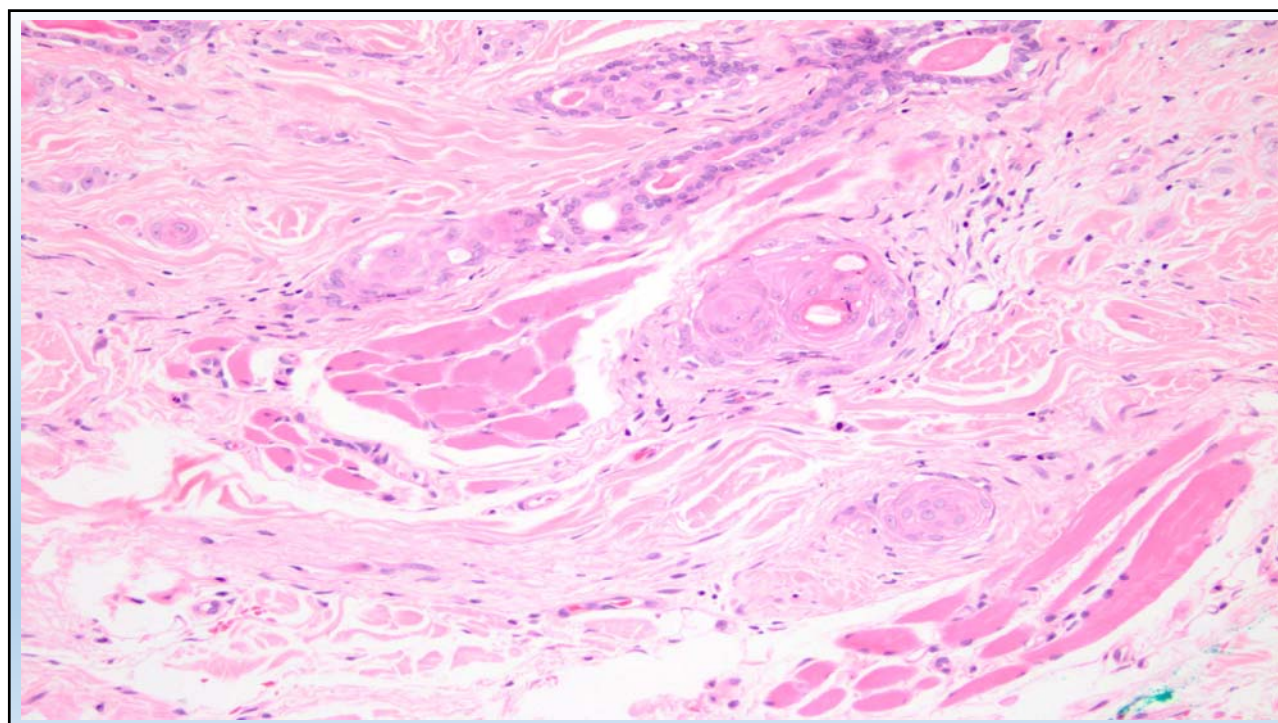
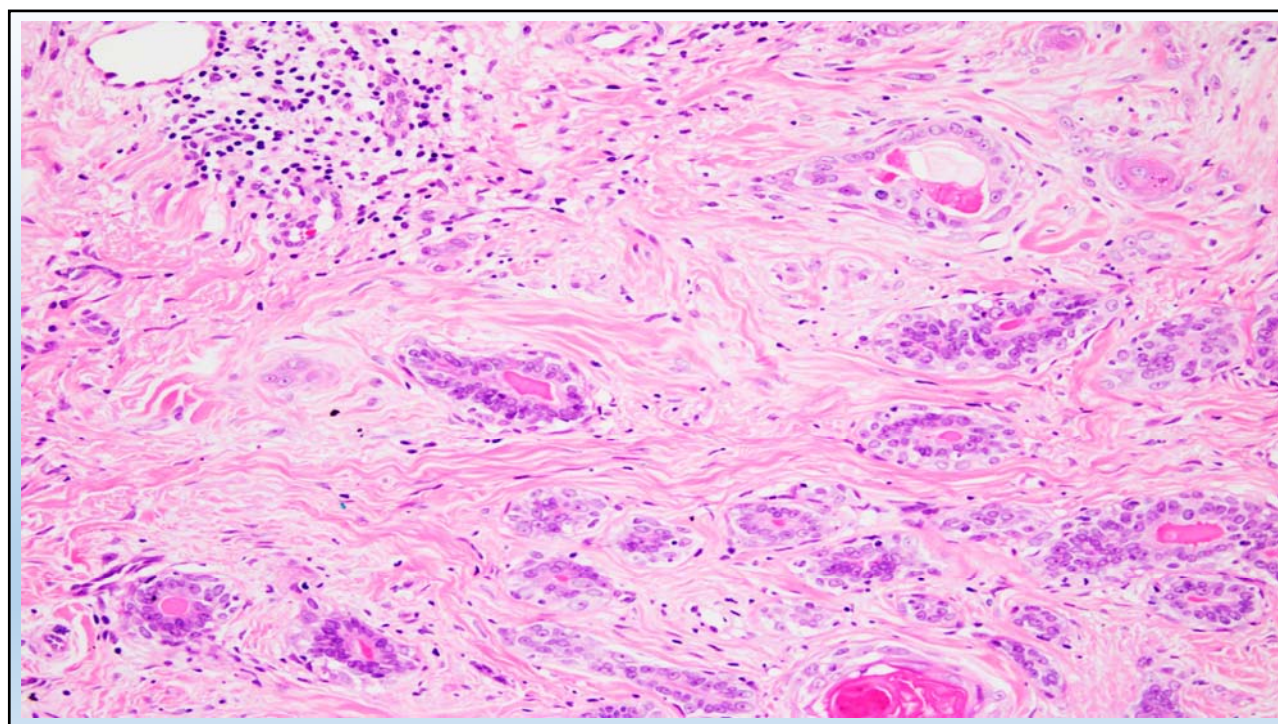


Microcystic adnexal carcinoma

- **Histologic features:**

- Poorly circumscribed proliferation of bland epithelial cells arranged in rounded or syringoid profiles
- Keratin-filled microcysts are often present in superficial dermis
- Infiltrates throughout dermis and subcutis
- Dense, often hyalinized stroma
- Peri-neural invasion
- DDx: Syringoma, desmoplastic trichoepithelioma, and morpheaform BCC

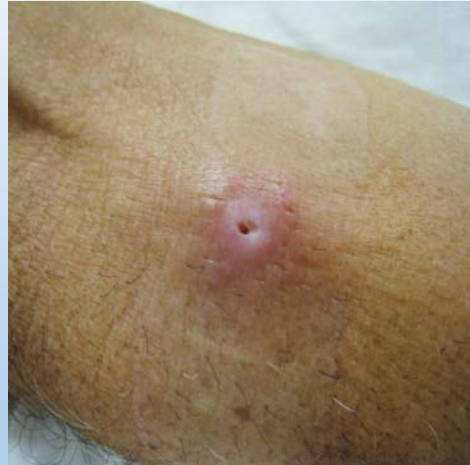



Trichofolliculoma

- **Clinical:**

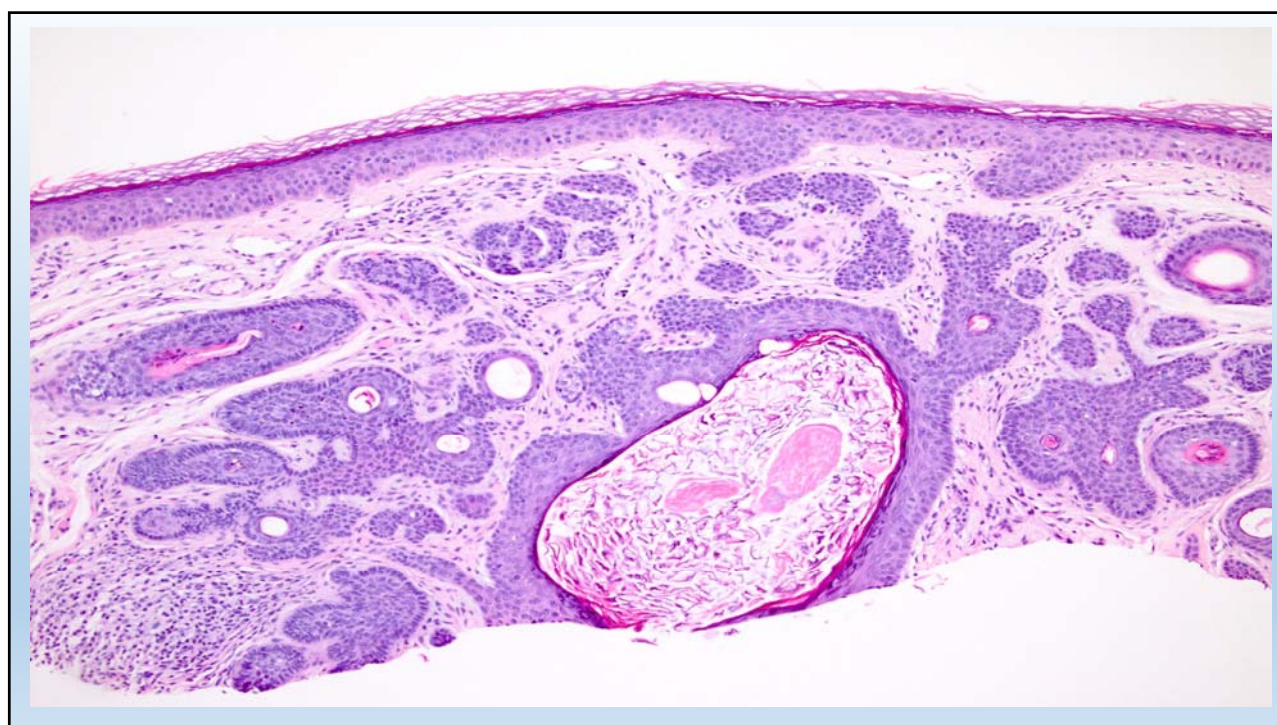
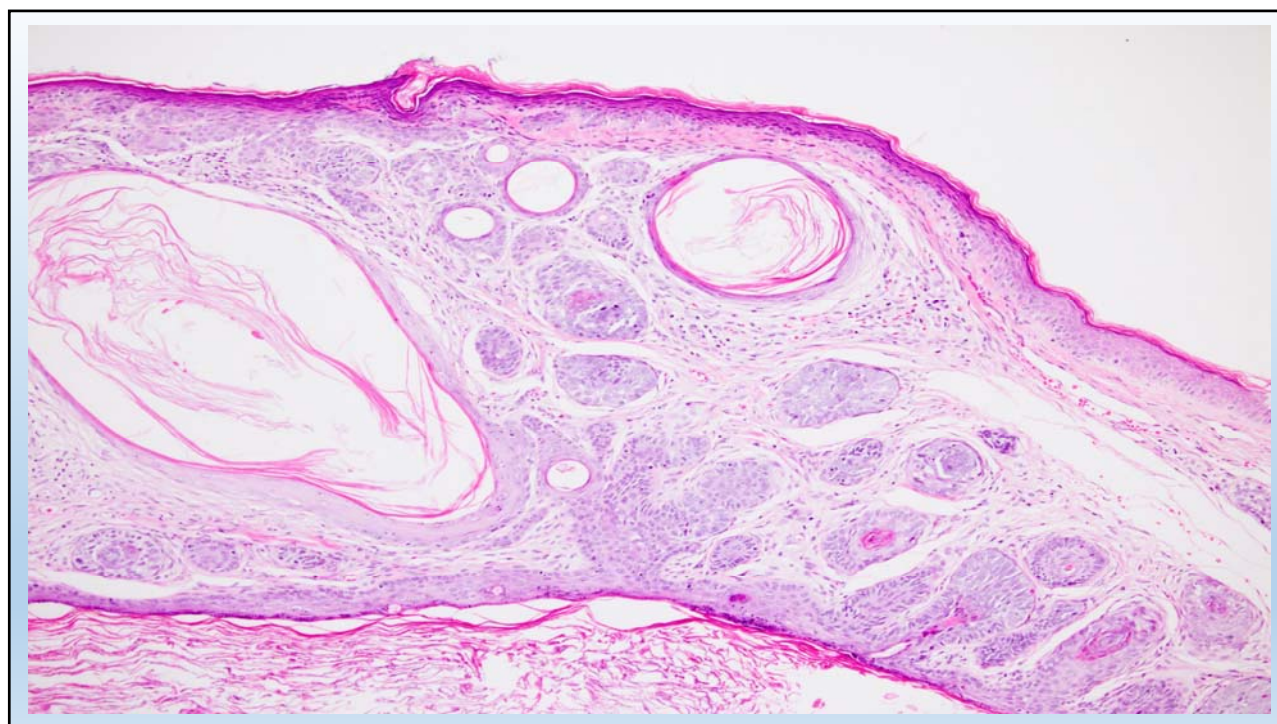
- Commonly arises on the face
- Single, dome-shaped papule, 0.5-1.0 cm in diameter
- Often with a central pore
 - May see hair growing out of the pore
- Middle aged to older patients

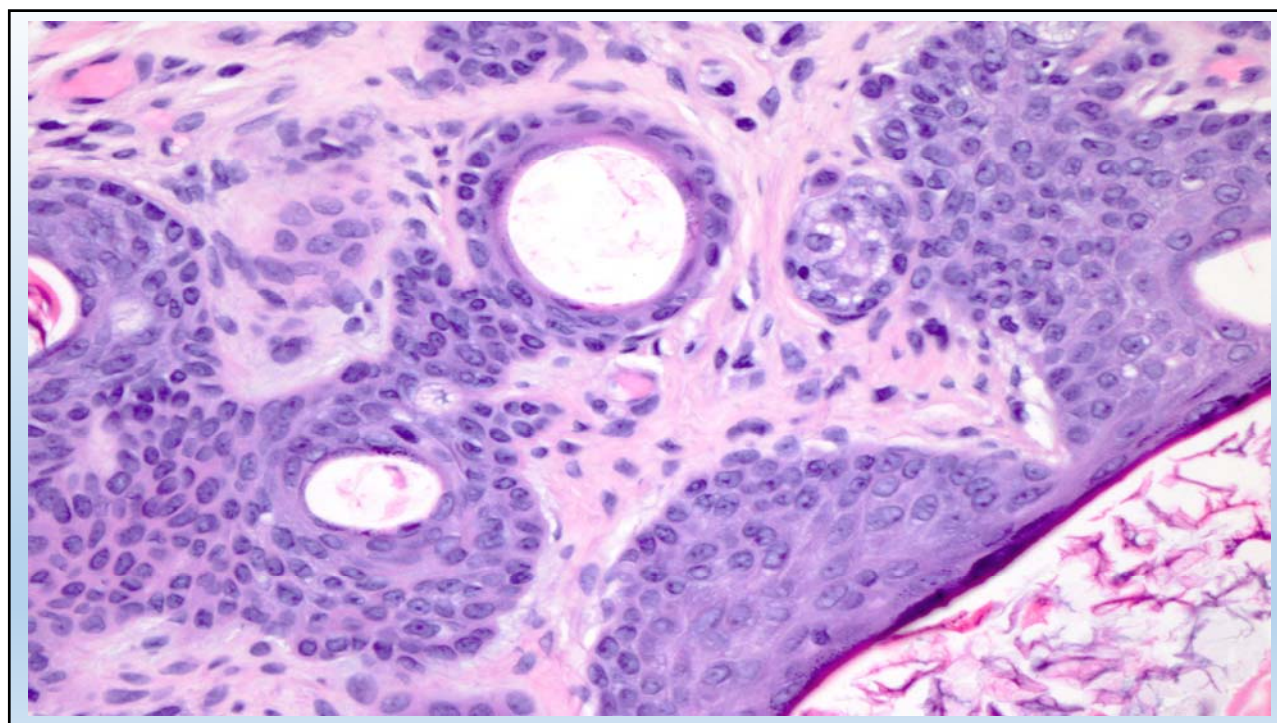
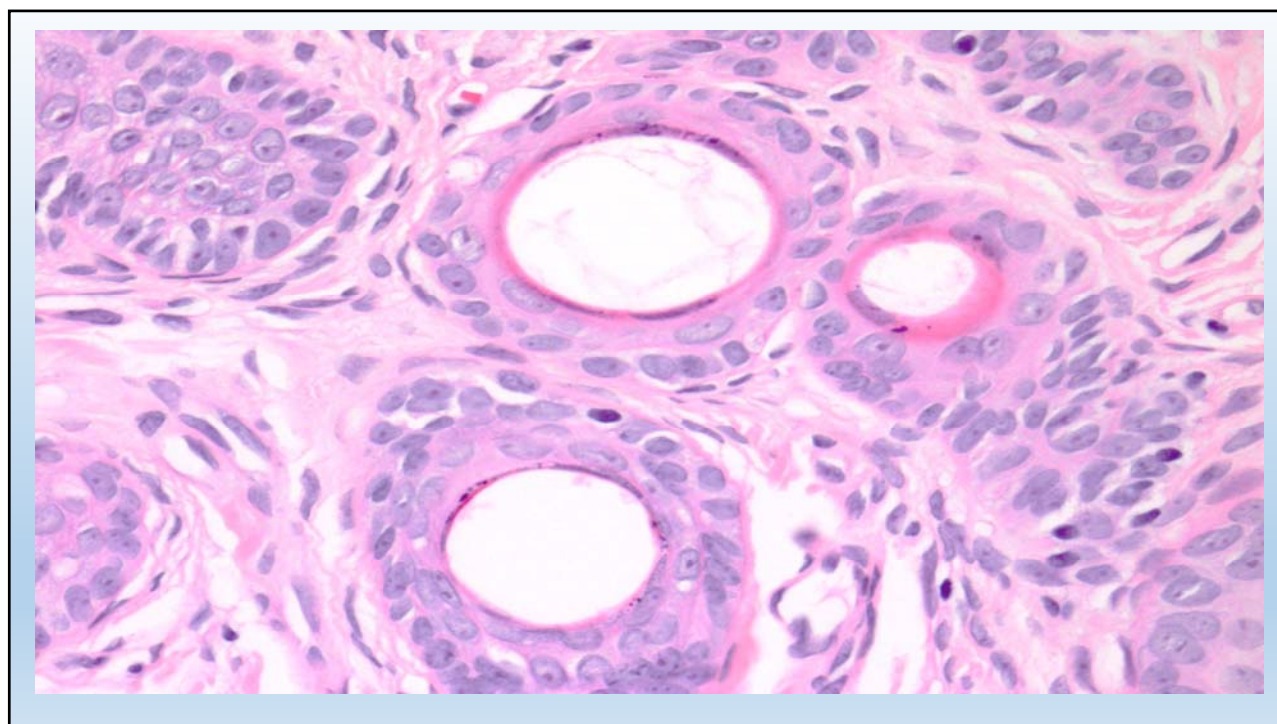


Trichofolliculoma

- **Histologic features:**

- Dilated hair follicle containing keratin debris and hair shaft fragments
- Numerous small hair follicles arising from the wall of the dilated hair follicle
 - "Parent and babies"
 - Each follicle is surrounded by a clearly defined peri-follicular sheath
- Occasionally may see small sebaceous glands and keratocysts associated with these neoplasms

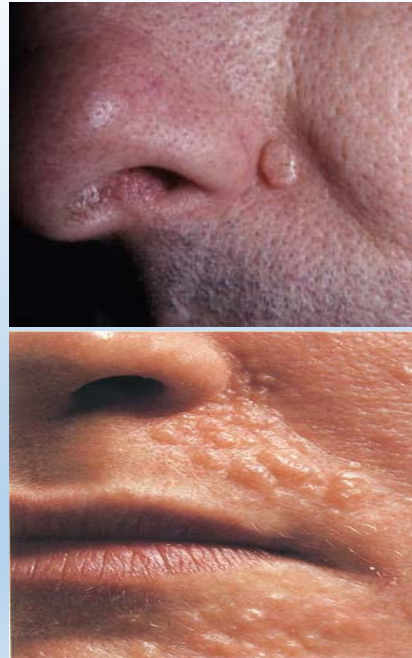



Trichoepithelioma

- **Clinical:**

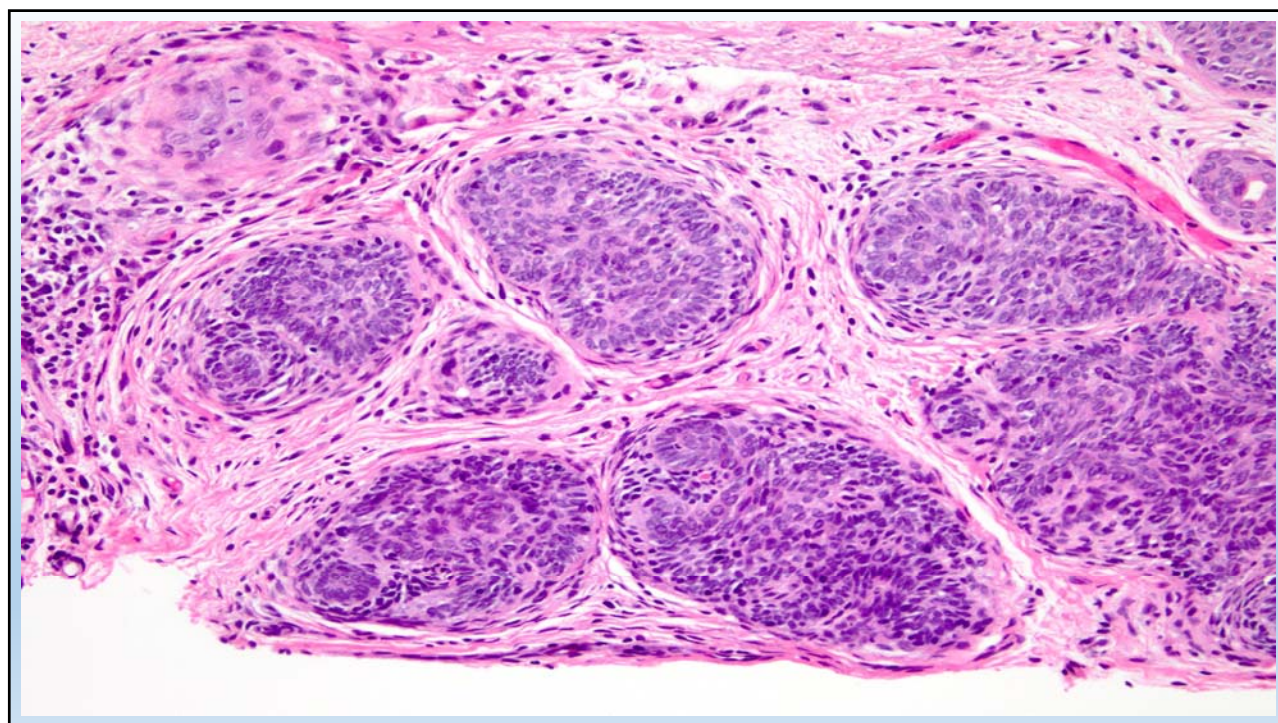
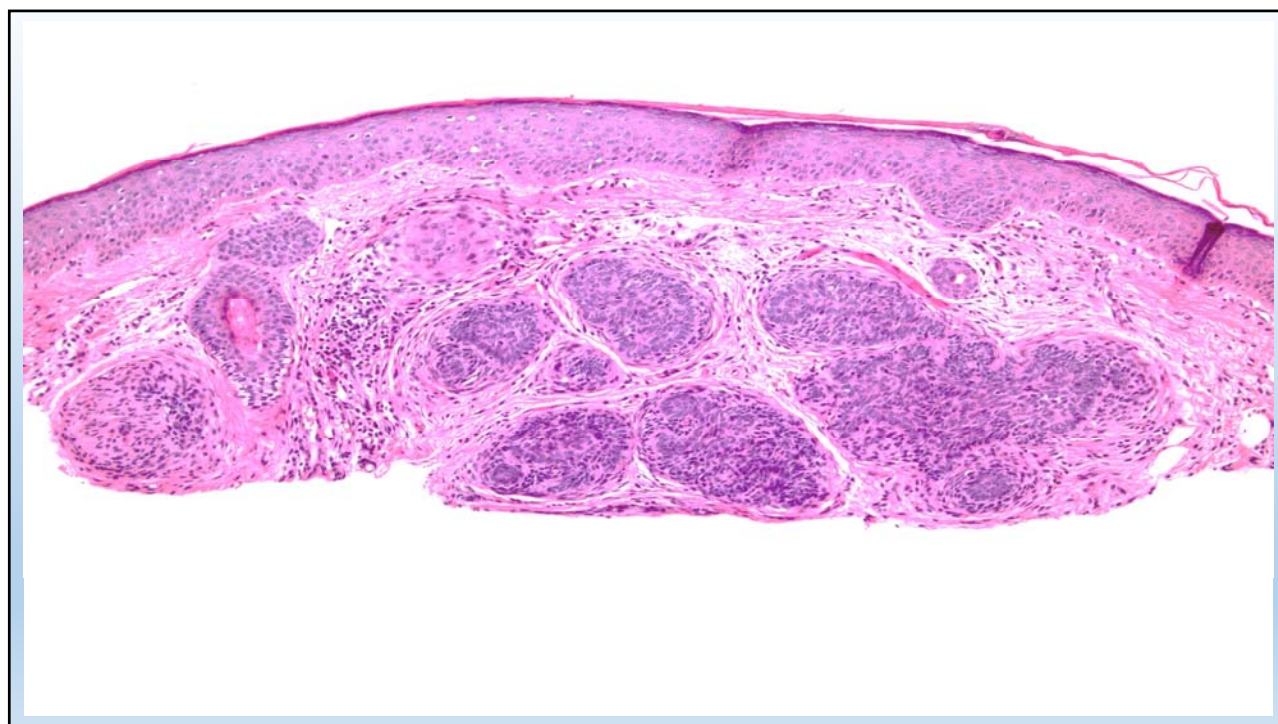
- Skin-colored papule on the face
- Can be solitary and sporadic or multiple and associated with different syndromes
 - Multiple familial trichoepithelioma (AD)
 - Brook-Spiegler Syndrome (AD)
 - Rombo syndrome

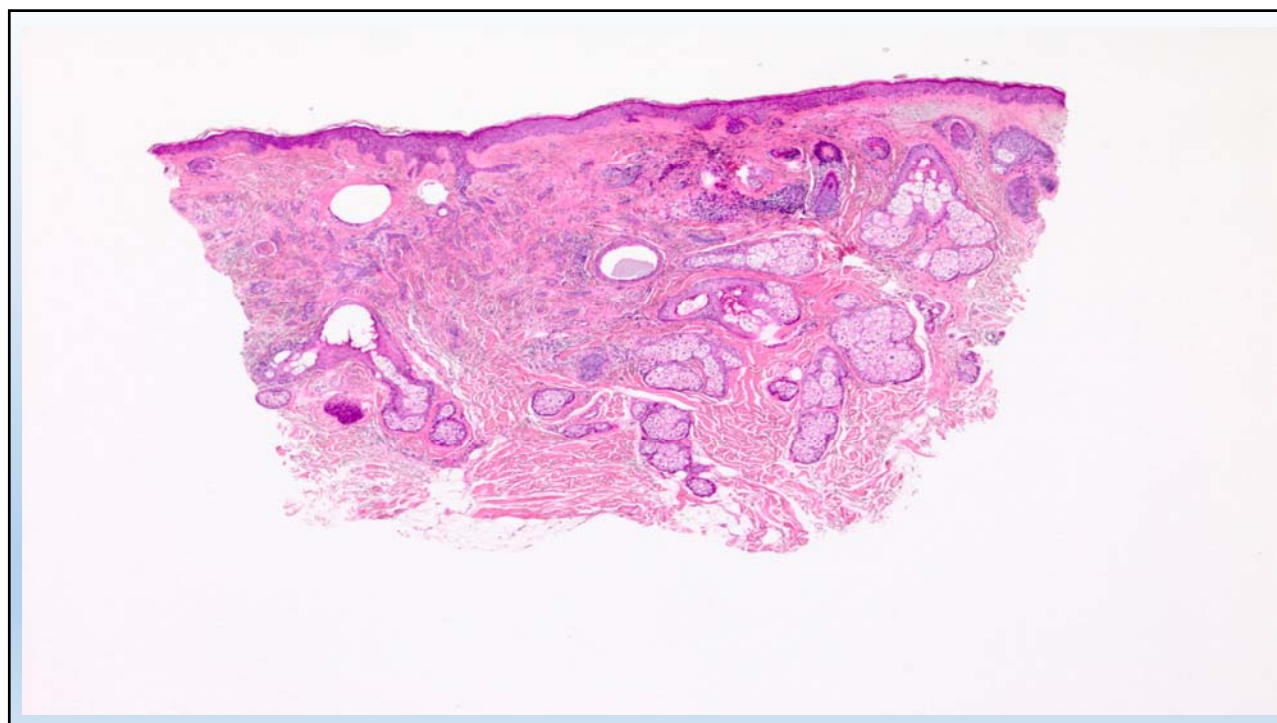
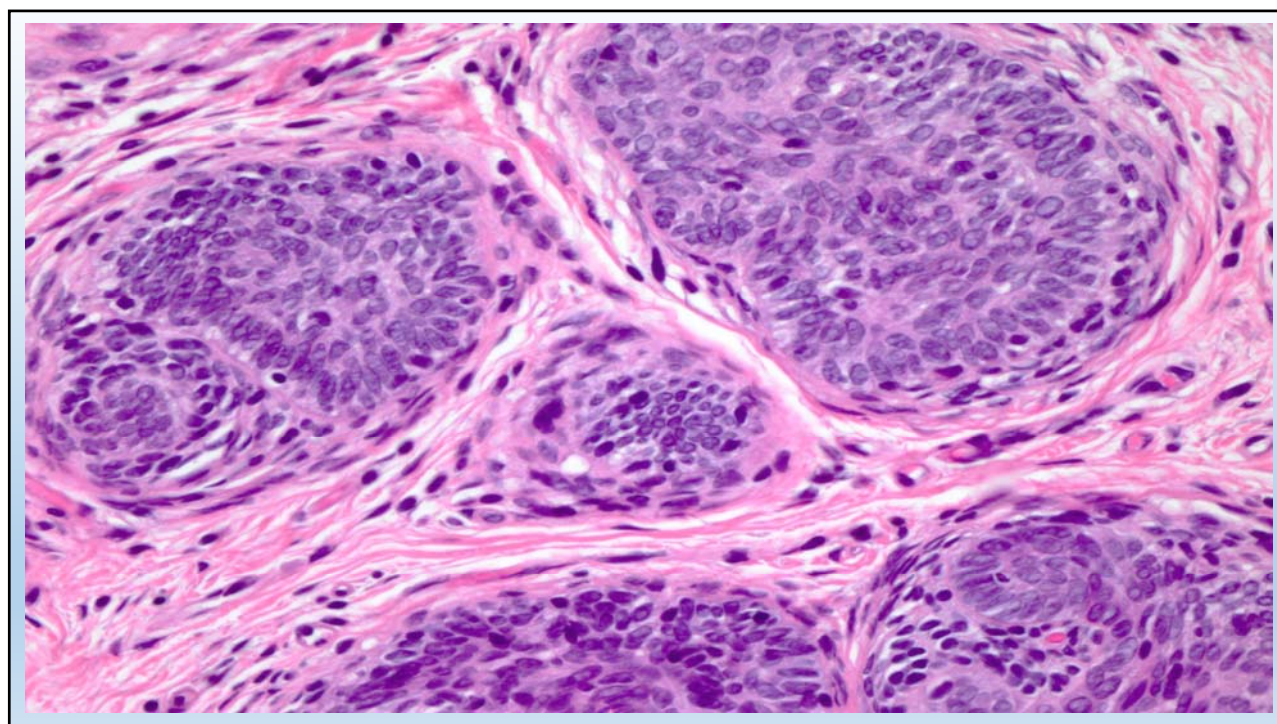


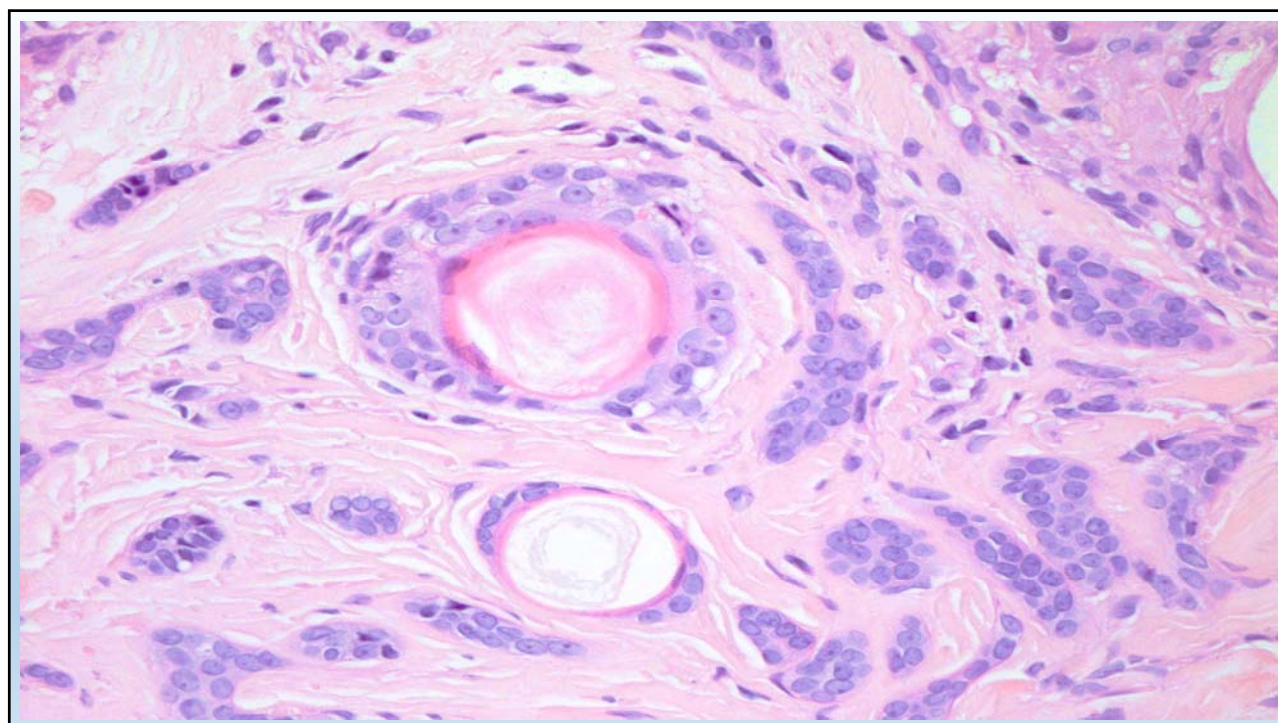
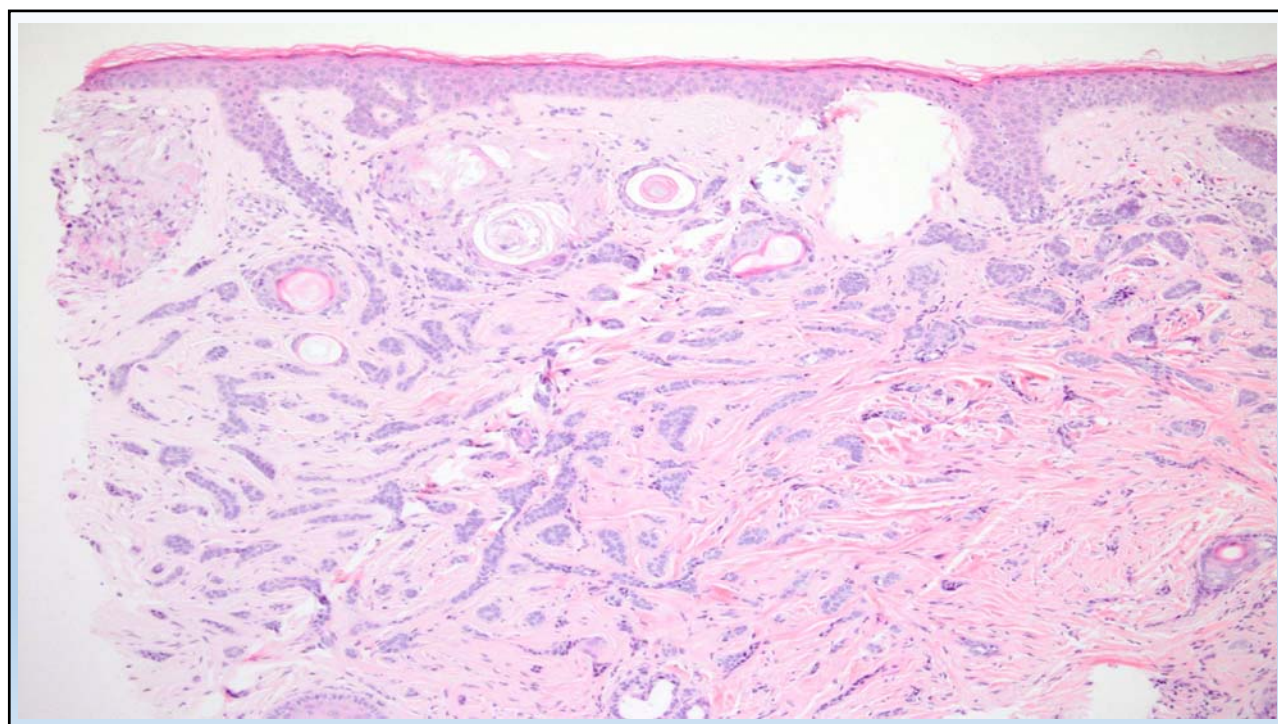
Trichoepithelioma

- **Histologic features:**

- Dermal neoplasm that may show focal attachment to the overlying epidermis
- Basophilic nests of cells surrounded by a dense fibrous stroma
- Stroma to stroma retraction
- May see mucin within the epithelial islands
- Papillary mesenchymal bodies
- Peripheral palisading of nuclei
- Desmoplastic subtype
 - Narrow strands of bland epithelial cells
 - Keratin cysts
 - Desmoplastic stroma
 - No peripheral palisading
 - May see keratin granulomas and calcification
 - Not mitotically active
- DDx: Keratotic/infundibulocystic basal cell carcinoma, syringoma, MAC





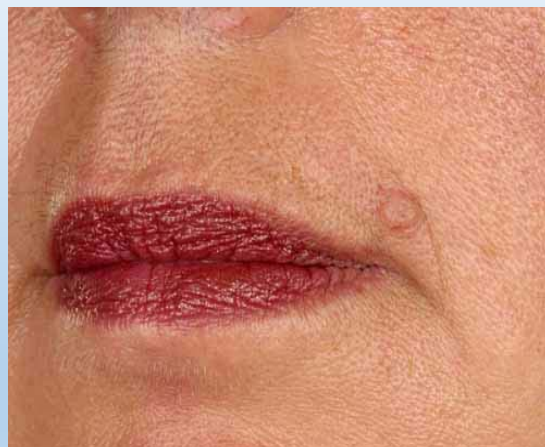

Trichoepithelioma vs. Basal cell carcinoma

	Bcl-2	CD10	Keratin 20	CD34	AR
Trichoepithelioma	+ Peripheral staining of tumor	+ Stromal staining	+	+ Stromal staining	-
Basal cell carcinoma	+ Diffuse staining of tumor	+ Basal layer of epithelium	-	- No stromal staining	+

Trichilemmoma

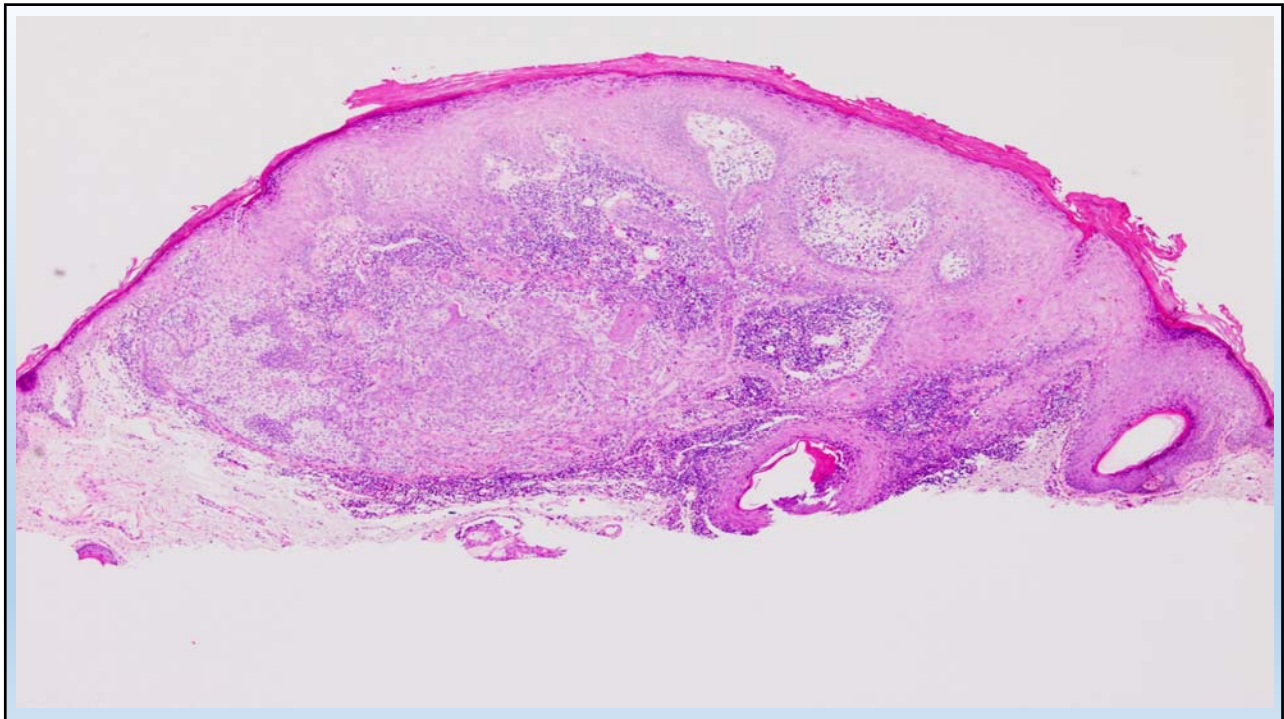
- **Clinical:**
 - Solitary or multiple
 - Small, warty or smooth, skin-colored papule
 - Face of older adults
 - Multiple lesions are associated Cowden's disease

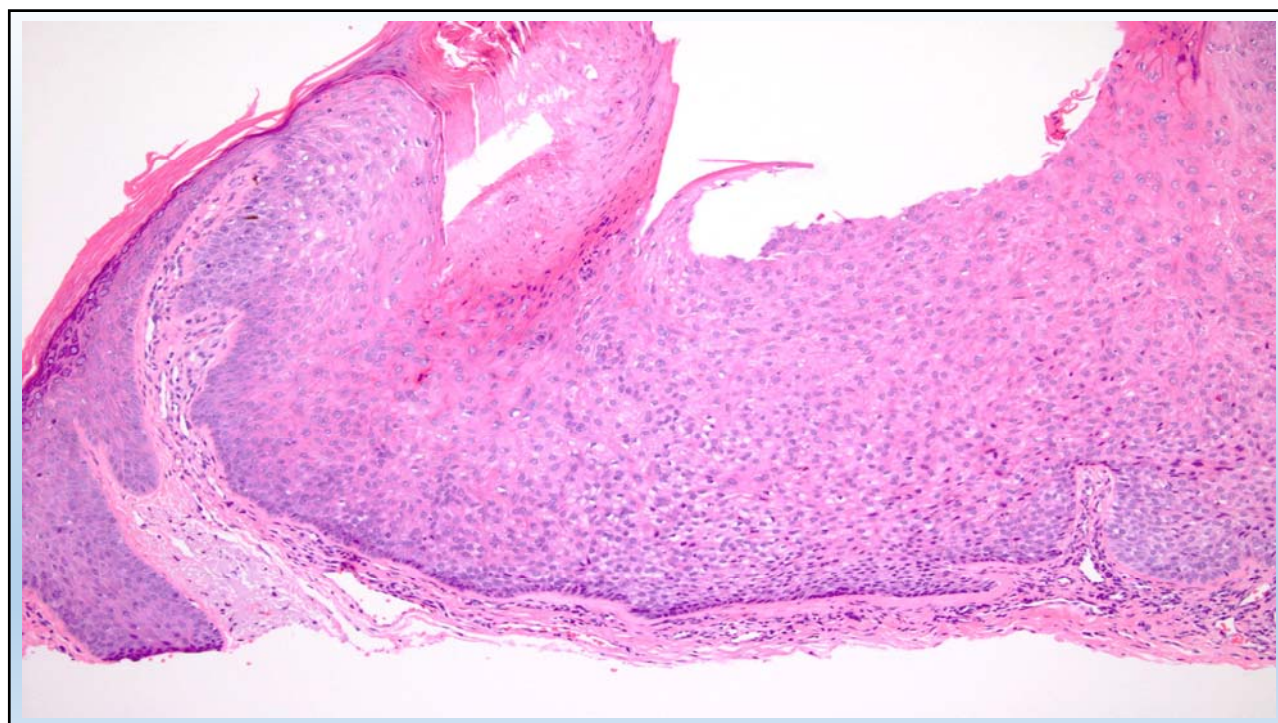
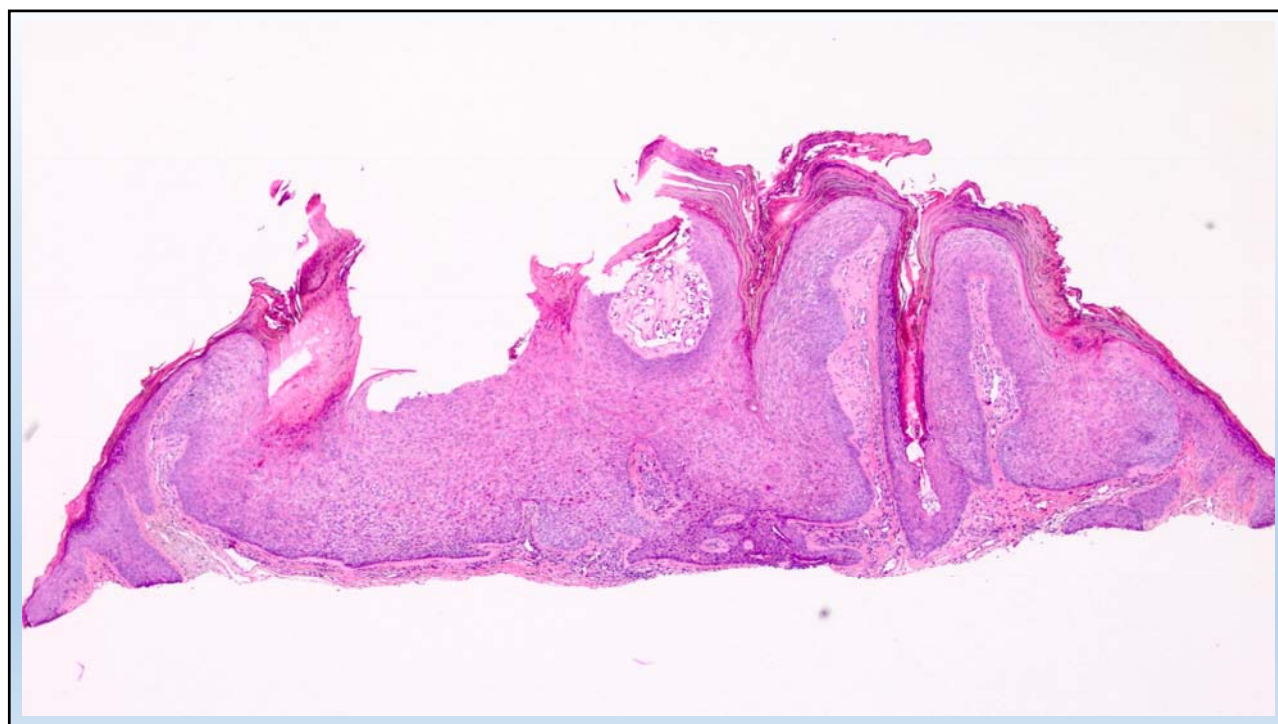


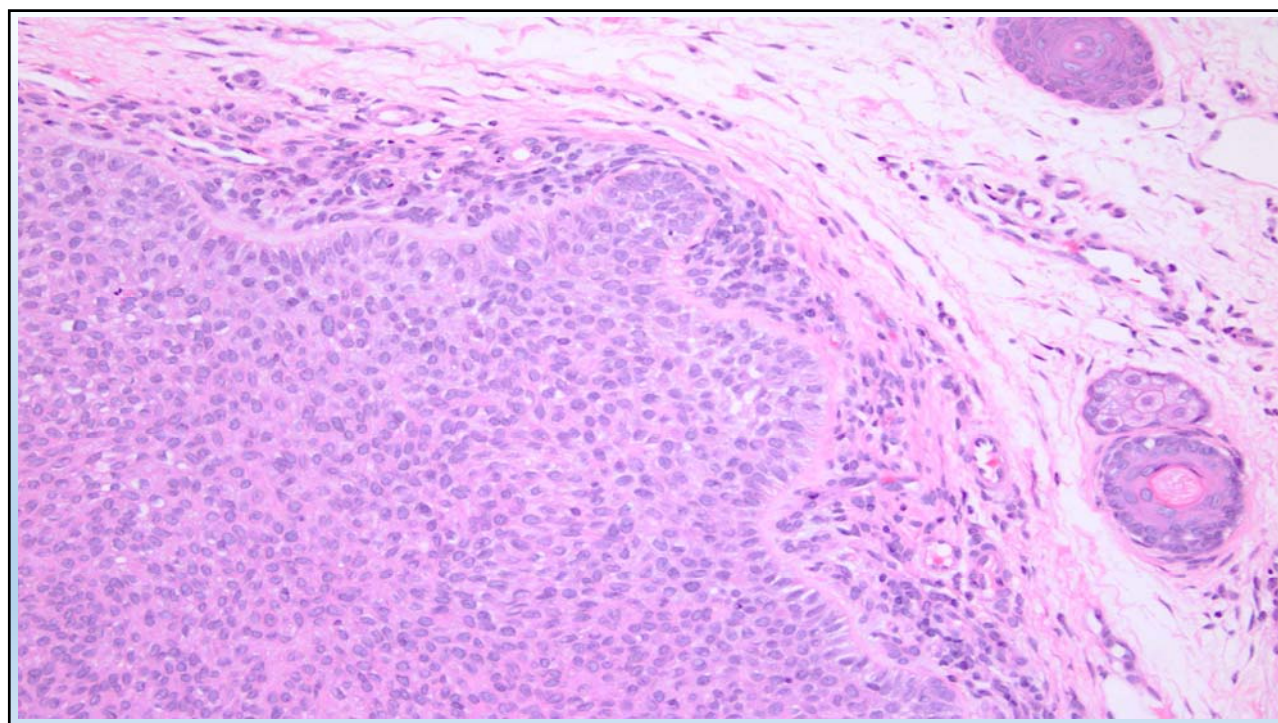
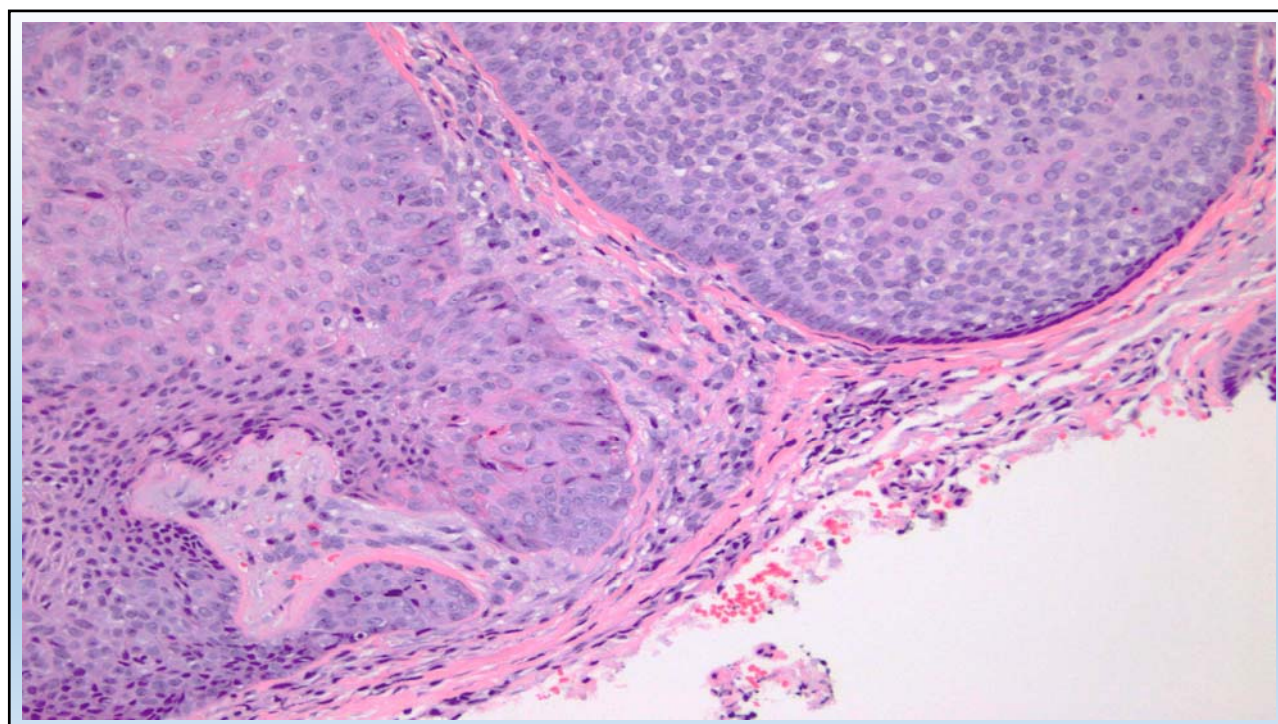
Trichilemmoma

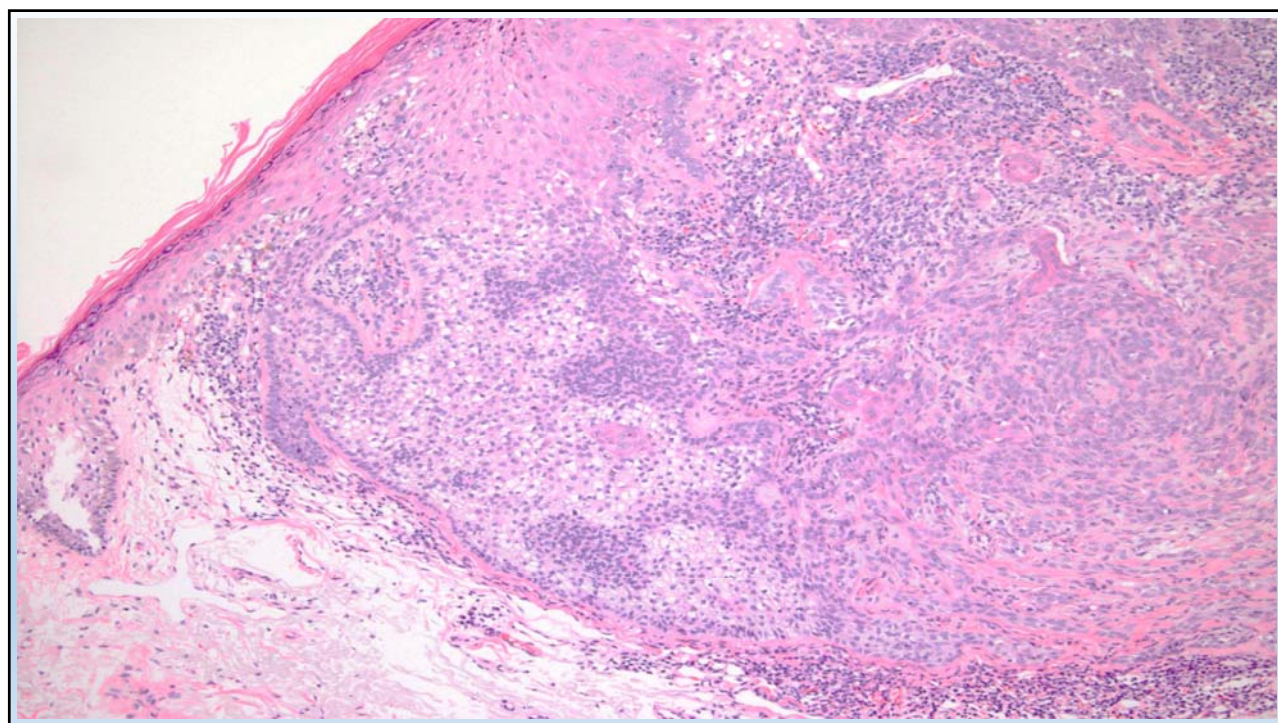
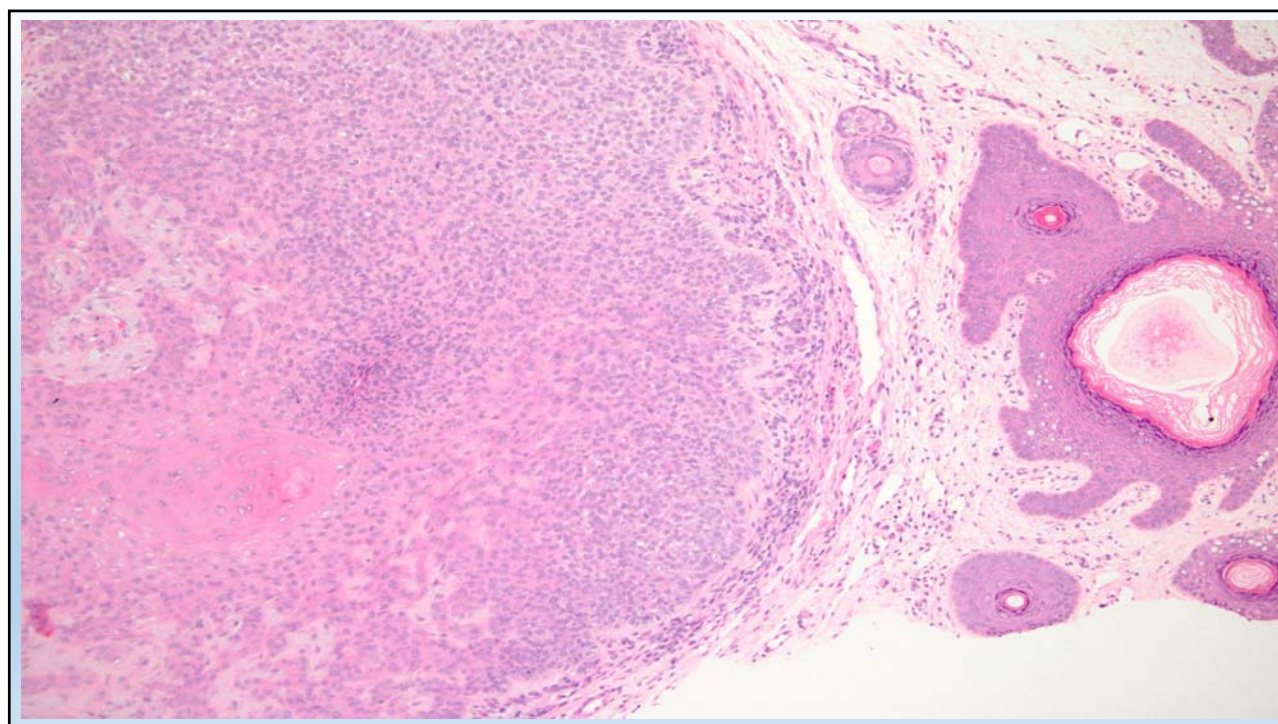
- **Histologic features:**

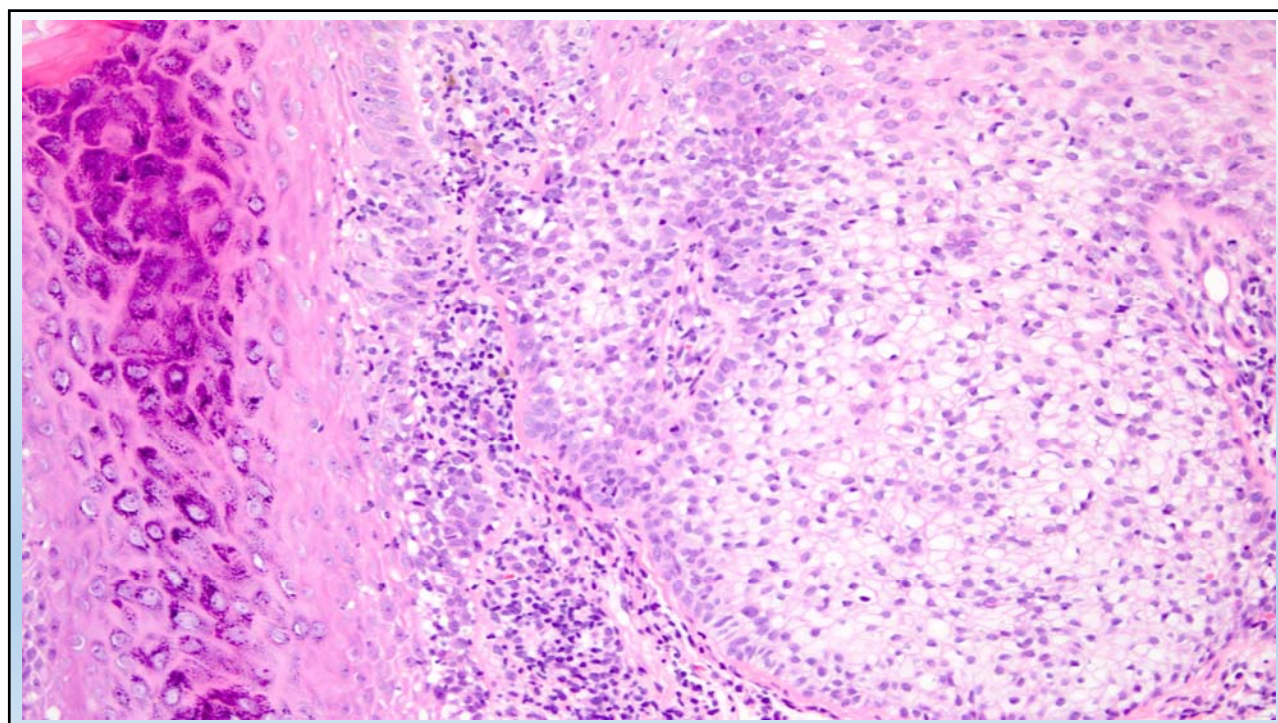
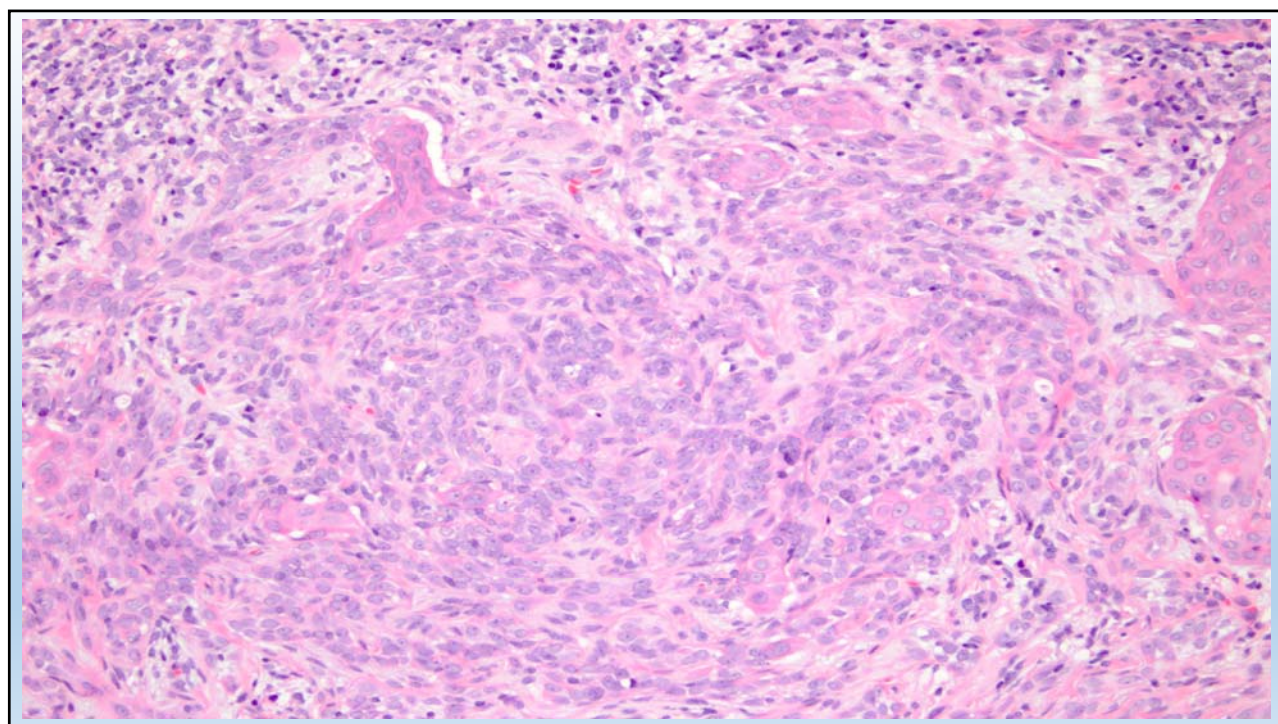
- Inverted proliferation of outer root sheath epithelium that connects to the epidermis
- Monomorphous population of epithelial cells
- Peripheral palisading of the nuclei
- Conspicuous clear cells
- Dense PAS positive membrane outlining the periphery of the neoplasm
- Little to absent mitotic activity
- No ducts present







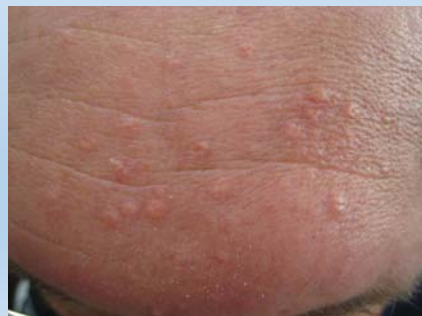
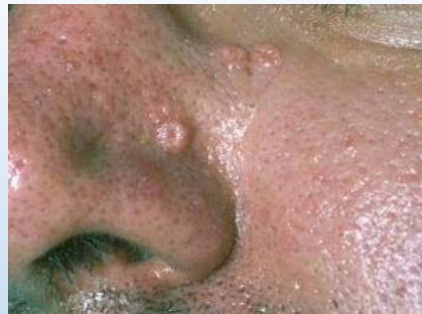


Sebaceous hyperplasia

- **Clinical:**

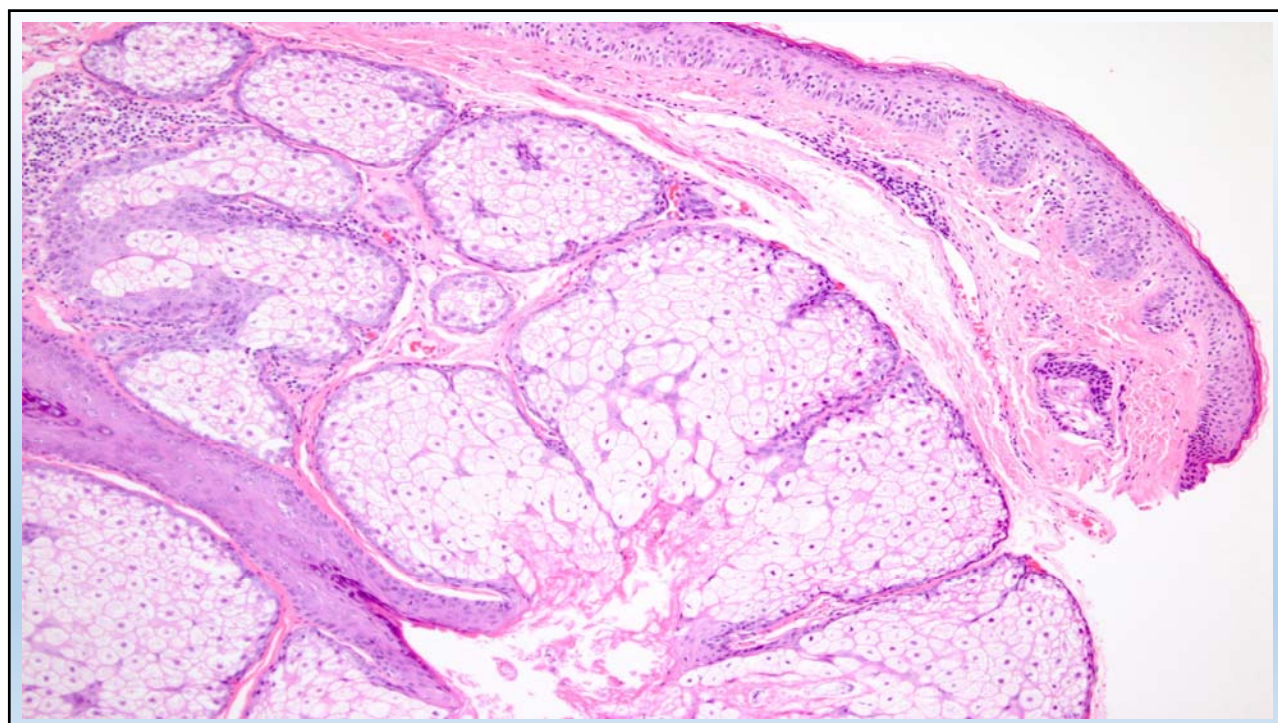
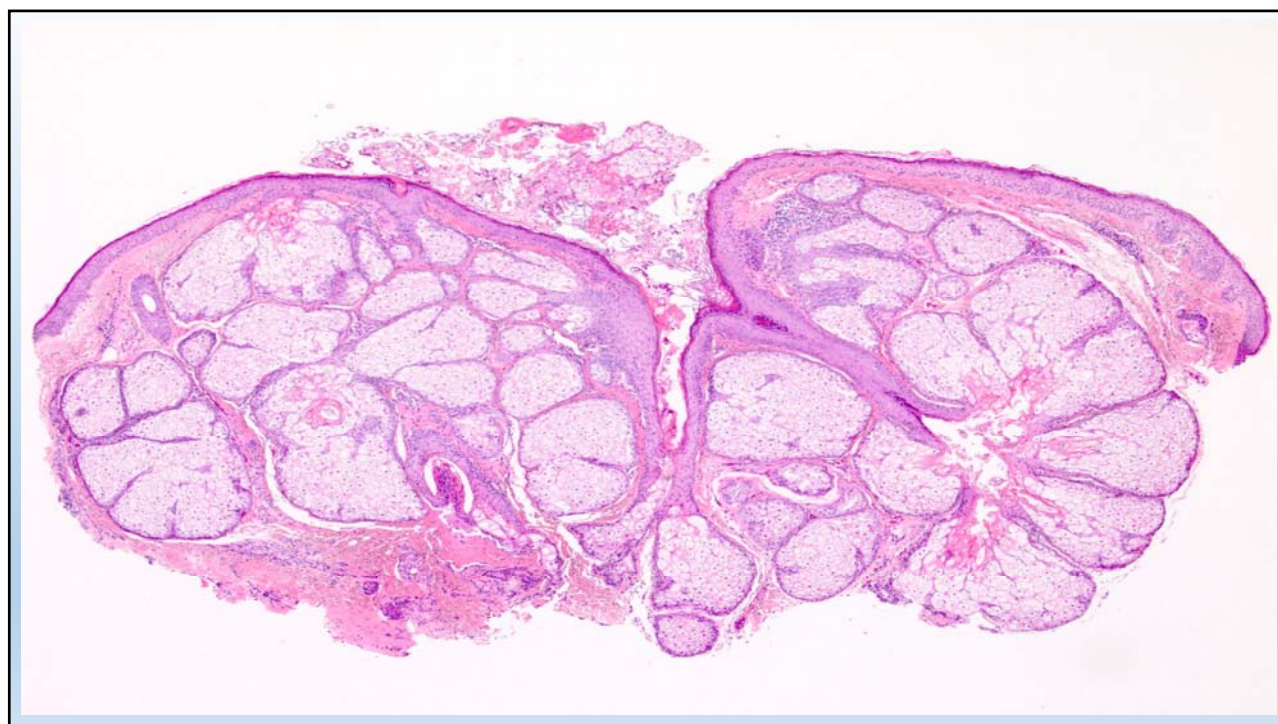- Usually occurs on the face of older individuals
- May occur as single lesions or in groups
- Yellow, dome-shaped, umbilicated papules, 1-2 mm in diameter

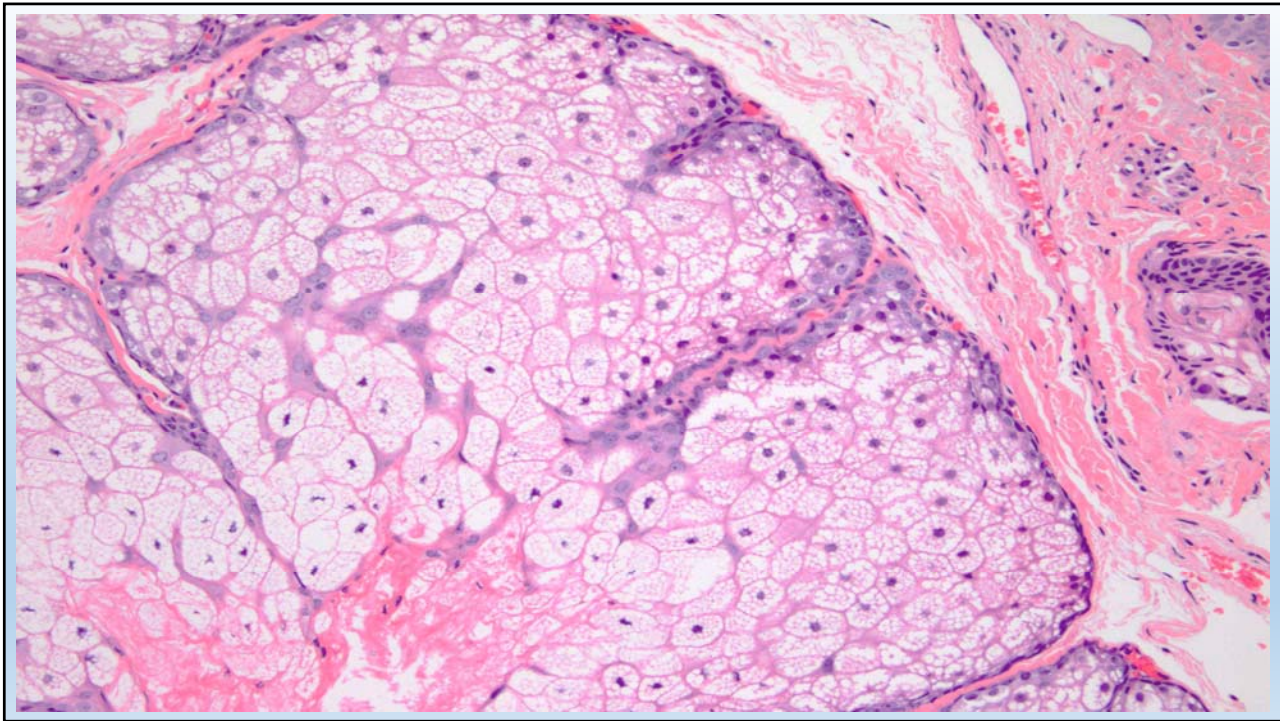


Sebaceous hyperplasia

- **Histologic features:**

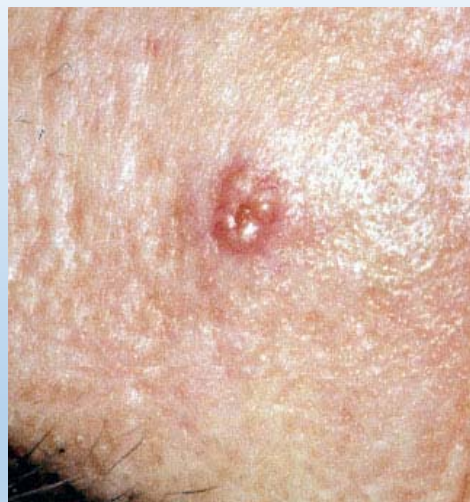- Enlarged gland is located higher in the dermis
- Dilated hair follicle surrounded by an increase in mature sebaceous lobules
- The individual lobules drain into a central duct associated with the follicle
- One layer of germinative cells at the periphery of the lobules





Sebaceous adenoma

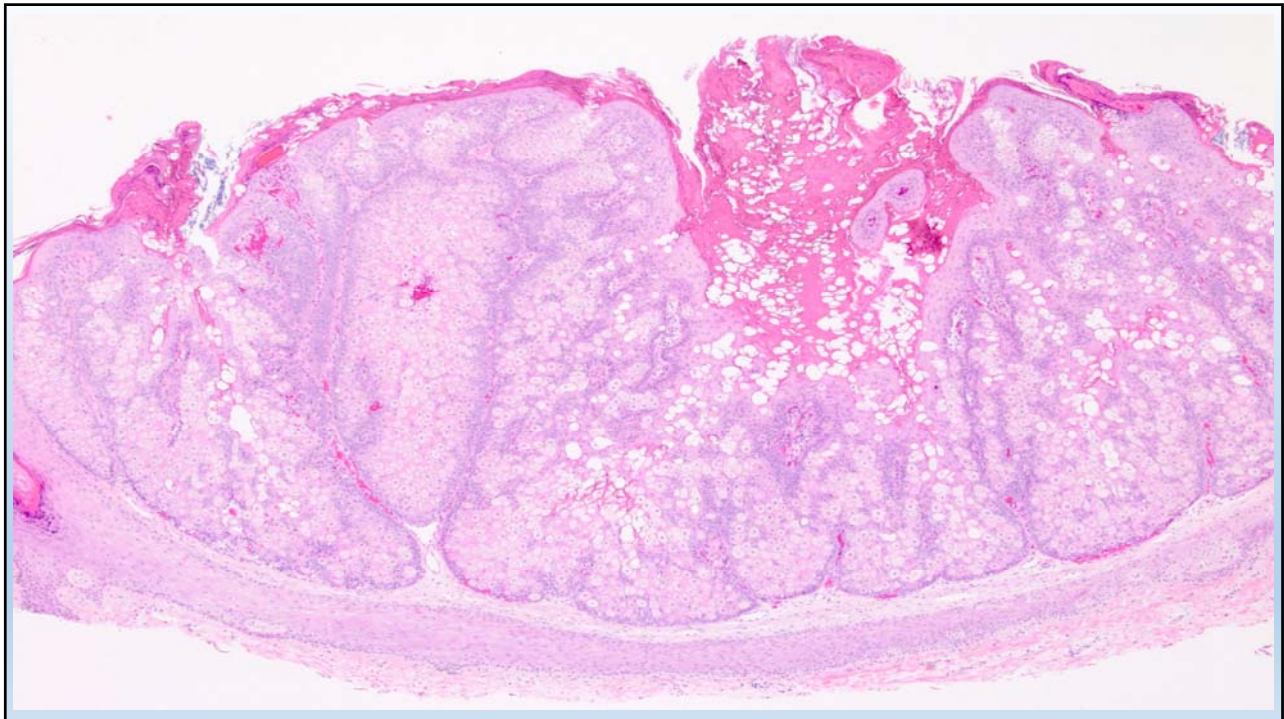
- **Clinical:**
 - Usually occurs in older individuals
 - Tan, pink-red or yellow papulonodule
 - Occasionally may have a polypoid appearance
 - Face and scalp are common sites of involvement
 - Associated with Muir-Torre Syndrome

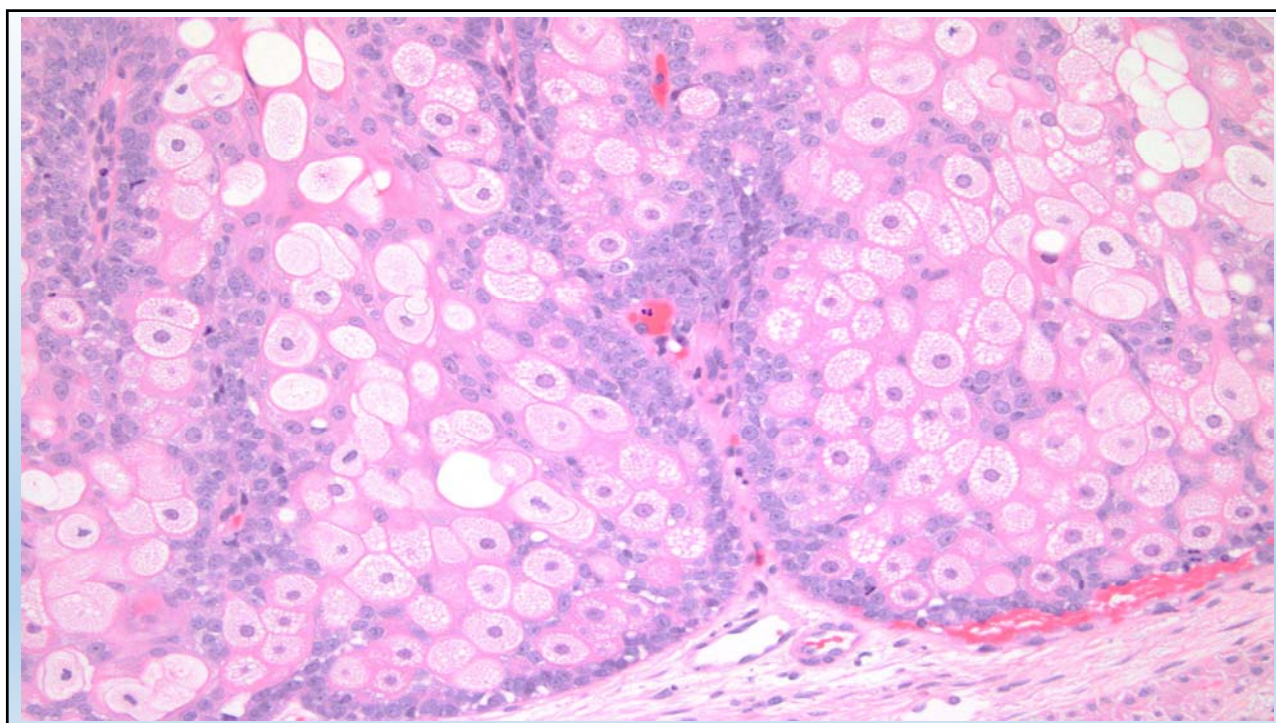
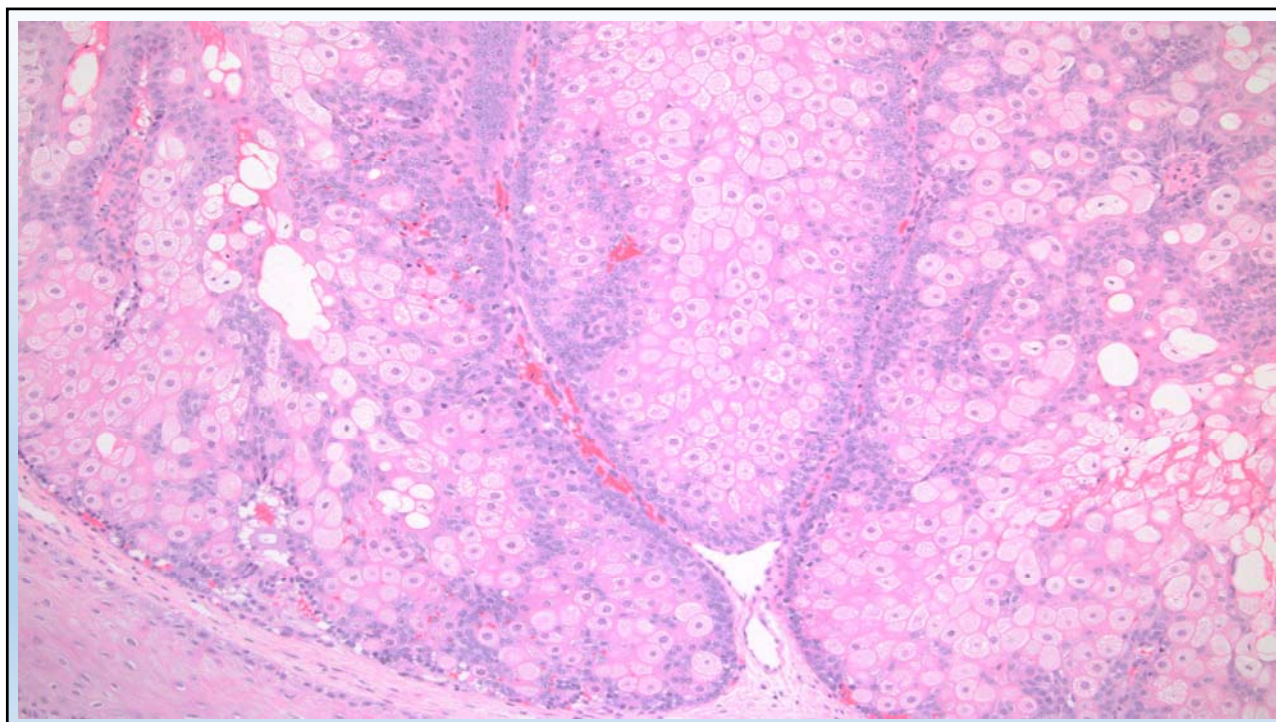


Sebaceous adenoma

- **Histologic features:**

- Multi-lobulated, well-circumscribed
- May appear to replace the overlying squamous epithelium
- Individual lobules of sebocytes surrounded by a collagenous pseudocapsule
- At the periphery of the lobules there is an increase in the number of germinative cells (<50% of the neoplasm)
- May see peripheral palisading of the nuclei

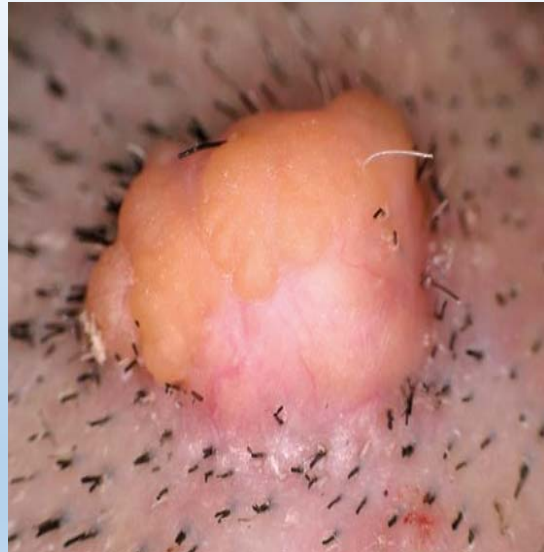



Sebaceoma

- **Clinical:**

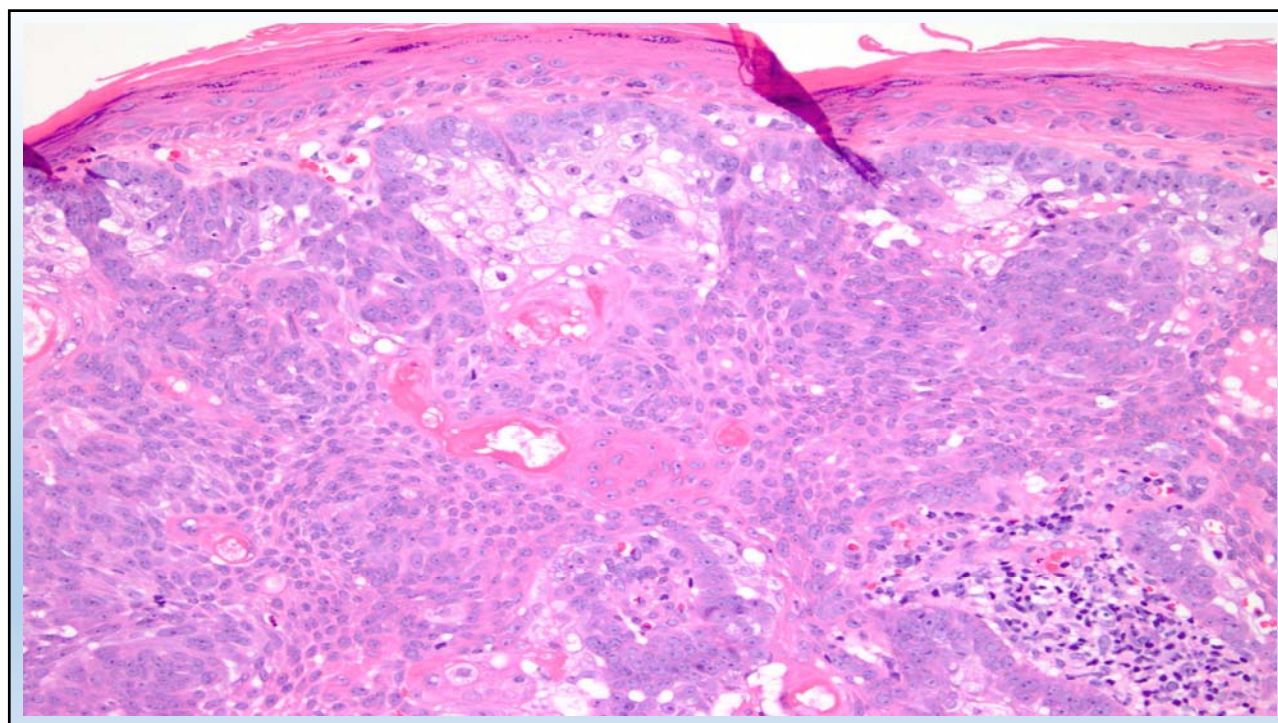
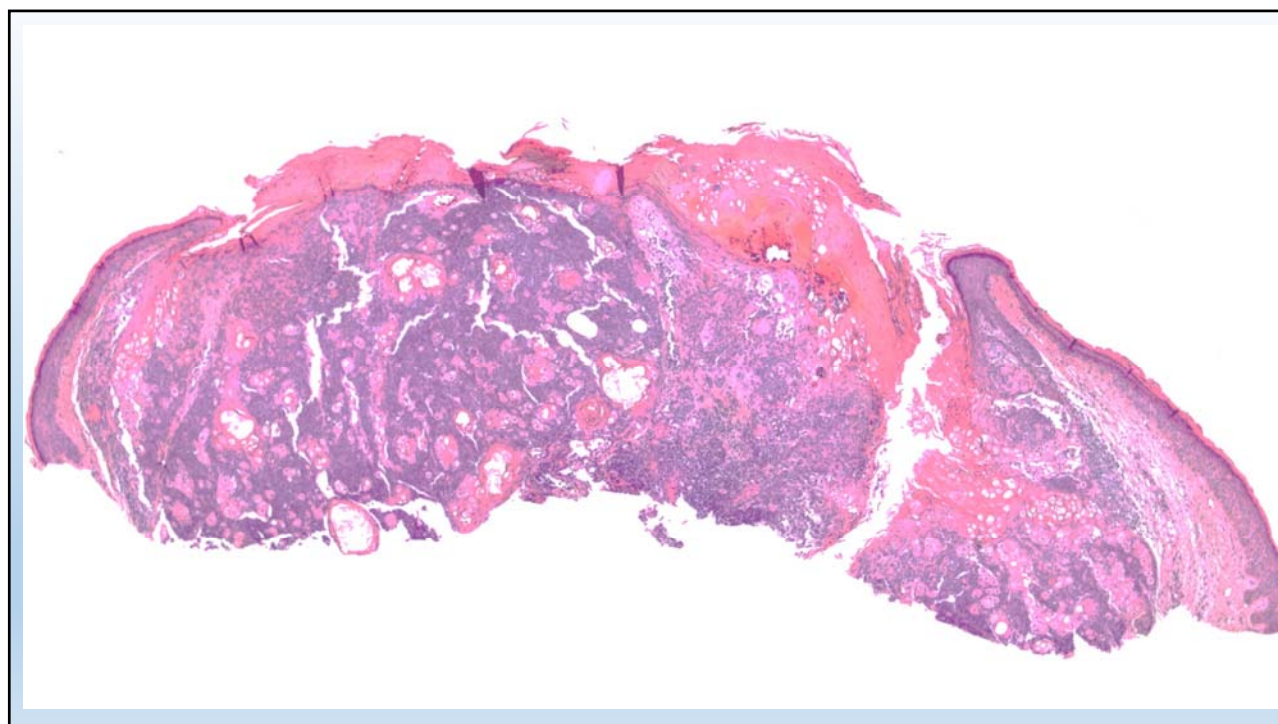
- Yellow to orange, flesh-colored papule or nodule
- Measuring approximately 1-3 cm in diameter
- Majority of patients older (6-9th decades)
- Commonly occur on the face and scalp
- Associated with Muir-Torre syndrome

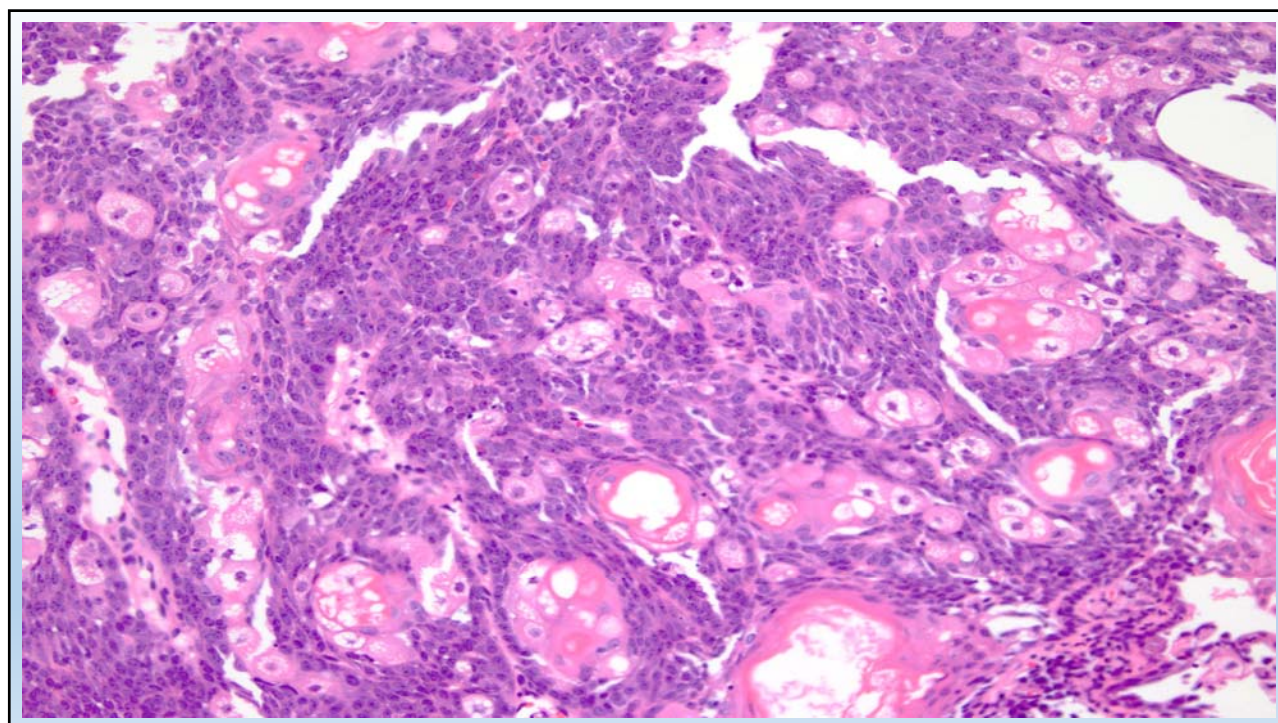
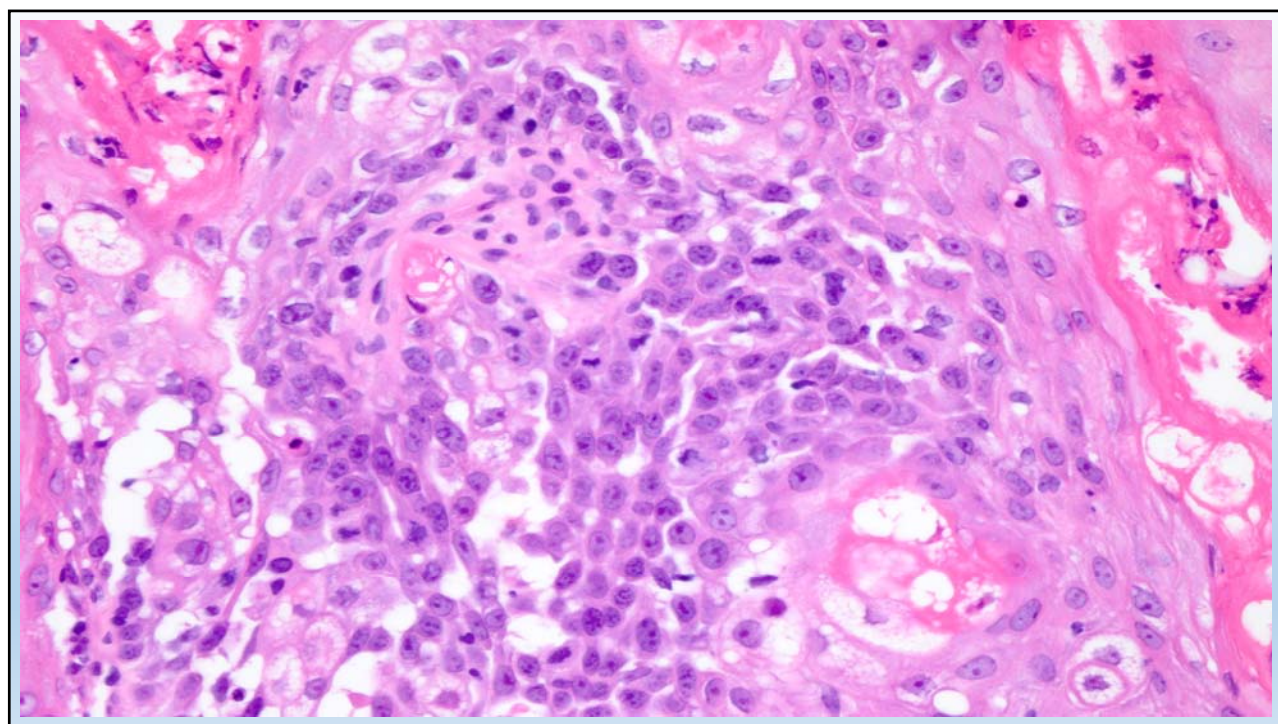


Sebaceoma

- **Histologic features:**

- Dermal tumor with connection to the overlying epidermis
- Multiple nodules, symmetrically distributed surrounded by a fibrous stroma
- Well-circumscribed
- Admixture of germinative cells (>50%) and mature sebocytes
- Peripheral palisading may be seen
- May see ducts
- No nuclear pleomorphism
- Mitotic figures present but should be sparse

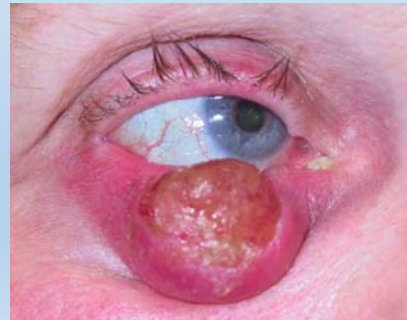
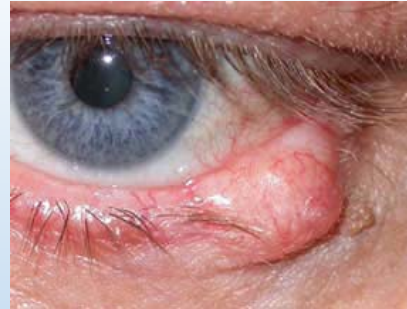




Sebaceous carcinoma

- **Clinical:**

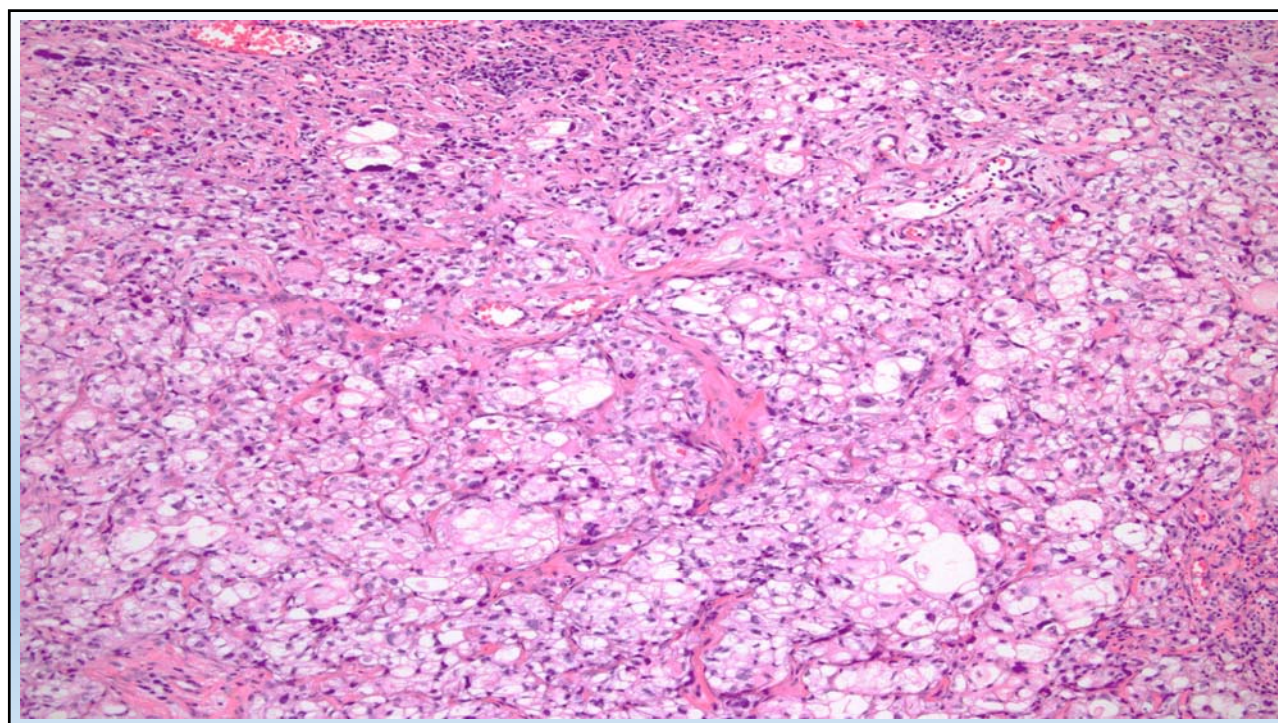
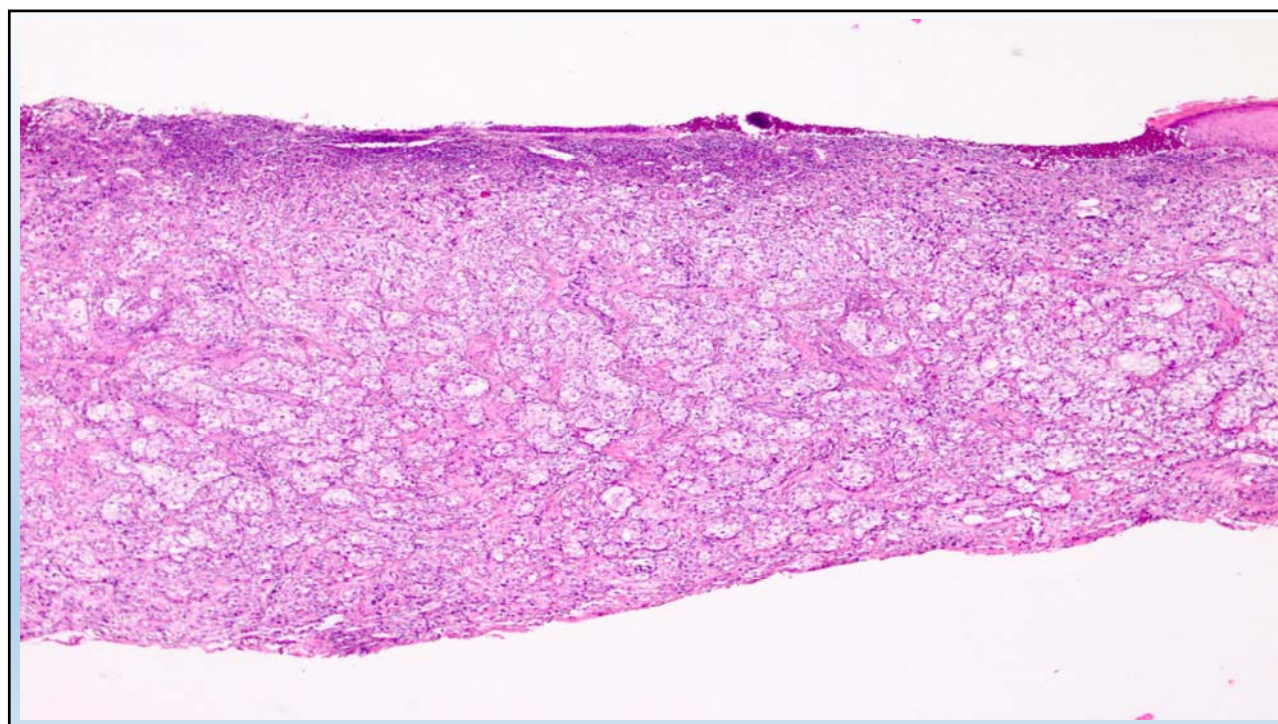
- Ocular (approx. 75% of cases)
 - Steadily enlarging, non-ulcerated mass
 - Upper eyelid is commonly affected
- Extra-ocular—less aggressive
 - Presents on the head and neck
 - Males>females
- Associated with Muir-Torre syndrome

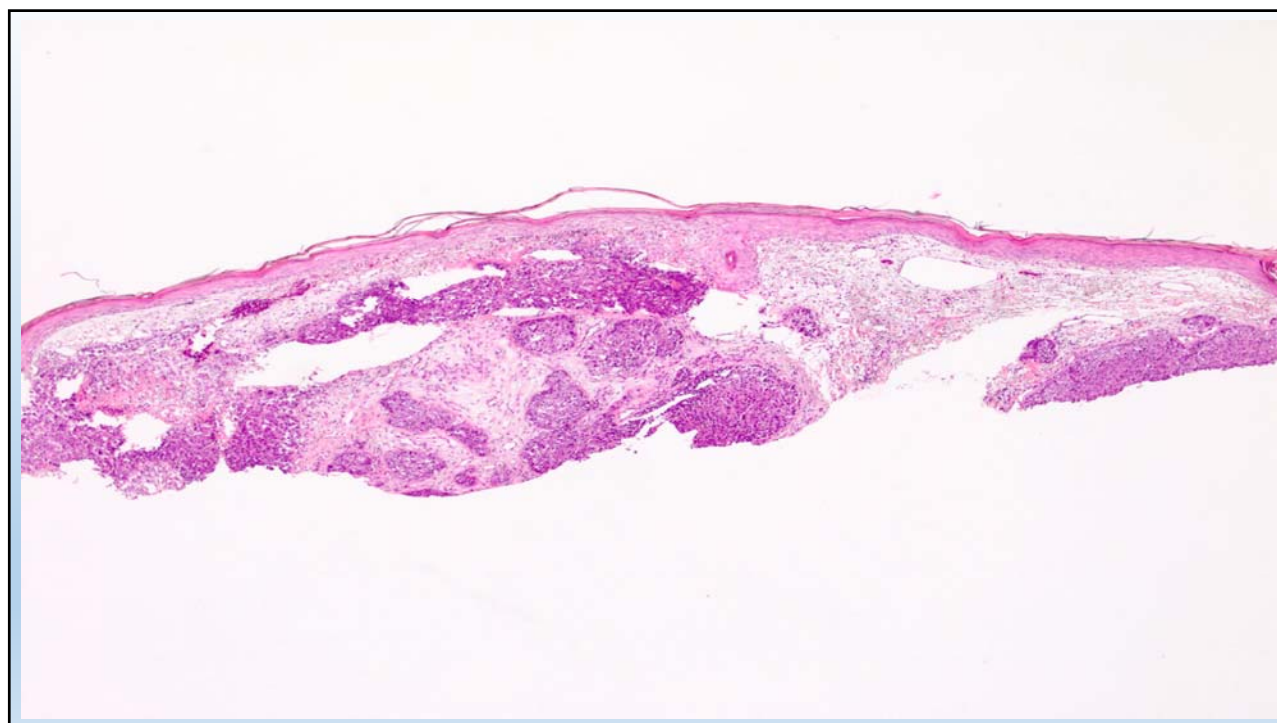
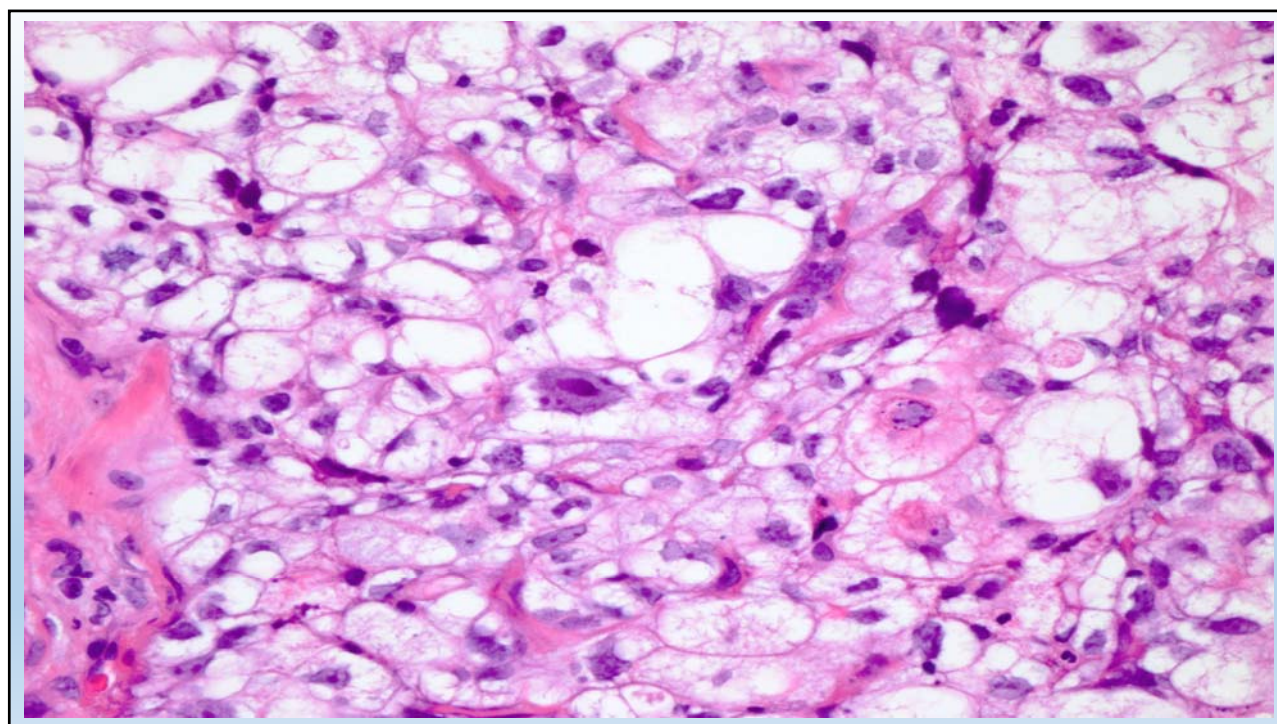


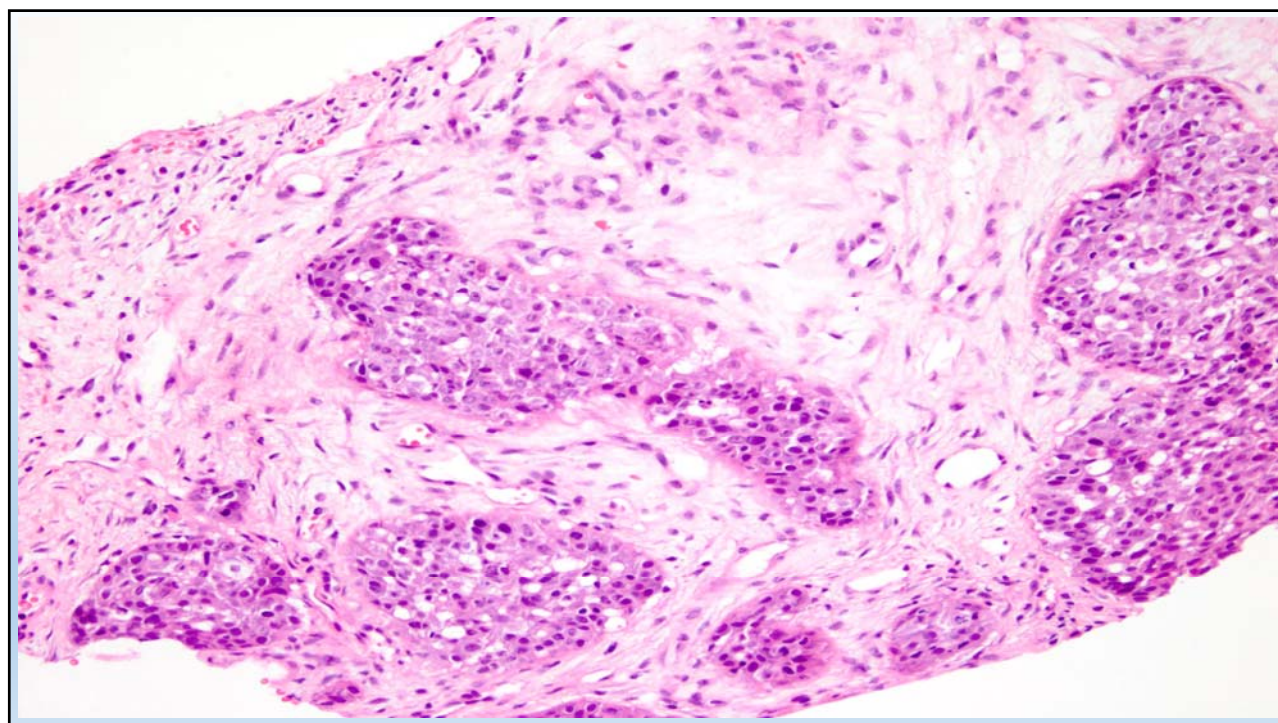
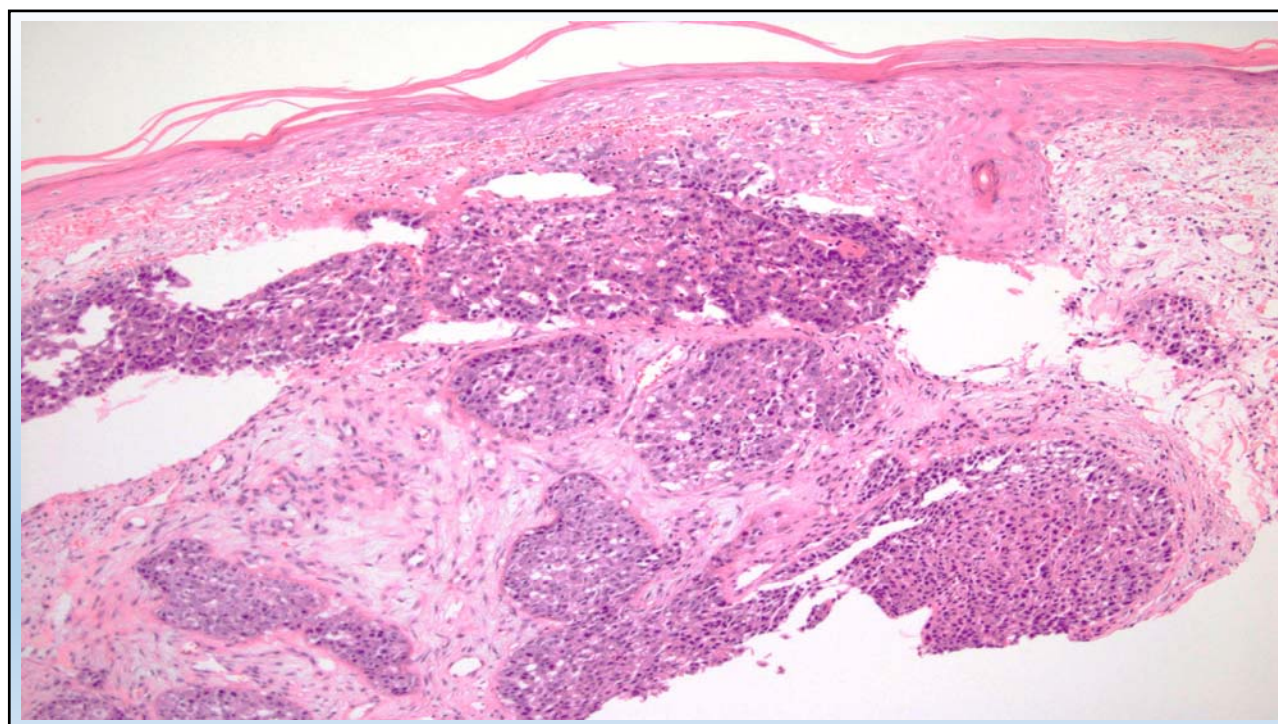
Sebaceous carcinoma

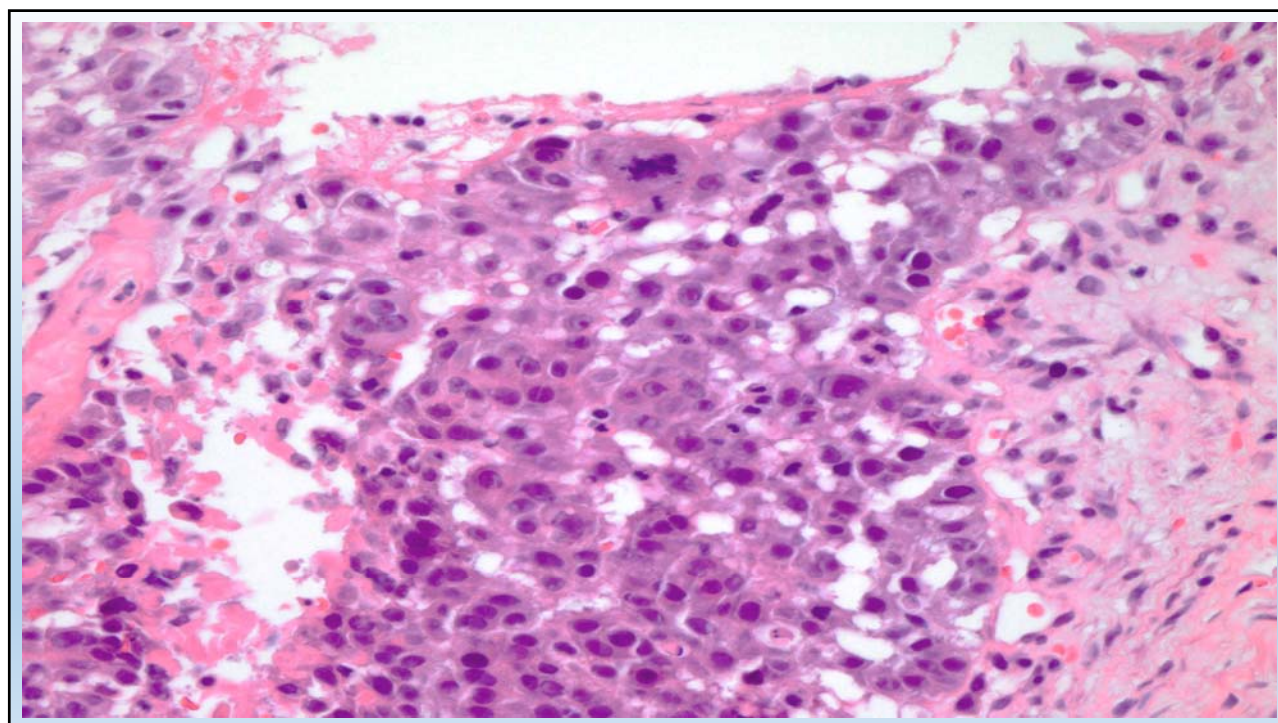
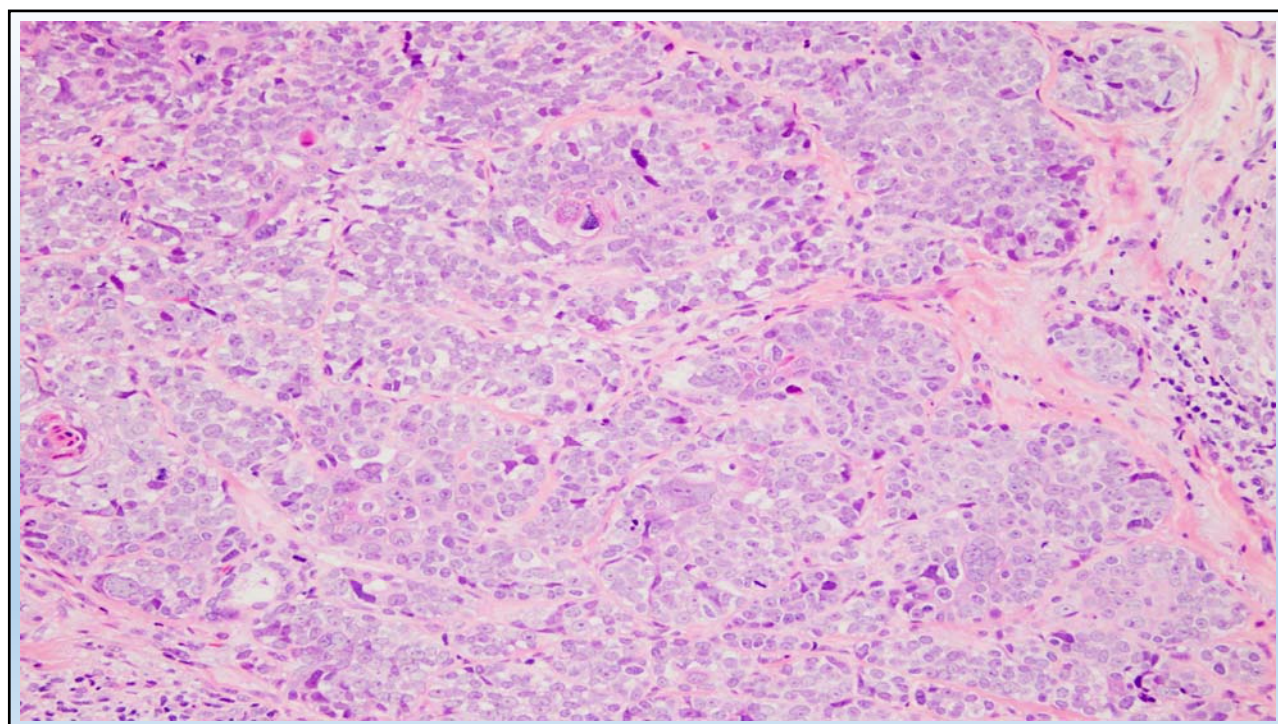
- **Histologic features:**

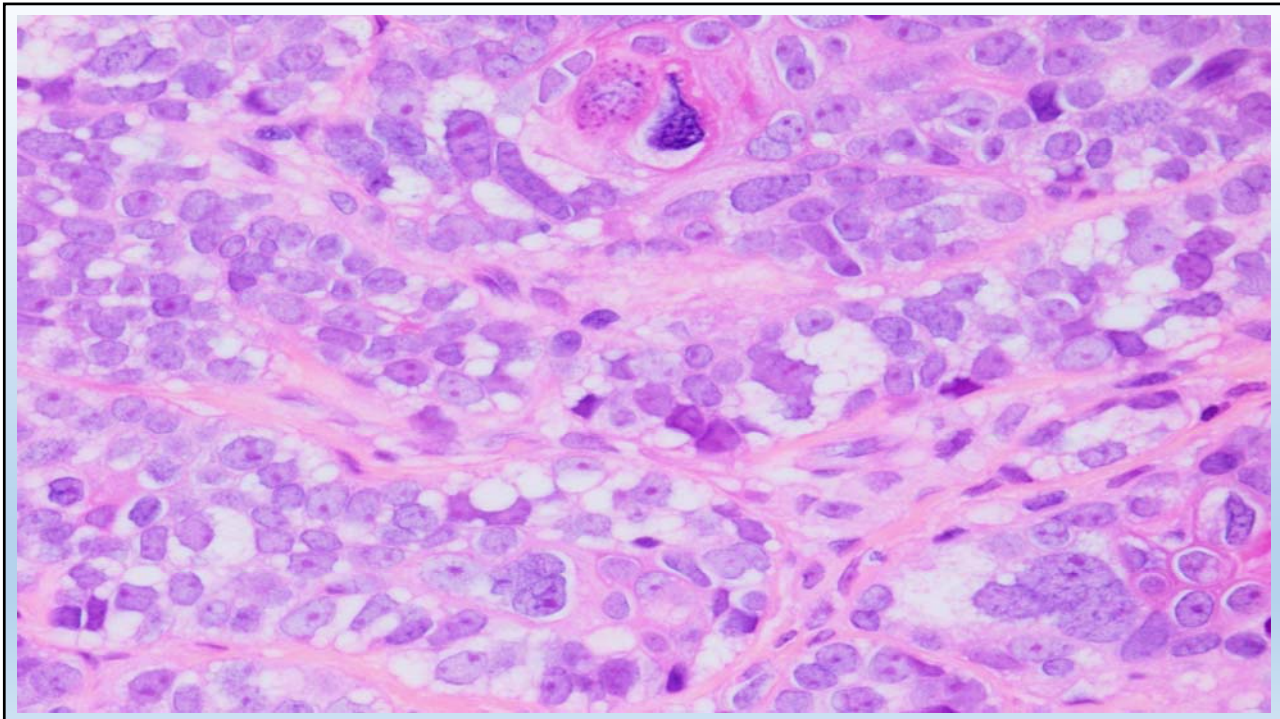
- Well-differentiated
 - Lobules of mature sebocytes with a diffuse, infiltrative growth pattern
 - Occasionally shows connection with the overlying epidermis
 - Lobules are composed of a disorderly mixture of mature sebocytes and germinative cells
 - Necrosis is present
 - Mitotic figures present in the mature sebocytes
- Poorly differentiated
 - Hyperchromatic, pleomorphic cells with minimal lipid
 - May see keratinization











Am J Dermatopathol. 2015 Nov;37(11):809-21. doi: 10.1097/DAD.0000000000000255.

Role of Immunohistochemistry in the Diagnosis of Sebaceous Carcinoma: A Clinicopathologic and Immunohistochemical Study.

Plaza JA¹, Mackinnon A, Carrillo L, Prieto VG, Sanguenza M, Suster S.

Am J Dermatopathol. 2011 Aug;33(6):579-87. doi: 10.1097/DAD.0b013e31820a2027.

Sebaceous carcinoma: an immunohistochemical reappraisal.

Ansai S¹, Takeichi H, Arase S, Kawana S, Kimura T.

Histopathology. 2007 Jul;51(1):80-6.

Characteristic Ber-EP4 and EMA expression in sebaceoma is immunohistochemically distinct from basal cell carcinoma.

Fan YS¹, Carr RA, Sanders DS, Smith AP, Lazar AJ, Calonje E.

Role of immunohistochemistry in DDx of sebaceous CA

	BerEP4	EMA
Sebaceous CA	+	+
Basal cell CA	+	-
Squamous cell CA	-	+

Sebaceous neoplasms and the pathologist's role

- What do we need to worry about when diagnosing these neoplasms?
 - Muir-Torre Syndrome (MTS)
 - AD genodermatosis in which patients develop cutaneous neoplasms (sebaceous tumors and keratoacanthomas) and visceral malignancies
 - Due to germline mutations in DNA mismatch repair proteins
 - MSH-2 (>90%), MLH-1 (<10%), and MSH-6
 - Nearly 50% of patients with MTS develop two or more visceral malignancies

Sebaceous neoplasms and associated syndromes

Histopathology, 2010 Jan;56(1):133-47. doi: 10.1111/j.1365-2559.2009.03454.x.

Sebaceous neoplasia and the Muir-Torre syndrome: important connections with clinical implications.

Shalin SC¹, Lyle S, Calonje E, Lazar AJ.

JAMA Dermatol, 2014 Dec;150(12):1315-21.

Screening for germline mismatch repair mutations following diagnosis of sebaceous neoplasm.

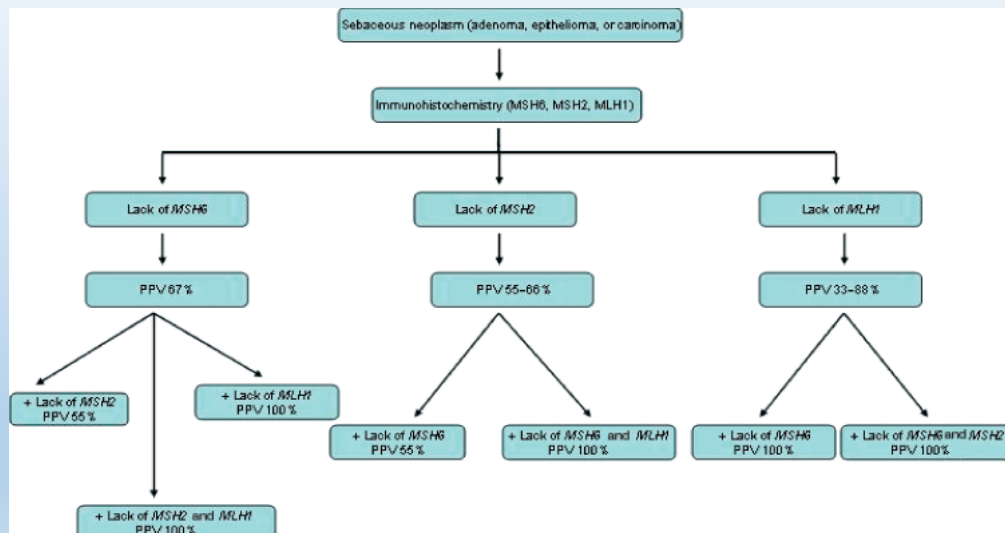
Everett JN, Raymond VM, Dandapani M, Marvin M, Kohlmann W, Chittenden A, Koeppe E, Gustafson SL, Else T, Fullen DR, Johnson TM, Syngal S, Gruber SB, Stoffel EM.

J Cutan Pathol, 2009 Jun;36(6):613-9. doi: 10.1111/j.1600-0560.2009.01248.x.

Cutaneous sebaceous neoplasms as markers of Muir-Torre syndrome: a diagnostic algorithm.

Abbas O¹, Mahalingam M.

Cutaneous sebaceous neoplasms as markers of Muir-Torre syndrome: a diagnostic algorithm



Journal of Cutaneous Pathology
Volume 36, Issue 6, pages 613-619, 21 MAY 2009 DOI: 10.1111/j.1600-0560.2009.01248.x
<http://onlinelibrary.wiley.com/doi/10.1111/j.1600-0560.2009.01248.x/full#ft4>

Can immunohistochemical stains help with the identification of adnexal neoplasms?

- Helpful when trying to determine if you are dealing with a cutaneous metastasis versus a primary lesion
- Also may aid in identification of ducts within these neoplasms if they are not apparent by the H&E stain
 - EMA
 - CEA
 - GCDFP-15 (apocrine)

Am J Clin Pathol. 2015 Mar;143(3):430-6. doi: 10.1309/AJCP2N1AFXEFOVYE.

Immunohistochemical distinction of primary sweat gland carcinoma and metastatic breast carcinoma: can it always be accomplished reliably?

Mentrikoski MJ¹, Wick MR².

Mod Pathol. 2010 May;23(5):713-9. doi: 10.1038/modpathol.2010.46. Epub 2010 Feb 26.

The diagnostic utility of immunohistochemistry in distinguishing primary skin adnexal carcinomas from metastatic adenocarcinoma to skin: an immunohistochemical reappraisal using cytokeratin 15, nestin, p63, D2-40, and calretinin.

Mahalingam M¹, Nguyen LP, Richards JE, Muzikansky A, Hoang MP.

J Cutan Pathol. 2007 Jun;34(6):474-80.

Use of p63 expression in distinguishing primary and metastatic cutaneous adnexal neoplasms from metastatic adenocarcinoma to skin.

Ivan D¹, Nash JW, Prieto VG, Calonje E, Lyle S, Diwan AH, Lazar AJ.

J Cutan Pathol. 2010 Apr;37(4):403-10. doi: 10.1111/j.1600-0560.2010.01517.x.

Value of p63 and podoplanin (D2-40) immunoreactivity in the distinction between primary cutaneous tumors and adenocarcinomas metastatic to the skin: a clinicopathologic and immunohistochemical study of 79 cases.

Plaza JA¹, Ortega PF, Stockman DL, Suster S.

Arch Pathol Lab Med. 2011 Aug;135(8):975-83. doi: 10.5858/2009-0445-OAR2.

An immunohistochemical panel to differentiate metastatic breast carcinoma to skin from primary sweat gland carcinomas with a review of the literature.

Rollins-Raval M¹, Chivukula M, Tseng GC, Jukic D, Dabbs DJ.

Primary cutaneous sweat gland CA vs. Metastatic Adenocarcinoma

Primary cutaneous sweat gland carcinoma	Metastatic adenocarcinoma
P63 positive	P63 negative
Keratin 5/6 positive	Keratin 5/6 negative
Podoplanin (D2-40) positive	Podoplanin (D2-40) negative
Cytokeratin 15 positive	Cytokeratin 15 negative
P40 positive	P40 negative

Stains that are not particularly helpful:
GCDFP-15, ER, and PR

Conclusion:

- Cutaneous appendageal tumors display a wide variety of morphologic features
 - Folliculo-sebaceous/apocrine
 - Eccrine
- When examining these lesions microscopically the first step is to determine the origin of the tumor
 - Pattern recognition is key
- Always remember to think about a cutaneous metastasis when the tumor is forming glands and perform the appropriate immunohistochemical work-up (after you get the appropriate clinical history first!)
- Malignant counterparts to a majority of these neoplasms exist so be wary of making a definitive diagnosis of a benign neoplasm based on a partial biopsy

References:

1. Ansai S, Takayama R, et al. BerEP4 is a useful marker for follicular germinative differentiation of cutaneous epithelial neoplasms. *J Dermatol*. 2012; 39(8): 688-92.
2. Abbas O, Mahalingham M. Cutaneous sebaceous neoplasms as markers of Muir-Torre syndrome: a diagnostic algorithm. *J Cutan Pathol*. 2009; 36: 613-19.
3. Swanson PE, Fitzpatrick MM, et al. Immunohistologic differential diagnosis of basal cell carcinoma, squamous cell carcinoma, and trichoepithelioma in small cutaneous biopsy specimens. *J Cutan Pathol*. 1998; 25(3): 153-59.
4. Lee JJ, Mochel MC, et al. P40 exhibits better specificity in distinguishing primary skin adnexal carcinomas from cutaneous metastases. *Hum Pathol*. 2014; 45(5): 1078-83.
5. Plaza JA, Mackinnon A et al. Role of immunohistochemistry in the diagnosis of sebaceous carcinoma: A clinicopathologic and immunohistochemical study. *Am J Dermatopathol*. 2015; 37(11): 809-21.
6. Ansai S, Takeichi H, et al. Sebaceous carcinoma: an immunohistochemical reappraisal. *Am J Dermatopathol*. 2011; 33(6): 579-87.
7. Fan YS, Carr RA et al. Characteristic Ber-EP4 and EMA expression in sebaceoma is immunohistochemically distinct from basal cell carcinoma. *Histopathology*. 2007; 51(1): 80-86.
8. Mentrikoski MJ, Wick MR. Immunohistochemical distinction of primary sweat gland carcinoma and metastatic breast carcinoma: can it always be accomplished reliably? *Am J Clin Pathol*. 2015; 143(3): 430-6.
9. Mahalingham M, Nguyen LP, et al. The diagnostic utility of immunohistochemistry in distinguishing primary skin adnexal carcinomas from metastatic adenocarcinoma to skin: an immunohistochemical reappraisal using cyfokeratin 15, nestin, p63, D2-40, and calretinin. *Mod Pathol*. 2010; 23(5): 713-9.
10. Ivan D, Nash JW et al. Use of p63 expression in distinguishing primary and metastatic cutaneous adnexal neoplasms from metastatic adenocarcinoma to skin. *J Cutan Pathol*. 2007; 34(6): 474-80.
11. Plaza JA, Ortega PF et al. Value of p63 and podoplanin (D2-40) immunoreactivity in the distinction between primary cutaneous tumors and adenocarcinomas metastatic to the skin: a clinicopathologic and immunohistochemical study of 79 cases. *J Cutan Pathol*. 2010; 37(4): 403-10.
12. Rollins-Raval M, Chivukula M et al. An immunohistochemical panel to differentiate metastatic breast carcinoma to skin from primary sweat gland carcinomas with a review of the literature. *Acrh Pathol Lab Med*. 2011; 135(8): 975-83.
13. McKee PH, Calonje E, et al. *Pathology of the Skin*, Fourth Edition. Elsevier Mosby, London 2012.