



CHAPTER 1

Tumours of the Breast

Cancer of the breast is one of the most common human neoplasms, accounting for approximately one quarter of all cancers in females. It is associated with the Western lifestyle, and incidence rates are, therefore, highest in countries with advanced economies. Additional risk factors include early menarche and late childbirth. Breast cancer is further characterized by a marked genetic susceptibility. Early detection and advances in treatment have begun to reduce mortality rates in several countries. Through the use of cDNA expression profiles, it may become possible to predict clinical outcome in individual patients.

The typing of invasive breast cancer and its histological variants is well established. More difficult is the classification of pre-invasive breast lesions which are now increasingly detected by mammography. The WHO Working Group agreed that more clinical follow-up and genetic data are needed for a better understanding of the natural history of these lesions.

WHO histological classification of tumours of the breast

Epithelial tumours		Adenomas	
Invasive ductal carcinoma, not otherwise specified	8500/3	Tubular adenoma	8211/0
Mixed type carcinoma		Lactating adenoma	8204/0
Pleomorphic carcinoma	8022/3	Apocrine adenoma	8401/0
Carcinoma with osteoclastic giant cells	8035/3	Pleomorphic adenoma	8940/0
Carcinoma with choriocarcinomatous features		Ductal adenoma	8503/0
Carcinoma with melanotic features			
Invasive lobular carcinoma	8520/3	Myoepithelial lesions	
Tubular carcinoma	8211/3	Myoepitheliosis	
Invasive cribriform carcinoma	8201/3	Adenomyoepithelial adenositis	
Medullary carcinoma	8510/3	Adenomyoepithelioma	8983/0
Mucinous carcinoma and other tumours with abundant mucin		Malignant myoepithelioma	8982/3
Mucinous carcinoma	8480/3		
Cystadenocarcinoma and columnar cell mucinous carcinoma	8480/3	Mesenchymal tumours	
Signet ring cell carcinoma	8490/3	Haemangioma	9120/0
Neuroendocrine tumours		Angiomatosis	
Solid neuroendocrine carcinoma		Haemangiopericytoma	9150/1
Atypical carcinoid tumour	8249/3	Pseudoangiomatous stromal hyperplasia	
Small cell / oat cell carcinoma	8041/3	Myofibroblastoma	8825/0
Large cell neuroendocrine carcinoma	8013/3	Fibromatosis (aggressive)	8821/1
Invasive papillary carcinoma	8503/3	Inflammatory myofibroblastic tumour	8825/1
Invasive micropapillary carcinoma	8507/3	Lipoma	8850/0
Apocrine carcinoma	8401/3	Angiolipoma	8861/0
Metaplastic carcinomas	8575/3	Granular cell tumour	9580/0
Pure epithelial metaplastic carcinomas	8575/3	Neurofibroma	9540/0
Squamous cell carcinoma	8070/3	Schwannoma	9560/0
Adenocarcinoma with spindle cell metaplasia	8572/3	Angiosarcoma	9120/3
Adenosquamous carcinoma	8560/3	Liposarcoma	8850/3
Mucoepidermoid carcinoma	8430/3	Rhabdomyosarcoma	8900/3
Mixed epithelial/mesenchymal metaplastic carcinomas	8575/3	Osteosarcoma	9180/3
Lipid-rich carcinoma	8314/3	Leiomyoma	8890/0
Secretory carcinoma	8502/3	Leiomyosarcoma	8890/3
Oncocytic carcinoma	8290/3		
Adenoid cystic carcinoma	8200/3	Fibroepithelial tumours	
Acinic cell carcinoma	8550/3	Fibroadenoma	9010/0
Glycogen-rich clear cell carcinoma	8315/3	Phyllodes tumour	9020/1
Sebaceous carcinoma	8410/3	Benign	9020/0
Inflammatory carcinoma	8530/3	Borderline	9020/1
Lobular neoplasia		Malignant	9020/3
Lobular carcinoma in situ	8520/2	Periductal stromal sarcoma, low grade	9020/3
Intraductal proliferative lesions		Mammary hamartoma	
Usual ductal hyperplasia			
Flat epithelial atypia		Tumours of the nipple	
Atypical ductal hyperplasia		Nipple adenoma	8506/0
Ductal carcinoma in situ	8500/2	Syringomatous adenoma	8407/0
Microinvasive carcinoma		Paget disease of the nipple	8540/3
Intraductal papillary neoplasms			
Central papilloma	8503/0	Malignant lymphoma	
Peripheral papilloma	8503/0	Diffuse large B-cell lymphoma	9680/3
Atypical papilloma		Burkitt lymphoma	9687/3
Intraductal papillary carcinoma	8503/2	Extranodal marginal-zone B-cell lymphoma of MALT type	9699/3
Intracystic papillary carcinoma	8504/2	Follicular lymphoma	9690/3
Benign epithelial proliferations			
Adenosis including variants		Metastatic tumours	
Sclerosing adenosis			
Apocrine adenosis		Tumours of the male breast	
Blunt duct adenosis		Gynaecomastia	
Microglandular adenosis		Carcinoma	
Adenomyoepithelial adenositis		Invasive	8500/3
Radial scar / complex sclerosing lesion		In situ	8500/2

¹ Morphology code of the International Classification of Diseases for Oncology (ICD-O) {921} and the Systematized Nomenclature of Medicine (<http://snomed.org>).
Behaviour is coded /0 for benign tumours, /2 for in situ carcinomas and grade 3 intraepithelial neoplasia, /3 for malignant tumours, and /1 for borderline or uncertain behaviour.

TNM classification of carcinomas of the breast

TNM Clinical Classification^{1,2}

T	Primary Tumour
TX	Primary tumour cannot be assessed
T0	No evidence of primary tumour
Tis	Carcinoma in situ
Tis (DCIS)	Ductal carcinoma in situ
Tis (LCIS)	Lobular carcinoma in situ
Tis (Paget)	Paget disease of the nipple with no tumour

Note: Paget disease associated with a tumour is classified according to the size of the tumour.

T1	Tumour 2 cm or less in greatest dimension
T1mic	Microinvasion 0.1 cm or less in greatest dimension ^a
T1a	More than 0.1 cm but not more than 0.5 cm in greatest dimension
T1b	More than 0.5 cm but not more than 1 cm in greatest dimension
T1c	More than 1 cm but not more than 2 cm in greatest dimension
T2	Tumour more than 2 cm but not more than 5 cm in greatest dimension
T3	Tumour more than 5 cm in greatest dimension
T4	Tumour of any size with direct extension to chest wall or skin only as described in T4a to T4d

Note: Chest wall includes ribs, intercostal muscles, and serratus anterior muscle but not pectoral muscle.

T4a	Extension to chest wall
T4b	Oedema (including peau d'orange), or ulceration of the skin of the breast, or satellite skin nodules confined to the same breast
T4c	Both 4a and 4b, above
T4d	Inflammatory carcinoma ^b

Notes: ^a Microinvasion is the extension of cancer cells beyond the basement membrane into the adjacent tissues with no focus more than 0.1 cm in greatest dimension. When there are multiple foci of microinvasion, the size of only the largest focus is used to classify the microinvasion (Do not use the sum of all individual foci). The presence of multiple foci of microinvasion should be noted, as it is with multiple larger invasive carcinomas.

^b Inflammatory carcinoma of the breast is characterized by diffuse, brawny induration of the skin with an erysipeloid edge, usually with no underlying mass. If the skin biopsy is negative and there is no localized measurable primary cancer, the T category is pTX when pathologically staging a clinical inflammatory carcinoma (T4d). Dimpling of the skin, nipple retraction, or other skin changes, except those in T4b and T4d, may occur in T1, T2, or T3 without affecting the classification.

N – Regional Lymph Nodes³

NX	Regional lymph nodes cannot be assessed (e.g. previously removed)
N0	No regional lymph node metastasis
N1	Metastasis in movable ipsilateral axillary lymph node(s)
N2	Metastasis in fixed ipsilateral axillary lymph node(s) or in clinically apparent* ipsilateral internal mammary lymph node(s) in the absence of clinically evident axillary lymph node metastasis
N2a	Metastasis in axillary lymph node(s) fixed to one another or to other structures
N2b	Metastasis only in clinically apparent* internal mammary lymph node(s) and in the absence of clinically evident axillary lymph node metastasis
N3	Metastasis in ipsilateral infraclavicular lymph node(s) with or without axillary lymph node involvement; or in clinically apparent* ipsilateral internal mammary lymph node(s) in the presence of clinically evident axillary lymph node metastasis; or metastasis in ipsilateral supraclavicular lymph node(s) with or without axillary or internal mammary lymph node involvement
N3a	Metastasis in infraclavicular lymph node(s)
N3b	Metastasis in internal mammary and axillary lymph nodes
N3c	Metastasis in supraclavicular lymph node(s)

Note: * clinically apparent = detected by clinical examination or by imaging studies (excluding lymphoscintigraphy)

M	Distant Metastasis
MX	Distant metastasis cannot be assessed
M0	No distant metastasis
M1	Distant metastasis

pTNM Pathological Classification

pT – Primary Tumour

The pathological classification requires the examination of the primary carcinoma with no gross tumour at the margins of resection. A case can be classified pT if there is only microscopic tumour in a margin. The pT categories correspond to the T categories.

Note: When classifying pT the tumour size is a measurement of the invasive component. If there is a large in situ component (e.g. 4 cm) and a small invasive component (e.g. 0.5 cm), the tumour is coded pT1a.

pN – Regional Lymph Nodes⁴

pNX	Regional lymph nodes cannot be assessed (not removed for study or previously removed)
pN0	No regional lymph node metastasis*
pN1mi	Micrometastasis (larger than 0.2 mm, but none larger than 2 mm in greatest dimension)
pN1	Metastasis in 1 - 3 ipsilateral axillary lymph node(s), and/or in internal mammary nodes with microscopic metastasis detected by sentinel lymph node dissection but not clinically apparent**
pN1a	Metastasis in 1-3 axillary lymph node(s), including at least one larger than 2 mm in greatest dimension
pN1b	Internal mammary lymph nodes with microscopic metastasis detected by sentinel lymph node dissection but not clinically apparent
pN1c	Metastasis in 1 - 3 axillary lymph nodes and internal mammary lymph nodes with microscopic metastasis detected by sentinel lymph node dissection but not clinically apparent
pN2	Metastasis in 4 - 9 ipsilateral axillary lymph nodes, or in clinically apparent*** ipsilateral internal mammary lymph node(s) in the absence of axillary lymph node metastasis
pN2a	Metastasis in 4-9 axillary lymph nodes, including at least one that is larger than 2 mm
pN2b	Metastasis in clinically apparent internal mammary lymph node(s), in the absence of axillary lymph node metastasis
pN3	Metastasis in 10 or more ipsilateral axillary lymph nodes; or in infraclavicular lymph nodes; or in clinically apparent ipsilateral internal mammary lymph nodes in the presence of one or more positive axillary lymph nodes; or in more than 3 axillary lymph nodes with clinically negative, microscopic metastasis in internal mammary lymph nodes; or in ipsilateral supraclavicular lymph nodes
pN3a	Metastasis in 10 or more axillary lymph nodes (at least one larger than 2 mm) or metastasis in infraclavicular lymph nodes
pN3b	Metastasis in clinically apparent internal mammary lymph node(s) in the presence of one or more positive axillary lymph node(s); or metastasis in more than 3 axillary lymph nodes and in internal mammary lymph nodes with microscopic metastasis detected by sentinel lymph node dissection but not clinically apparent
pN3c	Metastasis in supraclavicular lymph node(s)

Note: * Cases with only isolated tumour cells (ITC) in regional lymph nodes are classified as pN0. ITC are single tumour cells or small clusters of cells, not more than 0.2 mm in greatest dimension, that are usually detected by immunohistochemistry or molecular methods but which may be verified on H&E stains. ITCs do not typically show evidence of metastatic activity (e.g., proliferation or stromal reaction).

** not clinically apparent = not detected by clinical examination or by imaging studies (excluding lymphoscintigraphy).

*** clinically apparent = detected by clinical examination or by imaging studies (excluding lymphoscintigraphy) or grossly visible pathologically.

pM – Distant Metastasis

The pM categories correspond to the M categories.

Stage Grouping

Stage 0	Tis	N0	M0
Stage I	T1	N0	M0
Stage IIA	T0	N1	M0
	T1	N1	M0
	T2	N0	M0
Stage IIB	T2	N1	M0
	T3	N0	M0
	T0	N2	M0
Stage IIIA	T1	N2	M0
	T2	N2	M0
	T3	N1, N2	M0
	T4	N0,N1,N2	M0
Stage IIIB	Any T	N3	M0
Stage IIIC	Any T	Any N	M1

¹ {51,2976}.

² A help desk for specific questions about the TNM classification is available at <http://tnm.uicc.org>.

³ The regional lymph nodes are:

1. Axillary (ipsilateral): interpectoral (Rotter) nodes and lymph nodes along the axillary vein and its tributaries, which may be divided into the following levels:
 - (i) Level I (low-axilla): lymph nodes lateral to the lateral border of pectoralis minor muscle.
 - (ii) Level II (mid-axilla): lymph nodes between the medial and lateral borders of the pectoralis minor muscle and the interpectoral (Rotter) lymph nodes.
 - (iii) Level III (apical axilla): apical lymph nodes and those medial to the medial margin of the pectoralis minor muscle, excluding those designated as subclavicular or infraclavicular.

Note: Intramammary lymph nodes are coded as axillary lymph nodes, level I.

2. Infraclavicular (subclavicular) (ipsilateral).
3. Internal mammary (ipsilateral): lymph nodes in the intercostal spaces along the edge of the sternum in the endothoracic fascia.
4. Supraclavicular (ipsilateral).

⁴ The pathological N classification requires the resection and examination of at least the low axillary lymph nodes (level I). Examination of one or more sentinel lymph nodes may be used for pathological classification. If classification is based solely on sentinel node biopsy without subsequent axillary lymph node dissection it should be designated (sn) for sentinel node, e.g. pN1(sn).

Invasive breast carcinoma

I.O. Ellis	C.J. Cornelisse
S.J. Schnitt	A.J. Sasco
X. Sastre-Garau	R. Kaaks
G. Bussolati	P. Pisani
F.A. Tavassoli	D.E. Goldgar
V. Eusebi	P. Devilee
J.L. Peterse	M.J. Cleton-Jansen
K. Mukai	A.L. Børresen-Dale
L. Tabár	L. van't Veer
J. Jacquemier	A. Sapino

Definition

Invasive breast carcinoma is a group of malignant epithelial tumours characterized by invasion of adjacent tissues and a marked tendency to metastasize to distant sites. The vast majority of these tumours are adenocarcinomas and are believed to be derived from the mammary parenchymal epithelium, particularly cells of the terminal duct lobular unit (TDLU). Breast carcinomas exhibit a wide range of morphological phenotypes and specific histopathological types have particular prognostic or clinical characteristics.

Epidemiology

Invasive breast cancer is the most common carcinoma in women. It accounts for 22% of all female cancers, 26% in affluent countries, which is more than twice the occurrence of cancer in women at any other site [2188]. The areas of high risk are the affluent populations of North America, Europe and Australia where 6% of women develop invasive breast cancer before age 75. The risk of breast cancer is low in the less developed regions of sub-Saharan Africa and Southern and Eastern Asia, including Japan, where the probability of developing breast cancer by age 75 is one third that of rich countries. Rates are intermediate elsewhere. Japan is the only rich country that in year 2000 still showed low incidence rates.

The prognosis of the disease is very good if detected at an early stage. Significant improvements in survival have been recorded in western countries since the late 1970s [37,485], but advancements have been dramatic in the 1990s due to the combined effect of population screening and adjuvant hormonal treatment. As a result, the increasing mortality trend observed until the 1980s leveled off or declined in several high risk countries e.g. the United States of America (USA), the United Kingdom and the Netherlands [3155].

The risk of the disease had been increasing until the early 1980s in both developed and developing countries and continues to increase in particular in the developing countries [3068]. Thereafter, in developed countries, the advent of mammography and the previously mentioned improvements in survival altered both incidence and mortality; the latter no longer appropriately reflect trends in the underlying risk of the disease.

Breast cancer incidence, as with most epithelial tumours, increases rapidly with age. Figure 1.02 shows age-specific incidence rates for three selected populations representing countries with low (Japan), intermediate (Slovenia) and high incidence rates (USA), just before screening was implemented. The curves show a characteristic shape, rising steeply up to menopausal age and less rapidly or not at all afterwards. The different behaviour at older ages is due to a cohort effect in the populations of Japan

and Slovenia experiencing an increase in risk that affects mainly younger generations. If current trends persist, these generations will maintain their higher risk and the age-specific curve will approach that of Americans.

Around 1990, breast cancer incidence varied 10-fold world wide, indicating important differences in the distribution of the underlying causes [2189]. Geographical variations, time trends, and studies of populations migrating from low to high risk areas which show that migrant populations approach the risk of the host country in one or two generations [174,1478,3266], clearly suggest an important role of environmental factors in the aetiology of the disease.

Aetiology

The aetiology of breast cancer is multifactorial and involves diet, reproductive factors, and related hormonal imbalances. From descriptive epidemiological

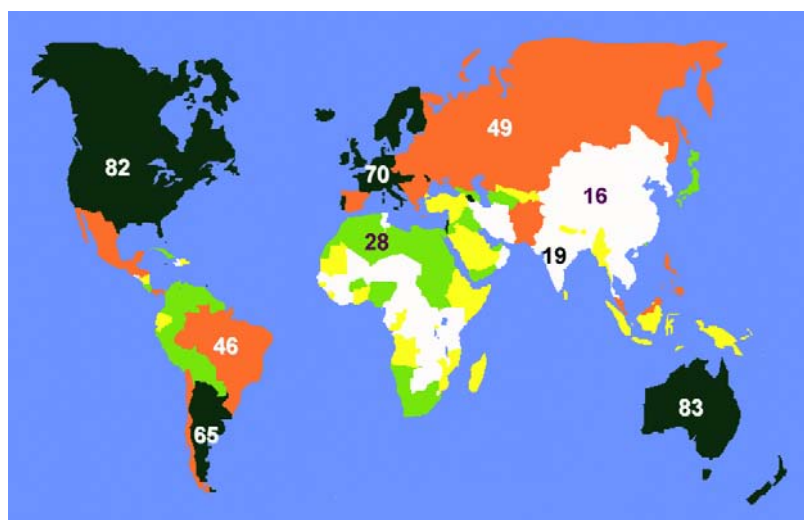


Fig. 1.01 Global incidence rates of breast cancer. Age-standardized rates (ASR) per 100,000 population and year. From Globocan 2000 [846].

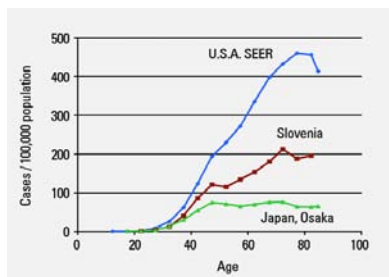


Fig. 1.02 Incidence of female breast cancer by age in selected populations 1988-1993. From M. Parkin et al. [2189].

data it has clearly emerged that breast cancer is a disease of affluent societies which have acquired the Western lifestyle, characterized by a high-caloric diet rich in animal fat and proteins, combined with a lack of physical exercise. Regions which have featured this lifestyle for a long period of time (North America, Northern Europe, Australia) have reached a plateau of an incidence rate of 70 to 90 new cases per 100,000 population/year while countries that have more recently become industrialized and affluent show a marked increase in incidence and mortality. In addition to breast cancer, the Western lifestyle carries a high risk of cancer of the prostate, colon/rectum, and endometrium. Specific environmental exposures operative in the development of breast cancer (e.g. radiation, alcohol, exogenous hormones) have been identified but carry a lower risk.

More than most other human neoplasms, breast cancer often shows familial clustering. Two high penetrance genes have been identified (*BRCA1/2*) which greatly increase the breast cancer risk (see Chapter 8). However, it is anticipated that multigenic traits also play a significant role in the inherited susceptibility to breast cancer.

Reproductive lifestyle

For almost half a century, the events of reproductive life have been considered to be risk factors for breast cancer in women. Breast cancer occurs more frequently among women who have an early menarche, remain nulliparous or, if parous, have few children with a late age at first delivery. Infertility per se appears to be a risk factor as may be lack of breast-feeding. Finally, late age at menopause also increases the risk [1430].

Most of these factors have also been found relevant in populations at low risk of breast cancer such as the Japanese and Chinese. Although the data is limited in Africa, at least one study confirmed the negative impact of late age at first delivery, reduced number of pregnancies and shorter breast feeding time [2770]. Recent data indicates that the age at any delivery, not just the first is associated with breast cancer risk, with deliveries occurring before the age of 30 having a protective effect [3137].

Controversies still surround the issue of abortion, some studies, but not others,

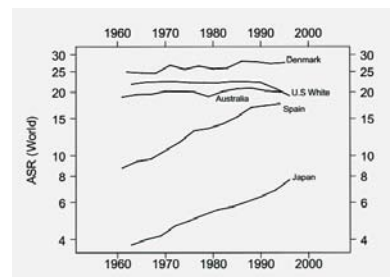


Fig. 1.04 Female breast cancer mortality trends. Source: WHO/NCHS.

finding an increased risk for induced abortion. Similarly, the protective effect of lactation, once considered quite a strong factor, was later given less importance; its impact appears limited to long-term cumulative breast feeding, preferably exceeding two years [435].

Exogenous hormones

Two major types of hormonal compounds have been evaluated in relation to breast cancer: oral contraceptives and menopausal replacement therapy.

The evidence suggests a small increase in the relative risk associated with the use of combined oral contraceptives, especially among current and recent users, which is not related to duration of use and type or dose of preparation, and may be partly linked to detection bias [1296]. Data on injectable pure progestogen contraceptives shows relative risks from 1.0 to 1.3, which are not statistically significant [1294].

Epidemiological studies on postmenopausal estrogen therapy show a small increase in risk with longer duration of use in current and recent users [1298]. Information on the effect of postmenopausal estrogen-progestogen therapy was provided in only a minority of studies, but indicates that the increased relative risk in long-term users is not significantly different from that for long-term use of estrogens alone [1297]. Yet it should be noted that, among hormone replacement therapy users, there is an over representation of tumours that, with regard to tumour stage, type and grade are associated with a more favourable prognosis [1760].

Nutrition

High intakes of fruit and vegetables are probably associated with a slightly reduced risk of breast cancer [3153].

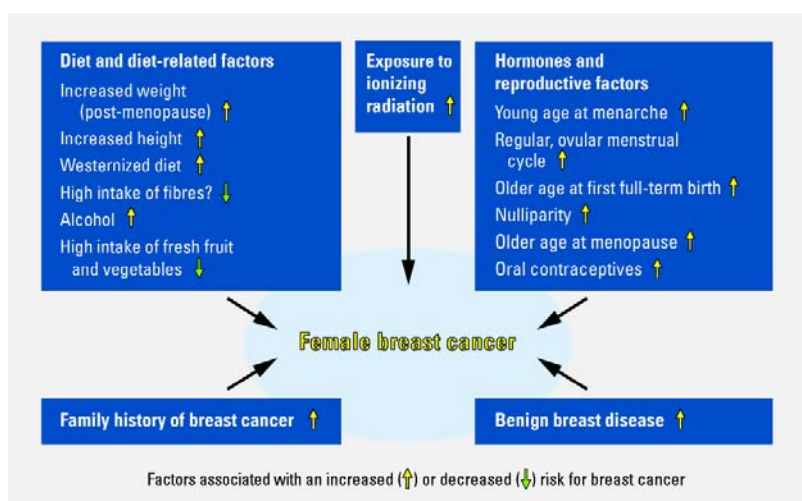


Fig. 1.03 Aetiological factors involved in the development of breast cancer.

Rapid growth and greater adult height, reflecting in part, the total food intake in early years, are associated with an increased risk [674]. Similarly a high body mass, also linked to a high total caloric intake, or intake not counterbalanced by caloric expenditure, is a risk factor for postmenopausal breast cancer. Total fat, as well as saturated animal fat, also possibly increases the risk [674, 3153].

Meat consumption is possibly associated with an increased risk. Red meat was more frequently cited as a risk factor and diets rich in poultry possibly have no links [3153]. In countries with different meat consumption levels within the population, higher risks were associated with higher total meat, red meat or processed meat intake in most studies, although this was not always statistically significant. In conclusion there is considerable consistent evidence that higher meat consumption, particularly red or fried/browned meat is associated with a higher risk of breast cancer [674].

Recent studies, however, tend to suggest that several associations, either preventive for vegetables and fruit, or risk for fat may have been overstated [804,815,817]. Other questions remaining unsolved include the long term cumulative effects of exposure to contaminants, either formed during cooking, such as heterocyclic amines in well-done meat or pesticide residues.

Alcohol

The consumption of alcohol has been relatively consistently found to be associated with a mild increase in risk of breast cancer [2729,3153]. A dose-response

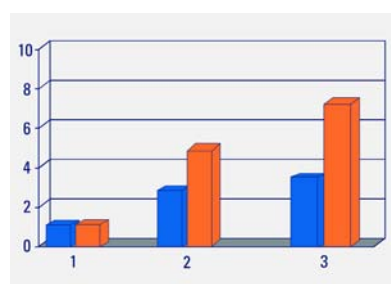


Fig. 1.05 Breast cancer risk by increasing levels of circulating insulin-like growth factor (IGF-1) in women <50 years. Blue columns, IGF-1, orange columns, IGF-1 binding protein (IGFBP-3). From S.E. Hankinson et al. [1127].

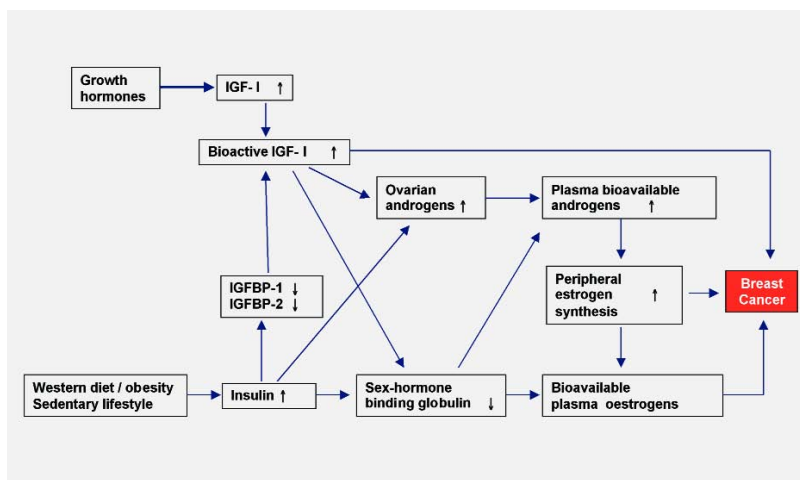


Fig. 1.06 Insulin, IGF-I, bioavailable sex steroids, and breast cancer.

was found with number of drinks per day, including a low level of consumption [1691]. Hormone use or other factors potentially including genetic polymorphism [2182] may modify the risk.

Smoking

The evidence on smoking and breast cancer remains inconclusive [787,816, 784,402]. Tobacco has been viewed as an anti-estrogen and a potential protective factor [182].

Body weight

It has long been known that the influence of weight on breast cancer risk depends on the menopausal status [1292]. More than 100 studies over nearly 30 years in many countries have established that higher body weight increases breast cancer risk among postmenopausal women. This is largely independent of reproductive and lifestyle risk factors and of the effect of physical activity. The association appears to increase in a stepwise fashion with advancing age after menopause.

The increase in risk with body-mass index (BMI) has been somewhat modest in the majority of studies [1292]. Above a BMI of 24 kg/m², the incidence rate increases among postmenopausal women. The greatest slope of increases in risk across higher BMI levels is in low and moderate risk countries suggesting that increases in BMI now being observed in those countries may become a major factor contributing to future increases in breast cancer rates.

While risk ratios have levelled off at BMI levels near 25 kg/m² in high risk countries, this is not the case in low to moderate risk countries, where risk has continued to increase across a wider range of body weight. The association between BMI and breast cancer is stronger among women who have never used postmenopausal hormone replacement therapy, suggesting that the risk from being overweight may be mediated by the elevations in endogenous estrogen production among heavier women. Adult weight gain is a strong and consistent predictor of postmenopausal breast cancer risk particularly among women who have never used hormone replacement therapy [1292].

In populations with a high incidence of breast cancer, the overall association between BMI and breast cancer risk among premenopausal women is the inverse. The reduction in risk with excessive weight is modest and not observed until a BMI of 28 kg/m². Despite this, however, the breast cancer mortality rate is not lower among heavier premenopausal women [1292].

Physical activity

The association between physical activity and breast cancer risk is independent of menopausal status [1292]. The decrease in risk among the most physically active women was about 20-40%. Activity that is sustained throughout lifetime, or at a minimum performed after menopause, may be particularly beneficial. It appears that physical activity has

similar effects within different populations. Although lifetime physical activity is desirable, beginning recreational physical activity after the menopause can probably be beneficial for both weight control and breast cancer risk reduction [1292].

Endogenous hormones

There is overwhelming evidence from epidemiological studies that sex steroids (androgens, estrogens, progestogens) have an important role in the development of breast tumours. Breast cancer incidence rates rise more steeply with age before menopause than after, when ovarian synthesis of estrogens and progesterone ceases and ovarian androgen production gradually diminishes [1447].

The estrogen excess hypothesis is central, stipulating that breast cancer risk depends directly on breast tissue exposure to estrogens. In vitro studies show increased breast cell proliferation and inhibition of apoptosis. Animal studies show increased rates of tumour development when estrogens are administered. The risk is higher among postmenopausal women who have elevated plasma levels of testosterone and androstenedione, reduced levels of sex hormone-binding globulin (SHBG), and increased levels of oestrone, oestradiol, and bioavailable oestradiol not bound to SHBG.

A second major theory, the estrogen plus progestogen hypothesis [255, 1446], postulates that, compared to exposure to estrogens alone (as in postmenopausal women not using exogenous hormones), risk of breast cancer is further increased in women who have elevated plasma and tissue levels of estrogens in combination with progestogens. This theory is supported by observations that proliferation of mammary epithelial cells is increased during the luteal phase of the menstrual cycle, compared to the follicular phase.

Among premenopausal women, several studies have not shown any clear association between breast cancer risk and circulating levels of androgens, estrogens, or progesterone [255,1183,2448, 2613,2909].

A metabolic consequence of excess body weight and lack of physical activity is development of insulin resistance. Elevated insulin levels, may lead to increased ovarian and/or adrenal synthesis of sex steroids, particularly of andro-

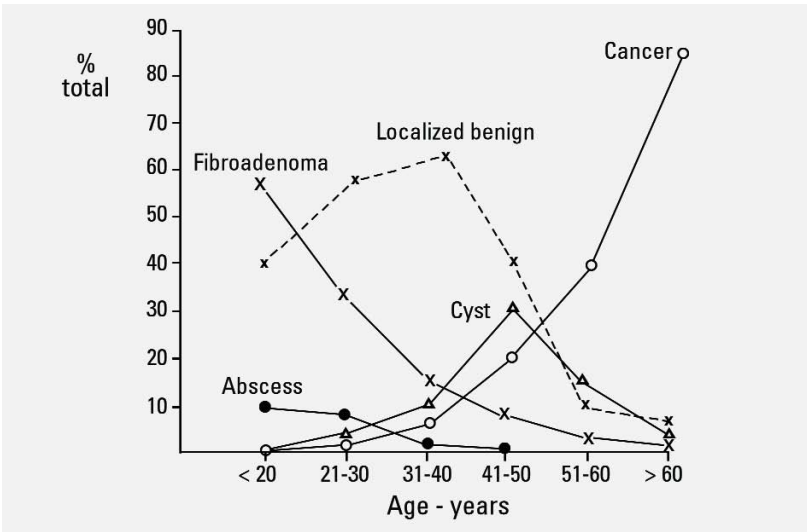


Fig. 1.07 Age distribution of benign and malignant breast lesions in patients presenting with a discrete breast lump. From Dixon and Sainsbury [707].

gens, and decrease the hepatic synthesis and circulating levels of SHBG [1376]. Especially in postmenopausal women, elevated plasma androgens lead to increased estrogen formation in adipose tissue, and hence to increased levels of oestrone and oestradiol. The hypothesis that chronic hyperinsulinemia might explain the observed associations of breast cancer risk with low plasma SHBG and elevated androgens and estrogens, among postmenopausal women [1376] has, however, received only limited support [661,1377]. Insulin-growth factor-I (IGF-I) and IGF-binding proteins (IGFBP) appear to be significant risk predictors [1127,1377].

Future adult cancer risk is in part set by conditions of exposure in utero. The preventive effect of gravidic toxemia is recognized [1288] and since the 1950s studies have incriminated high birth weight as a risk factor for cancer, in particular of the breast [1857]. Similarly, among twins, the risk of breast cancer may be affected by the type of twinning (dizygotic versus monozygotic) and sex of the dizygotic twin [429]. A study of maternal pregnancy hormone levels in China and the United States of America (USA) did not find, however, the expected higher levels in the USA but rather the reverse [1676]. Another important period is adolescence, where diet may play a role either directly or possibly indirectly through a modification of growth velocity [242].

Some specific exposures

Only limited data is available on specific exposures in relation to breast cancer. Long-term follow-up of women exposed to the Hiroshima or Nagasaki nuclear explosions indicates an increased risk of breast cancer, in particular for women exposed around puberty [2938]. Similarly, exposure as a result of treatment and surveillance of tuberculosis is associated with risk [304]. Yet there is little evidence for a different pattern of risk as a function of fractionated versus one time only irradiation [1678]. Systematic reviews on occupation and breast cancer are few, indicating an increased risk for selected occupations and specific chemical and physical exposures. This data contrasts with the long-held view that risk of breast cancer is related to social class, with higher risk for execu-

Table 1.01
Frequency of symptoms of women presenting in a breast clinic [288,698].

Lump	60-70%
Pain	14-18%
Nipple problems	7-9%
Deformity	1%
Inflammation	1%
Family history	3-14%

tives, administrative and clerical jobs [387]. A recent hypothesis deals with circadian disruption through night work, with an increased risk in women working predominantly at night [632,2556]. Over the last ten years concerns have arisen as to the potential risks of exposure to, not only hormones, but to artificial products mimicking hormonal activities. This led to the concept of xeno-hormones, mostly represented so far by xeno-estrogens. The exact role they play is unknown. Most epidemiological studies deal with various pesticides, essentially organochlorines which remain in the environment for a very long time and the residues of which may be found in adipose tissue of various species, including humans [628]. Studies have produced conflicting results with some suggesting a possibly increased risk, some no risk and others showing a negative effect. For the time being, many consider these links as speculative and unfounded [1951,2503] or as markers of susceptibility [1951]. Finally, based on animal experience, a viral hypothesis has been put forward. In mice, a retrovirus, the murine mammary

Table 1.02
Conditions requiring referral to a specialist clinic.

Lump
Any new discreet mass
A new lump in pre-existing nodularity
Asymmetrical nodularity that persists at review after menstruation
Abscess on breast inflammation which does not settle after one course of antibiotics
Cyst persistently refilling or recurrent cyst (if the patient has recurrent multiple cysts and the GP has the necessary skills, then aspiration is acceptable)
Pain
If associated with a lump
Intractable pain that interferes with a patient's lifestyle or sleep and which has failed to respond to reassurance, simple measures such as wearing a well supporting brassiere and common drugs
Unilateral persistent pain in postmenopausal women
Nipple discharge
All women > 50
Women < 50 with:
bilateral discharge sufficient to stain clothes
bloodstained discharge
persistent single duct discharge
Nipple retraction, distortion, eczema
Change in skin contour
Family history of breast cancer

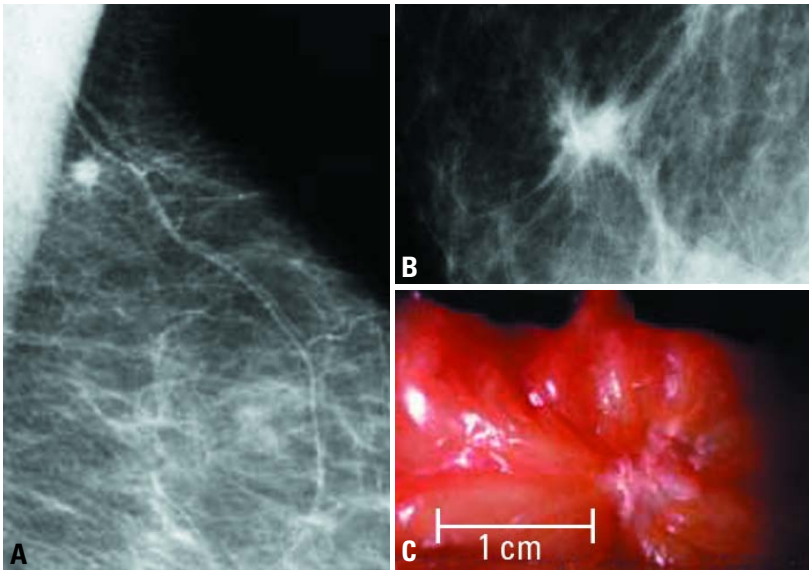


Fig. 1.08 **A** Mammogram of infiltrating carcinoma, clinically occult, less than 1 cm. **B** Mammographic detail of small, non-palpable, infiltrating carcinoma (<1 cm). **C** Macroscopic picture.

tumour virus, is a recognized cause of mammary tumours, transmitted with milk from mothers to daughters. Another candidate is the Epstein-Barr virus, although data from the USA are not particularly supportive [1015]. Other potential viral candidates remain to be searched for.

Localization

Breast carcinoma arises from the mammary epithelium and most frequently the epithelial cells of the TDLU. There is a slightly higher frequency of invasive breast cancer in the left breast with a reported left to right ratio of approximately 1.07 to 1 [1096]. Between 40 and 50% of tumours occur in the upper outer quadrant of the breast and there is a decreasing order of frequency in the other quadrants from the central, upper inner, lower outer to the lower inner quadrant [1096].

Clinical features

Symptoms and signs

The majority of women with breast cancer present symptomatically, although the introduction of breast screening has led to an increasing proportion of asymptomatic cases being detected mammographically. Breast cancer does not have specific signs and symptoms, which allow reliable distinction from various forms of benign breast disease. However, the frequency distribution of

benign and malignant disease does differ between age cohorts, benign conditions being more common in younger women and breast cancer the commonest cause of symptoms in older women. The most common findings in symptomatic women are breast lumps, which may or may not be associated with pain. Nipple abnormalities (discharge, retraction, distortion or eczema) are less common and other forms of presentation are rare. Some symptoms have a higher risk of underlying malignancy for which hospital referral is recommended. Breast abnormalities should be evaluated by triple assessment including clinical examination, imaging (mammography and ultrasound) and tissue sampling by either fine needle aspiration cytology or needle core biopsy. Clinical examination should be systematic and take account of the nature of the lump and, if present, any skin dimpling or change in contour of the breast and also assessment of the axilla.

Imaging

Imaging should include mammography except in women under age 35, where it is rarely of value, unless there is strong clinical suspicion or tissue/needle biopsy evidence of malignancy. The mammographic appearances of breast carcinoma are varied and include well defined, ill defined and spiculate

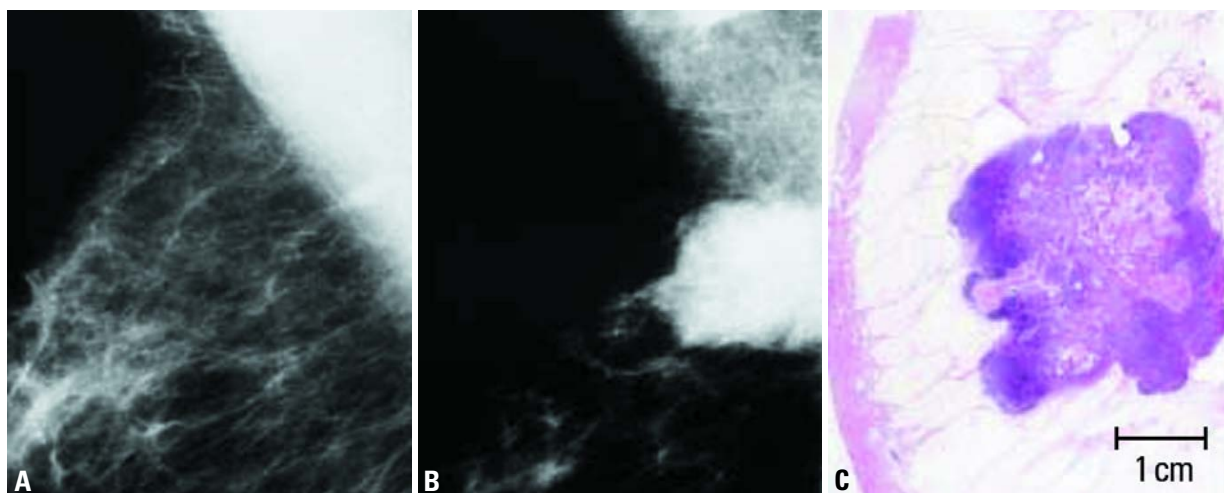


Fig. 1.09 Mammographic demonstration of the evolution of a poorly differentiated invasive ductal carcinoma, a circular tumour mass on the mammogram. **A** Non-specific density in the axillary tail of the right breast, undetected at screening. **B** 18 Months later: >30 mm ill defined, high density lobulated tumour, mammographically malignant. Metastatic lymph nodes are seen in the axilla. **C** Large section histology of the tumour.

masses, parenchymal deformity and calcification with or without a mass lesion. By far the most common manifestation of breast cancer on the mammogram is tumour mass without calcifications. The mammographic histological correlation of 1,168 open surgical biopsies at Falun Central Hospital, Sweden, included 866

Table 1.03

Mammographic appearance of histologically malignant breast lesions.

Stellate and circular without calcifications	64%
Stellate and circular with calcifications	17%
Calcifications only	19%

Table 1.04

Spectrum of histological diagnosis corresponding to mammographic circular/oval lesions.

Invasive ductal carcinoma, NOS	59%
Medullary carcinoma	8%
Mucinous carcinoma	7%
Intracystic carcinoma	5%
Tubular carcinoma	4%
Invasive lobular carcinoma	4%
Other diagnoses	13%

histologically proven malignancies. As seen in Table 1.03, the mammograms of these breast cancer showed:

- 1) Stellate or circular tumour mass with no associated calcifications in 64% of the cases.
- 2) An additional 17% had both calcifications and tumour mass.
- 3) Only calcifications without associated tumour mass accounted for less than 20% of all malignancies detectable on the mammogram.

Grading of invasive carcinoma

Invasive ductal carcinomas and all other invasive tumours are routinely graded based on an assessment of tubule/gland formation, nuclear pleomorphism and mitotic counts.

Many studies have demonstrated a significant association between histological grade and survival in invasive breast carcinoma. It is now recognized as a powerful prognostic factor and should be included as a component of the minimum data set for histological reporting of breast cancer [779,1190]. Assessment of histological grade has become more objective with modifications of the Patley & Scarff [2195] method first by Bloom and Richardson [293] and more recently by Elston and Ellis [777,2385].

Method of grading

Three tumour characteristics are evaluated; tubule formation as an expression of glandular differentiation, nuclear pleomor-

phism and mitotic counts. A numerical scoring system of 1-3 is used to ensure that each factor is assessed individually.

When evaluating tubules and glandular acini only structures exhibiting clear central lumina are counted; cut off points of 75% and 10% of glandular/tumour area are used to allocate the score.

Nuclear pleomorphism is assessed by reference to the regularity of nuclear size and shape of normal epithelial cells in adjacent breast tissue. Increasing irregularity of nuclear outlines and the number and size of nucleoli are useful additional features in allocating scores for pleomorphism.

Evaluation of mitotic figures requires care and observers must count only defined mitotic figures; hyperchromatic and pyknotic nuclei are ignored since they are more likely to represent apoptosis than proliferation. Mitotic counts require standardization to a fixed field area or by using a grid system [1984]. The total number of mitoses per 10 high power fields. Field selection for mitotic scoring should be from the peripheral leading edge of the tumour. If there is heterogeneity, regions exhibiting a higher frequency of mitoses should be chosen. Field selection is by random meander through the chosen area. Only fields with a representative tumour cell burden should be assessed.

The three values are added together to produce scores of 3 to 9, to which the grade is assigned as follows:

Grade 1 - well differentiated: 3-5 points
Grade 2 - moderately differentiated: 6-7 points
Grade 3 - poorly differentiated: 8-9 points

Invasive ductal carcinoma, not otherwise specified (NOS)

Definition
Invasive ductal carcinoma, not otherwise specified (ductal NOS) comprises the largest group of invasive breast cancers. It is a heterogeneous group of tumours that fail to exhibit sufficient characteristics to achieve classification as a specific histological type, such as lobular or tubular carcinoma.

ICD-O code 8500/3

Synonyms and historical annotation
Invasive ductal carcinoma, no specific type (ductal NST); infiltrating ductal carcinoma.
Many names have been used for this form of breast carcinoma including scirrhous carcinoma, carcinoma simplex and spheroidal cell carcinoma. Infiltrating ductal carcinoma is used by the Armed Forces Institute of Pathology {1832,2442} and was the nomenclature adopted in the previous WHO classifica-

Table 1.05
Semi-quantitative method for assessing histological grade in breast. From Elston and Ellis{777}.

Feature	Score
Tubule and gland formation	
Majority of tumour (>75%)	1
Moderate degree (10-75%)	2
Little or none (<10%)	3
Nuclear pleomorphism	
Small, regular uniform cells	1
Moderate increase in size and variability	2
Marked variation	3
Mitotic counts	
Dependent on microscope field area	1-3

Examples of assignment of points for mitotic counts for three different field areas:

Field diameter (mm)	0.44	0.59	0.63
Field area (mm ²)	0.152	0.274	0.312
Mitotic count*			
1 point	0-5	0-9	0-11
2 points	6-10	10-19	12-22
3 points	>11	>20	>23

tion {2548,3154}. This perpetuates the traditional concept that these tumours are derived exclusively from mammary ductal epithelium in distinction from lobular carcinomas, which were deemed to have arisen from within lobules for which there is no evidence. In addition it has been shown that the terminal duct-lobular unit (TDLU) should be regarded as a

single entity from the point of view of the site of origin of most breast carcinomas {147,3091}. Some groups {874,2325} have retained the term ductal but added the phrase 'not otherwise specified (NOS)', whilst others {2147} prefer to use 'no specific type (NST)' to emphasize their distinction from specific type tumours. This latter view is increasingly

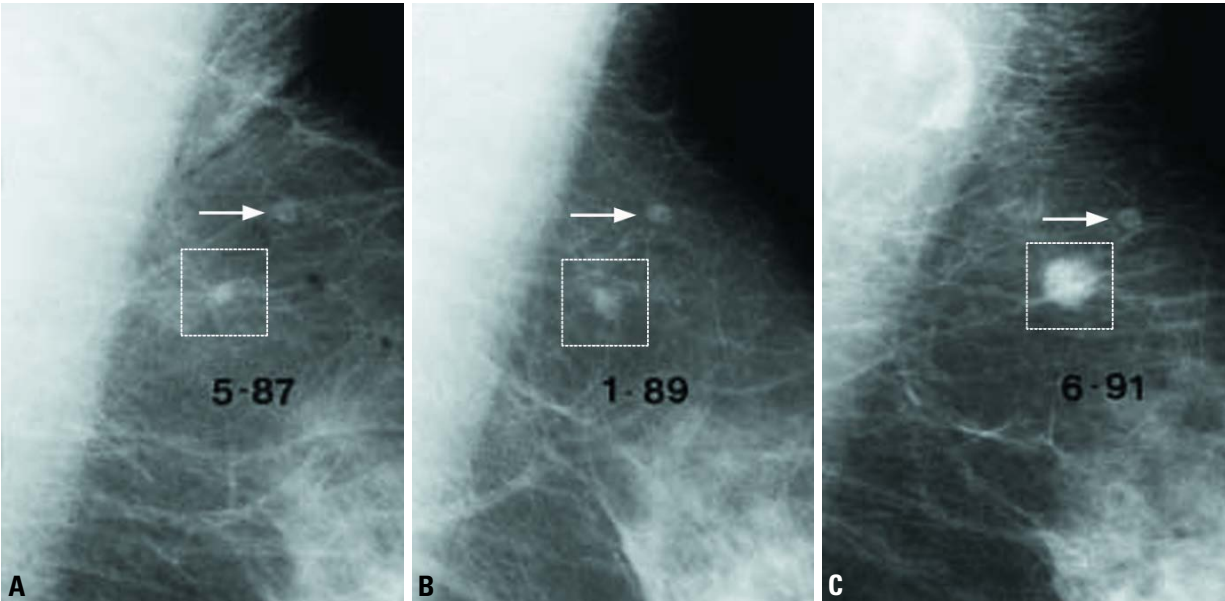


Fig. 1.10 Well differentiated infiltrating ductal carcinoma, Grade 1. **A** First screen. Intramammary lymph node and small (<5 mm), nonspecific density. **B** Second screen: 20 months later. The density has grown a little. **C** Third screen: after another 29 months. The 10 mm tumour is more obvious but still not palpable.

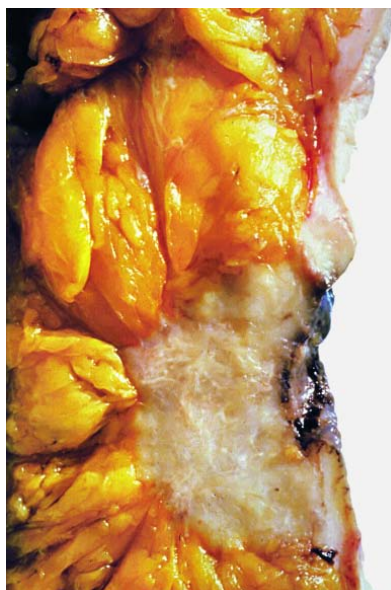

Fig. 1.11 Invasive ductal carcinoma, not otherwise specified. 84 year old patient, mastectomy specimen.

accepted internationally, but since 'ductal' is still widely used the terms invasive ductal carcinoma, ductal NOS or NST are preferred terminology options.

Epidemiology

Ductal NOS carcinoma forms a large proportion of mammary carcinomas and its epidemiological characteristics are similar to those of the group as a whole (see epidemiology). It is the most common 'type' of invasive carcinoma of the breast comprising between 40% and 75% in published series [774]. This wide range is possibly due to the lack of application of strict criteria for inclusion in the special types and also the fact that some groups do not recognize tumours with a combination of ductal NOS and special type patterns as a separate

mixed category, preferring to include them in the no special type (ductal NOS) group.

Ductal NOS tumours, like all forms of breast cancer, are rare below the age of 40 but the proportion of tumours classified as such in young breast cancer cases is in general similar to older cases [1493]. There are no well recognized differences in the frequency of breast cancer type and proportion of ductal NOS cancers related to many of the known risk factors including geographical, cultural/lifestyle, reproductive variables (see aetiology). However, carcinomas developing following diagnosis of conditions such as atypical ductal hyperplasia and lobular neoplasia, recognized to be associated with increased risk include a higher proportion of tumours of specific type specifically tubular and classical lobular carcinoma [2150]. Familial breast cancer cases associated with *BRCA1* mutations are commonly of ductal NOS type but have medullary carcinoma like features, exhibiting higher mitotic counts, a greater proportion of the tumour with a continuous pushing margin, and more lymphocytic infiltration than sporadic cancers [1572]. Cancers associated with *BRCA2* mutations are also often of ductal NOS type but exhibit a high score for tubule formation (fewer tubules), a higher proportion of the tumour perimeter with a continuous pushing margin and a lower mitotic count than sporadic cancers [1572].

Macroscopy

These tumours have no specific macroscopical features. There is a marked variation in size from under 10 mm to over 100 mm. They can have an irregular, stellate outline or nodular configuration. The tumour edge is usually moderately or ill defined and lacks sharp circumscription.

Classically, ductal NOS carcinomas are firm or even hard on palpation, and may have a curious 'gritty' feel when cut with a knife. The cut surface is usually grey-white with yellow streaks.

Histopathology

The morphological features vary considerably from case to case and there is frequently a lack of the regularity of structure associated with the tumours of specific type. Architecturally the tumour cells may be arranged in cords, clusters and trabeculae whilst some tumours are characterized by a predominantly solid or syncytial infiltrative pattern with little associated stroma. In a proportion of cases glandular differentiation may be apparent as tubular structures with central lumina in tumour cell groups. Occasionally, areas with single file infiltration or targetoid features are seen but these lack the cytomorphological characteristics of invasive lobular carcinoma. The carcinoma cells also have a variable appearance. The cytoplasm is often abundant and eosinophilic. Nuclei may be regular, uniform or highly pleomorphic with prominent, often multiple, nucleoli, mitotic activity may be virtually absent or extensive. In up to 80% of cases foci of associated ductal carcinoma in situ (DCIS) will be present [147,2874]. Associated DCIS is often of high grade comedo type, but all other patterns may be seen.

Some recognize a subtype of ductal NOS carcinoma, infiltrating ductal carcinoma with extensive in situ component. The stromal component is extremely variable. There may be a highly cellular fibroblastic proliferation, a scanty connective tissue element or marked hyalinisation. Foci of elastosis may also be present, in a periductal or perivenous distribution. Focal necrosis may be pres-

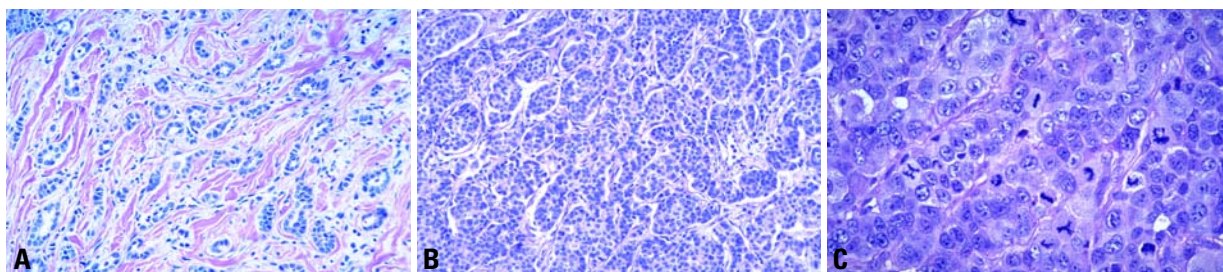


Fig. 1.12 **A** Infiltrating ductal carcinoma, grade I. **B** Infiltrating ductal carcinoma, grade II. **C** Invasive ductal NOS carcinoma, grade III with no evidence of glandular differentiation. Note the presence of numerous cells in mitosis, with some abnormal mitotic figures present.

ent and this is occasionally extensive. In a minority of cases a distinct lymphoplasmacytoid infiltrate can be identified.

Mixed type carcinoma

For a tumour to be typed as ductal NOS it must have a non-specialized pattern in over 50% of its mass as judged by thorough examination of representative sections. If the ductal NOS pattern comprises between 10 and 49% of the tumour, the rest being of a recognized special type, then it will fall into one of the mixed groups: mixed ductal and special type or mixed ductal and lobular carcinoma. Apart from these considerations there are very few lesions that should be confused with ductal NOS carcinomas.

Pleomorphic carcinoma

ICD-O code 8022/3

Pleomorphic carcinoma is a rare variant of high grade ductal NOS carcinoma characterized by proliferation of pleomorphic and bizarre tumour giant cells comprising >50% of the tumour cells in a background of adenocarcinoma or adenocarcinoma with spindle and squamous differentiation [2683]. The patients range in age from 28 to 96 years with a median of 51. Most patients present with a palpable mass; in 12% of cases, metastatic tumour is the first manifestation of disease. The mean size of the tumours is 5.4 cm. Cavitation and necrosis occur in larger tumours.

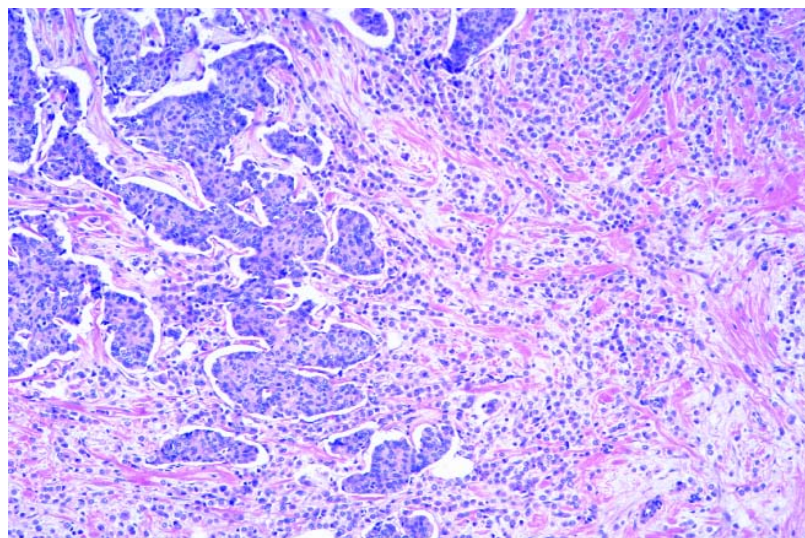


Fig. 1.13 Mixed infiltrating ductal and infiltrating lobular carcinoma. Two distinct morphologic patterns are seen in this tumour, ductal on the left and lobular on the right.

The tumour giant cells account for more than 75% of tumour cells in most cases. Mitotic figures exceed 20 per 10 high power fields. All these tumours qualify as grade 3 carcinomas. The intraepithelial component displays a ductal arrangement and is often high grade with necrosis. Lymphovascular invasion is present in 19% of cases.

Generally BCL2, ER and PR negative, two thirds of these pleomorphic carcinomas are TP53 positive, and one third are S-100 protein positive. All are positive for CAM5.2, EMA and pan-cytokeratin (AE1/AE3, CK1). A majority (68%) is aneuploid with 47% of them being triploid. A

high S-phase (>10%) is found in 63%. Axillary node metastases are present in 50% of the patients with involvement of 3 or more nodes in most. Many patients present with advanced disease.

Carcinoma with osteoclastic giant cells

ICD-O code 8035/3

The common denominator of all these carcinomas is the presence of osteoclastic giant cells in the stroma [1089]. The giant cells are generally associated with an inflammatory, fibroblastic, hyper-

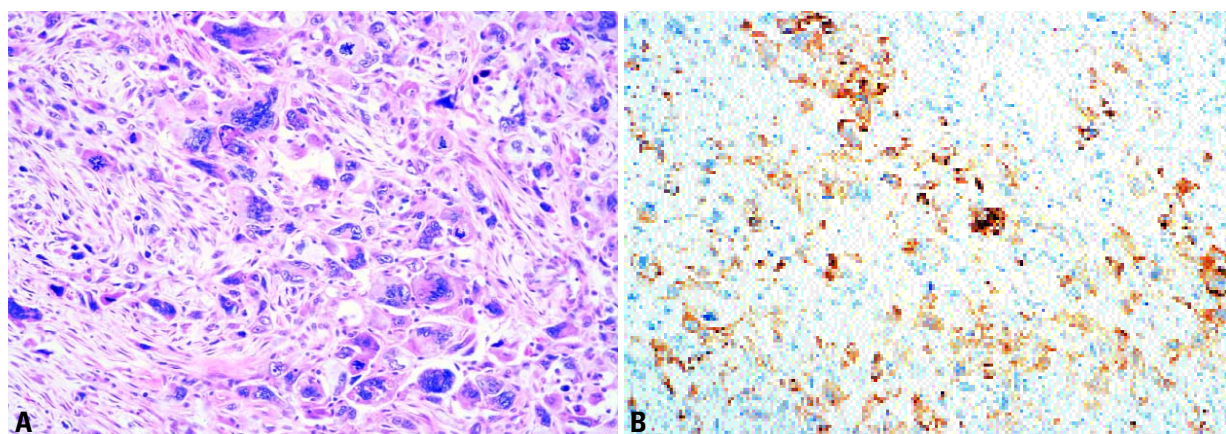


Fig. 1.14 Invasive ductal carcinoma: pleomorphic carcinoma. **A** Poorly differentiated cells without distinctive architecture often lead to misinterpretation of the lesion as a sarcoma. **B** Immunostain for keratin (AE1/AE3 and LP34) confirms the epithelial nature of the process.

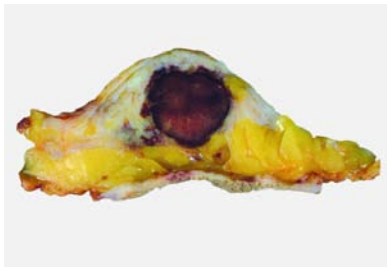


Fig. 1.15 Invasive carcinomas with stromal osteoclastic giant cells often have vascular stromal tissue with haemosiderin pigment accumulation giving them a brown macroscopic appearance.

vascular stroma, with extravasated red blood cells, lymphocytes, monocytes along with mononucleated and binucleated histiocytes some containing haemosiderin. The giant cells are variable in size and appear to embrace the epithelial component or are found within lumina formed by the cancer cells. The giant cells contain a variable number of nuclei. The giant cells and hypervascular reactive stroma can be observed in lymph node metastases and in recurrences [2952].

The carcinomatous part of the lesion is most frequently a well to moderately differentiated infiltrating ductal carcinoma but all the other histological types have been observed particularly invasive cribriform carcinoma [2003,2241], and also tubular, mucinous, papillary [3062], lobular [1274,2837], squamous and other metaplastic patterns [1200,2044,3062].

About one-third of the reported cases had lymph nodes metastasis. The five

year survival rate is around 70%, similar to, or better than, patients with ordinary infiltrating carcinomas [3062]. Prognosis is related to the characteristics of the associated carcinoma and does not appear to be influenced by the presence of stromal giant cells.

The giant cells show uniform expression of CD68 (as demonstrated by KP1 antibody on paraffin sections) [1200] and are negative for S100 protein, actin, and negative for cytokeratin, EMA, estrogen and progesterone receptors [2869].

The giant cells are strongly positive for acid phosphatase, non-specific esterase and lysosyme, but negative for alkaline phosphatase indicative of morphological similarity to histiocytic cells and osteoclasts [2423,2869,2952,3025].

A number of ultrastructural and immunohistochemical studies have confirmed the histiocytic nature of the osteoclastic cells present in these unusual carcinomas [2632,2869,2952,3025]. In vitro studies have recently shown that osteoclasts may form directly from a precursor cell population of monocytes and macrophages. Tumour associated macrophages (TAMs) are capable of differentiating into multinucleated cells, which can affect bone resorption in metastases [2313]. Osteoclastic giant cells in carcinoma are probably also related to TAMs. Angiogenesis and chemotactic agents produced by the carcinoma may be responsible for the migration of histiocytes to the area involved by cancer and their ultimate transformation to osteoclastic giant cells [2638,2869].

Carcinoma with choriocarcinomatous features

Patients with ductal NOS carcinoma may have elevated levels of serum human chorionic gonadotrophin (-HCG) [2649] and as many as 60% of ductal NOS carcinoma have been found to contain -HCG positive cells [1243]. Histological evidence of choriocarcinomatous differentiation, however, is exceptionally rare with only a few cases reported [993,1061,2508]. All were in women between 50 and 70 years old.

Carcinoma with melanotic features

A few case reports have described exceptional tumours of the mammary parenchyma that appear to represent combinations of ductal carcinoma and malignant melanoma [2031,2146,2485] and in some of these cases, there appeared to be a transition from one cell type to the other. A recent genetic analysis of one such case showed loss of heterozygosity at the same chromosomal loci in all the components of the tumour, suggesting an origin from the same neoplastic clone [2031].

The mere presence of melanin in breast cancer cells should not be construed as evidence of melanocytic differentiation, since melanin pigmentation of carcinoma cells can occur when breast cancers invade the skin and involve the dermoepidermal junction [150]. In addition, care must be taken to distinguish tumours showing melanocytic differentiation from breast carcinomas with prominent cytoplasmic lipofuscin deposition [2663].

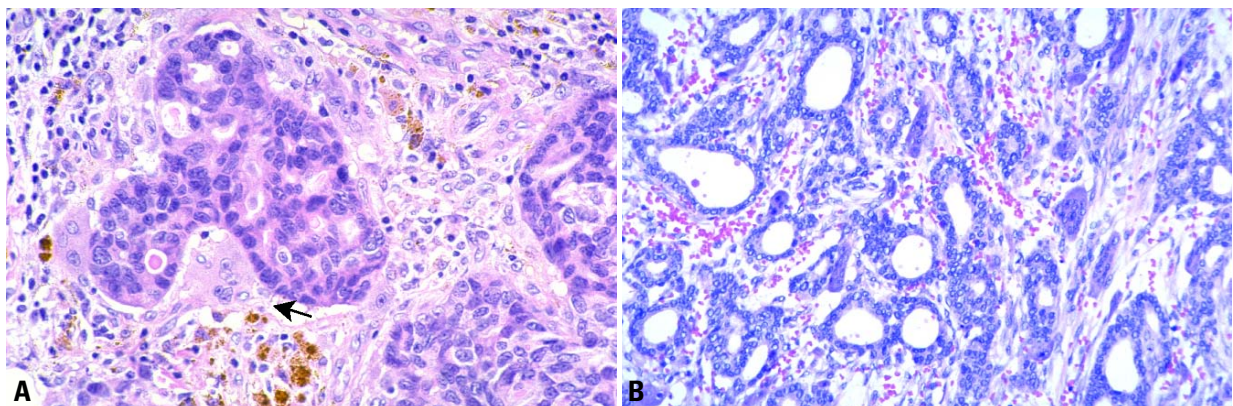


Fig. 1.16 **A** Invasive ductal carcinoma with stromal osteoclastic giant cells and haemosiderin-laden macrophages. **B** The invasive ductal carcinoma is low grade. Multinucleated giant cells are evident in the stroma.

Most melanotic tumours of the breast represent metastases from malignant melanomas originating in extra-mammary sites [2694]. Primary melanomas may arise anywhere in the skin of the breast, but an origin in the nipple-areola complex is extremely rare [2168]. The differential diagnosis of malignant melanoma arising in the nipple areolar region must include Paget disease, the cells of which may on occasion contain melanin pigment [2544]. This is discussed in the section on Paget disease.

Genetics

The genetic variation seen in breast cancer as a whole is similarly reflected in ductal NOS tumours and has until recently proved difficult to analyse or explain. The increasing accumulation of genetic alterations seen with increasing grade (decreasing degree of differentiation) has been used to support the hypothesis of a linear progression model in this type and in invasive breast cancer as a whole. The recent observation by a number of groups that specific genetic lesion or regions of alteration are associated with histological type of cancer or related to grade in the large ductal NOS group does not support this view. It implies that breast cancer of ductal NOS type includes a number of tumours of unrelated genetic evolutionary pathways [365] and that these tumours show fundamental differences when compared to some special type tumours including lobular [1085] and tubular carcinoma [2476]. Furthermore, recent cDNA microarray analysis has demonstrated that ductal NOS tumours can be classified in to subtypes on the basis of expression patterns [2218,2756].

Prognosis and predictive factors

Ductal NOS carcinoma forms the bulk (50-80%) of breast cancer cases and its prognostic characteristics and management are similar or slightly worse with a 35-50% 10 year survival [771] compared to breast cancer as a whole with around a 55% 10 year survival. Prognosis is influenced profoundly by the classical prognostic variables of histological grade, tumour size, lymph node status and vascular invasion (see general discussion of prognosis and predictive factors at the end of this chapter) and by predictors of therapeutic response such as estrogen receptor and ERBB2 status.

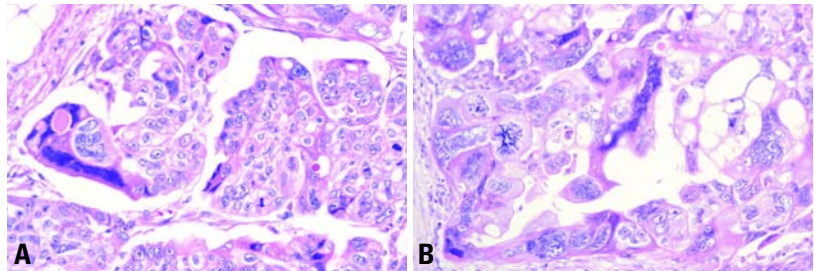


Fig. 1.17 Carcinoma with choriocarcinomatous features. **A,B** Multinucleated tumour cells with smudged nuclei extend their irregular, elongated cytoplasmic processes around clusters of monocytic tumour cells, mimicking the biphasic growth pattern of choriocarcinoma. **B** Note the abnormal mitotic figures in this high grade carcinoma.

Approximately 70-80% of ductal NOS breast cancers are estrogen receptor positive and between 15 and 30% of cases ERBB2 positive. The management of ductal NOS carcinomas is also influenced by these prognostic and predictive characteristics of the tumour as well as focality and position in the breast.

Invasive lobular carcinoma

Definition

An invasive carcinoma usually associated with lobular carcinoma in situ is composed of non-cohesive cells individually dispersed or arranged in single-file linear pattern in a fibrous stroma.

ICD-O code 8520/3

Epidemiology

Invasive lobular carcinoma (ILC) represents 5-15% of invasive breast tumours [725,771,1780,2541,2935,3133]. During the last 20 years, a steady increase in its incidence has been reported in women over 50 [1647], which might be attributable to the increased use of hormone replacement therapy [312,1648,2073]. The mean age of patients with ILC is 1-3 years older than that of patients with infiltrating ductal carcinoma (IDC) [2541].

Clinical features

The majority of women present with a palpable mass that may involve any part of the breast although centrally located tumours were found to be slightly more common in patients with ILC than with IDC [3133]. A high rate of multicentric tumours has been reported by some [699,1632] but this has not been found in other series based on clinical [2541] or

radiological [1599] analysis (see bilateral breast carcinoma section). An 8-19% incidence of contralateral tumours has also been reported [699,725,834], representing an overall rate of 13.3 %. This may be higher than that for IDC [1241,2696]. However, no significant difference in the rate of bilaterality was observed in other series of cases [648,1168,2186]. At mammography, architectural distortion is more commonly observed in ILC than in IDC whereas microcalcifications are less common in ILC [895,1780,3066].

Macroscopy

ILC frequently present as irregular and poorly delimited tumours which can be difficult to define macroscopically because of the diffuse growth pattern of the cell infiltrate [2696]. The mean diameter has been reported to be slightly larger than that of IDC in some series [2541,2696,3133].

Histopathology

The classical pattern of ILC [895,1780,3066] is characterized by a proliferation of small cells, which lack cohesion

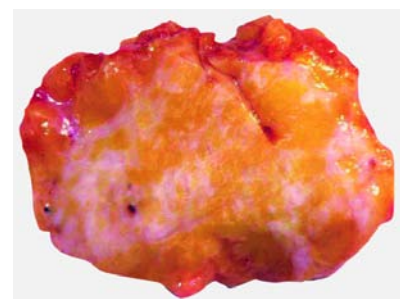


Fig. 1.18 Macroscopy of an invasive lobular carcinoma displays an ill defined lesion.

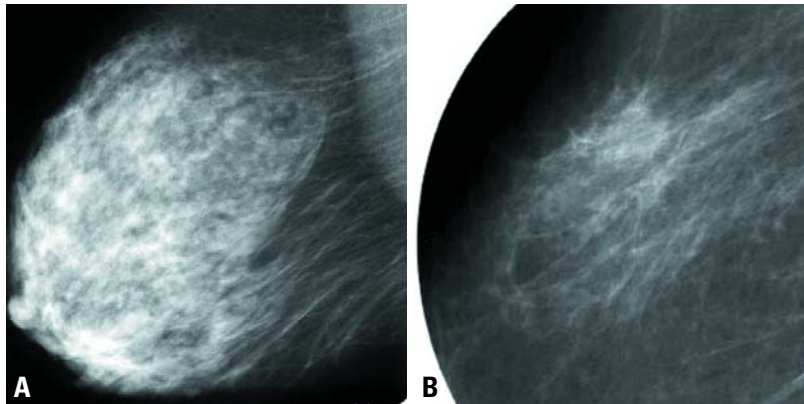


Fig. 1.19 Mammography of invasive lobular carcinoma. **A** Architectural distortion in the axillary tail, corresponding to a palpable area of thickening. **B** Magnification view of the architectural axillary distortion.

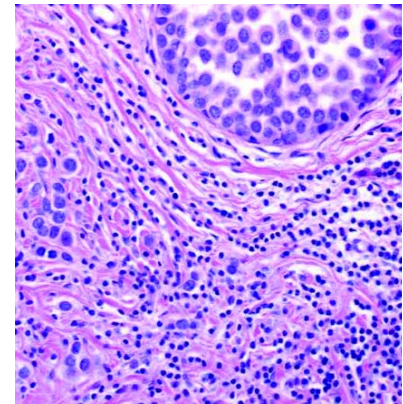


Fig. 1.20 In situ and invasive lobular carcinoma. The larger cells on the left and lower part of the field are invasive tumour cells.

and appear individually dispersed through a fibrous connective tissue or arranged in single file linear cords that invade the stroma. These infiltrating cords frequently present a concentric pattern around normal ducts. There is often little host reaction or disturbance of the background architecture. The neoplastic cells have round or notched ovoid nuclei and a thin rim of cytoplasm with an occasional intracytoplasmic lumen [2312] often harbouring a central mucoid inclusion. Mitoses are typically infrequent. This classical form of ILC is associated with features of lobular carcinoma in situ in at least 90% of the cases [705,2001].

In addition to this common form, variant patterns of ILC have been described. The *solid pattern* is characterized by sheets of uniform small cells of lobular morphology [835]. The cells lack cell to cell cohesion and are often more pleomorphic and have a higher frequency of mitoses than the classical type. In the *alveolar variant*, tumour cells are mainly

arranged in globular aggregates of at least 20 cells [2668], the cell morphology and growth pattern being otherwise typical of lobular carcinoma. *Pleomorphic lobular carcinoma* retains the distinctive growth pattern of lobular carcinoma but exhibits a greater degree of cellular atypia and pleomorphism than the classical form [808,1858,3082]. Intra-lobular lesions composed of signet ring cells or pleomorphic cells are features frequently associated with it. Pleomorphic lobular carcinoma may show apocrine [808] or histiocytoid [3047] differentiation. A mixed group is composed of cases showing an admixture of the classical type with one or more of these patterns [705]. In about 5% of invasive breast cancers, both ductal and lobular features of differentiation are present [1780] (see Mixed type carcinoma, page 21). Analysis of E-cadherin expression may help to divide these cases between ductal and lobular tumours but the immunophenotype remains ambiguous in a minority of cases [34].

The admixture of tubular growth pattern and small uniform cells arranged in a linear pattern defines tubulo-lobular carcinoma (TLC) (ICD-O 8524/3) [875]. LCIS is observed in about one third of TLC. Comparison of the clinico-pathological features of TLC and pure tubular carcinoma (TC) has shown that axillary metastases were more common in TLC (43%) than in TC (12%) [1062]. A high rate of estrogen receptor (ER) positivity has also been reported in TLC [3141]. Further analysis of TLC, especially regarding E-cadherin status, should help to determine whether TLC should be categorized as a variant of tubular or of lobular tumours. Without this data these tumours are best classified as a variant of lobular carcinoma.

Immunoprofile

About 70-95% of lobular carcinomas are ER positive, a rate higher than the 70-80% observed in IDC [2541,3235]. Progesterone receptor (PR) positivity is 60-70% in either tumour type [2541,

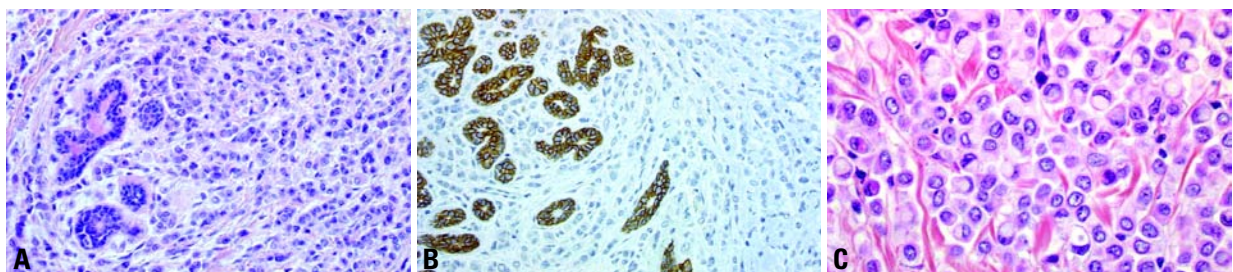


Fig. 1.21 **A** Invasive lobular carcinoma. **B** Loss of E-cadherin expression is typical of lobular carcinoma cells. Note immunoreactivity of entrapped normal lobules. **C** Large number of signet ring cells and intracytoplasmic lumina (targetoid secretion).

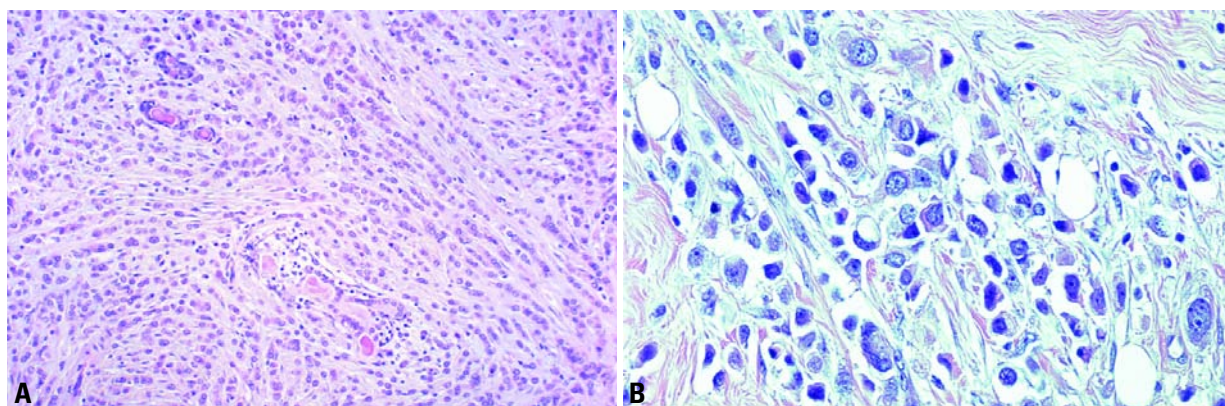


Fig. 1.22 **A** Classic invasive lobular carcinoma with uniform, single cell files compared to **(B)**. **B** Invasive pleomorphic lobular carcinoma with characteristic pleomorphic, atypical nuclei.

3235). ER was found to be expressed in the classical form and in variants [1994], but the rate of positivity was higher (100%) in alveolar [2668] and lower (10%) in pleomorphic ILC [2318] than in the classical type. The proliferation rate in ILC is generally low [2027]. With the exception of pleomorphic lobular carcinoma ERBB2 overexpression in ILC [2274,2477,2750], is lower than reported in IDC [2358].

Genetics

Using flow cytometry, ILCs were found near diploid in about 50% of the cases [887]. This fits with the finding that chromosomal abnormalities, assessed by cytogenetical [887] or comparative genomic hybridization (CGH) analysis [2027], are less numerous in ILC than in IDC. In ILC, the most common genetic alteration, found in 63-87% of the cases [887,2027], is a loss of the long arm of chromosome 16.

The E (epithelial)-cadherin gene, which maps in 16q22, is implicated in maintaining coherence of adult epithelial tissues [1217], and acts as a cell differentiation and invasion suppressor factor [922,3030]. A correlation has been found between deletion of 16q and the loss of E-cadherin expression [2027]. Immunohistochemical analysis has shown complete loss of E-cadherin expression in 80-100% of ILC [956,1892,2094,2152,2336]. This contrasts with the mere decrease in staining intensity observed in 30-60% of IDC.

Molecular analysis has shown that, in most cases, the lack of E-cadherin

immunostaining can be related to the presence of protein truncation mutations [260,1394,2380], together with the inactivation of the wild type allele. Alternative mechanisms may also be involved in the alteration of E-cadherin [723,3190] and/or of E-cadherin-associated proteins [723,1892,2337,2374].

Analysis of neoplastic lesions corresponding to early steps of tumour development has shown that both loss of heterozygosity of the 16q chromosomal region [800] and of E-cadherin expression [649,3034] were also observed in LCIS and in mixed ductal-lobular carcinoma [34]. Inactivation of the E-cadherin gene may thus represent an early event in oncogenesis and this biological trait indicates that LCIS is a potential precursor of ILC. However, other molecular events must be involved in the transition from in situ to invasive lobular tumours. Furthermore, genetic losses concerning other parts of the long arm of chromosome 16 than the locus of E-cadherin have been found in IDC and in ILC [2960], as well as in DCIS [460]. This strongly suggests that several genes localized in this chromosomal region, and presenting tumour suppressive properties, may be involved in breast oncogenesis.

A combination of mutation analysis and E-cadherin protein expression may offer a method for identification of lobular carcinoma.

Prognosis and predictive factors

A lower frequency of axillary nodal metastasis in ILC than in IDC has been reported in several series, the difference

ranging from 3-10% [1327,1578,2541,2696,2935]. Metastatic involvement by scattered isolated cells may simulate sinusoidal histiocytes and require immunohistochemical detection.

The metastatic pattern of ILC differs from that of IDC. A higher frequency of tumour extension to bone, gastro-intestinal tract, uterus, meninges, ovary and diffuse serosal involvement is observed in ILC while extension to lung is more frequent in IDC [319,1142,1327,2541,2696,2935]. IHC using antibodies raised against GCDPF-15, cytokeratin 7, ER, and E-cadherin may help establish a female genital tract tumour as a metastatic ILC. Several studies have reported a more favourable disease outcome for ILC than for IDC [705,725,771,2696,2935] whereas others found no significant differences [2205,2541,2696,2731] or a worse prognosis for ILC [126].

When the histological subtypes of ILC were analysed separately, a more favourable outcome was reported for the classical type than for variants [699,705,725]. However, alveolar ILC has been considered as a low grade tumour [2668], whereas a poor prognosis of pleomorphic ILC has been reported in some series [808,3082]. No difference in the outcome of different subtypes has been observed in other series [2935]. Furthermore, a large extent of lymph node involvement has not been found to increase significantly the risk of local relapse [2570]. A link between lack of E-cadherin expression and adverse outcome of the disease has also been reported [125,1176].

Treatment of ILC should depend on the stage of the tumour and parallel that of IDC. Conservative treatment has been shown to be appropriate for ILC [327, 2205,2269,2541,2570,2696].

Tubular carcinoma

Definition

A special type of breast carcinoma with a particularly favourable prognosis composed of distinct well differentiated tubular structures with open lumina lined by a single layer of epithelial cells.

ICD-O code 8211/3

Epidemiology

Pure tubular carcinoma accounts for under 2% of invasive breast cancer in most series. Higher frequencies of up to 7% are found in series of small T1 breast cancers. Tubular cancers are often readily detectable mammographically because of their spiculate nature and associated cellular stroma and are seen at higher frequencies of 9-19%, in mammographic screening series [1853, 2192,2322].

When compared with invasive carcinomas of no special type (ductal NOS), tubular carcinoma is more likely to occur in older patients, be smaller in size and have substantially less nodal involvement [691,1379,2166].

These tumours are recognized to occur in association with some epithelial proliferative lesions including well differentiated/low grade types of ductal carcinoma in situ (DCIS), lobular neoplasia and flat

epithelial atypia [915,1034]. In addition, an association with radial scar has been proposed [1668,2725].

Macroscopy

There is no specific macroscopical feature which distinguishes tubular carcinoma from the more common ductal no special type (NOS) or mixed types, other than small tumour size. Tubular carcinomas usually measure between 0.2 cm and 2 cm in diameter; the majority are 1 cm or less [772,1829,2081].

Two morphological subtypes have been described, the 'pure' type which has a pronounced stellate configuration with radiating arms and central yellow flecks due to stromal elastosis and the sclerosing type characterized by a more diffuse, ill defined structure [410,2190].

Histopathology

The characteristic feature of tubular carcinoma is the presence of open tubules composed of a single layer of epithelial cells enclosing a clear lumen. These tubules are generally oval or rounded and, typically, a proportion appears angulated. The epithelial cells are small and regular with little nuclear pleomorphism and only scanty mitotic figures. Multilayering of nuclei and marked nuclear pleomorphism are contraindications for diagnosis of pure tubular carcinoma, even when there is a dominant tubular architecture. Apical snouts are seen in as many as a third of the cases [2874], but are not pathognomonic. Myoepithelial cells are absent but some tubules may have an incomplete surrounding layer of basement membrane components.

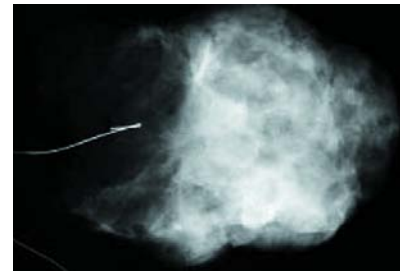

Fig. 1.23 Tubular carcinoma. Specimen X-ray.

A secondary, but important feature is the cellular desmoplastic stroma, which accompanies the tubular structures. Calcification may be present in the invasive tubular, associated in situ or the stromal components.

DCIS is found in association with tubular carcinoma in the majority of cases; this is usually of low grade type with a cribriform or micropapillary pattern. Occasionally, the in situ component is lobular in type. More recently an association has been described with flat epithelial atypia and associated micropapillary DCIS [915,1034].

There is a lack of consensus concerning the proportion of tubular structures required to establish the diagnosis of tubular carcinoma. In the previous WHO Classification [1,3154] and a number of published studies [410,1350, 1832] no specific cut-off point is indicated although there is an assumption that all the tumour is of a tubular configuration. Some authors have applied a strict 100% rule for tubular structures [409,552, 2190], some set the proportion of tubular structures at 75% [1668,1829, 2224,2442], and

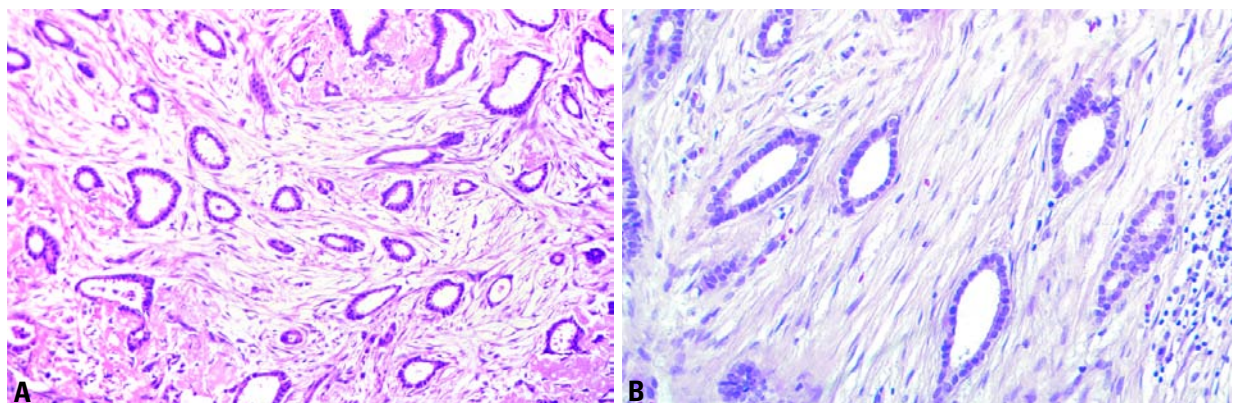


Fig. 1.24 Tubular carcinoma. **A** There is a haphazard distribution of rounded and angulated tubules with open lumens, lined by only a single layer of epithelial cells separated by abundant reactive, fibroblastic stroma. **B** The neoplastic cells lining the tear-drop shaped tubules lack significant atypia.

yet others at 90% [97,2147]. For pragmatic reasons, a 90% purity requirement offers a practical solution.

Tumours exhibiting between 50 and 90% tubular growth pattern with other types should be regarded as mixed type of carcinoma (see Mixed type carcinomas).

Differential diagnosis

Sclerosing adenosis (SA) can be distinguished from tubular carcinoma by its overall lobular architecture and the marked compression and distortion of the glandular structures. Myoepithelial cells are always present in sclerosing adenosis and can be highlighted by immunostaining for actin. Similarly, a fully retained basement membrane can be shown by immunohistological staining for collagen IV and laminin in tubules of SA. Microglandular adenosis (MA) can be more difficult to differentiate because of the rather haphazard arrangement of the tubules, and lack of myoepithelial cells in the tubules. However, the tubules of MA are more rounded and regular and often contain colloid-like secretory material, at least focally, compared to the often angulated tubules of tubular carcinoma. Furthermore a ring of basement membrane is present around tubules of MA. Complex sclerosing lesions/radial scars have a typical architecture with central fibrosis and elastosis containing a few small, often distorted, tubular structures in which myoepithelial cells can be demonstrated. The surrounding glandular structures show varying degrees of dilatation and ductal epithelial hyperplasia.

Immunophenotype

Tubular carcinoma is nearly always estrogen and progesterone receptor positive, has a low growth fraction, and is ERBB2 and EGFR negative [691, 1379,2166].

Genetics

Tubular carcinomas of the breast have a low frequency of genetic alterations when compared to other types of breast carcinoma. Using LOH and CGH techniques, alterations have been found most frequently at chromosomes 16q (loss), 1q (gain), 8p (loss), 3p FHIT gene locus, and 11q ATM gene locus [1754,1779,2476, 3046]. Of particular interest is the observation that other sites of chromosomal alteration previously found at high levels in other types

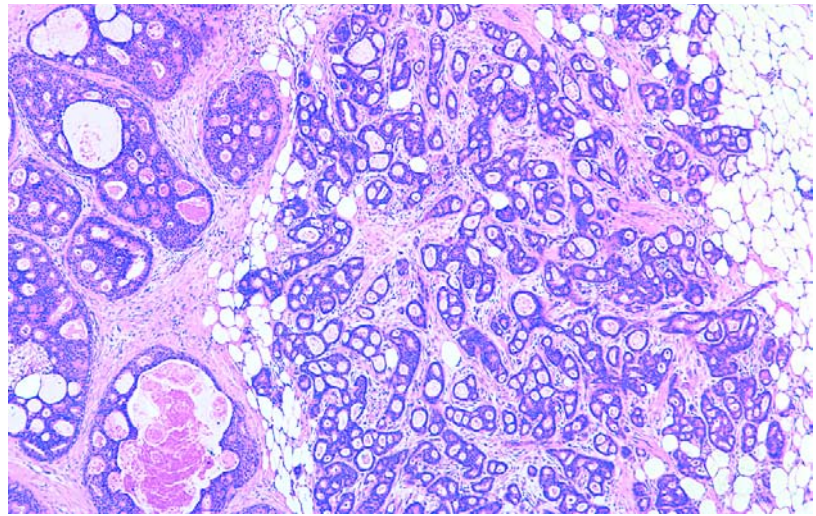


Fig. 1.25 Invasive cribriform carcinoma. The haphazard distribution of irregularly shaped and angulated invasive areas is in contrast with the rounded configuration of the ducts with cribriform DCIS on the left side of the field.

of breast cancer are not seen, which implies that tubular carcinoma of the breast is genetically distinct.

Prognosis and predictive factors

Pure tubular carcinoma has an excellent long term prognosis {409,410,552,771, 1829,2081,2224} which in some series is similar to age matched women without breast cancer [691]. Recurrence following mastectomy or breast conservation treatment is rare and localized tubular carcinomas are considered to be ideal candidates for breast conservation techniques. Following breast conservation, the risk of local recurrence is so low that some centres consider adjuvant radiotherapy unnecessary. Axillary node metastases occur infrequently, and when observed rarely involve more than one low axillary lymph node. There is little adverse effect of node positivity in tubular carcinoma [691,1471] and the use of systemic adjuvant therapy and axillary node dissection are considered unnecessary by some groups [691,2166].

Invasive cribriform carcinoma

Definition

An invasive carcinoma with an excellent prognosis that grows in a cribriform pattern similar to that seen in intraductal cribriform carcinoma; a minor (<50%) component of tubular carcinoma may be admixed.

ICD-O code 8201/3

Epidemiology

Invasive cribriform carcinoma (ICC) accounts for 0.8-3.5% of breast carcinomas. The mean age of patients is 53-58 years [2148,2670,3017].

Clinical features

The tumour may present as a mass but is frequently clinically occult. At mammography, tumours typically form a spiculated mass frequently containing microcalcifications [2670,2806]. Multifocality is observed in 20% of the cases [2148].

Histopathology

The pure ICC consists almost entirely (>90%) of an invasive cribriform pattern. The tumour is arranged as invasive islands, often angulated, in which well defined spaces are formed by arches of cells (a sieve-like or cribriform pattern). Apical snouts are a regular feature. The tumour cells are small and show a low or moderate degree of nuclear pleomorphism. Mitoses are rare. A prominent, reactive appearing, fibroblastic stroma is present in many ICC. Intraductal carcinoma, generally of the cribriform type, is observed in as many as 80% of cases [2148]. Axillary lymph node metastases occur in 14.3% [2148], the cribriform pattern being retained at these sites. Lesions showing a predominantly cribriform arrange-

ment associated with a minor (<50%) component of tubular carcinoma are also included in the group of classic ICC [2148]. Cases with a component (10-40%) of another carcinoma type, other than tubular carcinoma, should be called mixed type of carcinoma [2148,3017].

Immunoprofile

ICC is estrogen receptor positive in 100% and progesterone receptor in 69% of cases [3017].

Differential diagnosis

ICC should be differentiated from carcinoid tumour and adenoid cystic carcinoma; the former has intracytoplasmic argyrophilic granules, while the latter has a second cell population in addition to a variety of intracystic secretory and basement membrane-like material. The lack of laminin around the cribriform structures also differentiates ICC from adenoid cystic carcinoma [3092]. ICC is distinguished from extensive cribriform DCIS by the lack of a myoepithelial cell layer around its invasive tumour cell clusters, its haphazard distribution and irregular configuration.

Prognosis and predictive factors

ICC has a remarkably favourable outcome [771,2148,3017]. The ten-year overall survival was 90% [771] to 100% [2148]. The outcome of mixed invasive cribriform carcinoma has been reported to be less favourable than that of the classic form, but better than that of common ductal carcinoma [2148]. The biological behaviour of ICC is very similar to that of tubular carcinoma [771]. It has been suggested that cribriform elements might correspond to tubules [2148]. However, many ICC have no definite tubular structures and separation of this tumour as a distinct clinicopathological entity is justified.

Medullary carcinoma

Definition

A well circumscribed carcinoma composed of poorly differentiated cells arranged in large sheets, with no glandular structures, scant stroma and a prominent lymphoplasmacytic infiltrate.

ICD-O code 8510/3

Epidemiology

Medullary carcinoma (MC) represents between 1 and 7% [294,2334] of all breast carcinomas, depending on the stringency of diagnostic criteria used. The mean age of women with MC ranges from 45 to 52 years [623,2204,2334,3064].

Clinical features

The tumour is well delineated and soft on palpation. Mammographically MC is typically well circumscribed and may be confused with a benign lesion.

Macroscopy

MC has distinctive rounded, well defined margins and a soft consistency. Fleishy tan to grey in appearance, foci of necrosis and haemorrhage are frequent. The median diameter varies from 2.0-2.9 cm [2334,2370,3064].

Histopathology

Since the early descriptions of MC [895,1908,2367], the histological features of this tumour have been further specified [2334,2370,3064].

Classically, five morphological traits characterize MC.

1. A syncytial architecture should be observed in over 75% of the tumour mass. Tumour cells are arranged in sheets, usually more than four or five cells thick, separated by small amounts of loose connective tissue. Foci of necrosis and of squamous differentiation may be seen.
2. Glandular or tubular structures are not present, even as a minor component.
3. Diffuse lymphoplasmacytic stromal infiltrate is a conspicuous feature. The density of this infiltrate varies among cases, mononuclear cells may be scarce or so numerous that they largely obliterate the carcinoma cells. Lymphoid follicles and/or epithelioid granuloma may be present.
4. Carcinoma cells are usually round with abundant cytoplasm and vesicular nuclei containing one or several nucleoli. The nuclear pleomorphism is moderate or marked, consistent with grade 2 or 3. Mitoses are numerous. Atypical giant cells may be observed.
5. Complete histological circumscription of the tumour is best seen under low magnification. Pushing margins may delimit a compressed fibrous zone at the periphery of the lesion.

Besides these typical histologic traits, the presence of an intraductal component is considered as a criterion for exclusion by some authors [2370,3064], but acceptable by others [2334], especially when it is located in the surrounding tissue or reduced to small areas within the tumour mass.

These diagnostic criteria, particularly the status of the margin, may be difficult to assess in practice, and may explain the low reproducibility in the diagnosis of MC observed in certain series [950,2203,2372]. To overcome this difficulty, a simplified scheme has been proposed [2202]. Syncytial growth pattern, lack of tubule formation and lymphoplasmacytic infiltrate, together with sparse tumour necrosis (<25%) were found to be the most reproducible and characteristic features of MC. However, the prognostic significance of this simplistic scheme needs to be assessed [1339].

Tumours showing the association of a predominantly syncytial architecture with only two or three of the other criteria are usually designated as atypical medullary carcinoma (AMC) [2334,2370]. However, strictly defined morphological criteria are necessary to preserve the entity of MC characterized by its relatively favourable prognosis [2334,2478] which is not shared by AMC. Several works [2334,3064] have advocated the elimination of the AMC category in order to avoid confusion with MC and the term infiltrating ductal carcinoma with medullary features seems to be more appropriate for these tumours.

Immunoprofile and ploidy

Flow cytometry and immunohistochemical analysis has shown that most MC are aneuploid and highly proliferative tumours [551,1244,1345,1766,2108,2201]. A high apoptosis rate has also

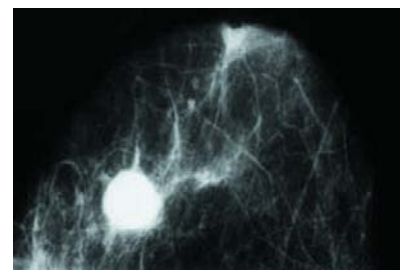


Fig. 1.26 Medullary carcinoma. Mammogram showing a typical rounded, dense tumour without calcifications.

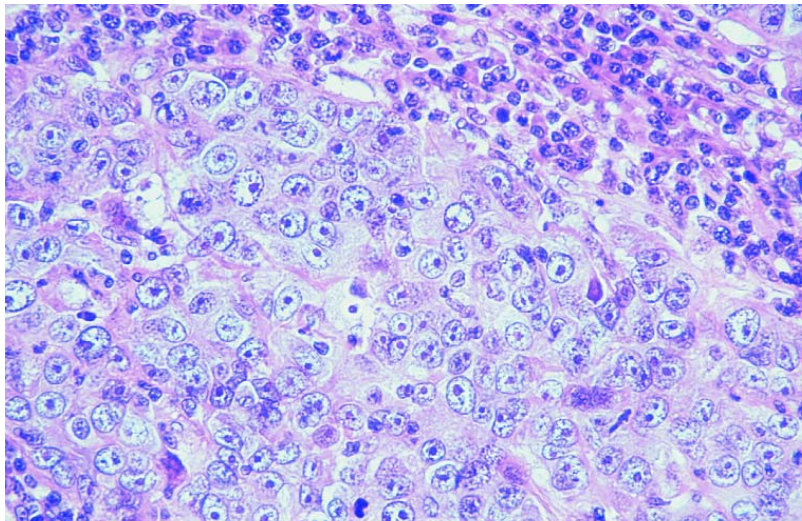


Fig. 1.27 Medullary carcinoma. The tumour is composed of a syncytial sheet of large pleomorphic cells. There is no glandular differentiation. The adjacent stroma contains numerous plasma cells and mature lymphocytes.

been reported [1386,3170]. MC typically lack estrogen receptors (ER) expression [1244,1340,2204,2272], and have a low incidence of ERBB2 overexpression [2439,2746,2750]. The cytokeratin profile is similar in typical and atypical MC, and does not differ significantly from that of common ductal tumours [610,1340,2943]. The cell cohesiveness of MC, contrasting with the poorly differentiated pattern and high mitotic index, has been characterized by the expression of the intercellular adhesion molecule-1 [156] and of E-cadherin [444]. This feature might account for the good limitation of the tumour and the late axillary lymph node extension. Immunophenotyping of the lymphoid infiltrate of MC has shown that most cells correspond to mature T lymphocytes, a profile similar to that observed in common ductal carcinomas [214]. Evidence

of polyclonality of the B-cell infiltrate has been obtained [1510]. Plasma cells were found to express IgG [1310] or IgA [1254]. The recent finding of an increased number of activated cytotoxic lymphocytes in MC may correspond to an active host versus tumour response [3169]. Expression of HLA class I and class II molecules by carcinoma cells, as a cause or a consequence of the immune response, was reported to characterize MC [840]. Although EBV-associated lymphoepithelioma shares some morphological features with MC, only a few cases were found associated with EBV, in contrast with the 31-51% rate of EBV-positive common ductal carcinomas [310,857].

Genetics

A high frequency of MC has been reported in patients with *BRCA1* germ line mutation, whereas this observation was less common among patients with *BRCA2* mutation or with no known germ line mutation. Typical MC were observed in 7.8% [1767] to 13% [8] of *BRCA1*-associated carcinomas, versus 2% in control populations. However, the presence of medullary features was found in 35% [1767] to 60% [121] of tumours arising in *BRCA1* carriers. Reciprocally, in a population of MC, germ line mutations of *BRCA1* was observed in 11% of the cases [764]. There is thus a large overlap between medullary features and the phe-

notype of *BRCA1* germline associated tumours, but not all *BRCA1* mutations lead to medullary phenotype. MC are also characterized by a high rate of *TP53* alterations. Somatic mutations were found in 39% [1766] to 100% [643] of MC, together with protein accumulation in 61-87% of the cases [643, 711,1345]. This contrasts with the 25-30% rate of *TP53* alterations found in common ductal carcinomas [643,711, 1345]. No specific *TP53* mutation was found to characterize MC [643] but *TP53* overstaining may be considered as a biological marker of MC. Both *TP53* and *BRCA1* are involved in the process of DNA repair and the alteration of these genes, together with a high proliferation rate, may account for the high sensitivity of MC to radio- and/or chemotherapy.

Prognosis and predictive factors

MC has been reported to have a better prognosis than the common IDC [1339, 1740,1908,2204,2334,2352,2367,2370, 3064] but this has been questioned by others [285,771,876]. The overall 10-year-survival reported for MC varies between about 50% [285,771,1740] to more than 90% [1339,2334,3064]. Differences in diagnostic criteria may account for this disparity and several reports underline that stringency in diagnostic criteria is required to preserve the anatomo-clinical identity of MC [876,2334,2370,3064] which is justified by the characteristic prognosis of this tumour. The outcome of MC associated with more than three metastatic axillary lymph nodes has been reported to be poor [285,1740,2202] or no different from that of common ductal tumours [876,2352]. However, less than 10% of MC [876,1339,2334,2352,2370] present with node metastases, and this might account in part for the relatively favourable overall prognosis of MC.

Table 1.06
Histological criteria required for a diagnosis of MC.

> Syncytial growth pattern (> 75%)
> Absence of glandular structures
> Diffuse lymphoplasmacytic infiltrate, moderate to marked
> Nuclear pleomorphism, moderate to marked
> Complete histological circumscription

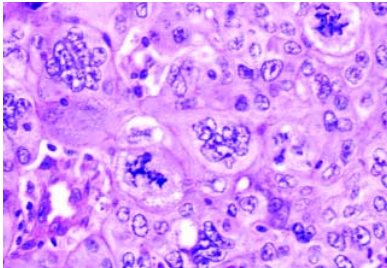


Fig. 1.28 Medullary carcinoma. Note multinucleated malignant cells with atypical mitoses.

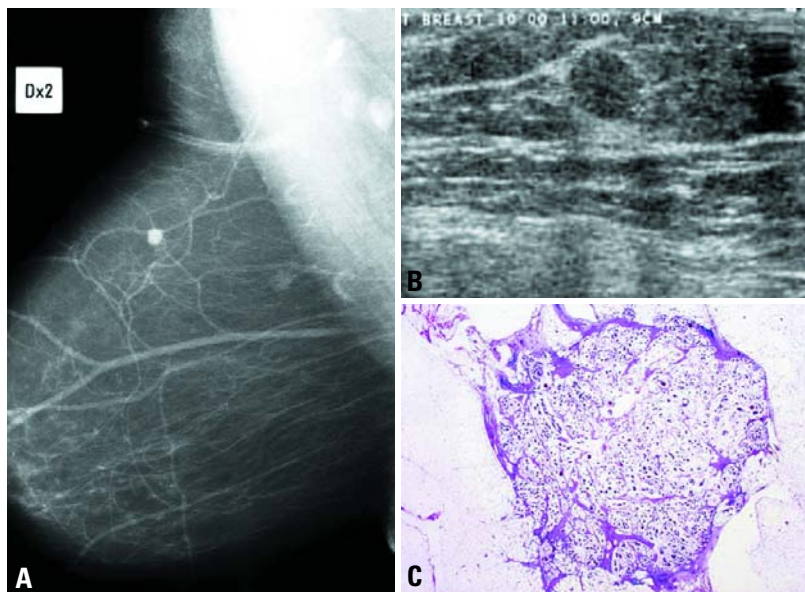


Fig. 1.29 Mucinous carcinoma. **A** Mammogram showing small rounded density of less than 10 mm diameter in the upper-outer quadrant. **B** Ultrasound suggests mucinous carcinoma. **C** Low power view of the mucinous carcinoma.

Mucin producing carcinomas

Definition

A variety of carcinomas in the breast are characterized by production of abundant extracellular and/or intracellular mucin. Among these are mucinous (colloid) carcinoma, mucinous cystadenocarcinoma, columnar cell mucinous carcinoma and signet ring cell carcinoma.

Mucinous carcinoma

Mucinous carcinoma is characterized by a proliferation of clusters of generally small and uniform cells floating in large amounts of extracellular mucus often visible to the naked eye.



Fig. 1.30 Mucinous carcinoma. 38 year old patient, tumour excision.

ICD-O code 8480/3

Synonyms

Colloid carcinoma, muroid carcinoma, gelatinous carcinoma.

Epidemiology

Pure mucinous carcinoma accounts for about 2% of all breast carcinomas {2338,2590,2934}. It occurs in a wide age range, but the mean and median age of patients with mucinous carcinoma in some studies is somewhat higher than that of regular infiltrating carcinomas, being often over 60 years {2447,2590}.

Clinical features

The tumours usually present as a palpable lump. The location is similar to that of breast carcinomas in general. Mammographically, mucinous carcinoma appears as a well defined, lobulated lesion. On magnification or compression views {547}, a less defined margin may become more evident. The mammographic resemblance to a benign process (circumscription and lobulation) increases with increasing mucin content.

Macroscopy

The typical glistening gelatinous appearance with bosselated, pushing margins and a soft consistency make the lesion

readily recognizable. The tumours range in size from less than 1 cm to over 20 cm, with an average of 2.8 cm {1498,2338,2447,2934}.

Histopathology

Mucinous carcinoma is characterized by proliferation of clusters of generally uniform, round cells with minimal amounts of eosinophilic cytoplasm, floating in lakes of mucus. Delicate fibrous septae divide the mucous lake into compartments. The cell clusters are variable in size and shape; sometimes with a tubular arrangement; rarely, they assume a papillary configuration. Atypia, mitotic figures and microcalcifications are not common, but occur occasionally. An intraepithelial component characterized by a micropapillary to solid pattern is present in 30-75% of the tumours. The lakes of mucin are mucicarmine positive, but intracytoplasmic mucin is rarely present. A notable proportion of the lesions have neuroendocrine differentiation {150,855} easily demonstrable by Grimelius stain or immunoreaction for chromogranin and synaptophysin (see also neuroendocrine carcinoma of breast).

The descriptive term cellular mucinous carcinoma has been used by some {1751} to differentiate the endocrine variant of mucinous carcinoma from the non-endocrine one; presence of intracytoplasmic neuroendocrine granules does not always correlate with the degree of cellularity, however.

Traditionally, pure and mixed variants of mucinous carcinoma have been described {1498,2934}. A pure tumour must be composed entirely of mucinous carcinoma. The pure mucinous carcinomas are further subdivided into cellular and hypocellular variants. The former is more likely to have intracytoplasmic mucin and argyrophilic granules. As soon as another pattern becomes evident as a component of the tumour mass, the lesions qualifies as a mixed tumour (the proportion of the different components should be noted). The most common admixture is with regular invasive duct carcinoma.

Differential diagnosis

The two lesions most likely to be confused with mucinous carcinoma are myxoid fibroadenoma and mucocoele like lesion {2417}. The presence of compressed spaces lined by epithelial and

myoepithelial cells in fibroadenomas, along with mast cells within the myxoid stroma, helps in its recognition. In mucocoele-like lesions, the presence of myoepithelial cells adhering to the strips of cells floating in the lakes of mucus serves as an important clue to their benign nature; the cell clusters in mucinous carcinoma are purely epithelial. The presence of ducts variably distended by mucinous material adjacent to a mucocoele is another helpful clue in distinguishing mucocoele-like lesions from mucinous carcinomas.

Immunoprofile and ploidy

Typically mucinous carcinoma is estrogen receptor positive [2669], while less than 70% [691] are progesterone receptor positive. Nearly all pure mucinous carcinomas are diploid, while over 50% of the mixed variety are aneuploid [2933].

Prognosis and predictive factors

Prognostic factors relevant to breast carcinomas in general are also applicable to pure mucinous carcinomas. Tumour cellularity has also been implicated in that cellular tumours are associated with a worse prognosis [502]. The presence or absence of argyrophilic granules had no prognostic significance in two studies

[2590,2934]. In general, pure mucinous carcinomas have a favourable prognosis [844,2590,2934]. The ten-year survival ranges from 80% [1498] to 100% [844,2053]. Pure mucinous carcinomas have a far better prognosis than the mixed variety with at least a 18% difference in survival rates noted in several studies [1498,2053,2934]. About 10% of women with the pure form die of their cancer compared to 29% of those with the mixed type [1498,2053]. A similar difference also exists in the incidence of axillary node metastases for pure and mixed types; only 3-15% of the pure variety show axillary node metastases compared to 33-46% of the mixed type [82,1498,2338]. Late distant metastases may occur [502,2447,2934].

A rare cause of death among women with mucinous carcinoma is cerebral infarction due to mucin embolism to the cerebral arteries [2944].

Mucinous cystadenocarcinoma and columnar cell mucinous carcinoma

Definition

A carcinoma composed of generally tall, columnar cells with basally located bland nuclei and abundant intracytoplasmic

mucin that appears either cystic (mucinous cystadenocarcinoma) or solid (columnar cell mucinous carcinoma) to the naked eye.

ICD-O code

Mucinous cystadenocarcinoma 8470/3

Epidemiology

Only four examples of mucinous cystadenocarcinoma and two of the solid columnar cell type have been reported [1486]. They occurred in women 49 to 67 years of age.

Clinical features

The clinical features of mucinous cystadenocarcinomas are similar to common infiltrating ductal carcinomas.

Macroscopy

The tumours vary in size from 0.8 to 19 cm, are cystic and display a gelatinous appearance with abundant mucoid material simulating an ovarian mucinous tumour.

Histopathology

Microscopically, both of these variants, are composed of tall columnar mucinous cells with abundant intracytoplasmic mucin and basal nuclei. In the

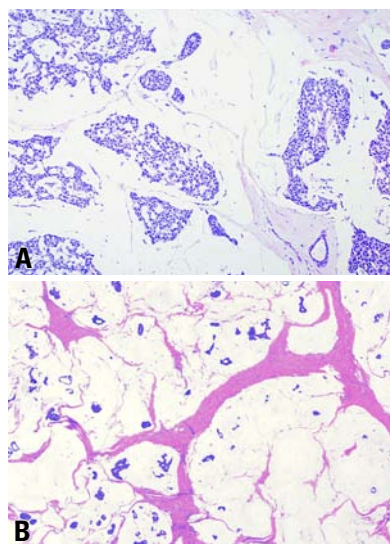


Fig. 1.31 Mucinous carcinoma. **A** Hypercellular variant with large clusters of densely packed malignant cells. **B** Hypocellular variant. Lakes of mucus are separated by fibrous septae. A few isolated or clusters of carcinoma cells are floating in the mucus lakes.

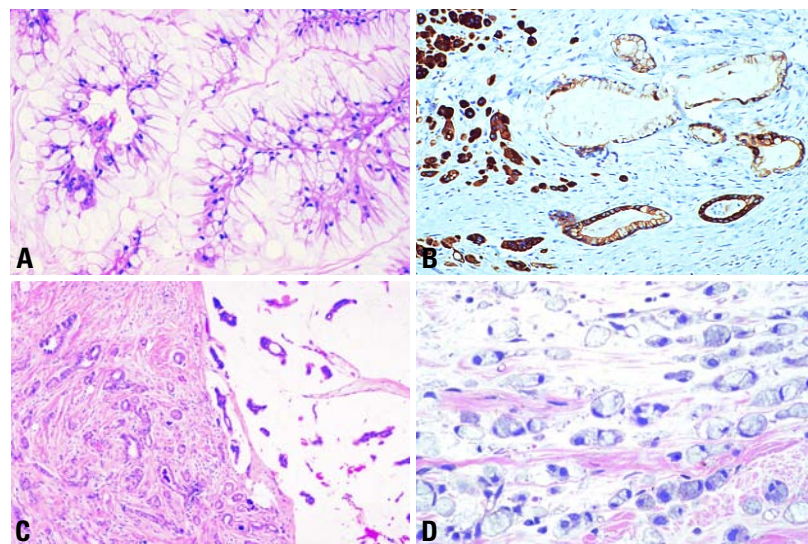


Fig. 1.32 **A** Mucinous cystadenocarcinoma. Papillary processes lined by mucinous columnar cells protrude into cystic spaces. **B** Mucinous cystadenocarcinoma. Many of the invasive cells are immunoreactive to CK34. **C** Combined mucinous and infiltrating ductal carcinoma. A favourable prognosis associated with pure mucinous carcinoma is no longer expected when it is admixed with regular infiltrating duct carcinoma. **D** Signet ring cell carcinoma. The invasive cells assume a lobular growth pattern and contain abundant intracytoplasmic mucin conferring a signet-ring cell appearance to the cells.

Table 1.07

Criteria for the differential diagnosis of mucin producing carcinomas.

Histological type	Location of mucin	Growth pattern	In situ component
Mucinous (colloid) carcinoma	Extracellular	Clusters of cells in mucus lakes	Ductal
Mucinous cystadenocarcinoma	Intracellular and extracellular	Large cysts, columnar cells, epithelial stratification, papillae, solid areas	Ductal
Columnar mucinous carcinoma	Intracellular	Round and convoluted glands lined by a single layer of columnar cells	Ductal
Signet ring cell carcinoma	Intracellular	Isolated cells, cords, clusters	Mainly lobular

cystic variant numerous cysts of variable size are formed, some with papillary fronds lined by a single layer of predominantly bland appearing, columnar mucinous cells. Focal atypia characterized by nuclear pleomorphism (but sparse mitotic activity), loss of polarity and eosinophilic cellular transformation is invariably present, as is invasion of surrounding stroma by most often the eosinophilic cells. Axillary node metastases occur in a quarter of mucinous cystadenocarcinomas. The columnar cell variant is composed of a compact to loose aggregation of round and convoluted glands lined by a single layer of generally tall, columnar mucinous epithelium with bland, basal nuclei and rare mitotic figures.

Prognosis and predictive factors

After a maximum follow-up of only 2 years, none of the patients has developed a recurrence or metastasis.

Signet ring cell carcinoma

ICD-O code 8490/3

Signet ring cell carcinomas are of two types. One type is related to lobular carcinoma and is characterized by large intracytoplasmic lumina which compress the nuclei towards one pole of the cell [1849]. Their invasive component has the targetoid pattern of classical lobular carcinoma. The other type is similar to diffuse gastric carcinoma, and is characterized by acidic mucosubstances that diffusely fill the cytoplasm and dislodge the nucleus to one pole of

the cell. This type of signet ring cell carcinoma can be seen in association with the signet ring cell variant of DCIS [1143].

Neuroendocrine tumours

Definition

Primary neuroendocrine (NE) carcinomas of the breast are a group, which exhibits morphological features similar to those of NE tumours of both gastrointestinal tract and lung. They express neuroendocrine markers in more than 50% of the cell population. Breast carcinoma, not otherwise specified, with focal endocrine differentiation, revealed by immunocytochemical expression of neuroendocrine markers in scattered cells, is not included this group.

Synonym

Endocrine carcinoma.

Epidemiology

NE breast carcinomas represent about 2-5% of breast carcinomas. Most patients are in the 6th or 7th decades of life [2535]. Neuroendocrine differentiation also occurs in male breast carcinoma [2591].

Clinical features

There are no notable or specific differences in presentation from other tumour types. Patients often present with a palpable nodule, which usually appears as a circumscribed mass on mammographic and ultrasound examination. Patients with small cell carcinoma often present at an advanced stage.

Endocrine hormone related syndromes are exceptionally rare. Of interest is the increase in the blood of neuroendocrine markers such as chromogranin A.

Macroscopy

NE breast carcinomas can grow as infiltrating or expansile tumours. The consistency of tumours with mucin production is soft and gelatinous.

Histopathology

Most NE breast carcinomas form alveolar structures or solid sheets of cells with a tendency to produce peripheral palisading. However, they may present as different subtypes, depending on the cell type, grade, degree of differentiation and presence of mucin production. The latter is observed in 26% of cases [2535].

Solid neuroendocrine carcinoma

These tumours consist of densely cellular, solid nests and trabeculae of cells that vary from spindle to plasmacytoid and large clear cells [2536] separated by delicate fibrovascular stroma. In some tumours, the nests are packed into a solitary, well defined to lobulated mass; the tumour cells rarely form rosette-like structures and display peripheral palisading reminiscent of *carcinoid* tumour.

Some of these appear to originate from solitary, solid papillary intraductal carcinomas. Others form multiple, often rounded solid nests separated by a dense, collagenous stroma resembling the alveolar pattern of invasive lobular carcinoma. Mitotic activity ranges from 4 in the carcinoid-like tumour to 12 in the alveolar variant; focal necrosis may be seen. The tumour cells contain NE granules.

Small cell / oat cell carcinoma

ICD-O codes

Small cell carcinoma	8041/3
Oat cell carcinoma	8042/3

This is morphologically indistinguishable from its counterpart in the lung on the basis of histological and immunohistochemical features [2662]. The tumours are composed of densely packed hyperchromatic cells with scant cytoplasm and display an infiltrative growth pattern. An in situ component with the same cytological features may

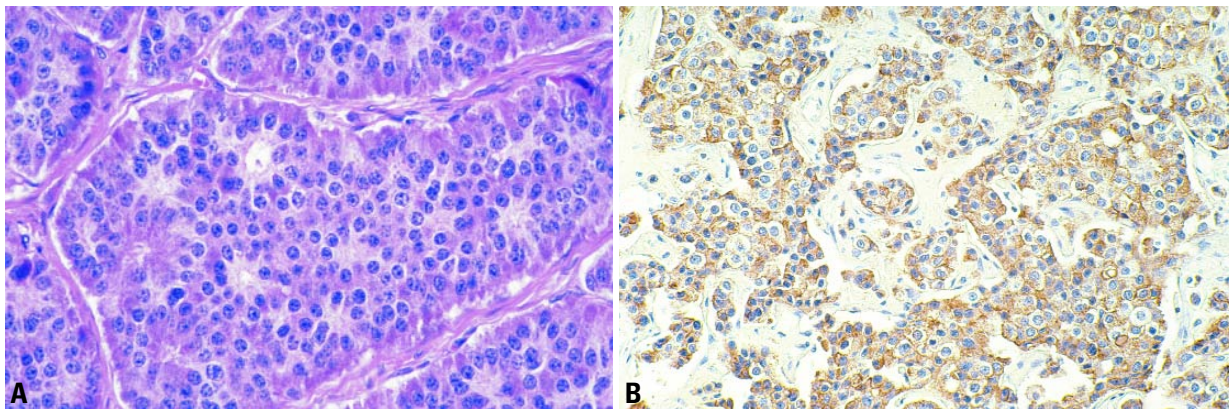


Fig. 1.33 Neuroendocrine carcinoma. **A** Tumour cells are polarized around lumina; some cells show eosinophilic granules – carcinoid-like pattern. **B** IHC staining is positive for chromogranin.

be present. Areas of tumour necrosis containing pyknotic hyperchromatic nuclei are rarely detectable. Crush artefact and nuclear streaming occur, but are more typical of aspiration cytology samples. Lymphatic tumour emboli are frequently encountered.

Large cell neuroendocrine carcinoma

ICD-O code 8013/3

These poorly differentiated tumours are composed of crowded large clusters of cells, with moderate to abundant cytoplasm, nuclei with vesicular to finely granular chromatin and a high number of mitotic figures ranging from 18 to 65 per 10 hpf. Focal areas of necrosis are present [2535]. These tumours exhibit neuroendocrine differentiation similar to those encountered in the lung (see also below).

Differential diagnosis

A nodule of NE carcinoma in the breast may reflect metastatic carcinoid or small cell carcinoma from another site [2022]. Immunohistochemistry may help to distinguish between metastatic and primary small cell carcinomas. Mammary small cell carcinomas are cytokeratin 7-positive and cytokeratin 20-negative, whereas, for example, pulmonary small cell carcinomas are negative for both [2662]. The presence of DCIS with similar cytological features is supportive of breast origin. In addition, the expression of estrogen (ER) and progesterone receptors (PR) and of the

apocrine marker GCDPF-15, which is frequently expressed by well and moderately differentiated endocrine breast carcinomas [2535], are supportive of a primary breast carcinoma.

Mammary small cell carcinoma can be confused histologically with lobular carcinoma. The negative immunoreaction for E-cadherin in lobular carcinomas, in contrast to a positive reaction in 100% of small cell carcinomas, is useful in the differential diagnosis [2661].

It is also important to differentiate neuroendocrine breast carcinomas from carcinomas with neuroendocrine differentiation. The latter have immunoex-

pression for neuroendocrine markers in scattered cells; this feature is noted in 10-18% of breast carcinomas of the usual type. Such focal neuroendocrine differentiation does not seem to carry a special prognostic or therapeutic significance [1876].

Immunoprofile

Argyrophilia demonstrated by Grimelius silver precipitation is a feature of neuroendocrine breast carcinomas. Only darkly granulated cells should be considered as argyrophilic [2536].

Expression of chromogranin proteins and/or synaptophysin also confirmed

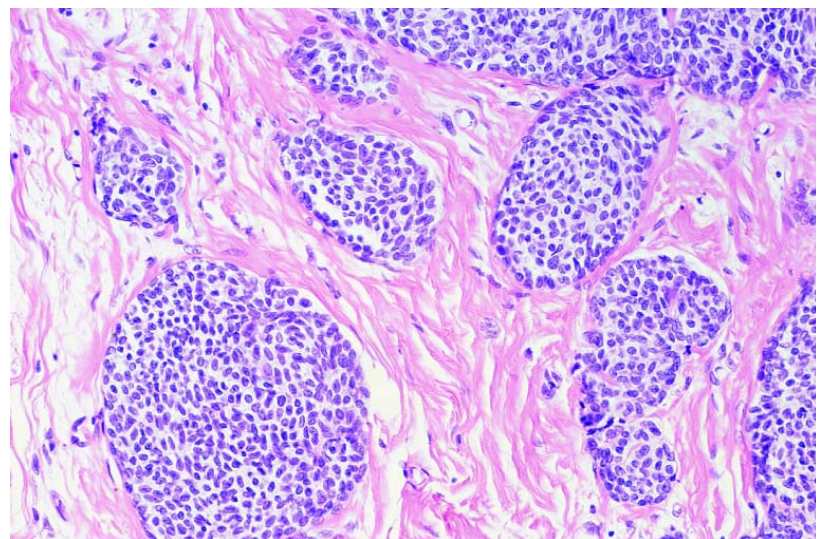


Fig. 1.34 Neuroendocrine carcinoma of the breast. Alveolar pattern with rounded solid nests of spindle cells invading a dense collagenous stroma.

evidence of neuroendocrine differentiation [2533]. These proteins are identifiable by immunohistochemical and immunoblot analysis. Poorly and moderately differentiated endocrine breast carcinomas of the alveolar subtype, in general, express chromogranin A. The mRNA specific for chromogranin A is detectable by in situ hybridization technique [2535]. About 50% of well or moderately differentiated tumours express chromogranin B and A and only 16% express synaptophysin [2535]. A monoclonal antibody against neurone-specific enolase (NSE) has also been used and is expressed in 100% of small cell carcinomas of the breast [2662], whereas chromogranin A and synaptophysin are expressed in about 50% of such cases. In addition, 20% of small cell mammary carcinomas express thyroid transcription factor-1 (TTF-1) [2661].

Immunodetection of pan-endocrine markers may fail to recognize endocrine tumours, which produce but do not retain the specific antigen in the cells. Estrogen (ER) and progesterone receptors (PR) are expressed in the majority of tumour cells in well differentiated tumours [2535], and in more than 50% of small cell carcinomas [2662]. Expression of somatostatin receptors (SSR), a known feature of tumours showing neuroendocrine differentiation, has been demonstrated in endocrine breast carcinomas as well [2169].

Ultrastructure

Different types of dense core granules, whose neurosecretory nature is confirmed by ultrastructural immunolocalization of chromogranin A have been identified by electron microscopy in endocrine breast carcinomas [397].

The presence of clear vesicles of pre-synaptic type is correlated with the expression of synaptophysin.

Both dense core granules and mucin vacuoles are present in neuroendocrine mucinous carcinomas [1265].

Genetics

Neuroendocrine breast carcinomas have not been correlated to specific gene mutations.

Postulated normal counterpart

Argyrophilic and chromogranin A-reactive cells, located between the basal myoepithelial and the luminal epithelial cells, have been demonstrated in histologically normal breast tissue surrounding infiltrating and in situ neuroendocrine breast carcinomas [382,1995,2542,2956].

Prognosis and predictive factors

Histological grading is one of the most important prognostic parameters. NE breast carcinomas may be graded using classical criteria described elsewhere.

Excluding the rare small cell variety, 45% of NE breast carcinomas are well differentiated, 40% are moderately differentiated, and only 15% are poorly differentiated. Small cell NE carcinomas should be considered as undifferentiated carcinomas [2535].

Mucinous differentiation is a favourable prognostic factor [2535].

The prognosis of primary small cell carcinomas of the breast depends on the stage of disease at the time of diagnosis. It has been demonstrated that low stage small cell carcinomas respond to conventional treatment without progression of the disease at a follow up of 33 to 48 months [2662].

Invasive papillary carcinoma

Definition

When papillary intraductal carcinomas invade, they generally assume the pattern of infiltrating duct carcinoma and lack a papillary architecture. Most of the published literature concerning papillary carcinomas of the breast probably include both invasive and in situ papillary lesions as they do not generally specify features of an invasive process [413,603,969,1269,1604,1618,1834]. In this section, however, only data concerning invasive papillary carcinomas will be reviewed. Invasive papillary carcinomas comprise less than 1-2% of invasive breast cancers, and are characterized by a relatively good prognosis [879,2567].

ICD-O code 8503/3

Clinical features

Invasive papillary carcinomas are diagnosed predominantly in postmenopausal patients. Fisher et al. [879] noted a disproportionate number of cases in non-Caucasian women. Similar to medullary carcinomas, Fisher et al. noted that a significant proportion of patients with invasive papillary carcinoma exhibit axillary lymphadenopathy suggestive of metastatic disease, but which on pathological examination is due to benign reactive changes [879].

Mammographically, invasive papillary carcinoma is usually characterized by nodular densities which may be multiple, and are frequently lobulated [1880,2567]. These lesions are often hypoechoic on ultrasound [1827]. One study noted the difficulty in distinguishing between intracystic papillary carcinoma, intracystic papillary carcinoma with invasion, and invasive papillary carcinoma [1827].

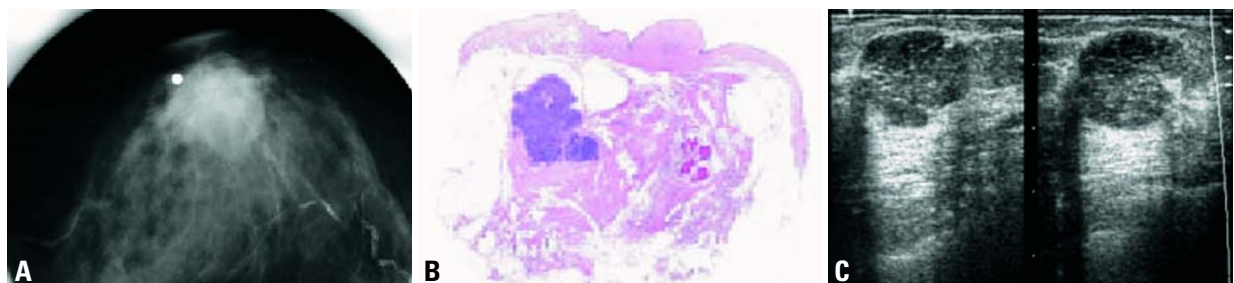


Fig. 1.35 Invasive papillary carcinoma. **A** Microfocus magnification image of a papillary carcinoma shows a low density rounded tumour. **B** Large section histology. **C** Ultrasonography shows a lobulated, well delineated lesion.

Macroscopy

Fisher et al. reported that invasive papillary carcinoma is grossly circumscribed in two-thirds of cases [879]. Other invasive papillary carcinomas are grossly indistinguishable from invasive breast cancers of no special type.

Histopathology

Of the 1,603 breast cancers reviewed in the NSABP-B04 study, 38 had papillary features, and all but 3 of these were "pure," without an admixture of other histologic types [879]. Microscopically, expansile invasive papillary carcinomas are characteristically circumscribed, show delicate or blunt papillae, and show focal solid areas of tumour growth. The cells typically show amphophilic cytoplasm, but may have apocrine features, and also may exhibit apical "snouting" of cytoplasm similar to tubular carcinoma. The nuclei of tumour cells are typically intermediate grade, and most tumours are histologic grade 2 [879]. Tumour stroma is not abundant in most cases, and occasional cases show prominent extracellular mucin production. Calcifications, although not usually evident mammographically, are commonly seen histologically, but usually are present in associated DCIS. DCIS is present in more than 75% of cases, and usually, but not exclusively, has a papillary pattern. In rare lesions in which both the invasive and in situ components have papillary features, it may be difficult to determine the relative proportion of each. Lymphatic vessel invasion has been noted in one third of cases. Microscopic involvement of skin or nipple was present in 8 of 35 cases (23%), but Paget disease of the nipple was not observed [879].

Estrogen receptor positivity was observed in all 5 cases of invasive papillary carcinoma examined in one study, and progesterone receptor positivity in 4 of 5 (80%) [2351]. In a review of cytogenetic findings in 5 examples of invasive papillary carcinoma, 60% exhibited relatively simple cytogenetic abnormalities [40]. In addition, none of the 4 examples of papillary carcinomas examined in two recent reports were associated with either TP53 protein accumulation or ERBB2 oncogene overexpression [2440,2750].

Clinical course and prognosis

There are only limited data on the prognostic significance of invasive papillary

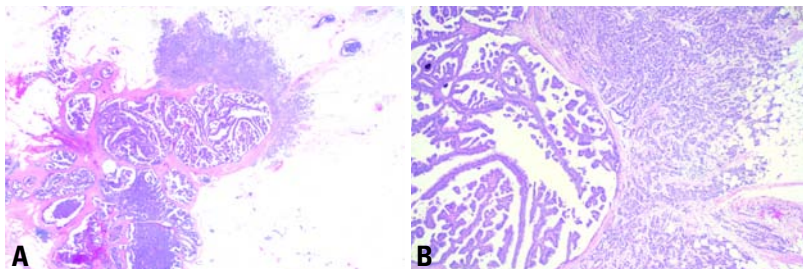


Fig. 1.36 Papillary carcinoma with invasion. **A** Overview of an intraductal papillary carcinoma, present at the centre, with invasive carcinoma apparent in the upper right side of the lesion. **B** Higher magnification shows an infiltrating duct carcinoma pattern by the invasive component of the lesion while the in situ region is clearly papillary.

carcinoma [868,871,879]. Among 35 patients with this tumour in the NSABP-B04 trial, after 5 years median follow-up, there were only 3 treatment failures, including 1 patient who died from metastatic papillary carcinoma. These survival data were similar to those reported in patients with pure tubular and mucinous carcinomas in this study [879]. A later publication updating the NSABP-B04 results at 15 years revealed that patients with "favourable" histology tumours (including invasive papillary carcinomas) still had significantly better survival in univariate analysis, but tumour histology was not an independent predictor of survival in multivariate analysis [871]. However, node-negative patients with invasive papillary carcinomas enrolled in the NSABP-B06 trial experienced improved survival after 10 years follow-up compared to patients with carcinomas of no special type, and tumour histology was an independent predictor of survival in multivariate analysis [868].

Invasive micropapillary carcinoma

Definition

A carcinoma composed of small clusters of tumour cells lying within clear stromal spaces resembling dilated vascular channels.

ICD-O code 8507/3

Epidemiology

Carcinomas with a dominant micropapillary growth pattern account for less than 2% of all invasive breast cancers [707, 1715,1982,2194,2229]. The term inva-

sive micropapillary carcinoma was coined by Siriaunkgul and Tavassoli who first described nine examples of this lesion [707]. While quite rare in its pure form, focal micropapillary growth has been reported in 3-6% of more common types of invasive carcinomas [1982,2194]. It occurs in the same age range as invasive ductal carcinoma of no special type.

Clinical features

Invasive micropapillary carcinoma usually presents as a solid mass. Axillary lymph node metastases are present at first presentation in 72-77% [707,1715, 1982,2194,2229,3049].

Macroscopy

Pure micropapillary carcinoma has a lobulated outline due to the expansive mode of growth.

Histopathology

Micropapillary carcinoma consists of hollow aggregates of malignant cells, which on cross section have the appearance of tubules with diminished or obliterated lumens rarely containing pyknotic nuclei. These tumour cell clusters lie within artifactual stromal spaces caused by shrinkage of the surrounding tissue. The stromal spaces lack an endothelial lining and may be part of a speculated "missing lymphatic labyrinth" in mammary stroma [1152]. Nuclear pleomorphism is moderate, mitotic activity low, and there is neither necrosis nor lymphocytic reaction. In non-pure tumours, gradual or abrupt transitions from typical invasive ductal carcinoma to the micropapillary components are found. Peritumoural angioinvasion may be present in up to 60% of cases. Intravascular tumour emboli,

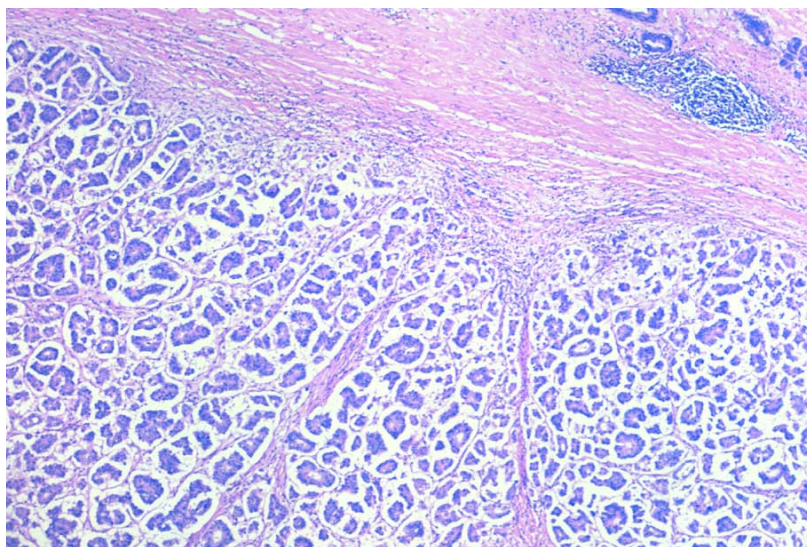


Fig. 1.37 Invasive micropapillary carcinoma. Tumour cell clusters with irregular central spaces proliferate within empty stromal spaces. Some clusters have reversed polarity with an "inside out" morphology.

lymph node metastases and malignant cells in pleural fluids all show the same arrangement found in the primary tumour.

Prognostic and predictive features

This unusual growth pattern is correlated with the presence of vascular invasion and axillary lymph node metastases. In multivariate analyses, however, a micropapillary growth pattern has no independent significance for survival [1982,2194].

Apocrine carcinoma

Definition

A carcinoma showing cytological and immunohistochemical features of apocrine cells in >90% of the tumour cells.

ICD-O code 8401/3

Epidemiology

The reported incidence of apocrine carcinoma depends on the method of detection. Based on light microscopy alone it is only 0.3-4% [149,910]. An ultrastructural study found a frequency of 0.4% for apocrine carcinomas in a prospective series [1926]. Immunohistochemical studies using anti GCDFP-15, a putative marker of apocrine differentiation [1800] gave conflicting data with an incidence ranging from 12% [809] to 72% [3113]. Twenty seven per cent of cases were positive with an in situ hybridization method using a mRNA probe against the sequence of the GCDFP-15 [1700]. In conclusion, carcinomas composed

predominantly of apocrine cells constitute at the most 4% of all invasive carcinomas; focal apocrine cells diagnosed either by histology, immunohistochemistry or genetic techniques are frequent and occur in at least 30% of "ordinary" invasive carcinomas [1700].

Clinical features

There is no difference between the clinical or mammographic features, size and site of carcinomas among apocrine and non-apocrine lesions. Bilaterality is rare in apocrine carcinomas.

Histopathology

Any type and grade of breast carcinoma can display apocrine differentiation including ordinary invasive duct carcinomas, tubular, medullary, papillary, micropapillary and neuroendocrine types [17,569,809,1700], as well as classical and pleomorphic invasive lobular carcinomas [802,808]. However, recognition of apocrine carcinoma at present has no practical importance and is only of academic value.

Apocrine lobular in situ neoplasias [802,2534], and apocrine ductal in situ carcinomas (ADCIS) are also well recognized [17,1605,2887]. Apocrine carcinomas, whatever their origin, are usually composed by two types of cells variously intermingled [804]. Type A cell recognized first by most authors has abundant granular intensely eosinophilic cytoplasm. The granules are periodic acid-Schiff positive after diastase digestion. Their nuclei vary from globoid with prominent nucleoli to hyperchromatic. Some tumours, when constituted by a pure proliferation of type A cells, superficially mimic granular cell tumours. This type of apocrine carcinoma has sometimes been referred

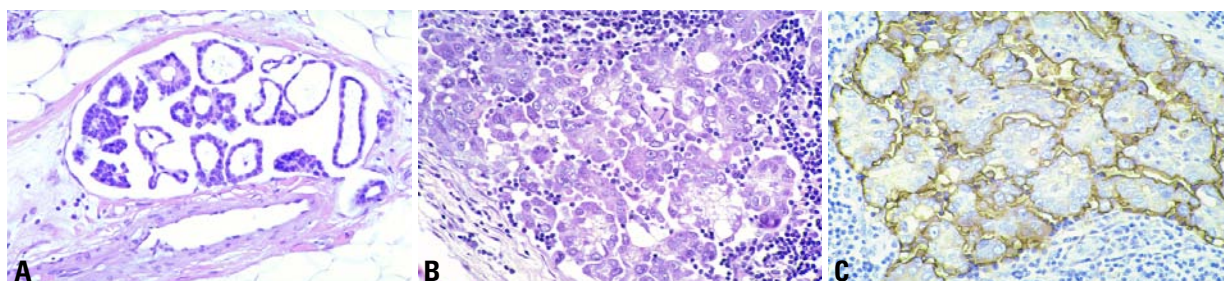


Fig. 1.38 Invasive micropapillary carcinoma. **A** Note the prominent vascular invasion and occasional pyknotic nuclei within the central spaces. **B** Lymph node metastasis. **C** EMA staining of the peripheral cell membranes suggestive of an "inside out" morphology.

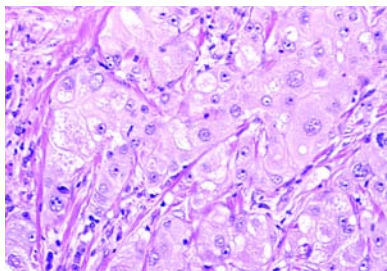


Fig. 1.39 Apocrine carcinoma. Note abundant eosinophilic cytoplasm and vesicular nuclei.

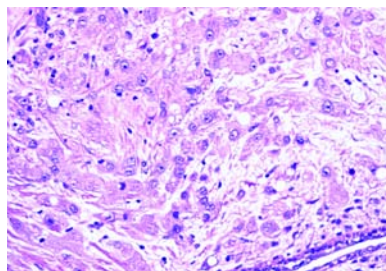


Fig. 1.40 Apocrine carcinoma, superficially resembling a granular cell tumour.

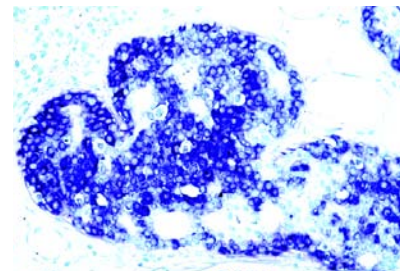


Fig. 1.41 Apocrine carcinoma. Immunostaining shows intense positivity for GCDFP-15.

to as myoblastomatoid [806]. Type B cell shows abundant cytoplasm in which fine empty vacuoles are seen. These latter result in foamy appearance so that the cells may resemble histiocytes and sebaceous cells. Nuclei are similar to those in type A cells. These same cells have been designated as sebocrine [2876]. (See also Sebaceous carcinoma, page 46). Carcinomas composed purely of foamy apocrine cells may superficially resemble a histiocytic proliferation or even an inflammatory reaction [806]. In difficult cases, both granular cell tumours and histiocytic proliferations can be easily distinguished by staining the tumours with keratin antibodies that are positive only in apocrine carcinomas.

Immunoprofile

Apocrine carcinomas are typically GCDFP-15 positive and BCL2 protein negative. Expression of GCDFP-15 is a feature common to many variants of breast carcinoma, however, and has been used to support breast origin in metastatic carcinomas of unknown primary site. Estrogen and progesterone receptors are usually negative in apocrine carcinoma by immunohistochemical assessment. Interestingly, many ER-, PR- apocrine carcinomas do have the ERmRNA, but fail to produce the protein [336]. The expression of other biological markers is in general similar to that of other carcinomas [177,1605,2425]. Androgen receptors have been reported as positive in 97% of ADCIS in one series [1605] and 81% in another [2624]. Sixty-two percent of invasive duct carcinomas were positive in the latter series [2624] and in 22% of cases in another study [1874]. The significance of AR in apocrine carcinomas is uncertain.

Genetics

Molecular studies in benign, hyperplastic and neoplastic apocrine lesions parallel those seen in non apocrine tumours [1357,1673].

Prognosis and predictive factors

Survival analysis of 72 cases of invasive apocrine duct carcinoma compared with non apocrine duct carcinoma revealed no statistical difference [17,809].

Metaplastic carcinomas

Definition

Metaplastic carcinoma is a general term referring to a heterogeneous group of neoplasms generally characterized by an intimate admixture of adenocarcinoma with dominant areas of spindle cell, squamous, and/or mesenchymal differentiation; the metaplastic spindle cell and squamous cell carcinomas may present in a pure form without any admixture with a recognizable adenocarcinoma. Metaplastic carcinomas can be classified into broad subtypes according to the phenotypic appearance of the tumour.

ICD-O code 8575/3

Synonyms

Matrix producing carcinoma, carcinosarcoma, spindle cell carcinoma.

Epidemiology

Metaplastic carcinomas account for less than 1% of all invasive mammary carcinomas [1273]. The average age at presentation is 55.

Clinical features

Clinical presentation is not different from that of infiltrating duct NOS carcinoma.

Most patients present with a well circumscribed palpable mass, with a median size of 3-4 cm, in some reports more than half of these tumours measure over 5 cm, with some massive lesions (>20 cm) which may displace the nipple and ulcerate through the skin.

On mammography, most metaplastic carcinomas appear as well delineated mass densities. Microcalcifications are not a common feature, but may be present in the adenocarcinomatous areas; ossification, when present, is, of course, apparent on mammography.

Macroscopy

The tumours are firm, well delineated and often solid on cut surface. Squamous or chondroid differentiation is reflected as pearly white to firm glistening areas on the cut surface. One large and/or multiple small cysts may be apparent on the cut surface of larger squamous tumours.

Table 1.08

Classification of metaplastic carcinomas.

Purely epithelial
Squamous
Large cell keratinizing
Spindle cell
Acantholytic
Adenocarcinoma with spindle cell differentiation
Adenosquamous, including mucoepidermoid
Mixed epithelial and Mesenchymal (specify components)
Carcinoma with chondroid metaplasia
Carcinoma with osseous metaplasia
Carcinosarcoma (specify components)

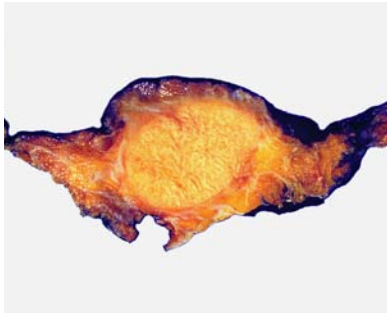

Fig. 1.42 Squamous cell carcinoma. A well circumscribed mass shows numerous irregularly shaped depressions on cut surface.

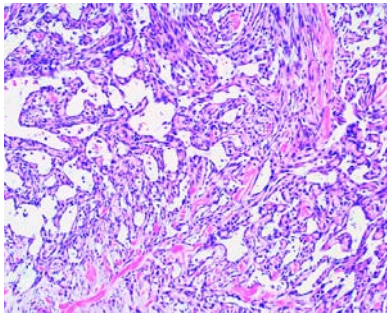


Fig. 1.43 Squamous cell carcinoma, acantholytic variant, which is often mistaken for angiosarcoma.

Squamous cell carcinoma

A breast carcinoma entirely composed of metaplastic squamous cells that may be keratinizing, non-keratinizing or spindled; they are neither derived from the overlying skin nor represent metastases from other sites.

ICD-O codes

Squamous cell carcinoma	8070/3
Large cell keratinizing variant	8071/3
Spindle cell variant	8074/3
Acantholytic variant	8075/3

Histopathology

Squamous cell carcinomas assume several phenotypes including large cell keratinizing, non-keratinizing, and less frequently spindle cell and acantholytic types; some show a combination of these patterns [752,987,1022,1928,2520,2932,3061]. The most bland appearing and well differentiated cells often line cystic spaces; as the tumour cells emanate out to infiltrate the surrounding stroma, they become spindle shaped and lose their squamous features. A pronounced stromal reaction is often admixed with the spindled squamous carcinoma. The squamous differentiation is retained in metastatic foci. Squamous cell carcinoma can be

graded based mainly on nuclear features and, to a lesser degree, cytoplasmic differentiation.

Immunoprofile

The spindle cell and acantholytic variants require immunohistochemical confirmation of their epithelial nature. The epithelial tumour cell components are positive for broad spectrum and high molecular weight cytokeratins (CK5 and CK34betaE12), but negative for vascular endothelial markers. Nearly all squamous cell carcinomas are negative for both estrogen (ER) and progesterone receptors (PR) [3059,3061].

Adenocarcinoma with spindle cell metaplasia

Definition

An invasive adenocarcinoma with abundant spindle cell transformation. The spindle cells are neither squamous, nor mesenchymal, but rather glandular in nature.

ICD-O code 8572/3

Clinical features

This tumour occurs mainly in postmenopausal women and presents as a discrete mass.

Pathologic features

Macroscopically, a well circumscribed, solid mass, the tumour is composed of tubules of adenocarcinoma admixed with neoplastic spindle cells. The spindle cells immunoreact with epithelial markers including CK7, but not with CK5,6 or other markers of squamous/myoepithelial differentiation. At the ultrastructural level, the spindle

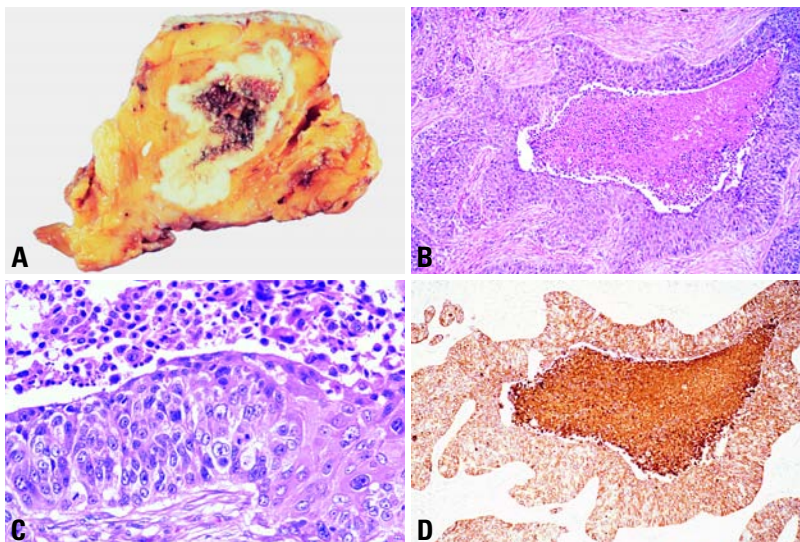


Fig. 1.44 Squamous cell carcinoma of the breast. **A** Macroscopically, there are often central cystic areas. **B** Various shaped spaces lined by squamous epithelium are characteristic of the more common mammary squamous cell carcinoma. **C** Higher magnification showing a range of squamous cell differentiation with the most differentiated at the right. **D** Immunostain for cytokeratins 5, 6 is positive as expected for squamous epithelium.

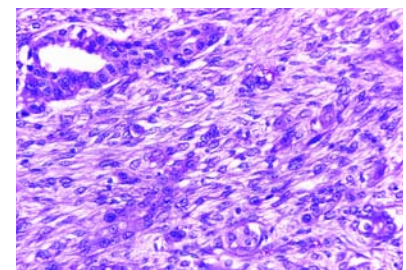


Fig. 1.45 Adenocarcinoma with spindle cell metaplasia. The spindle cells are neither squamous nor mesenchymal, but rather glandular, intermixed with glands.

cells contain intracytoplasmic lumens confirming a glandular cell population.

Adenosquamous carcinoma

Definition

An invasive carcinoma with areas of well developed tubule/gland formation intimately admixed with often widely dispersed solid nests of squamous differentiation.

ICD-O code 8560/3

Histopathology

While focal squamous differentiation has been observed in 3.7% of infiltrating duct carcinomas [878], a prominent admixture of invasive ductal and squamous cell carcinoma is rarely observed. The squamous component is often keratinizing, but ranges from very well differentiated keratinizing areas to poorly differentiated non-keratinizing foci.

Eight tumours described as examples of low grade *mucoepidermoid carcinoma*, comparable to those occurring in the salivary glands, have been reported in the breast; these behave as low grade carcinomas [1130,1156,1515,1629,1709,2191,2234].

Immunoprofile

The squamous component is negative for both ER and PR, while the positivity of the ductal carcinoma component for ER and PR depends on its degree of differentiation.

Low grade adenosquamous carcinoma

Low grade adenosquamous carcinoma [2431] is a variant of metaplastic carcinoma which is morphologically similar to adenosquamous carcinoma of the skin and has been classified by some as syringomatous squamous tumour [2816]. The same lesion has been interpreted as an infiltrating syringomatous adenoma by others who prefer to avoid designation of carcinoma for a group of lesions which mainly recur after local excision.

ICD-O code 8560/1

Synonym

Infiltrating syringomatous adenoma. This entity is also discussed in Tumours of the Nipple.

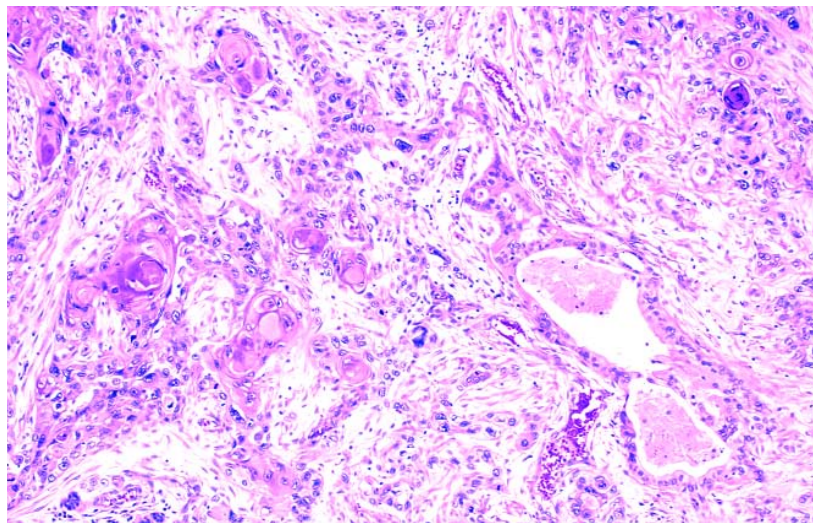


Fig. 1.46 Adenosquamous carcinoma. Both glandular and squamous differentiation coexist in this carcinoma.

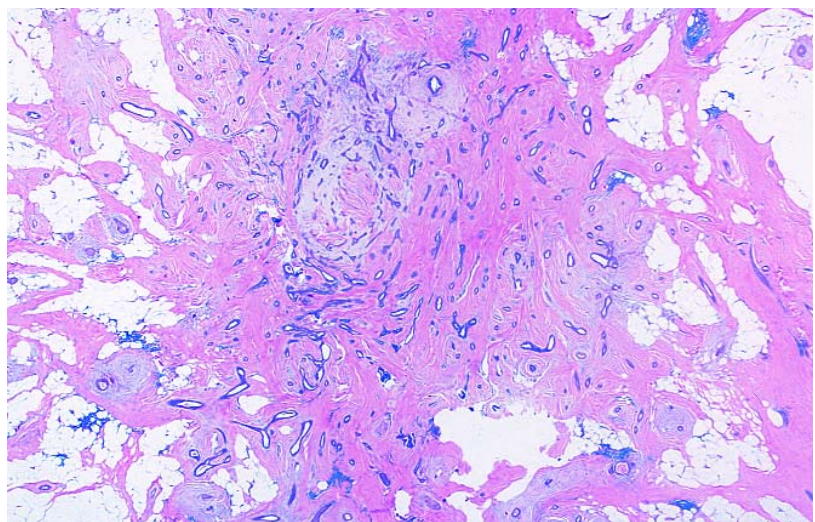


Fig. 1.47 Low grade adenosquamous carcinoma / infiltrating syringomatous adenoma. A highly infiltrative growth pattern is responsible for the high frequency of local recurrence associated with many lesions.

Clinical features

The age range at presentation is wide. These lesions usually present as a small palpable mass between 5 and 80 mm in size.

Histology

These tumours are composed of small glandular structure and solid cords of epithelial cells haphazardly arranged in an infiltrative spindle celled stromal component [2421,2995]. The proportions of these three components is variable between cases. The solid nests of cells

may contain squamous cells, squamous pearls or squamous cyst formation. The stroma is typically "fibromatosis-like" being cellular and composed of bland spindle cells. The stromal component can, however, be collagenous, hyalinized or variably cellular, and osteocartilagenous foci can occur rarely. It has been recognized that some low grade adenosquamous carcinomas may be found in association with a central sclerosing proliferation such as a radial scar, sclerosing papillary lesion or sclerosing adenosis [672,2421,2995]. The frequen-

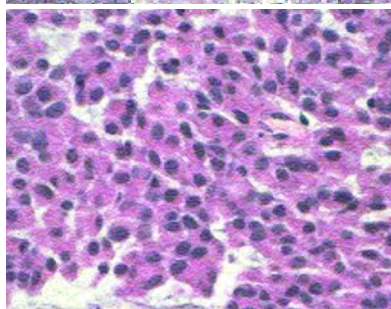
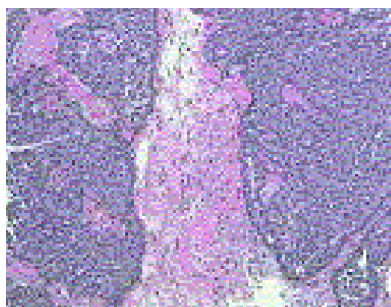


Fig. 1.48 Mucoepidermoid carcinoma. This low grade invasive carcinoma is morphologically similar to its counterpart in the salivary glands.

cy of ductal carcinoma in situ in association with adenosquamous carcinomas is variable. These tumours lack estrogen receptor expression [672,3142].

Prognosis and predictive factors

The majority of cases have an excellent prognosis, but a proportion of cases can behave in a locally aggressive manner [2995], recurrence appears to be related to adequacy of local excision. Lymph node metastatic spread is extremely rare and noted in a single case that was 3.5 cm [2995].

Mixed epithelial / mesenchymal metaplastic carcinomas

ICD-O code 8575/3

Synonyms

Carcinoma with osseous metaplasia (8571/3), carcinoma with chondroid metaplasia (8571/3), matrix producing carcinoma, carcinosarcoma (8980/3).

Histopathology

This wide variety of tumours, some of which are also regarded as "matrix producing carcinomas" [1414,2953], show infiltrating carcinoma mixed with often heterologous mesenchymal elements ranging from areas of bland chondroid and osseous differentiation to frank sarcoma (chondrosarcoma, osteosarcoma, rhabdomyosarcoma, liposarcoma, fibrosarcoma). When the mesenchymal component is malignant, the designation of carcinosarcoma is used. Undifferentiated spindle cell elements may form part of the tumour. Grading is based mainly on nuclear features and, to a lesser degree, cytoplasmic differentiation.

Immunoprofile

The spindle cell elements may show positive reactivity for cytokeratins, albeit focally. Chondroid elements are frequently S-100 positive and may coexpress cytokeratins, but are negative for actin. Many of these tumours are negative for ER and PR both in the adenocarcinoma and the mesenchymal areas, but the adenocarcinoma component may be ER and PR positive if well to moderately differentiated. In carcinosarcomas, the

mesenchymal component fails to immunoreact with any epithelial marker.

Differential diagnosis

The differential diagnosis varies for the different subtypes of metaplastic carcinoma.

Angiosarcoma may be confused with the acantholytic variant of squamous cell carcinoma, but focal areas of squamous differentiation can be found when sampled thoroughly. A negative immunoreaction with vascular endothelial markers and a positive reaction with cytokeratins will support the diagnosis of an epithelial neoplasm.

Fibromatosis and a variety of spindled mesenchymal tumours may be confused with spindle cell squamous carcinoma; these are all generally negative for epithelial markers.

Myoepithelial carcinoma is the most difficult lesion to distinguish from spindle cell squamous carcinoma. The former often has ducts with prominent to hyperplastic myoepithelial cells at its periphery, while the latter may have clear cut focal squamous differentiation. Reactions to a variety of immunostains may be similar, with the possible exception of those myoepithelial carcinomas that are diffusely S-100 positive. Electron microscopy may be needed to distinguish some of these lesions. Squamous carcinoma cells have abundant tonofilaments and well developed desmosomes whether spindled or polygonal. Intercellular bridges are abundant in the well differentiated areas. In contrast, the spindle cell myoepithelial carcinomas often have pinocytotic vesicles, myofibrils and basal lamina in addition to tonofilaments and desmosomes.

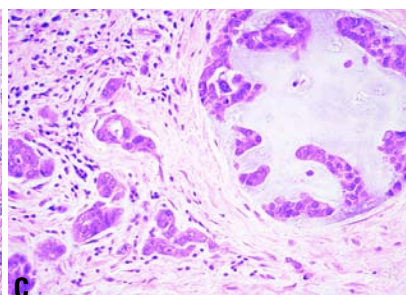
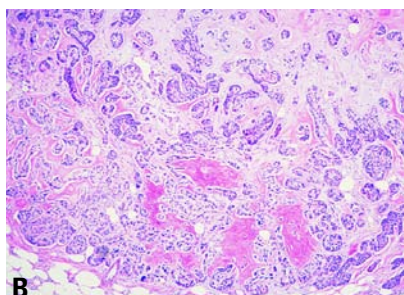
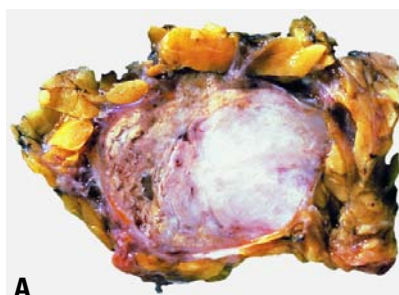

Fig. 1.49 **A** Metaplastic carcinoma with chondroid differentiation, 77 year old patient, mastectomy. **B** Carcinoma with mesenchymal (benign osseous and chondroid) differentiation. Typically, these carcinomas have a well delineated pushing margin. Areas of osseous and/or chondroid differentiation are variably scattered in an otherwise typical infiltrating ductal carcinoma. **C** Carcinoma with mesenchymal (benign osseous and chondroid) differentiation. The adenocarcinoma is admixed, in part, with chondroid matrix containing lacunar spaces and rare chondrocytes.

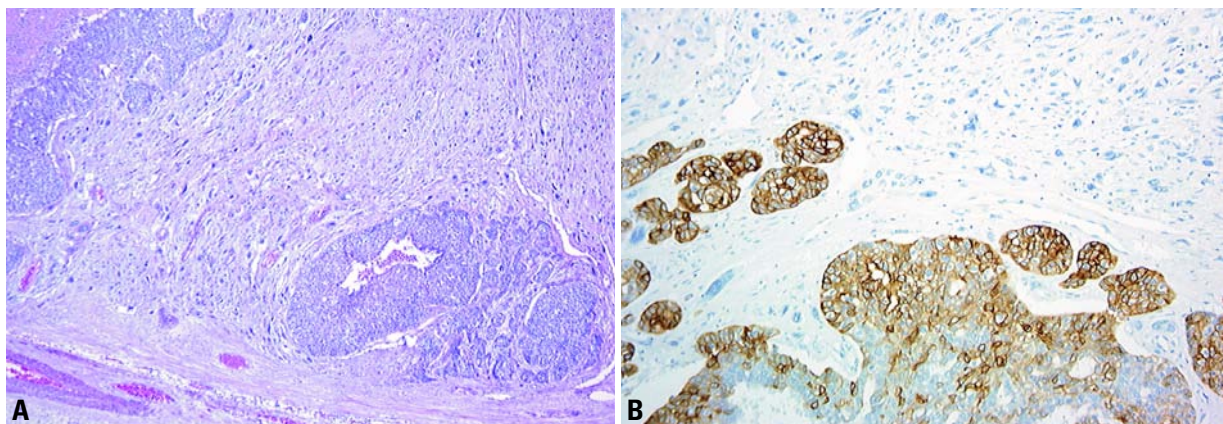


Fig. 1.50 Carcinosarcoma. **A** Two aggregates of carcinoma are separated by abundant sarcoma. **B** Immunostaining shows absence of reactivity with KerMix in the mesenchymal component, while the epithelial cells are positive.

The squamous and adenosquamous carcinoma should be distinguished from pleomorphic carcinomas that may have either pattern admixed with a large number of bizarre tumour giant cells; this distinction is important as pleomorphic carcinomas are far more aggressive than either squamous or adenosquamous carcinoma.

Adenocarcinomas with chondroid differentiation should be distinguished from pleomorphic adenomas. Pleomorphic adenomas invariably have a myoepithelial cell component (that may be dominant in some tumours) growing around spaces lined by benign epithelial cells. Myoepithelial cells are not evident in adenocarcinomas with chondroid differentiation.

Prognosis and predictive factors of metaplastic carcinomas

Given the tumour size of >3-4 cm in many cases, metastases to axillary nodes are relatively uncommon; approximately 10-15% of pure squamous cell carcinomas have axillary node metastases [503,1928]. About 19-25% of those with chondro-osseous elements have axillary node metastases [752,1273,2259], and 21% have distant metastases [752]. Axillary node metastases were more common (56%) among tumours with spindle and squamous metaplasia in Huvos's study [239], however. When metaplastic carcinomas metastasize to the axillary nodes or beyond, they retain and often manifest their metaplastic potential. In studies combining carcinomas with chondroid and osseous meta-

plasia, the five year survival has ranged from 28-68% [474,1273,3060]; those with spindle or squamous differentiation have a 63% 5-year survival [1273]. Advanced stage and lymph node involvement is associated with a more aggressive course as anticipated. Among squamous cell carcinomas, the acantholytic variant may exhibit a more aggressive behaviour [807].

The carcinosarcomas are very aggressive tumours. Some metastasize as mixed epithelial and mesenchymal tumours, while only the epithelial or the sarcomatous component may metastasize in others.

There is not much information available on the efficacy of current therapies in the management of metaplastic carcinomas.

Lipid-rich carcinoma

Definition

A breast carcinoma in which approximately 90% of neoplastic cells contain abundant cytoplasmic neutral lipids.

ICD-O code 8314/3

Synonym

Lipid secreting carcinoma.

Epidemiology

Using conventional morphological features only (i.e. foamy to vacuolated clear cells), incidences of <1-6%, have been reported [28,2330,2988]. Four cases only were seen within a 12-year period at

the AFIP [2876]. A frequency of 0.8% was found in a study using Sudan III on frozen sections [3158].

The age of patients with putative lipid rich carcinoma ranges from 33 to 81 years. All except one were female, the exception being a 55-year-old man [1803].

Clinical features

Most patients have palpable nodules. One case presented as Paget disease of the nipple [28].

Macroscopy

The tumour size in the cases reported varies from 1.2 to 15 cm [3158].

Histopathology

Lipid-rich carcinoma should be distinguished from other carcinomas with vacuolated, clear cytoplasm [702]. If histochemical methods are employed on frozen breast carcinomas, up to 75% contain cytoplasmic lipid droplets, but only 6% in large quantities [873]; only these cases should be designated lipid-rich carcinoma.

Histology shows a grade III invasive carcinoma in most cases. There may be associated in situ lobular or ductal carcinoma [28,2330]. The neoplastic cells have large, clear, foamy to vacuolated cytoplasm in which neutral lipids should be demonstrable [2876]. The tumour cells are devoid of mucins. Alpha lactalbumin and lactoferrin were found in five cases while fat globule membrane antigen was evident in occasional cells only [3158].

Lobular neoplasia

F.A. Tavassoli
R.R. Millis
W. Boecker
S.R. Lakhani

Definition

Characterized by a proliferation of generally small and often loosely cohesive cells, the term lobular neoplasia (LN) refers to the entire spectrum of atypical epithelial proliferations originating in the terminal duct-lobular unit (TDLU), with or without pagetoid involvement of terminal ducts. In a minority of women after long-term follow-up, LN constitutes a risk factor and a nonobligatory precursor for the subsequent development of invasive carcinoma in either breast, of either ductal or lobular type.

ICD-O code

Lobular carcinoma in situ (LCIS) 8520/2

Synonyms and historical annotation

The designations atypical lobular hyperplasia (ALH) and lobular carcinoma in situ (LCIS) have been widely used for variable degrees of the lesion. Two series published in 1978 [1100, 2438] concluded that the features generally used to subdivide the lobular changes into LCIS and ALH were not of prognostic significance. To avoid overtreatment, Haagensen suggested the designation lobular neoplasia (LN) for these lesions [1100]. To emphasize their non-invasive nature, the term lobular intraepithelial neoplasia (LIN) has been proposed. Based on morphological criteria and clinical outcome, LIN has been categorized into three grades [338].

Epidemiology

The frequency of LN ranges from less than 1% [3106,3107] to 3.8 % [1099] of all breast carcinomas. It is found in 0.5-4% of otherwise benign breast biopsies [2150]. Women with LN range in age from 15 [32] to over 90 years old [2876], but most are premenopausal.

Clinical features

The lesion is multicentric in as many as 85% of patients [2446,2876] and bilateral in 30% [1096] to 67% [2001] of women who had been treated by bilateral mas-

tectomy. No mammographic abnormalities are recognized [2128,2273], except in the occasional variant of LN characterized by calcification developing within central necrosis [2534].

Macroscopy

LN is not associated with any grossly recognizable features.

Histopathology

The lesion is located within the terminal duct-lobular unit [3091] with pagetoid involvement of the terminal ducts evident in as many as 75% of cases [86,1096]. On low power examination, while lobular architecture is maintained, the acini of one or more lobules are expanded to varying degrees by a monomorphic proliferation of loosely cohesive, usually small cells, with uniform round nuclei, indistinct nucleoli, uniform chromatin and rather indistinct cell margins with sparse cytoplasm. Necrosis and calcification are uncommon and mitoses are infrequent. Intracytoplasmic lumens are often present but are not specific to LN [89]. In some lesions, however, the proliferating cells are larger and more pleomorphic or of signet ring type. Apocrine metaplasia occurs but the existence of endocrine variant of LN [801] is disputed.

Two types of LN have been recognized [1100]: Type A with the more usual morphology described above and Type B composed of larger, more atypical cells with less uniform chromatin and conspi-

cuous nucleoli. The two cell types may be mixed. When composed of pleomorphic cells, the term pleomorphic LN has been used. The neoplastic cells either replace or displace the native epithelial cells in the TDLU. The myoepithelial cells may remain in their original basal location or they may be dislodged and admixed with the neoplastic cells. The basement membrane is generally intact although this is not always visible in all sections. Pagetoid involvement of adjacent ducts between intact overlying flattened epithelium and underlying basement membrane is frequent and can result in several different patterns including a 'clover leaf' or 'necklace' appearance [1099]. Solid obliteration of acini may occur, sometimes with massive distension and central necrosis. LN may involve a variety of lesions including sclerosing adenosis, radial scars, papillary lesions, fibroadenomas and collagenous spherulosis.

Immunoprofile

LN is positive for estrogen receptor (ER) in 60-90% of cases and in a slightly lower percentage for progesterone receptor (PR) [62,369,1010,2159,2483]. The classical variety of LN is more likely to be positive than the pleomorphic variant [223,2683]. Unlike high grade DCIS, however, classic LN rarely expresses ERBB2 or TP53 protein [62,2327a,2483, 2746]. Positivity is more likely with the pleomorphic variant [1859,2683]. Intra-

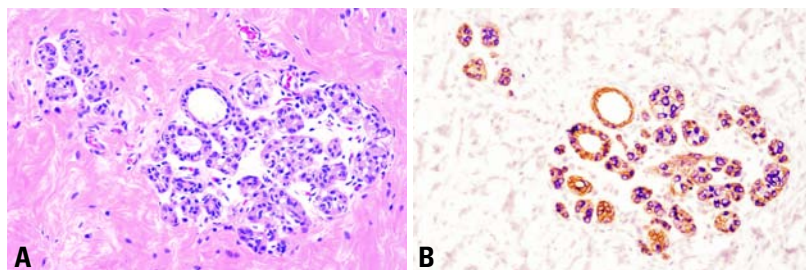


Fig. 1.74 Early lobular neoplasia. **A** The few neoplastic lobular cells are hardly apparent on a quick examination of the TDLU. **B** Double immunostaining with E-cadherin (brown) and CK34BE12 (purple) unmasks the few neoplastic cells (purple) proliferating in this lobule. These early lesions are often missed on H&E stained sections.

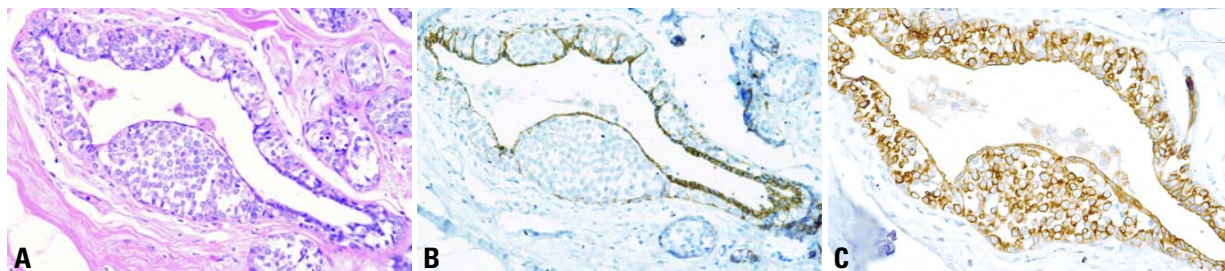


Fig. 1.75 Lobular neoplasia. **A** Aggregates of loosely cohesive neoplastic cells proliferate beneath the native epithelial cell lining (pagetoid growth pattern). **B** Typically, the neoplastic cells are E-cadherin negative. **C** Immunostain for CK34BE12 shows a polarized positive reaction in the cytoplasm.

cytoplasmic immunoreactivity for casein has also been reported [1994,2149]. E-cadherin, commonly identified in ductal lesions, is generally absent from both LN and invasive lobular carcinoma [1892,2336].

Grading

A three tiered grading system has been suggested, based on the extent and degree of proliferation and/or cytological features. Those lesions with markedly distended acini, often with central necrosis, and those composed of either severely pleomorphic cells or pure signet ring cells with or without acinar distension, were designated LIN 3; they have been reported to be often associated with invasive carcinoma [2876]. This grading system requires validation by other centres and is not endorsed at this time.

Differential diagnosis

Poor tissue preservation may give a false impression of loosely cohesive cells leading to over-diagnosis of LN. Distinction from a solid DCIS can be difficult on morphological grounds alone, particularly when DCIS remains confined

to the lobule without unfolding it (so called lobular cancerization). The presence of secondary lumina or a rosette-like arrangement of cells indicates a ductal lesion. In problematic cases, the immunoprofile may be helpful. LN is typically E-cadherin and CK 5,6 negative, but HMW CK34BE12 positive [337]. DCIS, on the other hand, is typically E-cadherin positive, but CK34BE12 negative. Occasional lesions are negative or positive for both HMWCK34BE12 and E-cadherin markers. Since, at present, it is uncertain how these morphologically and immunohistochemically hybrid lesions with ductal and lobular features would behave, it is important that they are recognized so that more can be learned about their nature in the future [337].

When LN involves sclerosing adenosis or other sclerosing lesions, it can be confused with an invasive carcinoma. The presence of a myoepithelial cell layer around the neoplastic cell clusters excludes the possibility of an invasive carcinoma; immunostaining for actin can unmask the myoepithelial cells, thus facilitating the distinction.

Presence of isolated cells invading the stroma around a focus of LN can cause diagnostic problems. Absence of myoepithelial cells around the individual cells and their haphazard distribution accentuated by any of the epithelial markers (optimally with double immunostaining techniques) can help establish the presence of stromal invasion by individual or small clusters of neoplastic cells.

Molecular genetics

Loss of heterozygosity (LOH) at loci frequently observed in invasive carcinoma has also been reported in LN, ranging from 8% on chromosome 17p to 50% on 17q [1569]. LOH on chromosome 16q,

the site of the E-cadherin gene, was found in approximately 30%. LOH was identified in LN associated with invasive carcinoma and in pure LN, suggesting that it may be a direct precursor of invasive lobular cancer. Further support for this hypothesis has come from a report that showed LOH in 50% of LN associated with invasive carcinoma at markers on chromosome 11q13 [1988]. LOH was seen in 10% of ALH and 41% of invasive lobular carcinomas. Using comparative genomic hybridization (CGH), loss of chromosomal material from 16p, 16q, 17p and 22q and gain of material to 6q was identified in equal frequency in 14 ALH and 31 LCIS

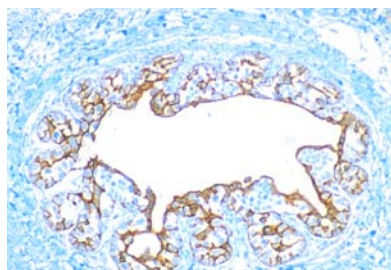


Fig. 1.76 Lobular neoplasia. CK5/6 immunohistochemistry demonstrating the pagetoid spread of tumour cells infiltrating the positively stained original epithelium, leading to a reticulated staining pattern.

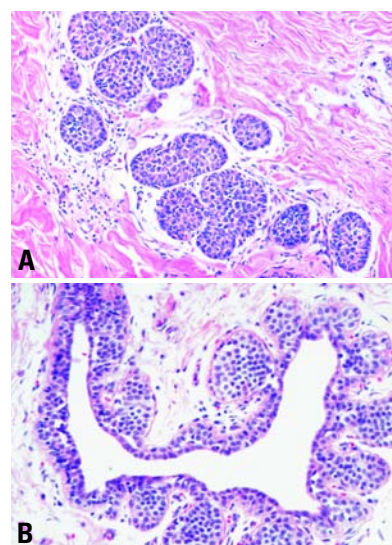


Fig. 1.77 Lobular neoplasia. **A** The acini are filled and moderately distended by neoplastic cells; the acinar outlines are retained. **B** Clover-leaf pattern. This is one of the classic patterns of LN, with the acini distended by neoplastic cells pulling away from the intralobular segment of the terminal duct, creating a clover-leaf or necklace appearance.

lesions [1707], suggesting that both are 'neoplastic' and at a similar stage of genetic evolution.

The most direct evidence for a precursor role of LN comes from mutational analysis of the E-cadherin gene [259,260]. In one study [261], 27 of 48 (56%) invasive lobular carcinomas had mutation in the E-cadherin gene, while none of 50 breast cancers of other types showed any alteration. It was subsequently demonstrated that truncating mutations identified in invasive lobular carcinoma were also present in the adjacent LN, providing direct proof that LN was a precursor lesion [3034].

Prognosis and predictive factors

The relative risk (RR) for subsequent development of invasive carcinoma among patients with LN ranges from 6.9 to about 12 times that expected in women without LN [87,88,1100].

Amongst 1174 women in 18 separate retrospective studies, diagnosed as having LN and treated by biopsy alone, 181 (15.4%) eventually developed invasive carcinoma [88,1096,1100,2150,2428,2438]. Of these, 102 (8.7%) developed in the ipsilateral breast, and 79 (6.7%) in the contralateral breast, demonstrating an almost equal risk for either breast. However, in a prospective study of 100 cases of LN with 10 years of follow-up, 11 of 13 invasive recurrences were ipsilateral [2127].

With extended follow-up, the risk of development of invasive cancer continues to increase to 35% for those women who survive 35 years after their initial diagnosis of LN. Furthermore, the RR increases substantially from 4.9 (95% CI: 3.7–6.4) after one biopsy with LN to 16.1 (95% CI: 6.9–31.8) after a second biopsy with LN [298].

Early studies suggested that among LN lesions, there are no clinical or pathological features associated with increased risk of subsequent invasive carcinoma [2150,2438]. However, a more recent study using the three tiered grading system, but with a comparatively short follow-up of 5 years, found that LIN 3 and, to a lesser extent LIN 2, were associated with an increased risk [869], but LIN 1 was not. In another study, 86% of invasive carcinomas associated with LIN 3 were lobular in type, in contrast to 47% of those associated with LIN 2 and only 11% of those associated with LIN 1 [338].

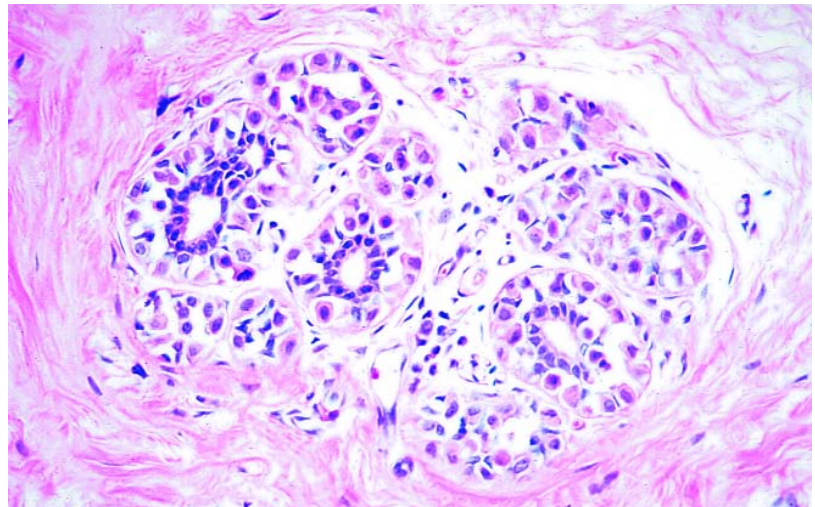


Fig. 1.78 Lobular neoplasia. Loosely cohesive neoplastic cells are proliferating in this lobule, but they have not distended the acini.

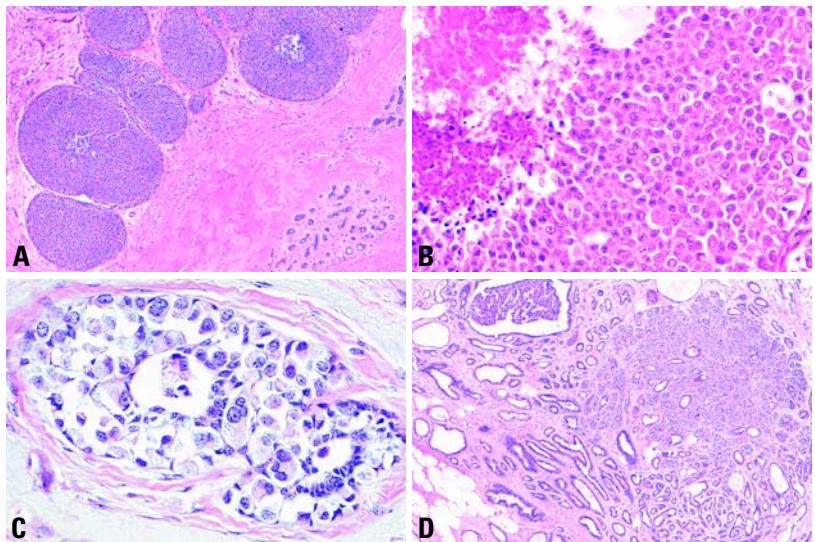


Fig. 1.79 Lobular neoplasia. **A** Necrotic type with massive distention of the acini. **B** Note the loosely cohesive cells and the necrosis. **C** Lobular neoplasia, pleomorphic type. Even though there is not a significant distention of the involved TDLU, the neoplastic cells are highly pleomorphic and loosely cohesive. This is the intraepithelial counterpart of pleomorphic invasive lobular carcinoma. **D** LN involving sclerosing adenosis. The lobulated configuration of the sclerosing adenosis is apparent at low magnification. The ductules in part of the lesion are filled and expanded by proliferation of a monotonous neoplastic cell population. This setting may be confused with invasive carcinoma, particularly when the sections are suboptimal.

Management of LN has evolved with increased understanding of the disease [1082]. The current consensus is that LN constitutes a risk factor and a non obligate precursor for subsequent development of invasive carcinoma in either breast, of either ductal or lobular type, but only in a minority of women after

long-term follow-up. The current recommended management for LN is, therefore, life long follow-up with or without tamoxifen treatment. Re-excision should be considered in cases of massive acinar distension, and when pleomorphic, signet ring or necrotic variants are identified at or close to the margin.

Intraductal proliferative lesions

F.A. Tavassoli
H. Hoeffler
J. Rosai
R. Holland
I.O. Ellis
S.J. Schnitt
W. Boecker
S.H. Heywang-Köbrunner
F. Moinfar
S.R. Lakhani

Definition

Intraductal proliferative lesions are a group of cytologically and architecturally diverse proliferations, typically originating from the terminal duct-lobular unit and confined to the mammary duct lobular system. They are associated with an increased risk, albeit of greatly different magnitudes, for the subsequent development of invasive carcinoma.

ICD-O codes

In the ICD-O classification, /2 is used for in situ carcinomas. The code 8500/2 covers all grades of ductal carcinoma in situ and ductal intraepithelial neoplasia, grade 3.

Site of origin and route of lesion progression

A vast majority of intraductal proliferative lesions originate in the terminal duct-lobular unit (TDLU) [3091]. A substantially smaller proportion originates in larger and lactiferous ducts.

Segmentally distributed, ductal carcinoma in situ (DCIS) progression within the duct system is from its origin in a TDLU toward the nipple and into adjacent branches of a given segment of the duct system. The rare lesions that develop within the lactiferous ducts may progress toward the nipple resulting in Paget disease or to the adjacent branches of a reference duct [2089,2090,2093].

Terminology

Intraductal proliferative lesions of the breast have traditionally been divided into three categories: usual ductal hyperplasia (UDH), atypical ductal hyperplasia (ADH) and ductal carcinoma in situ (DCIS). It should be noted, however, that the term "DCIS" encompasses a highly heterogeneous group of lesions that differ with regard to their mode of presentation, histopathological features, biological markers, and risk for progression to invasive cancer. In most cases, the histopathological distinction between different types of intraductal proliferation can be made on morphological grounds

alone, particularly with standardization of histopathological criteria. However, even then, the distinction between some of the lesions (particularly between ADH and some low grade forms of DCIS) remains problematic. In addition, population-based mammography screening has resulted in increased detection of lesions that show cytological atypia with or without intraluminal proliferation but do not fulfil the diagnostic criteria for any of the existing categories. Those lesions lacking intraluminal projection have been described in the past as clinging carcinoma and more recently referred to under a variety of names including flat epithelial atypia, atypical cystic lobules, atypical columnar alteration with prominent apical snouts and secretions.

Progression to invasive breast cancer

Clinical follow-up studies have indicated that these intraductal proliferative lesions are associated with different levels of risk for subsequent development of invasive breast cancer, that ranges from approximately 1.5 times that of the reference population for UDH, to 4-5-fold (range, 2.4-13.0-fold) for ADH, and 8-10-fold for DCIS [886]. Recent immunophenotypic and molecular genetic studies have provided new insights into these lesions indicating that the long-held notion of a linear progression from normal epithelium through hyperplasia, atypical hyperplasia and carcinoma in situ to invasive cancer is overly simplistic; the inter-relationship between these various intraductal proliferative lesions and invasive breast cancer is far more complex. In brief, these data have suggested that: (1) UDH shares few similarities with most ADH, DCIS or invasive cancer; (2) ADH shares many similarities with low grade DCIS; (3) low grade DCIS and high grade DCIS appear to represent genetically distinct disorders leading to distinct forms of invasive breast carcinoma, further emphasizing their heterogeneity; and (4) at least some lesions with flat epithelial atypia are neoplastic. These data support the notion that ADH and all forms of DCIS represent intra-

epithelial neoplasias which in the WHO classification of tumours of the digestive system have been defined as 'lesions characterized by morphological changes that include altered architecture and abnormalities in cytology and differentiation; they result from clonal alterations in genes and carry a predisposition, albeit of variable magnitude, for invasion and metastasis' [1114]. The WHO Working Group felt that UDH is not a significant risk factor and that at the time of the meeting, there was insufficient genetic evidence to classify it as a precursor lesion. However, a recent CGH study suggests that a subset of UDH can be a precursor of ADH [1037].

Classification and grading

These emerging genetic data and the increasingly frequent detection of ADH and low grade DCIS by mammography have raised important questions about the manner in which intraductal proliferative lesions are currently classified.

Although used by pathology laboratories worldwide, the traditional classification system suffers from high interobserver variability, in particular, in distinguishing between atypical ductal hyperplasia (ADH) and some types of low grade ductal carcinoma in situ (DCIS). Some members of the Working Group proposed that the traditional terminology be replaced by ductal intraepithelial neoplasia (DIN), reserving the term carcinoma for invasive tumours. This would help to avoid the possibility of overtreatment, particularly in the framework of population-based mammography screening programmes. In several other organ sites, the shift in terminology has already occurred e.g. cervix (CIN), prostate (PIN) and in the recent WHO classification of tumours of the digestive system [1114].

The majority of participants in the WHO Working Group was in favour of maintaining the traditional terminology which in Table 1.11 is shown next to the corresponding terms of the DIN classification. For purposes of clinical management and tumour registry coding, when the

DIN terminology is used, the traditional terminology should be mentioned as well. The classification of intraductal proliferative lesions should be viewed as an evolving concept that may be modified as additional molecular genetic data become available.

Diagnostic reproducibility

Multiple studies have assessed reproducibility in diagnosing the range of intraductal proliferative lesions, some with emphasis on the borderline lesions {299, 503, 2155, 2157, 2411, 2571, 2723, 2724}. These studies have clearly indicated that interobserver agreement is poor when no standardized criteria are used {2411}. Although diagnostic reproducibility is improved with the use of standardized criteria {2571} discrepancies in diagnosis persist in some cases, particularly in the distinction between ADH and limited forms of low grade DCIS. In one study, consistency in diagnosis and classification did not change significantly when interpretation was confined to specific images as compared with assessment of the entire tissue section on a slide, reflecting inconsistencies secondary to differences in morphological interpretation {780}. While clinical follow-up studies have generally demonstrated increasing levels of breast cancer risk associated with UDH, ADH and DCIS respectively, concerns about diagnostic reproducibility have led some to question the practice of utilizing these risk estimates at the individual level {299}.

Aetiology

In general, the factors that are associated with the development of invasive breast carcinoma are also associated with increased risk for the development of intraductal proliferative lesions {1439a, 1551a, 2536a}. (See section on epidemiology of breast carcinoma).

Genetics of precursor lesions

To date, several genetic analyses have been performed on potential precursor lesions of carcinoma of the breast. The sometimes contradictory results (see below) may be due to: (i) small number of cases analysed, (ii) the use of different histological classification criteria, (iii) histomorphological heterogeneity of both the normal and neoplastic breast tissue and (iv) genetic heterogeneity, as identified by either conventional cytogenetics {1175} or by fluorescence in situ hybridization

Table 1.11

Classification of intraductal proliferative lesions.

Traditional terminology	Ductal intraepithelial neoplasia (DIN) terminology
Usual ductal hyperplasia (UDH)	Usual ductal hyperplasia (UDH)
Flat epithelial atypia	Ductal intraepithelial neoplasia, grade 1A (DIN 1A)
Atypical ductal hyperplasia (ADH)	Ductal intraepithelial neoplasia, grade 1B (DIN 1B)
Ductal carcinoma in situ, low grade (DCIS grade 1)	Ductal intraepithelial neoplasia, grade 1C (DIN 1C)
Ductal carcinoma in situ, intermediate grade (DCIS grade 2)	Ductal intraepithelial neoplasia, grade 2 (DIN 2)
Ductal carcinoma in situ, high grade (DCIS grade 3)	Ductal intraepithelial neoplasia, grade 3 (DIN 3)

(FISH) analysis {1949}. Further evidence for genetic heterogeneity comes from comparative genomic hybridization (CGH) data of microdissected tissue in usual ductal hyperplasia (UDH), atypical ductal hyperplasia (ADH) {135} and DCIS {134, 366}.

There has been a tendency to interpret loss of heterozygosity as evidence for clonal evolution and neoplastic transformation. However, histologically normal ductal epithelium closely adjacent to invasive ductal carcinoma may share an LOH pattern with the carcinoma, while normal ducts further away in the breast do not {671}. LOH has been reported in normal epithelial tissues of the breast, in association with carcinoma and in reduction mammoplasties, however, the significance of these findings remains to be evaluated {671, 1586, 1945}. LOH has also been identified in the stromal component of in situ {1889} and invasive breast carcinoma {1545, 1889}, in non-neoplastic tissue from reduction mammoplasty specimens {1568}, and in normal-appearing breast ducts {1586}. The biological significance of these alterations are still poorly understood, but the available data suggest that genetic alterations may occur very early in breast tumorigenesis prior to detectable morphological changes and that epithelial/stromal interactions play a role in progression of mammary carcinoma.

Clinical features

The age range of women with intraductal proliferative lesions is wide, spanning 7

to 8 decades post adolescence. All these lesions are extremely rare prior to puberty; when they do occur among infants and children, they are generally a reflection of exogenous or abnormal endogenous hormonal stimulation. The mean age for DCIS is between 50-59 years. Though most often unilateral, about 22% of women with DCIS in one breast develop either in situ or invasive carcinoma in the contralateral breast {3055}.

Macroscopy

A vast majority of intraductal proliferative lesions, particularly those detected mammographically, are not evident on macroscopic inspection of the specimen. A small proportion of high grade DCIS may be extensive enough and with such an abundance of intraluminal necrosis or associated stromal reaction that it would present as multiple areas of round, pale comedo necrosis or a firm, gritty mass.

Usual ductal hyperplasia (UDH)

Definition

A benign ductal proliferative lesion typically characterized by secondary lumens, and streaming of the central proliferating cells. Although not considered a precursor lesion, long-term follow-up of patients with UDH suggests a slightly elevated risk for the subsequent development of invasive carcinoma.

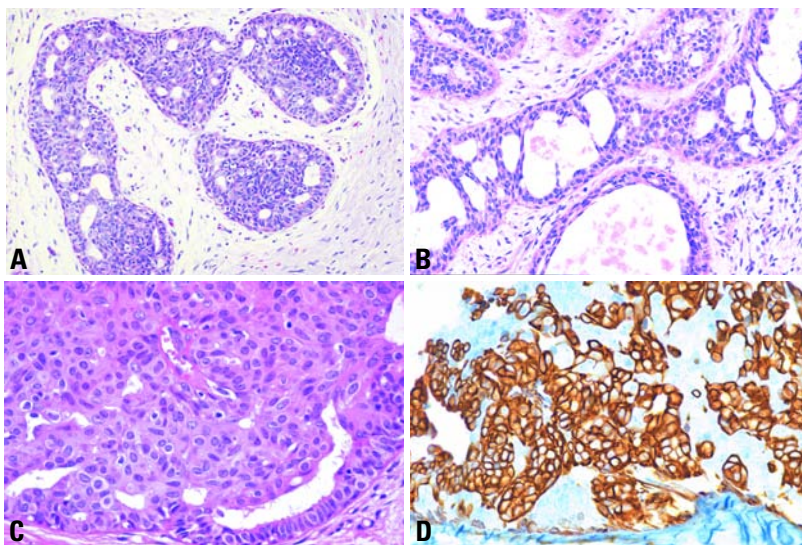


Fig. 1.80 Usual ductal hyperplasia. **A** Florid type. The peripheral distribution of irregularly sized spaces is a characteristic of UDH readily apparent at low magnification. **B** The proliferating cells may form epithelial bridges, but the bridges are delicate and formed by spindled stretched cells. **C** Intensive, predominantly solid intraductal proliferation of a heterogeneous cell population. Note spindling of the cells. Several irregular peripheral luminal spaces. **D** Intraluminal proliferation with many CK5-positive and occasional CK5-negative cells.

Synonyms

Intraductal hyperplasia, hyperplasia of the usual type, epitheliosis, ordinary intraductal hyperplasia.

Mammography

UDH does not have a mammographic presentation, except in rare cases with microcalcification.

Risk of progression

Long-term follow up of patients with UDH in one study showed that 2.6% develop subsequent invasive carcinoma after an average interval of over 14 years, compared to 8.3 years for those with ADH [2886]. In another study, the absolute risk of a woman with UDH developing breast cancer within 15 years was 4% [732]. The Cancer Committee of the College of American Pathologists has assigned UDH a slightly increased risk (RR of 1.5-2.0) for subsequent development of invasive carcinoma [885].

Histopathology

UDH is characterized by irregularly shaped and sized secondary lumens, often peripherally distributed, and streaming of the central bolus of proliferating cells. Epithelial bridges are thin and stretched; nuclei are unevenly distributed.

In some cases, the proliferation has a solid pattern and no secondary lumens are evident. Cytologically, the lesion is composed of cells with indistinct cell margins, variation in the tinctorial features of the cytoplasm and variation in shape and size of nuclei. Admixture of epithelial, myoepithelial or metaplastic apocrine cells is not uncommon. The presence or

Table 1.12

Usual ductal hyperplasia.

Architectural features

1. Irregular fenestrations
2. Peripheral fenestrations
3. Stretched or twisted epithelial bridges
4. Streaming
5. Uneven distribution of nuclei and overlapped nuclei

Cellular features

1. Multiple cell types
2. Variation in appearance of epithelial cells
3. Indistinct cell margins and deviation from a round contour
4. Variation in the appearance of nuclei

One of the most important indicators of UDH is the presence of an admixture of two or more cell types (epithelial, myoepithelial and/or metaplastic apocrine cells).

absence of either microcalcifications or necrosis does not impact the diagnosis. UDH with necrosis, a rare event, may be mistaken for DCIS; the diagnosis should be based on the cytological features and not the presence of necrotic debris. UDH generally displays either diffuse or a mosaic pattern of positivity with high molecular weight cytokeratins {1963, 2126} such as CK5, CK1/5/10/14 (clone CK34betaE12 or clone D5/16 B4); it is also positive for E-cadherin. In UDH, the percentage of ER-positive cells was found slightly increased compared to the normal breast [2667]. Increased levels of cyclin D1 expression were recently described in 11-19% of UDH cases [1172,3264].

Genetic alterations

Approximately 7% of UDH show some degree of aneuploidy. Loss of heterozygosity (LOH) for at least one locus, has been noted in one-third of UDH [2071]. On chromosome 11p, LOH was present in 10-20% of UDH cases [72,2071]. Losses on 16q and 17p were identified in UDH lesions without evidence of adjacent carcinoma [1037] whereas no alterations were reported by others [301]. In UDH adjacent to carcinoma, polysomy of chromosome 1 as well as increased signal frequencies for the 20q13 region (typically present in DCIS) were identified by FISH [593,3100]. By CGH, UDH lesions adjacent to carcinoma showed gain on chromosome 20q and loss on 13q in 4 of 5 cases [136], although no alteration was reported in another study [301]. Some recent CGH studies suggest that a proportion of UDH lesions is monoclonal [1037,1358], and that a subset shows alterations similar to those observed in ADH [1037]; however, the frequency of genetic alterations seen in UDH using LOH and CGH is much lower than in ADH. TP53 protein expression has not been demonstrated in UDH or in any other benign proliferative lesions [1567]. Mutations of the *TP53* gene are also absent, except as inherited mutations in Li-Fraumeni patients [72].

Flat epithelial atypia

Definition

A presumably neoplastic intraductal alteration characterized by replacement of the native epithelial cells by a single or 3-5 layers of mildly atypical cells.

Synonyms

Ductal intraepithelial neoplasia 1A (DIN 1A); clinging carcinoma, monomorphous type; atypical cystic lobules; atypical lobules, type A; atypical columnar change.

Risk of progression

Some cases of flat epithelial atypia may progress to invasive breast cancer but no quantitative epidemiological data are currently available for risk estimation.

Histopathology

A flat type of epithelial atypia, this change is characterized by replacement of the native epithelial cells by a single layer of mildly atypical cells often with apical snouts, or proliferation of a monotonous atypical cell population in the form of stratification of uniform, cuboidal to columnar cells generally up to 3-5 cell layers with occasional mounding. Arcades and micropapillary formations are absent or very rare. The TDLUs involved are variably distended and may contain secretory or floccular material that often contains microcalcifications.

Genetic alterations

Data on genetic alterations in flat epithelial atypia are limited. LOH has been found in at least one locus in 70% of cases in a study evaluating eight loci in thirteen lesions [1889]. LOH on 11q (D11S1311) was the most commonly noted in 50% of the pure flat atypia,

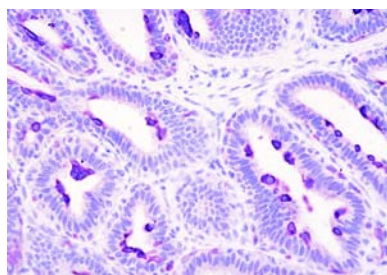


Fig. 1.82 Flat epithelial atypia. Immunostain for CK34 E12 shows no staining in the neoplastic cells lining the ductules, but the residual luminal epithelial cells adherent along the luminal surface show intense staining.

while among seven flat atypias associated with infiltrating carcinomas, the frequency of LOH on 11q (D11S1311) was 57% [1889].

Atypical ductal hyperplasia (ADH)

Definition

A neoplastic intraductal lesion characterized by proliferation of evenly distributed, monomorphic cells and associated with a moderately elevated risk for progression to invasive breast cancer.

Synonyms

Ductal intraepithelial neoplasia 1B (DIN 1B), atypical intraductal hyperplasia.

Risk of progression

The Cancer Committee of the College of American Pathologists has assigned ADH a moderately increased risk (RR of 4.0-5.0) for subsequent development of invasive breast cancer [885]. Following a breast biopsy diagnosis of ADH, 3.7-22% of the women develop invasive carcinomas [299,733,1520,2886]. On the other hand, ADH has also been present in 2.2% [2158] to 10.5% [1688] of controls who did not develop subsequent carcinoma. The average interval to the subsequent development of invasive carcinoma is 8.3 years compared to 14.3 years for women with UDH [2886].

However, drastically different relative risk (RR) estimations have been reported for ADH, ranging from a low of 2.4 to a high of 13 [412,732,1688,1775,1830,2155,2158]. The upper values are even higher than the RR of 8-11 suggested for DCIS [732,885]. On the other hand, the RR of 2.4 for ADH reported in one study [1775] is much closer to the RR of 1.9 associated with UDH.

Histopathology

The most distinctive feature of this lesion is the proliferation of evenly distributed, monomorphic cells with generally ovoid to rounded nuclei. The cells may grow in micropapillae, tufts, fronds, arcades, rigid bridges, solid and cribriform patterns. Cytologically, ADH corresponds to low grade DCIS.

ADH is diagnosed when characteristic cells coexist with patterns of UDH, and/or there is partial involvement of TDLU by classic morphology. There is currently no general agreement on whether quantitative criteria should be applied to separate ADH from low grade DCIS. Some define the upper limit of ADH as one or more completely involved duct/ductular cross sections measuring 2 mm in aggregate, while others require that the characteristic cytology and architecture be present completely in two spaces. Microcalcifications may be absent, focal or extensive within the lumen of involved ducts; its presence does not impact diagnosis.

Immunoprofile

ERBB2 protein overexpression is rare in ADH [72,1172], in contrast to high amplification rates in high grade DCIS, suggesting that ERBB2 alterations are either

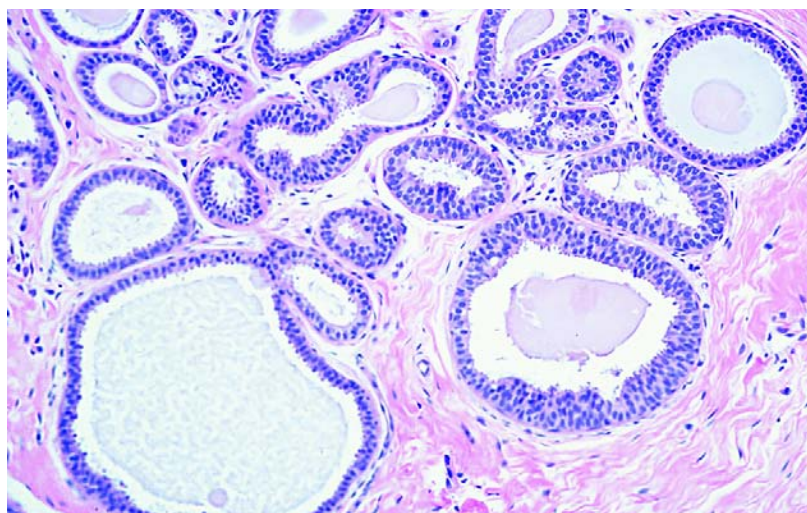


Fig. 1.81 Flat epithelial atypia. A terminal duct-lobular unit with distended acini and a floccular secretory luminal content. The spaces are lined by one to three layers of monotonous atypical cells.

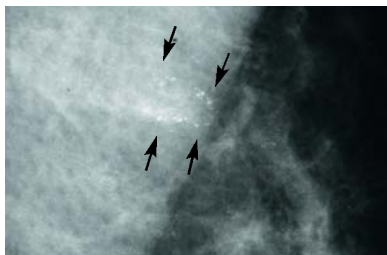


Fig. 1.83 Atypical ductal hyperplasia. Several rounded calcifications, possibly including 1-2 “tea cup” shaped calcifications are seen. Usually such calcifications indicate benign changes. However, the calcifications appear to follow two ducts. Furthermore, a faint group of very fine microcalcifications can barely be perceived.

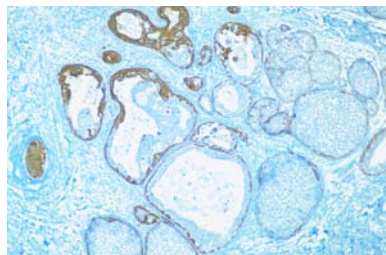


Fig. 1.84 Atypical ductal hyperplasia. A terminal duct-lobular unit with dilated ductules that are partly filled with a CK5/6 negative ductal proliferation which on H&E had the characteristics of a low grade DCIS. Note on the left side some cyokeratin positive ductules.

not an early event in malignant transformation or that they are largely restricted to high grade DCIS. Increased levels of cyclin D1 expression were recently described in 27-57% of ADH [1172, 3264]. Nuclear accumulation of the TP53 protein is absent in ADH and low grade DCIS [1567]. Nearly 90% of ADH are negative for high molecular weight cytokeratins 1/5/10/14 (clones CK34BetaE12 and D5/16 B4), an important feature in separating ADH from UDH [1963,2126].

Genetic alterations

Fifty percent of ADH cases share their LOH patterns with invasive carcinomas from the same breast, strongly supporting a precursor relationship between these lesions [1567]. LOH has been identified frequently on chromosomes 16q, 17p, and 11q13 [1567,1570]. *TP53* mutations are restricted to affected members of Li-Fraumeni families.

Ductal carcinoma in situ (DCIS)

Definition

A neoplastic intraductal lesion characterized by increased epithelial proliferation, subtle to marked cellular atypia and an inherent but not necessarily obligate tendency for progression to invasive breast cancer.

ICD-O code 8500/2

Synonyms

Intraductal carcinoma, ductal intraepithelial neoplasia (DIN 1C to DIN 3).

Risk of progression

DCIS is considered a precursor lesion (obligate or non-obligate), with a relative risk (RR) of 8-11 for the development of invasive breast cancer [732,885]. However, there is evidence that conser-

vative treatment (complete local eradication) is usually curative (see below).

Epidemiology

A striking increase in the detection of DCIS has been noted with the introduction of widespread screening mammography and increasing awareness of breast cancer in the general population since 1983. The average annual increase in the incidence rate of DCIS in the decade of 1973 to 1983 was 3.9% compared to 17.5% annually in the decade between 1983 to 1992, increasing from 2.4 per 100,000 women in 1973 to 15.8 per 100,000 in 1992 for women of all races, an overall increase of 557% [794]. In the US, data from the National Cancer Institute's Surveillance, Epidemiology and End Results (SEER) program noted that the proportion of breast carcinomas diagnosed as DCIS increased from 2.8% in 1973 to 14.4% in 1995 [794]. While close to 90% of pre-mammography DCIS were of the high grade comedo type, nearly 60% of mammographically detected lesions are non-comedo and this percentage is increasing.

Interestingly, despite the more limited surgical excisions, mortality from "DCIS" has declined. Of women with DCIS diagnosed between 1978 and 1983 (pre-mammographic era), 3.4% died of breast cancer at 10 years, despite having been treated by mastectomy in the vast majority of cases. On the other hand, only 1.9% of women diagnosed with DCIS between 1984 and 1989 died of breast cancer at 10 years, despite the increasing trend toward lumpectomy [794]. Judging from the 10-year follow-

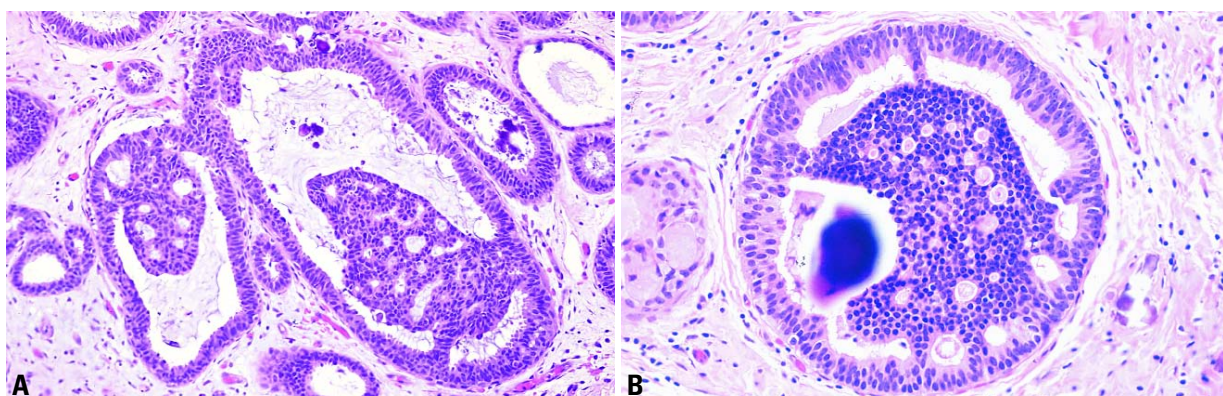


Fig. 1.85 Atypical ductal hyperplasia. **A** Two adjacent ducts showing partial cribriform involvement in a background of flat epithelial atypia. **B** Partial involvement of a duct by a cribriform proliferation of uniform, rounded cells in the setting of a flat epithelial atypia. Microcalcification is also present.

up period currently available for these women, it appears as if "DCIS per se is not a life threatening disease" [794]. The deaths that do occur are related to an undetected invasive carcinoma present at the time of the initial diagnosis of DCIS, progression of residual incompletely excised DCIS to invasive carcinoma, or development of a de novo invasive carcinoma elsewhere in the breast [794].

Clinical features

In countries where population screening is performed, the vast majority of DCIS (>85%) are detected by imaging alone. Only approximately 10% of DCIS are associated with some clinical findings and up to 5% is detected incidentally in surgical specimens, obtained for other reasons. Clinical findings, which may be associated with DCIS include (i) palpable abnormality, (ii) pathological nipple discharge and (iii) nipple alterations associated with Paget disease.

Imaging

Mammography constitutes by far the most important method for the detection of DCIS. In current screening programs, 10-30% of all detected 'malignancies' are DCIS [810,1280]. In the majority of cases, mammographic detection is based on the presence of significant microcalcifications that are associated with most of these lesions [1206, 1231,2796].

Calcifications associated with well differentiated DCIS are usually of the laminated, crystalline type resembling psammoma bodies. They often develop as pearl-like particles in the luminal spaces within the secretion of the tumour and appear on the mammogram as multiple clusters of granular microcalcifications that are usually fine. These multiple clusters reflect the frequent lobular arrangement of this type of DCIS. Calcifications associated with poorly differentiated DCIS, are, histologically, almost exclusively of the amorphous type developing in the necrotic areas of the tumour. They appear on the mammogram as either linear, often branching, or as coarse, granular microcalcifications.

Calcifications associated with the intermediately differentiated DCIS may be of either the amorphous or the laminated type.

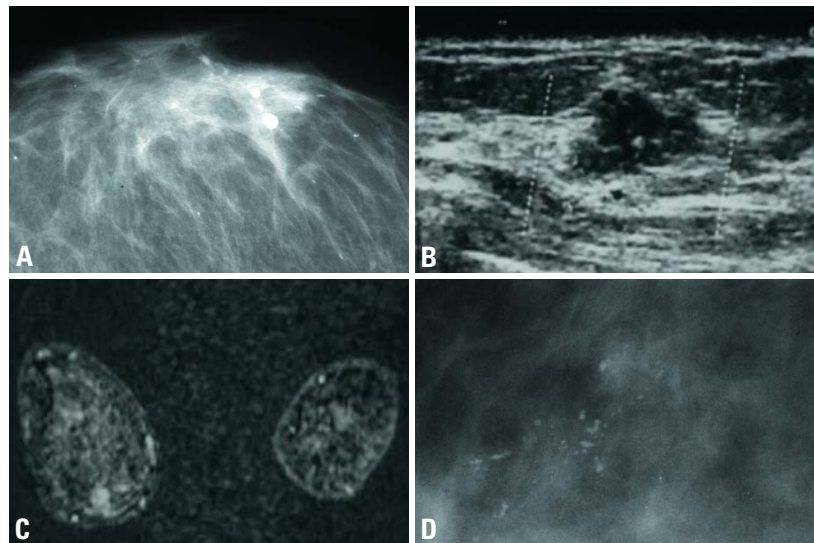


Fig. 1.86 Ductal carcinoma in situ images. **A** This galactogram was performed because of pathologic discharge from a single duct. On the galactogram multiple filling defects and truncation of the duct (approx. 4 cm behind the nipple) are demonstrated. **B** Low grade cribriform DCIS. In this patient, an ill circumscribed nodular nonpalpable (8 mm) low grade cribriform DCIS was detected by ultrasound. **C** MRI of an intermediate grade papillary DCIS. A strongly enhancing somewhat ill circumscribed lesion is visualized at 6 o'clock in the patient's right breast (coronal plane). **D** High grade comedo-type DCIS. Highly suspicious coarse granular and pleomorphic microcalcifications are shown, which follow the ductal course indicating presence of a DCIS.

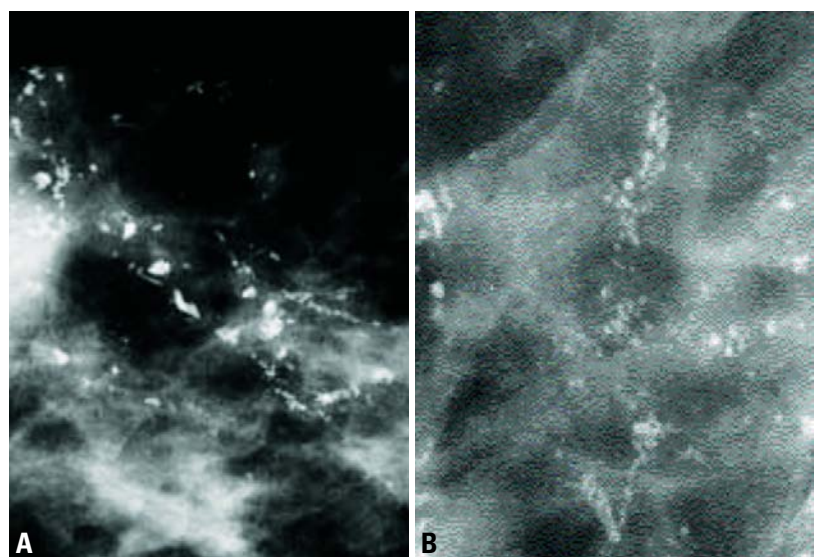


Fig. 1.87 **A** High grade DCIS with solid growth pattern is usually associated with fragmented, branching, casting type calcifications. Microfocus magnification, detail image. The rod-like, "casting-type" calcifications are characteristic for Grade 3 DCIS. **B** High grade DCIS with micropapillary growth pattern is usually associated with dotted casting type calcifications.

About 17% of the lesions lack histologic evidence of microcalcifications; they are either mammographically occult or manifest as an architectural distortion, a nodular mass or nonspecific density [1206].

Size, extent and distribution

Size/extent is an important factor in the management of DCIS. The assessment of extent of DCIS is complex and needs in optimal conditions the correlation of the

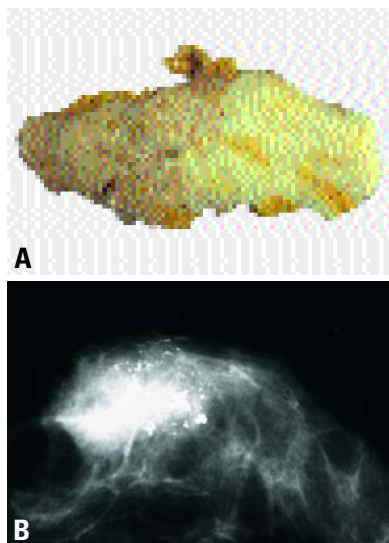


Fig. 1.88 Large excision biopsy of a high grade ductal carcinoma in situ. **A** Note the sharp demarcation between DCIS, comedo type (left), and adjacent fibrous stroma. **B** Mammography showing a large area with highly polymorphic microcalcifications.

mammogram, the specimen X-ray and the histologic slides. Since the majority of DCIS is non palpable, the mammographic estimate is the sole guide for resection. Therefore, data on the mammographic pathological correlation of the tumour size are essential for guiding the extent of surgery. The mammographic extent of a DCIS is defined as the greatest distance between the most peripherally located clusters of suspicious microcalcifications, and the histologic extent as the greatest distance between the most peripherally located, histologically verified, DCIS foci. Histologic evaluation supported by correlation with the X-ray of the sliced specimen allows a precise and reproducible assessment of the extent of any DCIS present. Whole organ studies have shown that mammography, on the basis of significant microcalcifications, generally underestimates the histologic or "real" size of DCIS by an average of 1-2 cm. In a series of DCIS cases with mammographic sizes up to 3 cm, the size difference was less than 2 cm in more than 80% of the cases {1231}. DCIS may appear as a multifocal process due to the presence of multiple tumour foci on two-dimensional plane sections. However, these tumour spots may not necessarily represent separate foci. Intraductal tumour growth on three-

dimensional studies appears to be continuous rather than discontinuous {831}. More specifically, whereas poorly differentiated DCIS shows a predominantly continuous growth, the well differentiated DCIS, in contrast, may present a more discontinuous (multifocal) distribution. These results have a direct implication on the reliability of the margin assessment of surgical specimens. In cases of poorly differentiated DCIS, margin assessment should, theoretically, be more reliable than well differentiated DCIS. In a multifocal process with discontinuous growth, the surgical margin may lie between the tumour foci, giving the false impression of a free margin.

The distribution of DCIS in the breast is typically not multicentric, defined as tumour involvement in two or more remote areas separated by uninvolved glandular tissue of 5 cm. On the contrary, DCIS is typically 'segmental' in distribution {1230}. In practical terms, this implies that two apparently separate areas of "malignant" mammographic microcalcifications usually do not represent separate fields of DCIS but rather a larger tumour in which the two mammographically identified fields are connected by DCIS, which is mammographically invisible due to the lack of detectable size of microcalcifications. One should be aware that single microscopic calcium particles smaller than about 80 μ cannot be seen on conventional mammograms.

Grading

Although there is currently no universal agreement on classification of DCIS, there has been a move away from traditional architectural classification. Most modern systems use cytonuclear grade alone or in combination with necrosis and or cell polarization. Recent international consensus conferences held on this subject endorsed this change and recommended that, until more data emerges on clinical outcome related to pathology variables, grading of DCIS should form the basis of classification and that grading should be based primarily on cytonuclear features {6,7,1565,2346}.

Pathologists are encouraged to include additional information on necrosis, architecture, polarization, margin status, size and calcification in their reports.

Depending primarily on the degree of nuclear atypia, intraluminal necrosis and, to a lesser extent, on mitotic activity and

Table 1.13

Features of DCIS to be documented for the surgical pathology report.

Major lesion characteristics

1. Nuclear grade
2. Necrosis
3. Architectural patterns

Associated features

1. Margins
If positive, note focal or diffuse involvement. Distance from any margin to the nearest focus of DCIS.
2. Size (either extent or distribution)
3. Microcalcifications (specify within DCIS or elsewhere)
4. Correlate morphological findings with specimen imaging and mammographic findings

calcification, DCIS is generally divided into three grades; the first two features constitute the major criteria in the majority of grading systems. It is not uncommon to find admixture of various grades of DCIS as well as various cytological variants of DCIS within the same biopsy or even within the same ductal space. When more than one grade of DCIS is present, the proportion (percentage) of various grades should be noted in the diagnosis {2876}. It is important to note that a three tiered grading system does not necessarily imply progression from grade 1 or well differentiated to grade 3 or poorly differentiated DCIS.

Histopathology

Low grade DCIS

Low grade DCIS is composed of small, monomorphic cells, growing in arcades, micropapillae, cribriform or solid patterns. The nuclei are of uniform size and have a regular chromatin pattern with inconspicuous nucleoli; mitotic figures

Table 1.14

Minimal criteria for low grade DCIS.

Cytological features

1. Monotonous, uniform rounded cell population
2. Subtle increase in nuclear-cytoplasmic ratio
3. Equidistant or highly organized nuclear distribution
4. Round nuclei
5. Hyperchromasia may or may not be present

Architectural features

Arcades, cribriform, solid and/or micropapillary pattern

are rare. Some require complete involvement of a single duct cross section by characteristic cells and architecture, while others require either involvement of two spaces or one or more duct cross sections exceeding 2 mm in diameter. Microcalcifications are generally of the psammomatous type. There may be occasional desquamated cells within the ductal lumen but the presence of necrosis and comedo histology are unacceptable within low grade DCIS.

DCIS with micropapillary pattern may be associated with a more extensive distribution in multiple quadrants of the breast compared to other variants [2584]. The working group's minimal criteria for diagnosis of low grade DCIS are shown in Table 1.14.

Intermediate grade DCIS

Intermediate grade DCIS lesions are often composed of cells cytologically

similar to those of low grade DCIS, forming solid, cribriform or micropapillary patterns, but with some ducts containing intraluminal necrosis. Others display nuclei of intermediate grade with occasional nucleoli and coarse chromatin; necrosis may or may not be present. The distribution of amorphous or laminated microcalcifications is generally similar to that of low grade DCIS or it may display characteristics of both low grade and high grade patterns of microcalcification.

High grade DCIS

High grade DCIS is usually larger than 5 mm but even a single <1 mm ductule with the typical morphological features is sufficient for diagnosis. It is composed of highly atypical cells proliferating as one layer, forming micropapillae, cribriform or solid patterns. Nuclei are high grade, markedly pleomorphic, poorly polarized,

with irregular contour and distribution, coarse, clumped chromatin and prominent nucleoli. Mitotic figures are usually common but their presence is not required. Characteristic is the comedo necrosis with abundant necrotic debris in duct lumens surrounded by a generally solid proliferation of large pleomorphic tumour cells. However, intraluminal necrosis is not obligatory. Even a single layer of highly anaplastic cells lining the duct in a flat fashion is sufficient. Amorphous microcalcifications are common.

Unusual variants

A minority of the DCIS lesions is composed of spindled [827], apocrine [2887], signet ring, neuroendocrine, squamous or clear cells. There is no consensus or uniform approach to grading of these unusual variants. Some believe assessment of nuclear features and necrosis can be applied to grading of the

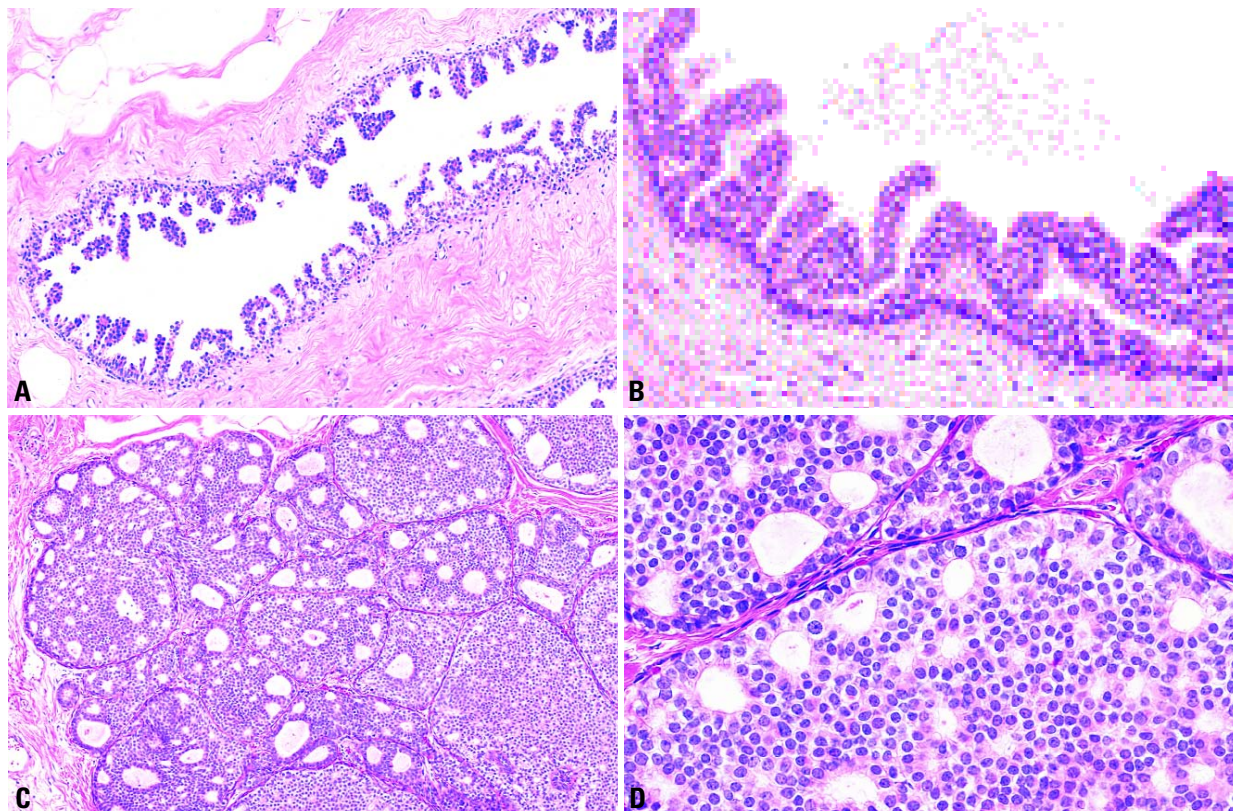


Fig. 1.89 Low grade ductal carcinoma in situ. **A** Micropapillary type showing the longitudinal segment of a duct with numerous micropapillae characteristic of this variant. **B** Micropapillary type. The micropapillae lack a fibrovascular core and are composed of a piling of uniform cells with rounded nuclei. **C** Cribriform type. Multiple adjacent ducts are distended by a sieve-like proliferation of monotonous uniform cells. The multiple spaces are rounded and distributed in an organized fashion. **D** Cribriform type. A highly uniform population of cells with round nuclei distributed equidistant from one another grow in a cribriform pattern.

unusual variants as well. Using this approach many apocrine DCIS lesions qualify as high grade, while a minority would qualify as intermediate or, rarely, high grade DCIS. The clear and spindle cell DCIS are sometimes found coexistent and continuous with typical low grade DCIS, but often the nuclei are moderately atypical qualifying the lesions as intermediate grade DCIS. High nuclear grade spindle or clear cell DCIS is extremely rare. A vast majority of apocrine carcinomas are ER, PR and BCL2 negative, but androgen receptor positive [2888].

Proliferation

In vivo labelling with bromodeoxyuridine (BrdU) has found no significant differences between proliferating cell fraction among UDH and ADH, but the proliferating cell fraction is significantly increased

in DCIS [412]. With the Ki67 antibody, the highest proliferating index (PI) of 13% has been noted among the comedo DCIS, while the PI for low grade DCIS, cribriform type is 4.5% and for micropapillary type, it is 0% [61].
DNA Ploidy: Aneuploidy has been found in 7% of UDH, 13-36% of ADH, and 30-72% of low to high grade DCIS respectively [408,579,792].

Hormone receptor expression

Estrogen plays a central role in regulating the growth and differentiation of breast epithelium as well as in the expression of other genes including the progesterone receptor (PR) [72]. The presence and concentration of the two receptors are used, not only as a clinical index of potential therapeutic response, but also as markers of prognosis for invasive breast carcinomas [196]. Only a few

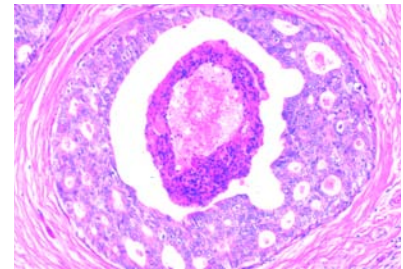


Fig. 1.91 DCIS, intermediate grade (DCIS grade 2). This typical and most common intermediate grade DCIS is characterized by a cribriform growth pattern and intraluminal necrosis.

studies have evaluated estrogen receptor (ER) in intraductal proliferative breast lesions. Among DCIS, about 75% of the cases show ER expression [72,1399], and an association between ER positivity and the degree of differentiation has been described [1399]. There is agreement that nearly all examples of ADH express high levels of ER in nearly all the cells [72,1301,2667]. The relationship between ER positive cell numbers and patient age, as found in normal breast epithelium, is lost in these ADH lesions, indicating autonomy of ER expression or of the cells expressing the receptor [2667].

Differential diagnosis

The solid variant of low grade DCIS may be misinterpreted as lobular neoplasia (LN). Immunohistochemistry for E-cadherin and CK1/5/10/14 (clone CK34BetaE12) are helpful in separating the two. Low grade DCIS is E-cadherin positive in 100% of cases [337,1090,3034] and CK34BetaE12 negative in 92% of cases [337,1890], whereas lobular neoplasia (LN) is E-cadherin negative [337,1033] and CK34BetaE12 positive in nearly all cases [337]. The presence of individual or clusters of cells invading the stroma (microinvasion) around a duct with DCIS is a frequent source of diagnostic problems. The difficulty is compounded by the frequent presence of dense lymphoplasmacytic infiltrate around the involved ducts. Immunostains for an epithelial and myoepithelial marker are helpful optimally in the form of double immunostaining; the epithelial cell marker can unmask the haphazard distribution of the cells, while the absence of a myoepithelial cell layer would generally ascertain the invasive nature of the cells in question. Despite all

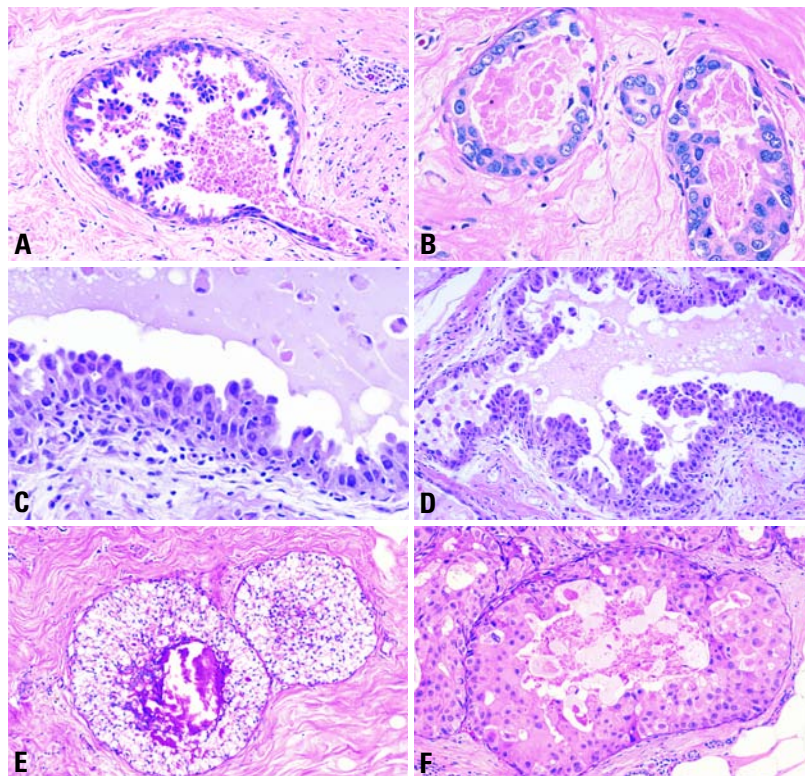


Fig. 1.90 Intermediate grade ductal carcinoma in situ. **A** Micropapillary type. The micropapillae are varied in shape and composed of cells with moderately atypical, pleomorphic nuclei. A few apoptotic cells are present in the lumen. **B** Flat type, approaching high grade DCIS. Two adjacent ductal spaces are lined by atypical cells, rare mitotic figures and a few apoptotic nuclei. **C, D** Duct/part of a duct with micropapillary atypical epithelial proliferation. Note secretory material in the lumen that should not be mixed up with comedo-type necrosis. **E** Clear cell type. The neoplastic cells have clear cytoplasm with moderate nuclear pleomorphism. **F** Apocrine type with moderate nuclear size variation. The abundant pink, granular cytoplasm suggests an apocrine cell type.

these added studies, the distinction can remain impossible in some cases.

An unknown, but relatively small, proportion of intraepithelial neoplasias cannot be easily separated into ductal or lobular subtypes on the basis of pure H&E morphology. Using immunostains for E-cadherin and CK34 E12, some of these will qualify as ductal (E-cadherin+, CK34BetaE12-), some as lobular (E-cadherin-, CK34 E12+), while others are either negative for both markers (negative hybrid) or positive for both (positive hybrid) [337]. This important group requires further evaluation as it may reflect a neoplasm of mammary stem cells or the immediate post-stem cells with plasticity and potential to evolve into either ductal or lobular lesions [338].

Expression profiling

Gene expression profiling has become a powerful tool in the molecular classification of cancer. Recently, the feasibility and reproducibility of array technology in DCIS was demonstrated [1721]. More than 100 changes in gene expression in DCIS were identified in comparison with control transcripts. Several genes, previously implicated in human breast cancer progression, demonstrated differential expression in DCIS versus non-malignant breast epithelium, e.g. up-regulation of lactoferrin (a marker of estrogen stimulation), PS2 (an estrogen-responsive marker), and SIX1 (a homeobox protein frequently up-regulated in metastatic breast cancer), and down-regulation of oxytocin receptor [3148].

Genetic alterations

Most studies on somatic gene alterations in premalignant breast lesions are based on small sample numbers and have not been validated by larger series [72], with the exceptions of the *TP53* tumour suppressor gene and the oncogenes *ERBB2* and *CCND1* [72,196]. Other genes, not discussed here (e.g. oncogenes *c-myc*, *fos*, *c-met*, and tumour suppressor gene *RB1*) may also play an important role in breast carcinogenesis (for review see [3048]).

Cytogenetics

Conventional cytogenetic analysis of premalignant lesions of the breast has been carried out in only a small number of cases, and, as with invasive ductal

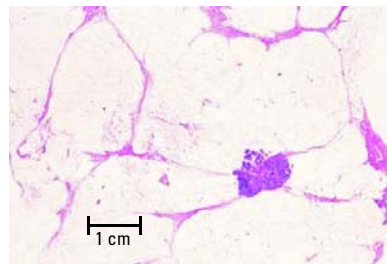


Fig. 1.92 High grade ductal carcinoma in situ forming a tumour mass. Large section, H&E.

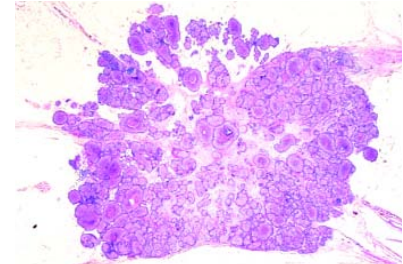


Fig. 1.93 High grade ductal carcinoma in situ. Low power view shows extensive DCIS with calcification.

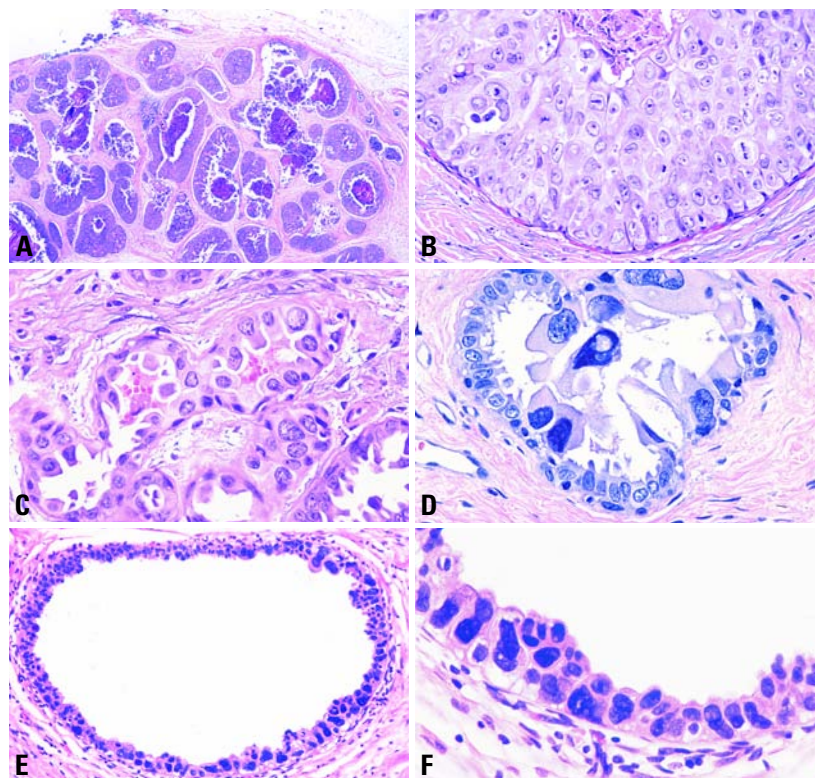


Fig. 1.94 High grade ductal carcinoma in situ. **A** Multiple duct spaces with amorphous microcalcifications and peripheral epithelial proliferations. **B** Comedo type. The proliferating cells show significant nuclear atypia, mitotic figures and there is intraluminal necrosis. **C** Flat type. Significantly atypical cells have replaced the native, normal mammary epithelium. **D** Flat type. A highly anaplastic cell population has replaced the native epithelial cell layer. **E** Flat type with significant nuclear pleomorphism. **F** Flat type. A highly anaplastic cell population has replaced the native epithelial layer, but there is no significant intraluminal proliferation.

carcinoma, abnormalities of chromosomes 1 and 16 have been identified in DCIS [1146,1567]. FISH-analyses using DNA probes to centromeric sequences of almost all chromosomes frequently identified polysomy of chromosome 3, 10, and 17 and loss of chromosome 1, 16, and 18 in DCIS [1949].

Chromosomal imbalance

CGH studies of DCIS have demonstrated a large number of chromosomal alterations including frequent gains on 1q, 6q, 8q, 17q, 19q, 20q, and Xq, and losses on 8p, 13q, 16q, 17p, and 22q [134,301,365,366,1333,1548,3045]. Most of these chromosomal imbalances

resemble those identified in invasive ductal carcinoma, adding weight to the theory that DCIS is a direct precursor.

LOH

In DCIS, loss of heterozygosity (LOH) was frequently identified at several loci on chromosomes 1 {1942}, 3p21 {1743}, and chromosomes 8p, 13q, 16q, 17p, 17q, and 18q {924,2317,3036}. The highest reported rates of LOH in DCIS are between 50% and 80% and involve loci on chromosomes 16q, 17p, and 17q, suggesting that altered genes in these regions may be important in the development of DCIS {72,924,3036}. Among more than 100 genetic loci studied so far on chromosome 17, nearly all DCIS lesions showed at least one LOH {72,301,924,1942,2071,2317,2475}. By CGH and FISH, low and some intermediate grade DCIS and invasive tubular carcinoma (G1) show loss of 16q, harbouring one of the cadherin gene clusters, whereas some intermediate grade and high grade DCIS and nearly all G2 and G3 invasive ductal carcinomas show no loss of genetic material on this locus but have alterations of other chromosomes (-13q, +17p, +20q). Based upon this data, a genetic progression model was proposed {301}.

ERBB2

The *ERBB2* (Her2/neu) oncogene has received attention because of its association with lymph node metastases, short relapse free time, poor survival, and decreased response to endocrine and chemotherapy in breast cancer patients {72,1567}. Studies of ERB B2 have used mainly FISH technique to identify amplification and immunohistochemistry (IHC) to detect over expression of the oncogene, which are highly correlated {72}. Amplification and/or over expression was observed on average in 30% of DCIS, correlating directly with differentiation {72}; it was detected in a high proportion of DCIS of high nuclear grade (60-80%) but was not common in low nuclear grade DCIS {196}. Patients with *ERBB2* positive tumours may benefit from adjuvant treatment with monoclonal antibody (Herceptin).

Cyclin D1

This protein plays an important part in regulating the progress of the cell during the G1 phase of the cell cycle. The gene

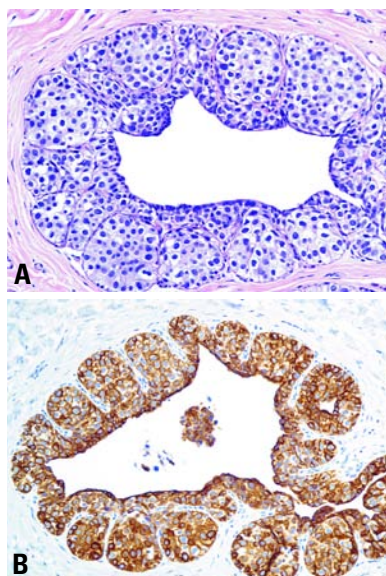


Fig. 1.95 Unusual intraductal proliferation. **A** The lesion shows a uniform cell population proliferating in a solid pagetoid pattern similar to lobular neoplasia, but the cells appear more adherent than in typical lobular neoplasia (LN). **B** Double immunostain is positive for both CK34 E12 (purple) and E-cadherin (brown), qualifying the lesion as a hybrid positive type that may suggest the diagnosis of DCIS.

(*CCND1*) is considered a potential oncogene, but in clinical studies of invasive breast cancer, overexpression of cyclin D1 was found to be associated with estrogen receptor expression and low histological grade, both markers of good prognosis {1007}. Amplification of *CCND1* occurs in about 20% of DCIS and is more commonly found in high grade than in low grade DCIS (32% versus 8%) {2700}. The cyclin D1 protein was detected in 50% of cases, and high levels were more likely in low grade than in the intermediate and high grade DCIS {2700}. Although so far no oncogene has been identified on chromosome 20q13, amplification of this region was frequently found in DCIS {134,856}.

TP53 mutations

The TP53 protein is a transcription factor involved in the control of cell proliferation, response to DNA damage, apoptosis and several other signaling pathways. It is the most commonly mutated tumour suppressor gene in sporadic breast cancer {196} and this is

generally associated with aggressive biological features and poor clinical outcome. Most *TP53* mutations are missense point mutations resulting in an inactivated protein that accumulates in the cell nucleus {72,712}. In DCIS, *TP53* mutations were found with different frequency among the three histological grades, ranging from rare in low grade DCIS, 5% in intermediate-grade, and common (40%) in high grade DCIS {712,3048}.

Prognosis and predictive factors

The most important factor influencing the possibility of recurrence is persistence of neoplastic cells post-excision; primary and recurrent DCIS generally have the same LOH pattern, with acquisition of additional alterations in the latter {1670}. The significance of margins is mainly to ascertain complete excision. In randomized clinical trials, comedo necrosis was found to be an important predictor of local recurrence in the NSABP-B17 trial {2843}, while solid and cribriform growth patterns along with involved margin of excision were found to be predictive of local recurrence in EORTC-10853 trial {270,271}. In retrospective trials, on the other hand, high nuclear grade, larger lesion size, comedo necrosis and involved margins of excision were all found to be predictive of local recurrence following breast conservative treatment for DCIS.

Although mastectomy has long been the traditional treatment for this disease, it likely represents over-treatment for many patients, particularly those with small, mammographically detected lesions. Careful mammographic and pathologic evaluation are essential to help assess patient suitability for breast conserving treatment.

While excision and radiation therapy of DCIS (with or without Tamoxifen) have significantly reduced the chances of recurrence {866,870}, some patients with small, low grade lesions appear to be adequately treated with excision alone, whereas those with extensive lesions may be better served by mastectomy. Better prognostic markers are needed to help determine which DCIS lesions are likely to recur or to progress to invasive cancer following breast conserving treatment. The optimal management is evolving as data accumulates from a variety of prospective studies.

Microinvasive carcinoma

I.O. Ellis
F.A. Tavassoli

Definition

A tumour in which the dominant lesion is non-invasive, but in which there are one or more clearly separate small, microscopic foci of infiltration into non-specialized interlobular stroma. If there is doubt about the presence of invasion, the case should be classified as an in situ carcinoma.

ICD-O code

Microinvasive carcinoma is not generally accepted as a tumour entity and does not have an ICD-O code.

Epidemiology

Microinvasive carcinomas are rare and occur mostly in association with an in situ carcinoma. They account for far less than 1% of breast carcinomas even in pure consultation practices where the largest number of microinvasive carcinoma is reviewed [2680].

Clinical features

There are no specific clinical features associated with microinvasive carcinoma. These lesions are typically associated with ductal carcinoma in situ which is often extensive. The features associated with the associated in situ component are responsible for detection as a mass lesion, mammographic calcification or a nipple discharge. (See clinical features of ductal and lobular carcinoma in situ).

Histopathology

There is no generally accepted agreement on the definition of microinvasive carcinoma. This is particularly true for the maximum diameter compatible with the diagnosis of microinvasive carcinoma.

Size limits

Microinvasive carcinoma has been defined as having a size limit of 1 mm [1984,2425,2739,2905]. Consequently, diagnosis of microinvasive carcinoma is rare in routine practice, in contrast to larger (>1 mm) foci of invasion.

Alternatively, it has also been defined as a single focus no larger than 2 mm in maximum dimension or 2-3 foci, none

exceeding 1 mm in maximum dimension. Some studies have provided no maximum size [2579,3140] or criteria [1467,2703]. Others have defined the microinvasive component as a percentage of the surface of the histologic sections [2583]. Some have described subtypes separating those purely composed of single cells and those also containing cell clusters and/or tubules of non-gradable tumour without providing information about maximum size, extent, or number of microinvasive foci [656]. More precise definitions accept an

unlimited number of clearly separate foci of infiltration into the stroma with none exceeding 1 mm in diameter [80], 1 or 2 foci of microinvasion with none exceeding 1 mm [2695], a single focus not exceeding 2 mm or three foci, none exceeding 2 mm in maximum diameter [2680].

Some authors propose that the definition of microinvasive carcinoma requires extension of the invasive tumour cells beyond the specialized lobular stroma [774,2905] despite the definitive presence of vascular channels both within

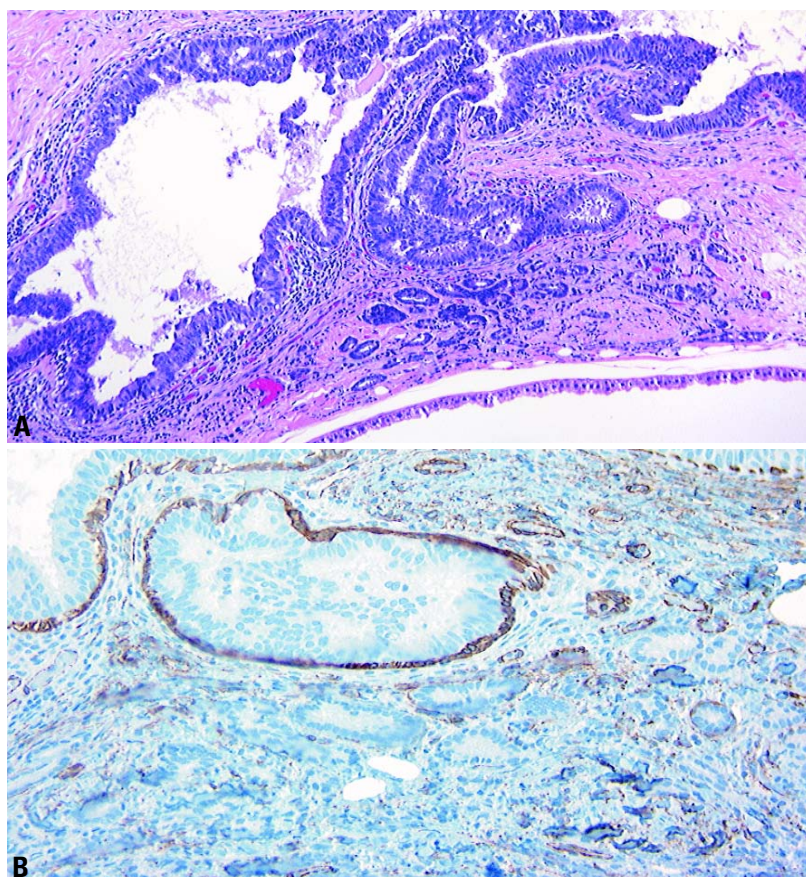


Fig. 1.96 Microinvasive carcinoma. **A** A small focus of invasive carcinoma barely 0.8 mm in maximum extent is present adjacent to an aggregate of ducts displaying mainly flat epithelial atypia. **B** Immunostain for actin shows no evidence of a myoepithelial (ME) cell layer around the invasive tubules, in contrast to persistence of a distinct ME cell layer around the adjacent tubules with flat epithelial atypia.

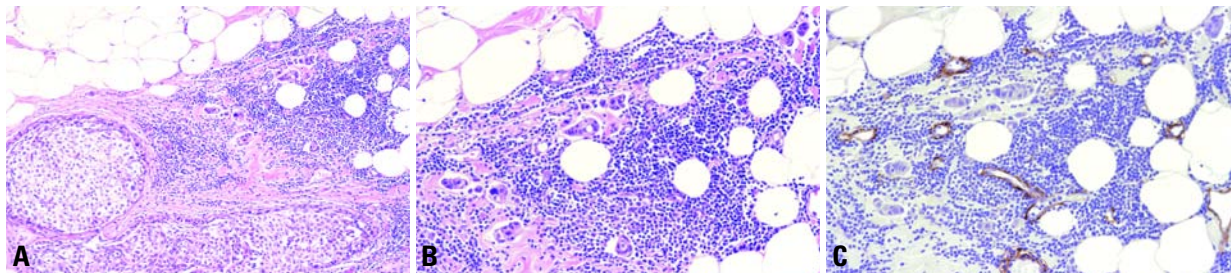


Fig. 1.97 Microinvasive carcinoma. **A** Two ducts are filled by DCIS, while small clusters of carcinoma cells invade the stroma (upper right quadrant of the field) admixed with a dense lymphocytic infiltrate. **B** Higher magnification shows small invasive cell clusters within stromal spaces distributed over a 0.7 mm area and surrounded by a dense lymphocytic infiltrate. **C** Immunostain for actin decorates the vessel walls, while absence of myoepithelial cells around the tumour cell clusters confirms their invasive nature.

the specialized lobular stroma and immediately surrounding the basement membrane that invests the ducts.

Associated lesions

Typically, microinvasive carcinoma occur in larger areas of high grade DCIS in which the tumour cell population extends to involve lobular units or areas of benign disease.

Microinvasion occurs in association not only with all grades of DCIS, including papillary DCIS, but also with other precursor lesions of invasive breast cancer, e.g. lobular neoplasia (LN) [1226,1249,1993], indicating that at least some forms of lobular neoplasia behave as true precursors of invasive lesions.

Stromal reaction

Microinvasion is most often present in a background of significant periductal / perilobular lymphocytic infiltrate or an altered desmoplastic stroma, features often present in cases of comedo DCIS. Angulation of mesenchymal structures may be emphasized by the plane of sectioning and can produce features reminiscent of invasive carcinoma. Basement membrane structures in such foci may be discontinuous but it is unusual to lose the entire basement membrane around such a lesion. Similarly myoepithelial cells may be scarce but are rarely totally absent in such areas.

Change in morphology

When true invasion extends into non-specialized stroma, the islands of tumour cells frequently adopt a different morphological character which is more typical of well established invasive mammary carcinoma of ductal NOS

type and is distinct from the patterns seen with cancerization of lobules.

Differential diagnosis

When there is doubt about the presence of invasion and particularly, if uncertainty persists even after recuts and immunostains for detection of myoepithelial cells, the case should be diagnosed as an in situ carcinoma. Similarly, suspicious lesions which disappear on deeper levels should be regarded as unproven, with no definite evidence of established invasion.

Invasion is associated with a loss of immunoreactivity to myoepithelial cells. A variety of markers is available for the identification of myoepithelial cells [3181]. The most helpful include smooth muscle actin, calponin, and smooth muscle myosin (heavy chain); the latter in particular shows the least cross-reactivity with myofibroblasts that may mimic a myoepithelial cell layer when apposed to the invasive cells.

Prognosis and predictive factors

In true microinvasive carcinomas of the breast, the incidence of metastatic disease in axillary lymph nodes is very low and the condition is generally managed clinically as a form of DCIS.

However, given the lack of a generally accepted standardized definition of microinvasive carcinoma, there is little evidence on the behaviour of microinvasive carcinoma. A recent detailed review of the literature [2425] concluded that a variety of different diagnostic criteria and definitions have been used and as a consequence it is difficult to draw any definitive conclusions.

There are studies that have found no evidence of axillary node metastases asso-

ciated with a finite number of invasive foci <1 mm in maximum dimension or a single invasive focus <2 mm [2680,2695]. Others have shown a small percentage (up to 5%) with axillary node metastases [2453,2744] or have described up to 20% axillary node metastases [656,1472,2282,2579,2583]. Of 38 women who had undergone mastectomy for their minimally invasive carcinomas (a single focus <2 mm or up to 3 invasive foci, none exceeding 1 mm, with no axillary node metastases), developed recurrences or metastases [2680]. The few other studies with comparable, but not exactly the same definition, and follow-up data support the excellent prognosis for these tumours within the short periods of available follow-up [2453,2695,3140].

In practice, it may be impossible for pathologists to routinely examine an entire sample exhaustively. Therefore, it is quite possible that small foci of invasive carcinoma may be missed, particularly in the setting of extensive in situ carcinoma. For this reason, it may be appropriate to sample the lowest axillary lymph nodes, or sentinel node as a matter of routine, when treating patients by mastectomy for extensive DCIS with or without accompanying microinvasive carcinoma [1472]. The pathology report should provide the size of the largest focus along with the number of foci of invasion, noting any special studies utilized to arrive at the diagnosis, ie. 1.3 mm, 2 foci, immunocytochemistry.

Until there is a generally accepted definition with reliable follow-up data, microinvasive carcinoma of the breast remains an evolving concept that has not reached the status of a WHO-endorsed disease entity.

Intraductal papillary neoplasms

G. MacGrogan
F. Moinfar
U. Raju

Definition

Papillary neoplasms are characterized by epithelial proliferations supported by fibrovascular stalks with or without an intervening myoepithelial cell layer. They may occur anywhere within the ductal system from the nipple to the terminal ductal lobular unit (TDLU) and may be benign (intraductal papilloma), atypical, or malignant (intraductal papillary carcinoma).

Intraductal papilloma

A proliferation of epithelial and myoepithelial cells overlying fibrovascular stalks creating an arborescent structure within the lumen of a duct.

Intraductal papilloma of the breast is broadly divided into central (large duct) papilloma, usually located in the subareolar region, and peripheral papilloma arising in the TDLU [2092]. The confusing term "papillomatosis" should be avoided as it has been used for usual ductal hyperplasia as well as for multiple papillomas.

ICD-O code 8503/0

Central papilloma

Synonyms

Large duct papilloma, major duct papilloma.

Epidemiology

The incidence of the various forms of intraductal papillary lesions is uncertain due to the lack of consistent terminology. Overall, less than 10% of benign breast neoplasms correspond to papillomas [413,1098]. Central papillomas can occur at any age, but the majority present during the fourth and fifth decades [1098,1945].

Clinical features

Unilateral sanguineous, or sero-sanguineous, nipple discharge is the most frequent clinical sign, and is observed in 64-88% of patients [3148]. A palpable mass is less frequent. Mammographic abnormalities include a circumscribed retro-areolar mass of benign appearance, a solitary retro-areolar dilated duct and, rarely, microcalcifications [401,3148]. Small papillomas may be mammographically occult because of their location in the central dense breast and usually lack of calcification. Typical sonographic features include a well defined smooth-walled, solid, hypoechoic nodule or a lobulated, smooth-walled, cystic lesion with solid components. Duct dilatation with visible solid intraluminal echoes is common [3176].

Galactography shows an intraluminal smooth or irregular filling defect associated with obstructed or dilated ducts, or a complete duct obstruction with ret-

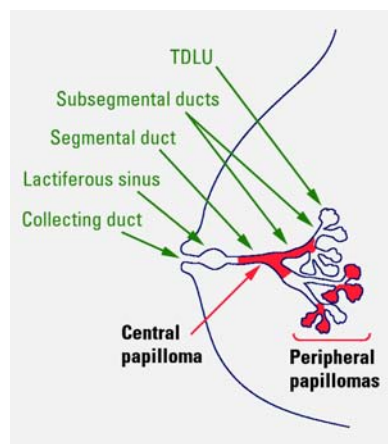


Fig. 1.98 Distribution of papillomas in breast.

rograde flow of contrast material. Galactography may be useful to the breast surgeon in identifying and localizing the discharging duct, prior to duct excision [3148].

Macroscopy

Palpable lesions may form well circumscribed round tumours with a cauliflower-like mass attached by one or more pedicles to the wall of a dilated duct containing serous and/or sanguineous fluid. The size of central papillomas varies considerably from a few millimetres to 3-4 cm or larger and they can extend along the duct for several centimetres.

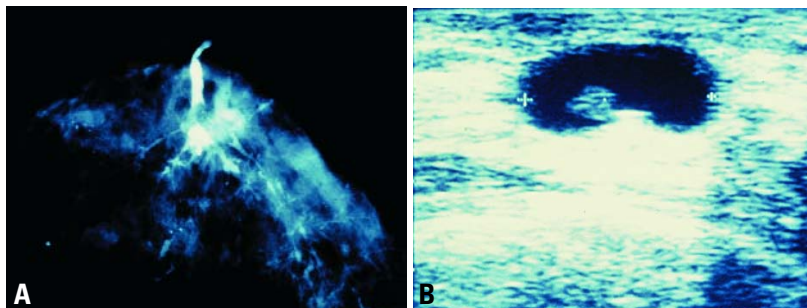


Fig. 1.99 Central papilloma. A Smooth intraluminal filling defect associated with duct dilatation. B Well defined smooth wall cystic lesion with a solid component.

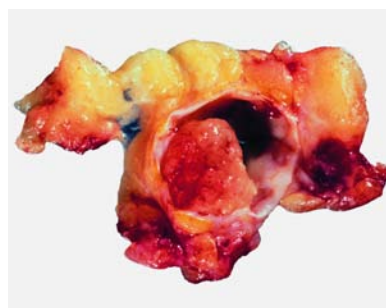

Fig. 1.100 Papilloma, gross. Nodular mass in a cystic duct.

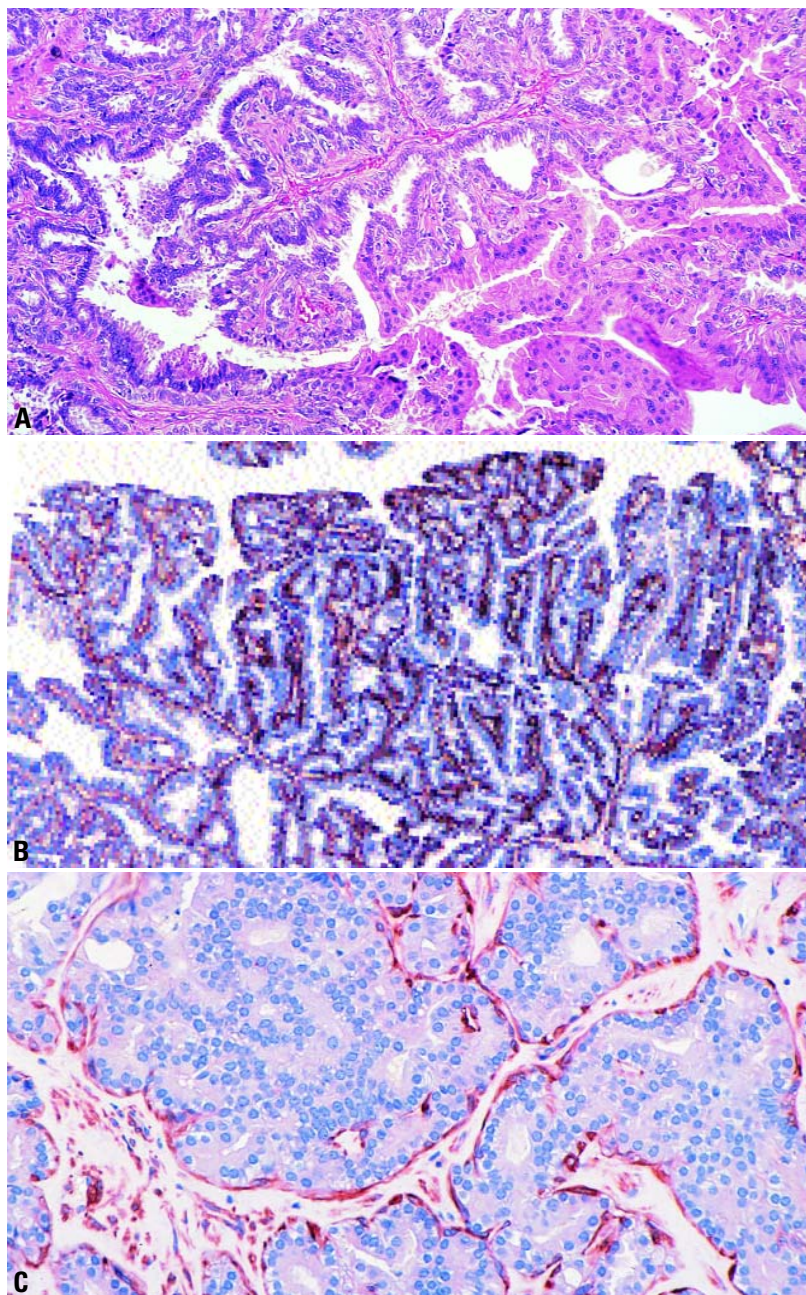


Fig. 1.101 **A** Typical morphology of a papilloma of the breast. **B** Cytokeratin (34 E12) staining decorates myoepithelial and some epithelial cells. **C** Papilloma with atypical ductal hyperplasia (ADH). Note HHF-35 immunoreactive myoepithelial cells at the periphery of ADH.

Histopathology

Papillomas are characterized by an arborescent structure composed of fibrovascular stalks covered by a layer of myoepithelial cells with overlying epithelial cells. In some lesions papillary and

ductal patterns coexist. When the ductal pattern predominates and is associated with marked sclerosis, the term sclerosing papilloma may be used. Ductal adenoma is considered by some as a variant of generally sclerosing papilloma.

Papilloma may be subject to morphological changes such as inflammation, necrosis, myoepithelial hyperplasia, apocrine, squamous, sebaceous, mucinous, osseous and chondroid metaplasia as well as usual intraductal hyperplasia [148,893,1350,1945,2327,2420,2873]. A pseudo-infiltrative pattern may be observed at the periphery of these lesions particularly in the sclerosing variant. The myoepithelial cell layer may have an uneven distribution both in areas of UDH, ADH, and DCIS [2325]. The entire range of ductal intraepithelial proliferations may arise within, or secondarily involve, a central papilloma. The clinical implications of such lesions have not at this time been fully established and should be considered in the context of the surrounding breast tissue.

Peripheral papilloma

Synonym

Microscopic papilloma.

Epidemiology

The average age at presentation of peripheral papillomas is similar to that of central papillomas or slightly younger [401,1097,1945].

Clinical features

Peripheral papillomas are often clinically occult. They rarely present as a mass and nipple discharge is far less frequent in this group [401]. They are also usually mammographically occult, but they may manifest as peripherally situated microcalcifications, nodular prominent ducts or multiple small peripheral well circumscribed masses [401]. Microcalcifications may be located in the peripheral papillomas or in adjacent non-papillary intraductal proliferative lesions, e.g. ADH.

Macroscopy

Unless they are associated with other changes, peripheral papillomas are usually a microscopic finding.

Histopathology

Peripheral papillomas are usually multiple. They originate within the TDLUs from where they may extend into the larger ducts [2092]. The histological features are basically the same as for central papillomas. Compared to central papillomas, however, peripheral papillomas are more frequently observed in association

Table 1.15

Differential diagnosis of benign papilloma and intraductal papillary carcinoma.

Feature	Papilloma	Papillary intraductal carcinoma
Cell types covering fibrovascular stalks	Epithelial and myoepithelial	Epithelial (myoepithelial cells may be seen at periphery of duct wall)*
Nuclei	Normochromatic vesicular chromatin; variable in size and shape	May be hyperchromatic, with diffuse chromatin: relatively uniform in size and shape
Apocrine metaplasia	Frequent	Absent
Fibrovascular stalks	Usually broad and present throughout lesion; may show sclerosis	Often fine and may be absent in some areas; sclerosis uncommon
Immunohistochemical markers for myoepithelial cells (e.g. smooth muscle actin, HMW-CK [such as CK 5/6])	Positive	Negative*
* Myoepithelial cells may be present in some papillary carcinomas—see text for explanation.		

with concomitant usual ductal hyperplasia, atypical intraductal hyperplasia, ductal carcinoma in situ or invasive carcinoma as well as with sclerosing adenosis or radial scar [1097,1945,2091,2092]. The term micropapilloma has been applied to the smallest type of peripheral papillomas corresponding to multiple microscopic papillomas that grow in foci of adenosis. Collagenous spherulosis, consisting of round eosinophilic spherules of basement membrane (type IV collagen), edged by myoepithelial cells may be seen in some peripheral papillomas.

Atypical papilloma

Atypical intraductal papillomas are characterized by the presence of a focal atypical epithelial proliferation with low grade nuclei. Such intraepithelial proliferations may occasionally resemble atypical ductal hyperplasia (ADH) or small foci of low grade DCIS.

Prognosis and predictive features of benign and atypical papillomas

The risk of subsequent invasive carcinoma associated with papillomas or atypical papillomas should be appreciated in the context of the surrounding breast tissue. A benign papilloma without surrounding changes is associated with a slightly increased relative risk of subsequent invasive breast carcinoma, similar to that of moderate or florid usual ductal hyperplasia in the breast proper [885,2151]. The relative risk associated

with peripheral papilloma may be higher compared to central papilloma. However, this risk also depends on the concurrent presence of other forms of proliferative disease and as yet no study has been designed to specifically answer this question [2151]. There is disagreement as to whether the risk of subsequent invasive breast carcinoma applies only to the same site in the ipsilateral breast or applies to both breasts [2151,2326]. The significance of atypia within a papilloma is still not clear and is obscured by the frequent concurrent presence of atypia within the surrounding breast parenchyma. It appears that if epithelial atypia is confined to the papilloma without surrounding proliferation or atypia the risk of subsequent invasive breast carcinoma is similar to that of non-atypical papilloma. As expected, epithelial atypia when present simultaneously both within and outside a papilloma is associated with a moderate to highly increased relative risk [2151]; this is not a reflection of the risk associated with pure atypical papilloma, however.

The standard treatment for papillomas has been complete excision with microscopic assessment of surrounding breast tissue. Because of potential variability within a papillary lesion, complete excision is prudent, regardless of the findings in a previous core biopsy. The differential diagnosis of benign and malignant papillary lesions on frozen section can be extremely difficult and a definitive diagnosis should always be made only after examination of paraffin embedded material.

Intraductal papillary carcinoma

ICD-O code 8503/2

Synonym

Papillary carcinoma, non-invasive.

Definition

This lesion is located within a variably distended duct and may extend into its branches. It is characterized by proliferation of fibrovascular stalks and its diagnosis requires that 90% or more of

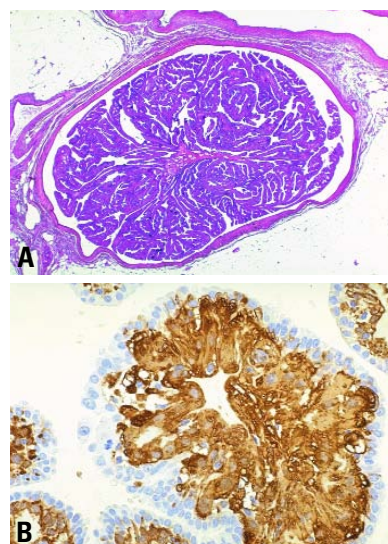


Fig. 1.102 Central papilloma. **A** An arborescent structure composed of papillary fronds within a dilated duct. **B** Myoepithelial hyperplasia with SMA positive "myoid" transformation.

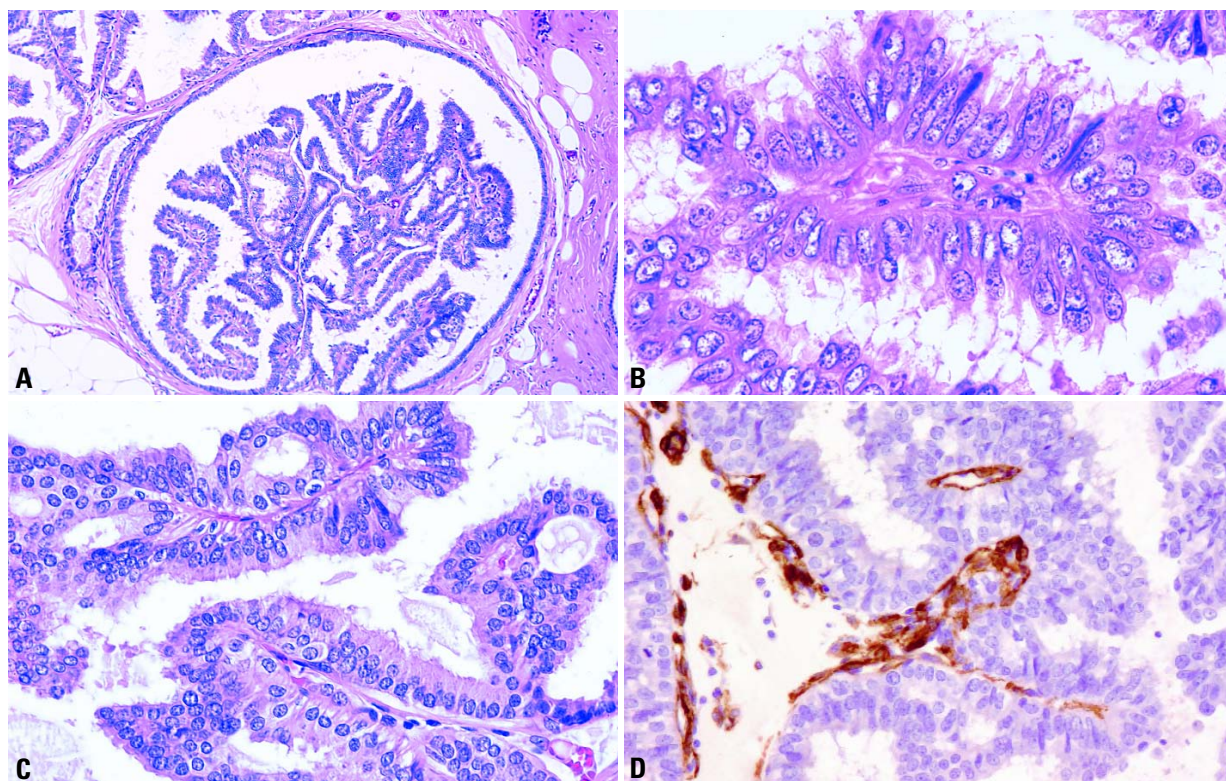


Fig. 1.103 Papillary intraductal carcinoma. **A** Cystically dilated duct with arborescent papillary tumour. **B** Papillary structure lined by epithelial columnar cells. **C** Two papillary structures lined by atypical cylindrical cells with formation of arcades. **D** Papillary structures are devoid of myoepithelial cells. Smooth muscle actin (SMA) immunostaining highlights vascular structures in papillary fronds. Epithelial cells lining the papillary fronds are CK 5/6 negative (not shown).

the papillary processes are totally devoid of a myoepithelial cell layer regardless of presence or absence of notable epithelial proliferation, and/or that any of the recognized patterns of low grade DCIS occupies 90% or more of the lesion.

These neoplasms can be either solitary and central in location corresponding to intracystic papillary carcinoma, or multifocal within the TDLU and correspond to the papillary type of DCIS.

Intracystic papillary carcinoma

Definition

This lesion is a variant of intraductal papillary carcinoma, located within a large cystic duct and characterized by thin fibrovascular stalks devoid of a myoepithelial cell layer and of a neoplastic epithelial cell population with histopathological features characteristic of low grade DCIS.

ICD-O code 8504/2

Synonyms

Intracystic papillary carcinoma, non-invasive; papillary intraductal carcinoma; papillary ductal carcinoma in situ; encysted papillary carcinoma.

Epidemiology

Less than 2% of breast carcinomas correspond to intraductal papillary carcinomas [413,1945]. The average age of occurrence is around 65 (range, 34-92 years) [413,1618].

Clinical and macroscopic features

On the basis of clinical presentation and macroscopy, there are no distinctive features that can separate papilloma from papillary carcinoma, nonetheless, intracystic papillary carcinomas tend to be larger.

Histopathology

Intraductal papillary carcinoma is a papillary lesion usually of large size

(mean 2 cm, range 0.4-10 cm) located within a large cystic duct characterized by thin fibrovascular stalks devoid of a myoepithelial cell layer and a neoplastic epithelial cell population usually presenting characteristics of low grade DCIS. These cells are arranged in either solid, cribriform, micropapillary or stratified spindle cell patterns [413,1618, 1945]. Some may show a dimorphic cell

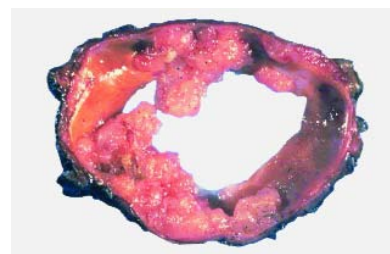

Fig. 1.104 Gross appearance of an intracystic papillary breast carcinoma. Macroscopically, the distinction between papilloma and papillary carcinoma may be difficult.

population (featuring epithelial and myoepithelial differentiation) which may be mistaken for two cell types [1618]. Less frequently, the epithelial cell component presents the characteristics of intermediate or high grade DCIS. Concomitant DCIS may be present in the surrounding breast tissue. A complete absence of the myoepithelial cell layer in the papillary processes indicates a carcinoma; the presence of myoepithelial cells does not invariably exclude the diagnosis of intraductal papillary carcinoma, however. A myoepithelial cell layer is usually present in the lining of the duct wall into which the papillary carcinoma proliferates.

Solid and transitional cell variants have been described [1752,1905]. The distinctive features of the former are production of extracellular and intracellular mucin, association with mucinous carcinoma and often a spindle cell population. Argyrophilia and neuroendocrine features have been noted in a large number of the solid cases [694,1752,2955]. The transitional cell variant is characterized by proliferation of sheets of transitional type cells overlying the fibrovascular cores.

As with benign papillomas entrapment of epithelial structures within the wall can result in a pseudoinvasive pattern. A definitive diagnosis of invasive carcinoma associated with intracystic papillary carcinoma should only be considered when neoplastic epithelial structures infiltrate the breast tissue beyond the fibrous wall and have one of the recognized patterns of invasive carcinoma. Following a needle biopsy (fine needle aspiration or core biopsy), epithelial displacement into the needle tract, scar tissue or lymphatic spaces can mimic invasion [3231].

Genetic alterations

Genetic alterations in the form of interstitial deletions [701], LOH [1671], numerical and structural alterations at chromosomes 16q and 1q with fusion of chromosomes 16 and 1 [der(1;16)] [2961] have been described, but the significance of these alterations are as yet, unclear.

Prognosis and predictive factors

Intraductal papillary carcinoma in the absence of concomitant DCIS or invasive carcinoma in the surrounding breast tissue has a very favourable prognosis with no reported lymph node metastases or disease-related deaths. The presence of

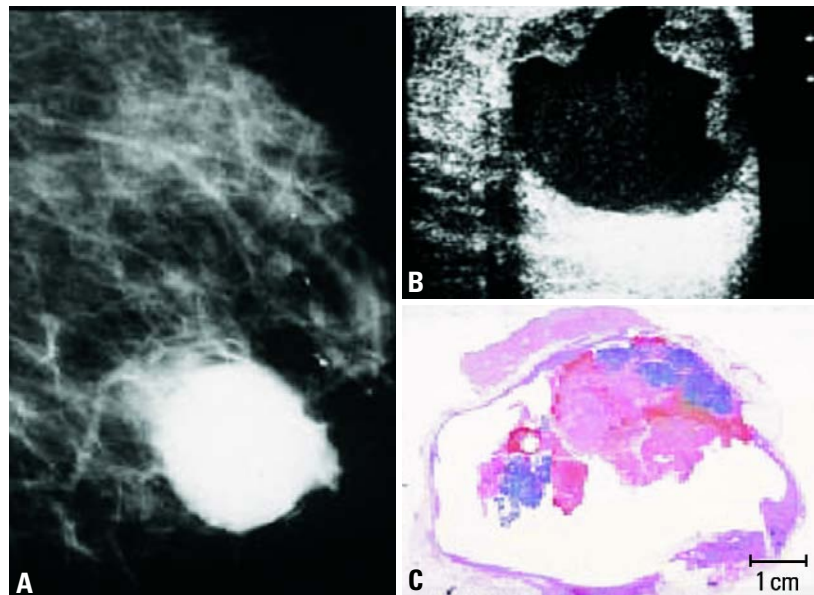


Fig. 1.105 Intracystic papillary carcinoma. **A** Left breast, medio-lateral oblique projection showing a 3x3 cm, solitary, high density circular mass in the lower half of the breast. **B** Breast ultrasound demonstrates intracystic growth. **C** Intracystic papillary carcinoma in situ. Large section histology.

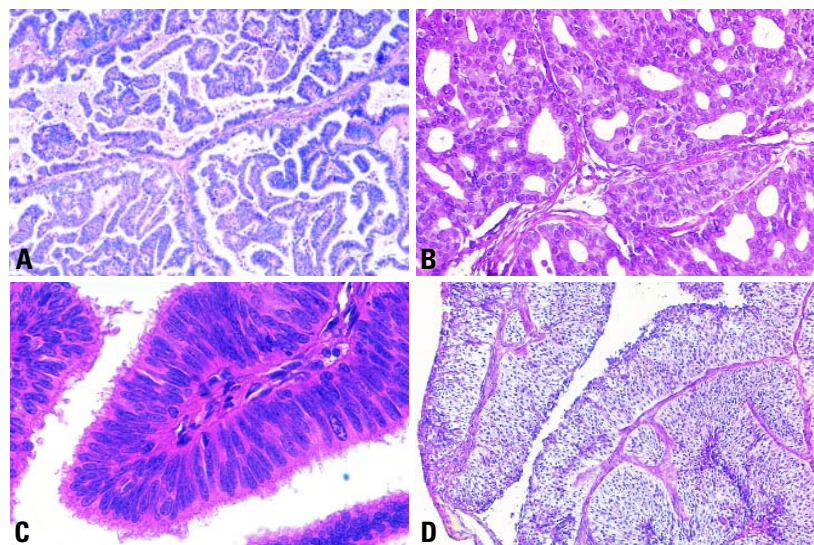


Fig. 1.106 Ductal intracystic papillary carcinoma. **A** Typical papillary pattern. **B** Cribriform pattern. **C** Stratified columnar cells, in the absence of myoepithelial cells. **D** Transitional cell-type pattern.

DCIS or invasive carcinoma in the surrounding breast tissue are associated with an increase in frequency of local recurrence (in situ or invasive) in the former, and an increase in local and metastatic rates in the latter [413]. Complete excision of intraductal papillary carcinoma with adequate sampling

of the lesion and surrounding breast tissue is mandatory for treatment and appreciation of subsequent breast cancer risk.

Prognosis and management of papillary type of DCIS is similar to that of common DCIS and is dealt with in the corresponding chapter.

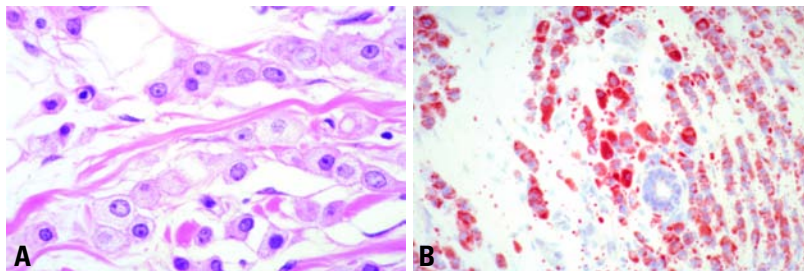


Fig. 1.51 Lipid rich carcinoma. **A** The cells have abundant eosinophilic or microvacuolated cytoplasm with round nuclei displaying prominent nucleoli. **B** Oil red O stain shows abundant intracytoplasmic lipids within every cell.

Immunoprofile

There is limited data in hormone receptor expression but all tumours from one series were negative [3158].

Ultrastructure

Well developed Golgi apparatus and lipid droplets of different sizes are recognized in the cytoplasm [1546].

Prognosis and predictive factors

Despite the positive correlation of lipid content with high histological grade [873] and extensive lymph node metastases in 11 of 12 patients [2330], at the present it is not possible to establish with certainty that lipid rich carcinomas are aggressive tumours. The reported series include very heterogeneous lesions and have very short follow up.

Secretory carcinoma

Definition

A rare, low grade carcinoma with a solid, microcystic (honeycomb) and tubular architecture, composed of cells that produce abundant intracellular and extracellular secretory (milk-like) material.

ICD-O code 8502/3

Synonym

Juvenile carcinoma.

Epidemiology

This is a rare tumour, with a frequency below 0.15% of all breast cancers [323,1579]. The tumour usually occurs in females, but has also been seen in males including a 3-year-old boy [1401]. It occurs in children [1831] as well as adults [1519,2080]. A recent report [2430] disclosed 67 patients. Twenty-five

(37%) were aged less than 20 years, 21 (31%) older than 30 years and the remaining 21 in between. Therefore, the term secretory carcinoma is preferred [2080]. Mucoid carcinoma, invasive lobular carcinoma and signet ring cell carcinoma are "secretory" carcinomas "in sensu strictu", but are all well defined distinct entities and therefore it is preferred to restrict the use of the term secretory carcinoma to this rare tumour type [2080].

Clinical features

The tumours manifest as indolent, mobile lumps, located near the areola in about half of the cases, this being especially so in men and children.

Macroscopy

SC usually presents as circumscribed nodules, greyish-white or yellow to tan in

colour measuring from 0.5 to 12 cm. Larger tumours occur in older patients.

Histopathology

Microscopically SC is generally circumscribed, but areas of invasion of the adipose tissue are frequent. Sclerotic tissue in the centre of the lesion may be observed. The lesions are structurally composed of 3 patterns present in varying combinations:

1. A microcystic (honeycombed) pattern composed of small cysts often merge into larger spaces closely simulate thyroid follicles [2722],
2. A compact more solid, and
3. A tubular pattern consisting of numerous tubular spaces containing secretions [1519].

The neoplastic cells have been subdivided into two types [2881] with all possible combinations. One has a large amount of pale staining granular cytoplasm, which on occasions can appear foamy. The nuclei are ovoid and have a small nucleolus. Intracytoplasmic lumina (ICL) are numerous and vary from small to "enormous" [1579]. Fusion of ICL generates the microcystic structures. The secretion located within the ICL or in the extracytoplasmic compartment is intensely eosinophilic and PAS positive after diastase digestion in most of the cases; Alcian blue positive material is also seen. The two types of mucosubstances are usually independently produced and a combination of the two

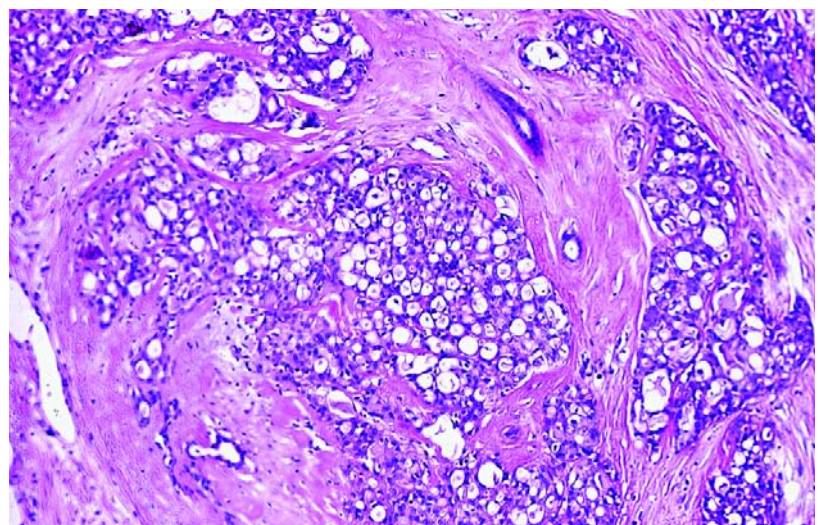


Fig. 1.52 Secretory carcinoma. The tumour cells have abundant pink eosinophilic cytoplasm.

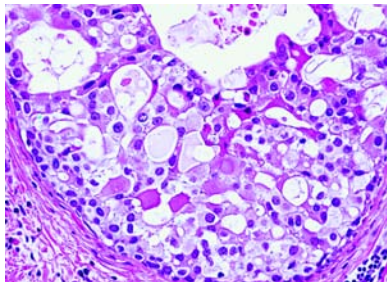


Fig. 1.53 Secretory carcinoma. The tumour cells have abundant pink eosinophilic cytoplasm.

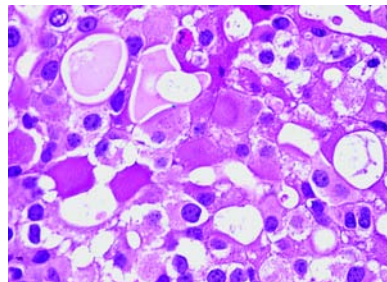


Fig. 1.54 Secretory carcinoma. Abundant secretory material is evident.

as seen in the "tagetoid pattern" of ICL described by Gad and Azzopardi [943] is rarely evident.

Mitoses and necrotic areas are rare. Ductal in situ carcinoma of either the secretory or low grade type may be present, either at the margins or within the tumour [2430].

Immunoprofile

EMA, alpha lactalbumin and S-100 protein are frequently expressed in SC [323,1579,2430]. Estrogen receptors are mostly undetectable.

Prognosis and predictive factors

SC has an extremely favourable prognosis in children and adolescents but seems slightly more aggressive in older patients [2881]. Isolated recurrences in children are exceptional [52], but the risk of nodal involvement is similar in young and older patients [2430]. Axillary lymph node metastases are found in approximately 15% of patients [2814] but metastases are confined to 4 lymph nodes at the most [52]. Tumours less than 2 cm in size are unlikely to progress [2881]. Simple mastectomy, as opposed to excision of the tumour, has led to a cure, with the exception of the case reported by Meis [1860]. Recurrence of the tumour may appear after 20 years [1519], and prolonged follow up is advocated. Fatal cases are the exception [1519,2881] and have never been reported in children.

Oncocytic carcinoma

Definition

A breast carcinoma composed of more than 70% oncocytic cells.

ICD-O code 8290/3

Historical annotation

Oncocyte (a Greek derived word) means "swollen cell", in this case due to an accumulation of mitochondria. The term oncocytic is used when mitochondria occupy 60% of the cytoplasm [990]. Oncocytic tumours can be seen in various organs and tissues [2271, 2405].

In oncocytes, mitochondria are diffusely dispersed throughout the cytoplasm while in mitochondrion-rich cells they are grouped to one cell pole [2948].

The proportion of oncocytes present within a tumour required to call it oncocytic has been arbitrarily proposed by various authors and varies from organ to organ. In a small series of breast oncocytic carcinomas, Damiani et al. [616], using immunohistochemistry with an anti

mitochondrial antibody, found 70-90% of the neoplastic cells packed massively with immunoreactive granules.

Epidemiology

Only occasional cases have been described [566,616]. However, the incidence in the breast is probably underestimated as oncocytes are easily overlooked or misdiagnosed as apocrine elements [615]. All described patients have been over 60 years old. There is no predilection for site. One case occurred in a man [566].

Macroscopy

The largest tumour measured 2.8 cm [616].

Histopathology

The tumours are all similar with defined, circumscribed borders and vary from glandular to solid. The cells have abundant cytoplasm filled with small eosinophilic granules. Nuclei are monotonous and round to ovoid with a conspicuous nucleolus. Mitoses are not frequent. In situ carcinomas with a papillary appearance have been described [616].

Differential diagnosis

Oncocytic carcinomas can be distinguished from apocrine, neuroendocrine carcinomas and oncocytic myoepithelial lesions [615,945,2013] by their immunophenotype.

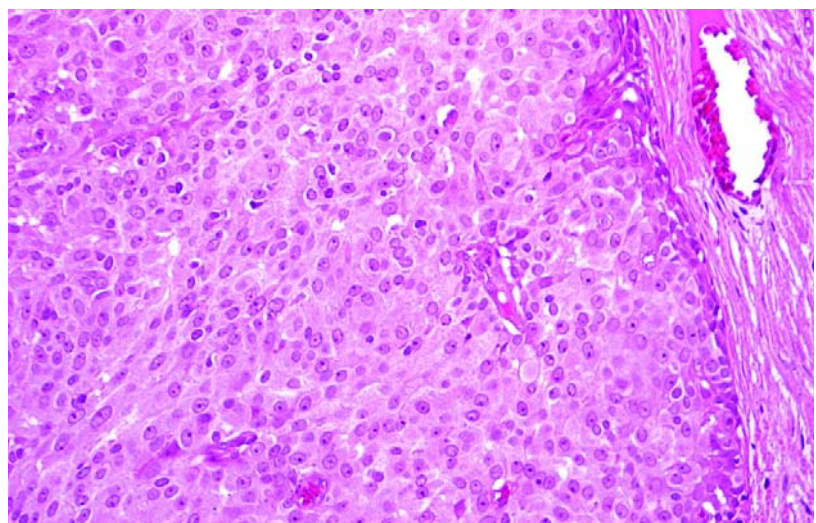


Fig. 1.55 Oncocytic carcinoma. Note well circumscribed nodule and cells with abundant eosinophilic cytoplasm.

Immunoprofile

The cases studied by Damiani et al. [616] showed diffuse and strong immunoreactivity with an anti mitochondrial antibody. Epithelial membrane antigen outlined the luminal borders of neoplastic glands when these were present. GCDFP-15 was absent in 3 cases and ER was observed in 90% of the cells in one [616].

Prognosis and predictive factors

The follow up and number of reported cases is too small to allow meaningful discussion of prognosis.

Adenoid cystic carcinoma

Definition

A carcinoma of low aggressive potential, histologically similar to the salivary gland counterpart.

ICD-O code 8200/3

Synonyms

Carcinoma adenoides cysticum, adenocystic basal cell carcinoma, cylindromatous carcinoma.

Epidemiology

Adenoid cystic carcinoma (ACC) represent about 0.1% of breast carcinomas [149,1581]. It is important that stringent criteria are adopted to avoid misclassified lesions as found in about 50% of the cases recorded by the Connecticut Tumor Registry [2815]. The age distribution, is similar to that seen in infiltrating duct carcinomas in general [2419].

Clinical features

The lesions are equally distributed between the two breasts and about 50% are found in the sub-periareolar region [149]. They may be painful or tender and unexpectedly cystic. A discrete nodule is the most common presentation.

Macroscopy

The size varies from 0.7 to 12 cm, with an average amongst most reported cases of 3 cm. Tumours are usually circumscribed, and microcysts are evident. They are pink, tan or grey in appearance [2309, 2419].

Histopathology

ACC of the breast is very similar to that of the salivary gland, lung and cervix [1838].

Three basic patterns are seen: trabecular-tubular, cribriform and solid. The 3 patterns have been used by Ro et al. [2381] to develop their grading system. The cribriform pattern is the most characteristic as the neoplastic areas are perforated by small apertures like a sieve. The "apertures" are of two types: The first, also referred to as pseudolumens [1406], results from intratumoral invaginations of the stroma (stromal space). Accordingly, this type of space is of varying shape, mostly round, and contains myxoid acidic stromal mucosubstances which stain with Alcian blue [152] or straps of collagen with small capillaries. Sometimes the stromal spaces are filled by hyaline collagen and the smallest are constituted by small spherules or cylinders of hyaline material which has been shown ultrastructurally and immunohistochemically to be basal lamina [463]. With immunohistochemistry a rim of laminin and collagen IV positive material outlines the stromal spaces. The second type of space is more difficult to see as it is less numerous and usually composed of small lumina. These are genuine secre-

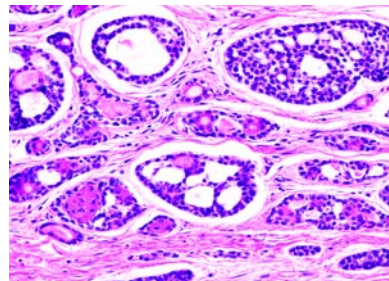


Fig. 1.56 Adenoid cystic carcinoma. The typical fenestrated nests composed of two cell types (dominant basaloid and few eosinophilic) are shown.

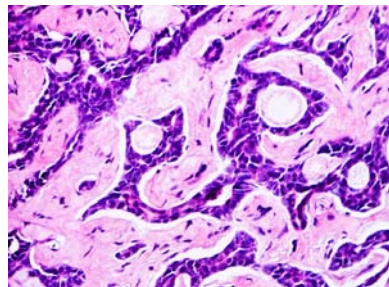


Fig. 1.57 Adenoid cystic carcinoma. In this case, there is a predominant tubular architecture.

tory glandular structures (glandular space) which contain eosinophilic granular secretion of neutral mucosubstances, and are periodic acid-Schiff positive after diastase digestion [152].

The dual structural pattern reflects a dual cell component. The basaloid cell has scanty cytoplasm, a round to ovoid nucleus and one to two nucleoli [1581]. It constitutes the bulk of the lesion and also lines the cribriform stromal spaces. The second type of cell lines the true glandular lumina, and has eosinophilic cytoplasm and round nuclei similar to those of the basaloid cells. A third type of cell seen in 14% of cases by Tavassoli and Norris [2885] consists of sebaceous elements that can occasionally be numerous.

ACC contains a central core of neoplastic cells, surrounded by areas of invasion; ductal carcinoma in situ is absent at the periphery. The stroma varies from tissue very similar to that seen in the normal breast to desmoplastic, myxoid or even extensively adipose.

ACC has been seen in association with adenomyoepithelioma [2994] and low grade syringomatous (adenosquamous) carcinoma [2419] which suggests a close relationship among these combined epithelial and myoepithelial tumours.

Differential diagnosis

ACC must be distinguished from benign collagenous spherulosis [519] and from cribriform carcinoma, which more closely simulates ACC. Cribriform carcinoma is characterized by proliferation of one type of neoplastic cell only, and one type of mucosubstance. In addition, estrogen and progesterone receptors are abundant in cribriform carcinomas and absent from virtually all cases of ACC [2381].

Immunoprofile and ultrastructure

The two main cell types are different at both ultrastructural and immunohistochemical levels.

Ultrastructurally, the basaloid cells have myoepithelial features particularly when located at the interstitial surface that lines the pseudoglandular spaces [3244]. They show thin cytoplasmic filaments with points of focal condensation [3094]. These cells have been shown to be positive for actomyosin [105] and similar to myoepithelial cells are posi-

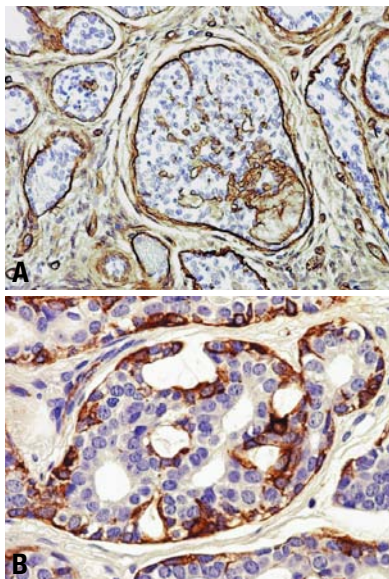


Fig. 1.58 Adenoid cystic carcinoma. Immunostain for laminin (A) decorates the basement membranes, while cytoplasmic immunoreaction with actin (B) unmasks the neoplastic myoepithelial cell component of the tumour.

tive for smooth muscle actin and calponin [902] as well as keratin 14. Nevertheless, most basaloid cells are nondescript elements showing at electron microscopy level few filaments and organelles without specific features [1507,2885].

The cells that line the glandular lumina are cuboidal to spindle-shaped. When cuboidal, they have blunt microvilli along the luminal margins (secretory type). When spindle-shaped, they show abundant tonofilaments along with microvillous cytoplasmic processes such as to merit the design [2885]. Accordingly, the secretory type of cell

is keratin 7 positive, while the adenoid squamous cell is both keratin 7 and 14 positive [902]. These cells can undergo squamous metaplasia as seen in two of the cases reported by Lamovec et al. [1581]. Squamous metaplasia is more common in breast ACC, but is virtually never seen in salivary gland ACC.

Prognosis and predictive factors

ACC is a low grade malignant tumour generally cured by simple mastectomy. Like its analogue in the salivary gland, it rarely spreads via the lymphatic stream. Local recurrence is related to incomplete excision, but patients have been reported to survive 16 years after the excision of the recurrence [2223]. Only two cases of axillary node metastases have been reported [2381,3094]. Distant metastases occur in about 10% of cases [544] and the lungs are frequently involved.

Acinic cell carcinoma

Definition

Acinic cell carcinoma (ACCA) is the breast counterpart of similar tumours that occur in the parotid gland and show acinic cell (serous) differentiation.

ICD-O code 8550/3

Epidemiology

ACCA is a rare tumour. Seven cases have been recorded [619,2561]. Other carcinomas showing serous secretion, probably related to ACCA, have also been reported [1287,1483]. It affects women between 35 and 80 years (mean 56 years) [619].

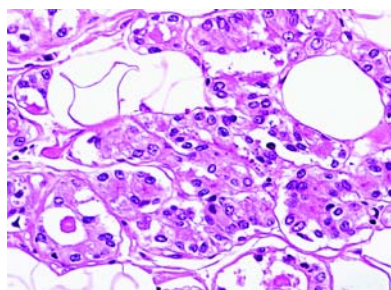


Fig. 1.59 Acinic cell carcinoma showing aggregates of cells with granular cytoplasm.

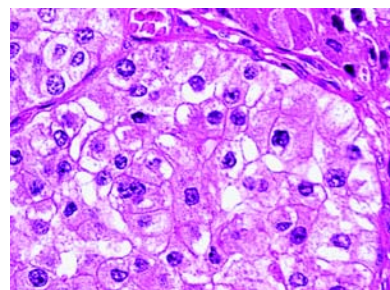


Fig. 1.60 Acinic cell carcinoma. Note the absence of nuclear atypia.

Clinical features

ACCA presents as a palpable nodule ranging from 2 to 5 cm size. One case was discovered at mammography [619].

Histopathology

The tumours show a combination of solid, microcystic and microglandular areas. One case [619] was mostly solid, and another [2404] had comedo-like areas with a peripheral rim of microglandular structures.

Cytologically, the cells have abundant, usually granular, amphophilic to eosinophilic cytoplasm. The granules may be coarse and, bright red, reminiscent of those in Paneth cells or amphophilic. However, clear "hypernephroid" cytoplasm is not unusual. The nuclei are irregular, round to ovoid, with a single nucleolus. The mitotic count varies and can be as high as 15 mitoses/10 high power fields [619].

Immunoprofile

Most of the cells stain intensely with anti-amylase, lysozyme, chymotrypsin, EMA and S-100 protein antisera [619]. GCDPF-15, the mucoapocrine marker, may also be focally positive.

Ultrastructure

Three cases published were composed of cells with cytoplasm filled by zymogen-like granules measuring from 0.08 to 0.9 μ m [619,2404,2561].

Prognosis and predictive factors

None of the 7 reported cases has died of the tumour, although follow up was limited (maximum 5 years). In two cases axillary lymph nodes contained metastases. Treatments varied from neoadjuvant chemotherapy with radical mastectomy to lumpectomy alone.

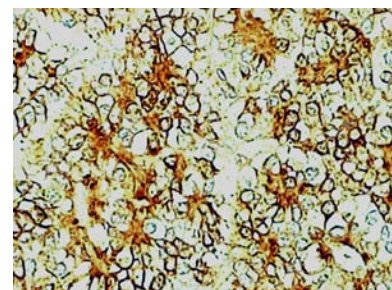


Fig. 1.61 Acinic cell carcinoma, immunostain is positive for lysozyme.

Glycogen-rich, clear cell carcinoma (GRCC)

Definition

A carcinoma in which more than 90% of the neoplastic cells have abundant clear cytoplasm containing glycogen.

ICD-O code 8315/3

Synonyms

Clear cell carcinoma 8310/3
Glycogen-rich carcinoma 8315/3

Epidemiology

The frequency is from 1-3% of breast carcinomas [880,1264], with an age range of 41-78 years, median 57 years [2870].

Clinical features

These tumours show similar presentation features to ductal NOS carcinoma.

Macroscopy

The clear cell glycogen-rich carcinoma does not differ grossly from that of usual invasive or intraductal carcinoma [1165]. The neoplasm ranges from 1 to 8 cm in size [2422,2754,2870].

Histopathology

A strict definition for clear cell glycogen-rich is necessary for two reasons. Carcinomas in the breast with a clear cell appearance are uncommon and are due to an artefact produced by extraction of intracytoplasmic substances during tissue processing. However, as the substances that are extracted differ, they may be of different biological significance. In addition, intracytoplasmic glycogen has

been observed without significant clear cell in 58% of breast carcinoma [880].

The lesions usually have the structural features of intraductal and infiltrating ductal neoplasms but rarely those of lobular, medullary or tubular types have been noted. GRCCs has either circumscribed or infiltrative borders [880,165,2754,2870].

The in situ component, either in the pure form or in association with most invasive cases has a compact solid, comedo or papillary growth pattern. The invasive tumour is generally composed of solid nests, rarely of tubular or papillary structures.

The tumour cells tend to have sharply defined borders and polygonal contours. The clear or finely granular cytoplasm contains PAS positive diastase labile glycogen. The nuclei are hyperchromatic, with clumped chromatin and prominent nucleoli.

Differential diagnosis

To differentiate this tumour from other clear cell tumours, including lipid rich carcinoma, histiocytoid carcinoma, adenomyoepithelioma, clear cell hidradenoma and metastatic clear cell carcinoma (particularly of renal origin), enzyme cytochemistry and immunohistochemistry are useful [702,1165,1549,2754].

Immunoprofile

Hormone receptor status is similar to ductal NOS [880].

Prognosis and predictive factors

Most reports suggest that GRCC is more aggressive than typical ductal carcinoma

[2313,2754]. The incidence of axillary lymph node invasion is significantly higher than in the other non-GRCC forms [1264]. The histologic grade is intermediate to high with a paucity of grade I tumours [1165].

Although follow up studies confirm that disease free and overall survival is significantly worse in GRCC, due to the low incidence, there are no multiparametric analyses to compare GRCC stage by stage with the other histological types of breast carcinoma.

Sebaceous carcinoma

Definition

A primary breast carcinoma of the skin adnexal type with sebaceous differentiation. There should be no evidence of derivation from cutaneous adnexal sebaceous glands.

ICD-O code 8410/3

Epidemiology

Only 4 examples of this rare mammary tumour have been observed [2876]. The women, three of whom were white, were aged 45-62 years [2876,3006].

Clinical features

All the patients presented with a palpable mass.

Macroscopy

The tumours range in size from 7.5-20 cm. The margins are sharply delineated, and the cut surface is solid and bright yellow.

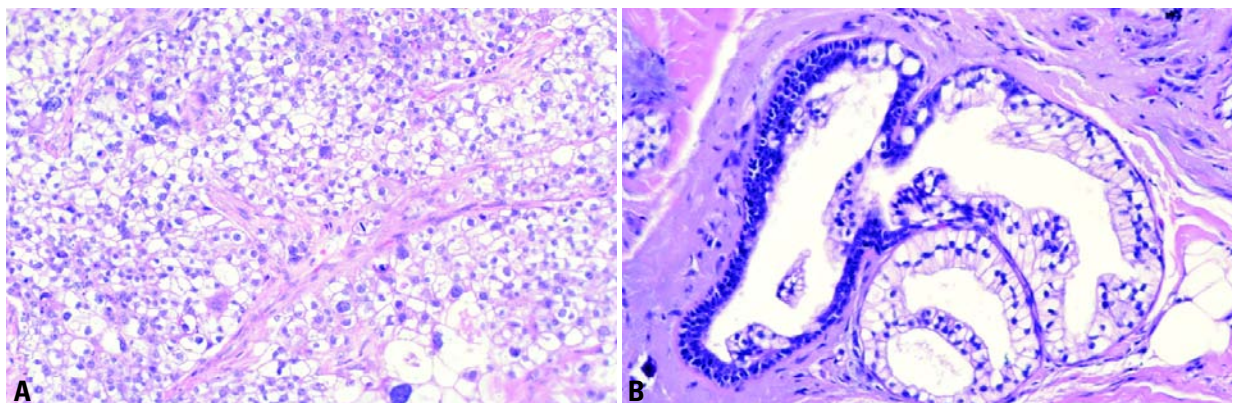


Fig. 1.62 Glycogen-rich carcinoma. **A** Cells with abundant clear cytoplasm and relatively uniform round nuclei grow in a solid pattern supported by branching vessels. **B** Note transition from typical ductal epithelial cells to clear cells in a duct adjacent to the invasive carcinoma.

Table 1.09

Glycogen-rich (GRCC) and non glycogen-rich clear cell tumours of the breast.

	GRCC	Lipid rich carcinoma	Histiocytoid lobular carcinoma	Apocrine carcinoma	Hidradenoma	Secretory carcinoma	Adenomyo-epithelioma	Metastatic clear cell carcinoma from the kidney
Cell type	One	One	One	One	Two	One	Two	One
Cytoplasm	Empty	Foamy	Foamy	Foamy	Empty	Foamy/empty/granular		Empty
Nuclei	High grade	High grade	Low grade	Low grade	Low grade	Low grade	Low grade	Low grade
PAS	+	-	-	+	+	+	+	+
PAS diastase	-	-	-	+	+	-	+/-	-
Mucicarmine	-	-	+	+	-	+	-	-
Oil red-O	-	+	-	-	-	-	-	-
Smooth actin	-	-	-	-	-	-	+	- Vimentin +
S100	-	-	-	-	+	+	+	-
GCDFP-15	+/-	-	+	+	-	-	+	-

Histopathology

The tumour is characterized by a lobulated or nested proliferation of a varying admixture of sebaceous cells with abundant finely vacuolated cytoplasm surrounded by smaller ovoid to spindle cells with a small amount of eosinophilic cytoplasm and without any vacuolization. The nuclei in both cell types are irregularly shaped to rounded, vesicular with 0 to 2 nucleoli. Mitotic figures are sparse, but may be focally abundant. Focal squamous morules may be present focally. Sebocrine cells with features of both apocrine and sebaceous cells and noted in a variety of apocrine lesions have not been a notable feature of sebaceous carcinomas.

Immunoprofile

The tumour cells stain positively with pan-cytokeratin (AE1/AE3/LP34). In the three cases assessed, immunostains for progesterone receptor (PR) were positive in all, two were estrogen receptor (ER) positive, and one was ER negative.

Differential diagnosis

Apocrine carcinoma with a large population of sebocrine cells and lipid rich carcinomas enter the differential diagnosis. The former invariably has typical apocrine cells admixed and the latter forms cords and irregular cell clusters with a more subtle vacuolization of the cells.

Neither has the smaller second cell population or the squamous metaplasia that may be present in sebaceous carcinoma.

Prognosis and predictive factors

Not much is known about the behaviour of these tumours. The 7.5 cm tumour was treated by radical mastectomy, but none of the 20 axillary nodes was positive [2876]. Another recently reported case was associated with extensive metastases with sebaceous differentiation evident at the distant sites [3006].

Inflammatory carcinoma**Definition**

A particular form of mammary carcinoma with a distinct clinical presentation [1607] believed to be due to lymphatic obstruction from an underlying invasive adenocarcinoma; the vast majority of cases have a prominent dermal lymphatic infiltration by tumour. Inflammatory carcinoma is a form of advanced breast carcinoma classified as T4d [51, 2976]. Dermal lymphatic invasion without the character-

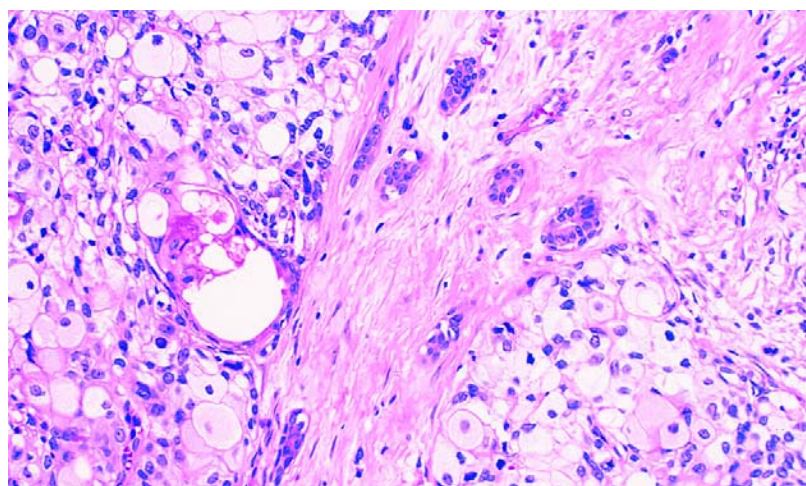


Fig. 1.63 Sebaceous carcinoma. The cells have abundant finely vacuolated cytoplasm and form rounded aggregates with a few amphophilic cells present in the periphery.

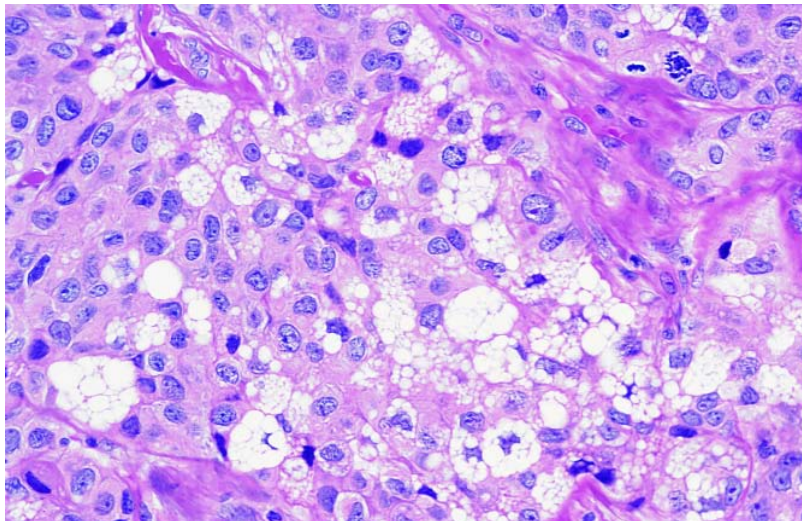


Fig. 1.64 Sebaceous carcinoma. Cells with moderate amounts of eosinophilic or abundant microvacuolated cytoplasm and variably compressed nuclei resembling lipoblasts are admixed.

istic clinical picture is insufficient to qualify as inflammatory carcinoma.

ICD-O code 8530/3

Epidemiology

The age distribution is similar to ductal NOS carcinoma and breast carcinoma in general [1095,2384]. There is no recognized specific association with younger age and pregnancy but the phenomenon of peritumoural lymphatic vascular invasion is found more frequently in younger women [1095,2795]. The reported frequency of an inflammatory presentation of primary breast carcinoma varies between 1 and 10%, being influenced by the diagnostic criteria (clinical or pathological) and the nature of the reporting centre (local population clinical centre versus tertiary referral centre) [769,1641,2517].

Clinical features

The clinical findings include diffuse erythema, oedema, peau d'orange, tenderness, induration, warmth, enlargement and in some cases a palpable ill defined mass. The diagnosis is based on clinical features and should be confirmed by biopsy. Dermal lymphatic tumour emboli are not always found in small diagnostic skin biopsy samples [724,2384].

Histopathology

Despite the name, inflammatory carcinoma is not associated with any significant degree of inflammatory cell infiltration and

is not an inflammatory condition. The cutaneous signs are produced as a consequence of lymphatic obstruction and consequent oedema, which produce signs mimicking an inflammatory process. Inflammatory signs can be the primary clinical presenting abnormality (primary inflammatory carcinoma) or develop as a consequence of tumour recurrence (secondary inflammatory carcinoma). Histologically the underlying invasive carcinoma is not regarded as having specific histological features, the majority of tumours have ductal NOS and are of grade 3 morphology [1708,1851]. These tumours often have an associated lymphoid infiltrate usually of mature lymphocytes and plasma cells, a low frequency of estrogen receptor positivity [445,1490] and ERBB2 overexpression [1074]. The skin often shows co-existing features associated with lymphatic obstruction including separation of collagen fibres with broadening of the reticular dermal layer due to oedema. Involved dermal lymphatics may have an associated lymphoplasmacytic infiltrate [2427]. Secondary or recurrent inflammatory carcinoma has been shown to be associated more with ductal NOS and apocrine histological types of breast carcinoma and is rare following presentation with other types, papillary, medullary and mucinous [2384]. The skin may also show stromal metastatic deposits of tumour particularly in secondary or recurrent inflammatory carcinoma.

Differential diagnosis

There may be a discrepancy between clinical presentation with inflammatory features and presence of dermal lymphatic emboli. Dermal vascular emboli may not be present in a biopsy taken from erythematous or oedematous area, or may be present in skin beyond the clinical skin changes. The skin biopsy will usually also show dermal lymphatic dilatation. The clinical features of inflammatory carcinoma are generally regarded as specific but underlying true inflammatory conditions should be excluded if histological confirmation is not achieved.

Prognosis and predictive factors

Prior to the introduction of systemic therapy the prognosis of inflammatory carcinoma even when treated by mastectomy, was very poor with 5 year survival under 5% [1052,2384]. Use of systemic chemotherapy has produced an improvement in survival figures reported as 25 to 50% at 5 years [406,828,1805,1907,2154]. In cases treated with neoadjuvant chemotherapy or radiotherapy, residual tumour, including intravascular emboli, are usually present in the mastectomy specimen even when a clinical response has been observed [2427]. Mastectomy and radiotherapy are considered beneficial for initial local control and palliation of symptoms [406,582,2243]. There are no consistent findings with respect to influence of additional clinical features such as presence of a clinical mass or findings in skin biopsy on survival. However, response to chemotherapy and radiotherapy, and pathological response have been shown to be associated with improved disease free survival [473,828,841,1826].

Bilateral breast carcinoma

Definition

A synchronous breast cancer is one detected within two months of the initial primary tumour.

Approximately 5-10% of women treated for breast cancer will have either synchronous bilateral cancers or will develop a subsequent contralateral breast cancer (CBC) [448,872,1219,1491,2383]. The prevalence of synchronous bilateral breast cancer is approximately 1% of all breast cancers [448,648,872,1491,1936]. An increase in the detection

of synchronous cancers has been reported following the introduction of bilateral mammography for the investigation of symptomatic breast disease and for population based breast screening {751,872,1491,1492}.

It is well recognized that a previous history of breast cancer increases the risk of subsequent breast cancer in the contralateral breast. The reported annual hazard rates of between 0.5-1% per year {448,872,1491,2383,2798} appear relatively constant up to 15 years {1491} giving a cumulative incidence rate for survivors of around 5% at 10 years and 10% at 15 years.

Family history {253,448,1219} and early age of onset {35,1168,2798} have been reported to increase the risk of CBC development in some studies but others have found no such associations with either early age of onset {252,253,872} or family history {35,872}. One study has reported that family history, early age of onset and lobular histology are independent predictors of metachronous contralateral breast cancer development {1492}. These characteristics suggest a possible genetic predisposition. Women with a strong family history who develop breast cancer at an early age are at considerable risk of contralateral breast cancer as a first event of recurrence particularly if the first primary is of lobular histology or is of favourable prognostic type {1491, 1492}.

Patients with metachronous CBC are younger at the age of onset of the original primary. Many, but not all, series report that a higher percentage of the tumours are of lobular type {35,252,872, 1219,1241,1492,2383}. This observation does not imply that tumours of lobular type, in isolation from other risk factors such as young age and family history, should be considered to have a higher risk of bilateral breast involvement {1491}. A greater frequency of multicentricity in one or both breast tumours has also been reported {355}. There does not appear to be any association with histological grade, other tumour types or the stage of the disease {355,1491,1492}.

Prognosis and predictive features

Theoretically women with synchronous CBC have a higher tumour burden than women with unilateral disease which may jeopardize their survival prospects {1035}. Indeed, synchronous CBC

appears to have a worse prognosis than unilateral cohorts or women with metachronous CBC {164,1092,1233}. Others have failed to demonstrate any survival difference between women with unilateral and those with synchronous CBC {911,1053,2555}.

Tumour spread and staging

Tumour spread

Breast cancer may spread via lymphatic and haematogenous routes and by direct extension to adjacent structures. Spread via the lymphatic route is most frequently to the ipsilateral axillary lymph nodes, but spread to internal mammary nodes and to other regional nodal groups may also occur. Although breast cancer may metastasize to any site, the most common are bone, lung, and liver. Unusual sites of metastasis (e.g. peritoneal surfaces, retroperitoneum, gastrointestinal tract, and reproductive organs) and unusual presentations of metastatic disease are more often seen with invasive lobular carcinomas than with other histological types {319,704,1142,1578}.

Several models have been proposed to explain the spread of breast cancer. The Halsted model, assumes a spread from the breast to regional lymph nodes and from there to distant sites. This hypothesis provided the rationale for radical en bloc resection of the breast and regional lymph nodes. Others suggest a systemic disease from inception, which implies that survival is unaffected by local treatment. However, clinical behaviour suggests that metastases occur as a function of tumour growth and progression {1181}. This concept is supported by the results of axillary sentinel lymph nodes, which show that metastatic axillary lymph node involvement is a progressive process.

Tumour staging

Both clinical and pathological staging is used in breast carcinoma. Clinical staging is based on information gathered prior to first definitive treatment, including data derived from physical examination, imaging studies, biopsy, surgical exploration, and other relevant findings. Pathological staging is based on data used for clinical staging supplemented or modified by evidence obtained during surgery, particularly from the pathologi-

cal examination of the resected primary tumour, regional lymph nodes, and/or more distant metastases, when relevant. The staging system currently in most widespread use is the TNM Classification {51,2976}. The most recent edition is provided at the beginning of this chapter. The pathological tumour status ("pT") is a measurement only of the invasive component. The extent of the associated intraductal component should not be taken into consideration. In cases of microinvasive carcinoma (T1mic) in which multiple foci of microinvasion are present, multiplicity should be noted but the size of only the largest focus is used, i.e. the size of the individual foci should not be added together. The pathological node status ("pN") is based on information derived from histological examination of routine haematoxylin and eosin-stained sections. Cases with only isolated tumour cells are classified as pNO (see relevant footnote in the TNM Table which also indicates how to designate sentinel lymph node findings). A subclassification of isolated tumour cells is provided in TNM publications {51,1195, 2976}.

Measurement of tumour size

The microscopic invasive tumour size (I) is used for TNM Classification (pT). The dominant (largest) invasive tumour focus is measured, except in multifocal tumours where no such large single focus is apparent. In these cases the whole tumour size (w) is used.

Somatic genetics of invasive breast cancer

As in other organ sites, it has become evident that breast cancers develop through a sequential accumulation of genetic alterations, including activation of oncogenes (e.g. by gene amplification), and inactivation of tumour suppressor genes, e.g. by gene mutations and deletions.

Cytogenetics

As yet no karyotypic hallmarks of breast cancer have been identified, such as the t(8;14) in chronic myelogenous leukaemia (CML), or the i(12p) in testicular cancer. There is not even a cytogenetic marker for any of the histological subtypes of breast cancer. One reason for this is certainly the technical difficulty of obtaining sufficient numbers of good

quality metaphase spreads from an individual tumour. However, it may also relate to the genetic complexity of this tumour. Nonetheless, several hundred primary tumours have been karyotyped to date, allowing some general patterns to be discerned [1879]. An increased modal chromosome number is the most conspicuous characteristic in many tumours, in keeping with the finding that approximately two-thirds of all breast cancers have a hyperploid DNA-content in flow-cytometric analysis. Unbalanced translocations are most often seen as recurrent changes, with the *i*(1)(q10) and the *der*(1;16)(q10;p10) the most prominent. For the latter, it is not clear whether loss of 16q or gain of 1q is the selective change, or whether both are. Other conspicuous changes are *i*(8)(q10), and subchromosomal deletions on chromosomes 1 (bands p13, p22, q12, q42), 3 (p12-p14), and 6 (q21). No specific genes have been associated with any of these changes.

DNA amplification

Classic cytogenetic analysis had already indicated that double minute chromo-

somes and homogeneously staining regions, are a frequent occurrence in breast cancer. These regions were later shown to contain amplified oncogenes (see below). Comparative genomic hybridization (CGH) has identified over 20 chromosomal subregions with increased DNA-sequence copy-number, including 1q31-q32, 8q24, 11q13, 16p13, 17q12, 17q22-q24 and 20q13. For many of these regions, the critically amplified genes are not precisely known. Chromosomal regions with increased copy-number often span tens of megabases, suggesting the involvement of more than one gene. Loss of chromosomal material is also detected by CGH, and this pattern is largely, though not completely, in agreement with loss of heterozygosity data (see below).

Oncogenes

A number of known oncogenes were initially found to be amplified in subsets of breast cancer by Southern blot analyses and fluorescent in situ hybridization. Subsequently, a number of genes have been identified as critical targets for DNA amplifications by a combination of

CGH and gene expression analysis. Oncogenic activation by point-mutation seems to be rare in breast tumours. Listed by chromosome region, the following (onco)gene amplifications seem to be involved in the progression of breast cancer.

1p13-21: *DAM1* has been found amplified in two breast cancer cell lines, but it is not certain whether this gene is driving the amplification [1962].

7p13: The epidermal growth factor receptor gene (*EGFR*), encoding a cell membrane localized growth factor receptor, is amplified in less than 3% of breast carcinomas.

8p12: The fibroblast growth factor receptor 1 gene (*FGFR1*; formerly called *FLG*) encoding a cell membrane located receptor for fibroblast growth factor, is amplified in approximately 10% of breast carcinomas [41].

8q24: *MYC* encodes a nuclear protein involved in regulation of growth and apoptosis. *MYC* amplification is found in approximately 20% of breast [250,596]. The *MYC* protein has a very short half-life, precluding the assessment of protein

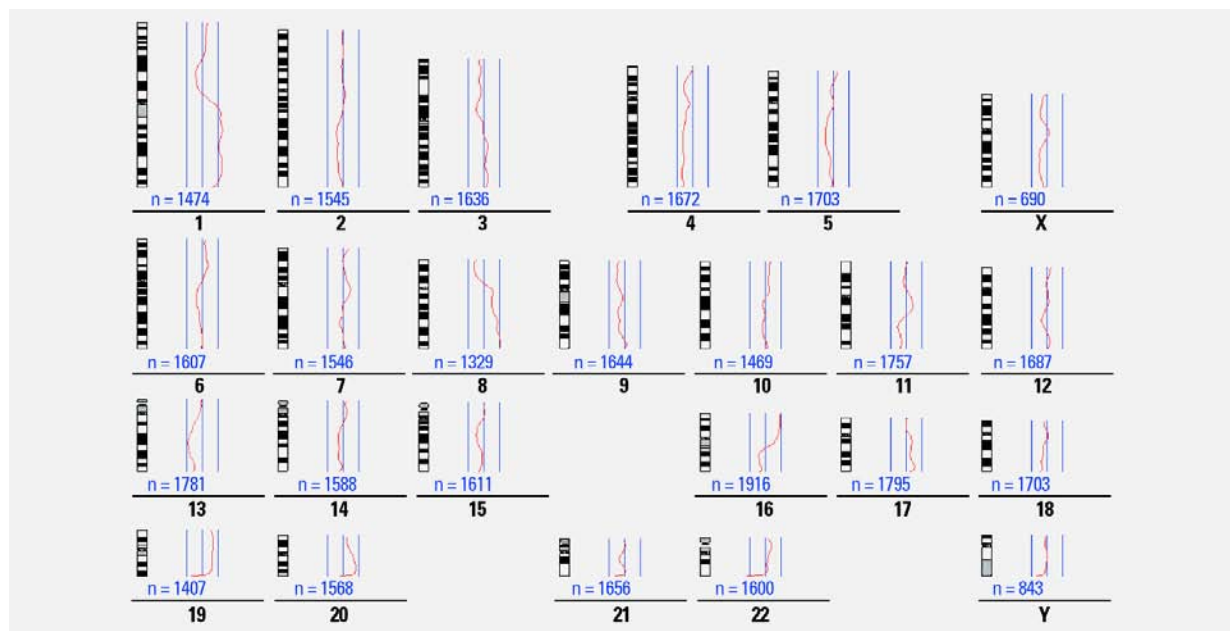


Fig. 1.65 Invasive ductal carcinoma. Summary of comparative genome hybridization analysis of 80 cases. The chromosome numbers are in black. The red curves depict the average ratio profiles between tumour-derived and normal-derived fluorescence signals. Of the three lines to the right of each chromosome, the middle represents a ratio of 1.0; deviations of the curve to the left or right indicate loss or gain of chromosomal material, respectively. Average ratios were computed from "n" single chromosomes from different metaphases. Data were retrieved from the Online CGH Tumour Database (<http://amba.charite.de/~ksch/cghdatabase/index.htm>). For details on methodology see F. Richard et al. [2366].

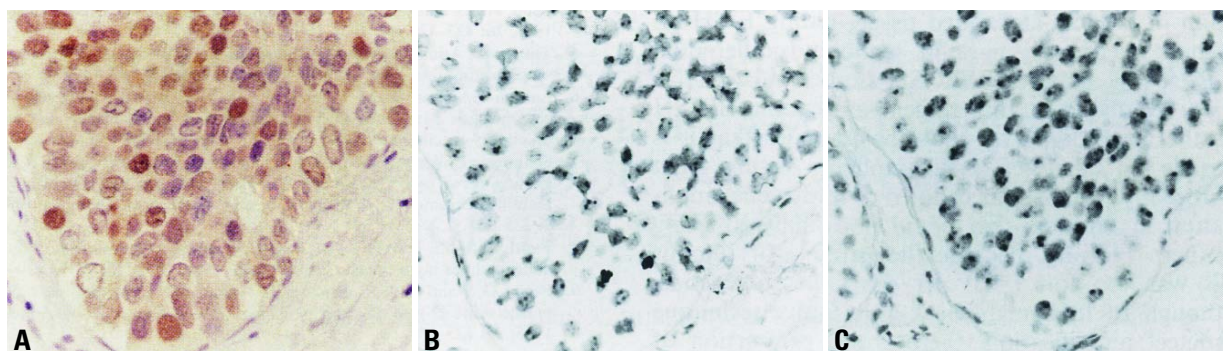


Fig. 1.66 Poorly differentiated DCIS. **A** Immunohistochemical staining and bright field in situ hybridization (BRISH) of cyclin D1 in the same case of DCIS. Strong staining of poorly differentiated DCIS. **B** Immunohistochemical staining and BRISH of cyclin D1 in the same case of DCIS. BRISH with a chromosome 11-specific (peri)centromeric probe. **C** BRISH with the cyclin D1 specific cosmid. Immunohistochemical staining and BRISH of cyclin D1 in the same case of DCIS. BRISH with the cyclin D1 specific cosmid. Reprinted with permission from C.B. Vos et al. [3035].

overexpression as a substitute for the analysis of gene amplification. Amplification of subregions of 8q can be complex. There appears to be at least one additional oncogene mapping to chromosome 8q12-22, which has not been identified yet.

10q26: The fibroblast growth factor receptor 2 (*FGFR2*; formerly: *BEK*) gene encodes a cell membrane located receptor for fibroblast growth factor. This gene is amplified in approximately 12% of breast carcinomas [41].

11q13: Amplification of the cyclin D1 gene (*CCND1*), encoding a nuclear protein involved in cell cycle regulation, has been found in 15-20% of breast tumours, in association with estrogen receptor positivity. Cyclin D1 can also bind to the estrogen receptor, resulting in ligand-independent activation of the receptor [3273]. Immunohistochemically, cyclin D1 appears to be overexpressed in 80% of invasive lobular carcinomas, but is not always accompanied by *CCND1* gene amplification [2133].

17q12: The human epidermal growth factor receptor-2 (*ERBB2*) proto-oncogene (also known as *HER2*, and equivalent to the rodent *neu* gene) encodes a 185-kD transmembrane glycoprotein with intrinsic tyrosine kinase activity. A ligand for *ERBB2* has not been identified but it is hypothesized that *ERBB2* amplifies the signal provided by other receptors of this family by heterodimerizing with them. Ligand-dependent activation of *ERBB1*, *ERBB3*, and *ERBB4* by EGF or heregulin results in heterodimerization and, thereby, *ERBB2* activation. *ERBB2* amplification results in overexpression of

ERBB2 protein, but not all tumours with overexpression have amplified 17q12. Overexpression is found in approximately 20-30% of human breast carcinomas [2962]. In breast cancers with normal *ERBB2* copy number, expression of *ERBB2* may be variable but is very rarely as high as that in tumours with *ERBB2* amplification (usually 10-fold to 100-fold higher and equivalent to millions of monomers). Numerous studies have investigated the relationship between *ERBB2* status and clinicopathological characteristics in breast cancer [2962].

17q22-q24: At least three genes (*RPS6KB1*, *PAT1*, and *TBX2*) have been found to be co-amplified and overexpressed in ~10% of breast cancers [181]. Further analysis identified *RPS6KB1*, *MUL*, *APPBP2*, *TRAP240* and one unknown gene to be consistently overexpressed in two commonly amplified subregions [1896]. The ribosomal protein S6 kinase (*RPS6KB1*) is a serine-threonine kinase whose activation is thought to regulate a wide array of cellular processes involved in the mitogenic response including protein synthesis, translation of specific mRNA species, and cell cycle progression from G1 to S phase.

20q13: It is presently unknown whether the *CSE1L/CAS* gene, the *NCOA3* gene or any other gene in this region serves as the target for the amplification, which is found in approximately 15% of breast carcinomas. Three independent regions of amplification have been identified and their co-amplification is common. Cellular apoptosis susceptibility (*CAS*) encodes a protein, which may have a function in the control of apoptosis and

cell proliferation [346]. *NCOA3* gene encodes a co-activator of the estrogen receptor [109], and its amplification has been found to be associated with estrogen receptor positivity. High resolution mapping of the amplified domains has suggested that a putative oncogene, *ZNF217*, and *CYP24* (encoding vitamin D 24 hydroxylase), whose overexpression is likely to lead to abrogation of growth control mediated by vitamin D, may be targets for the amplification [60].

The *STK15* gene (also known as *BTAK* and *Aurora-A*) is amplified in approximately 12% of primary breast tumours, as well as in breast, ovarian, colon, prostate, neuroblastoma, and cervical cancer cell lines [3259]. *STK15* encodes a centrosome-associated serine-threonine kinase, and may also be overexpressed in tumours without amplification of 20q13 [1885]. Centrosomes appear to maintain genomic stability through the establishment of bipolar spindles during cell division, ensuring equal segregation of replicated chromosomes to daughter cells. Deregulated duplication and distribution of centrosomes are implicated in chromosome segregation abnormalities, leading to aneuploidy seen in many cancer cell types. Elevated *STK15* expression induces centrosome amplification and overrides the checkpoint mechanism that monitors mitotic spindle assembly, leading to chromosomal instability [83,1885,3259].

Loss of heterozygosity (LOH)

Loss of heterozygosity (LOH) has been found to affect all chromosome arms

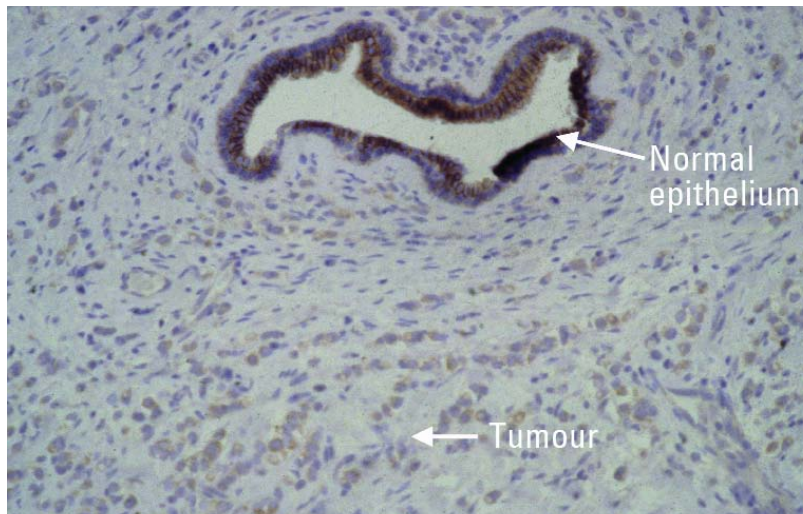


Fig. 1.67 Lobular carcinoma of breast. Immunohistochemical staining of a lobular breast carcinoma with a mutated *CDH1* gene. Normal duct epithelium shows positive staining for membrane associated E-cadherin, which is lacking in tumour cells.

in breast cancer to varying degrees [265,680]. Unfortunately, collation of LOH data into a coherent map has been complicated enormously by the use of different terminology and technology in this area [679]. A tumour specific loss of an allele, but also an imbalance in allele intensities (allelic imbalance) are both called LOH. LOH is often equated with 'deletion' although it may also be caused by somatic recombination. Complete loss of an allele can only be reliably and unequivocally measured in tumour DNA samples with very low levels of contamination from non-malignant cells (i.e. <25%). Without microdissection or flow sorting of tumour cells, this cannot be obtained from many primary breast cancer tissues. In addition, allelic imbalance can also be caused by chromosomal aneuploidy (trisomies etc), or low-copy amplification of certain chromosome regions, which is fundamentally different from 'classical' LOH. These factors impede meta-analysis of published allelic imbalance/LOH data in breast cancer, although it is clear that there are chromosome arms where LOH occurs at very high rates.

LOH is interpreted in the light of Knudson's two-hit model for the inactivation of a tumour suppressor gene [679]. Numerous studies have attempted to map common regions of LOH on chromosome arms with frequent LOH. Such a region could flag the position of

a tumour suppressor gene more accurately, aiding its identification.

Tumour suppressor genes

Several chromosome regions showing frequent LOH have been extensively investigated because of the presence of appealing candidate tumour suppressor genes. Many of these regions are supported by CGH and cytogenetic analyses. They include 1p32-36, 3p14-21, 6q25, 7q31, 8p12-21, 9p21, 13q12-q14, 16q22, 16q24, 17p13, 18q21. Several interesting candidate tumour suppressor genes lie in these regions (for example, *FANCA* in 16q24, *HIC1* in 17p13, *PDGFRL* in 8p21, *FHIT* in 3p14, *CDKN2A* in 9p21, *TP73* in 1p36), but their role in breast cancer remains to be established.

By definition, a tumour suppressor gene is a gene whose normal function inhibits the initiation or progression of tumour growth. This can be demonstrated by cell biological, biochemical or genetic evidence, which are not always in full agreement. For example, transfection of the retinoblastoma gene *RB1* into some breast cancer cell lines reverts their tumorigenic phenotype in vitro, yet no inactivating *RB1* mutations have been reported in primary breast tumours. *RASSF1A* is located in the region 3p21, which is frequently deleted in breast cancer. It might serve as a Ras effector, mediating the apoptotic effects of onco-

genic RAS [621]. In breast tumour cell lines, the promoter of *RASSF1A* is highly methylated and its expression is down-regulated [622]. In primary tumours, the proportion with promotor-hypermethylation is lower, and so is the effect on expression down-regulation [42]. No inactivating mutations in the coding regions have been detected, and the relationship between LOH and promotor-methylation status is presently unclear [1368]. To avoid these difficulties in interpreting the available data, we shall restrict ourselves here to those genes for which acquired inactivating mutations in the coding region have been demonstrated in a proportion of primary breast cancers or breast cancer cell lines. Using these criteria, very few tumour suppressor genes have been identified in breast cancer. Listed by chromosomal site, they are:

6q26: *IGF2R*. The *M6P/IGF2R* gene, encoding the insulin-like growth factor II (IGF-II)/mannose 6-phosphate receptor, is frequently inactivated during carcinogenesis. IGF2R is postulated to be a tumour suppressor due to its ability to bind and degrade the mitogen IGF-II, promote activation of the growth inhibitor TGF β , and regulate the targeting of lysosomal enzymes. Several missense mutations in *M6P/IGF2R* disrupt the ligand binding functions of the intact IGF2R. Missense mutations have been found in about 6% of primary breast tumours [1125].

7q31: *ST7* (for suppression of tumorigenicity 7) is a gene with unknown cellular function. Transfection of *ST7* into the prostate-cancer-derived cell line PC3, abrogated its tumorigenicity in vivo. Three breast tumour cell lines harboured frame shifting mutations in *ST7*, which was accompanied by LOH in at least one of them. A role of *ST7* in primary breast cancer has been questioned [358,2912].

8q11: *RB1CC1*. The *RB1CC1* protein is a key regulator of the tumour suppressor gene *RB1*. It is localized in the nucleus and has been proposed to be a transcription factor because of its leucine zipper motif and coiled-coil structure. Seven of 35 (20%) primary breast cancers examined contained mutations in *RB1CC1*, including 9 large interstitial deletions predicted to yield markedly truncated *RB1CC1* proteins [440]. In all 7 cases, both *RB1CC1* alleles were inactivated, and in each case both mutations were acquired somatically.

16q22: *CDH1*. The cell-cell adhesion molecule E-cadherin acts as a strong invasion suppressor in experimental tumour cell systems. Frequent inactivating mutations have been identified in *CDH1* in over 60% of infiltrating lobular breast cancers, but not in ductal carcinomas [261]. Most mutations cause translational frame shifting, and are predicted to yield secreted truncated E-cadherin fragments. Most mutations occur in combination with LOH, so that no E-cadherin expression is detectable immunohistochemically. This offers a molecular explanation for the typical scattered tumour cell growth in infiltrative lobular breast cancer. Lobular carcinoma in situ (LCIS) has also been found to contain *CDH1* mutations [3034].

17p13: *TP53* encodes a nuclear protein of 53 kD, which binds to DNA as a tetramer and is involved in the regulation of transcription and DNA replication. Normal p53 may induce cell cycle arrest or apoptosis, depending on the cellular environment [3147]. Mutations, which inactivate or alter either one of these functions, are found in approximately 20% of breast carcinomas [2237]. Most of these are missense changes in the DNA-binding domain of the protein; a small proportion (~20%) are frame shifting. The large majority of these mutations are accompanied by loss of the wildtype allele (LOH). Missense mutations in *TP53* can be detected immunohistochemically because mutated p53 fails to activate expression of MDM2. The MDM2 protein normally targets p53 for ubiquitin-mediated degradation, constituting a feedback loop to maintain low levels of p53 protein in the cell.

Microsatellite instability

Microsatellite instability (MSI) is a genetic defect caused by mutations in mismatch repair genes (*MLH1*, *MSH2*, *MSH6*, *PMS1*, and *PMS2*), reflected by the presence of multiple alleles at loci consisting of small tandem repeats or mononucleotide runs. MSI in breast cancer is negligible, with the possible exception of breast cancer arising in the context of the HNPCC inherited colon cancer syndrome. The most convincing study is probably that of Anbazhagan et al., who have analysed 267 breast carcinomas at 104 microsatellite loci [85]; not one single case of MSI was detected. Somatic mutations in the mismatch repair

genes have not yet been detected in breast cancer.

Gene expression patterns

Expression profiling is expression-analysis of thousands of genes simultaneously using microarrays [69,1072,1171,2218,2756,3104]. Tumours show great multidimensional variation in gene expression, with many different sets of genes showing independent patterns of variation. These sets of genes relate to biological processes such as proliferation or cell signalling. Despite this variation, there are also striking similarities between tumours, providing new opportunities for tumour classification. ER-positive and ER-negative cancers show distinct expression profiles [1072,2986,3104]. Breast cancers arising in women carrying a *BRCA1* mutation could be distinguished from sporadic cases, and from those that developed in *BRCA2* carriers [1171,2986]. Although this field is still in its infancy, 5 distinct gene expression patterns were discerned among 115 tumours [2218,2756,2757], one basal-like, one ERBB2-overexpressing, two luminal-like, and one normal breast tissue-like subgroup. Approximately 25% of the tumours did not fit any of these classifications. The luminal-like tumours express keratins 8 and 18, and show

strong expression of the estrogen receptor cluster of genes. The tumours of the other groups were mainly ER-negative. The basal-like group is characterized by high expression of keratins 5/6 and 17 and laminin. The ERBB2-group also expresses several other genes in the ERBB2 amplicon, such as *GRB7*. The normal breast-like group shows a high expression of genes characteristic of adipose tissue and other non-epithelial cell types. Cluster analyses of 2 published, independent data sets representing different patient cohorts from different laboratories, uncovered the same breast cancer subtypes [2757].

Somatic genetics of breast cancer metastases

According to the present view, metastasis marks the end in a sequence of genomic changes underlying the progression of an epithelial cell to a lethal cancer. Not surprisingly, therefore, lymph node metastases and distant metastases in general contain more genomic aberrations than their cognate primary tumours [1117,2028]. Flow cytometric DNA content measurements have demonstrated extensive DNA ploidy heterogeneity in primary breast carcinomas, with the concurrent presence of diploid and multiple aneuploid DNA stemlines. Identical het-

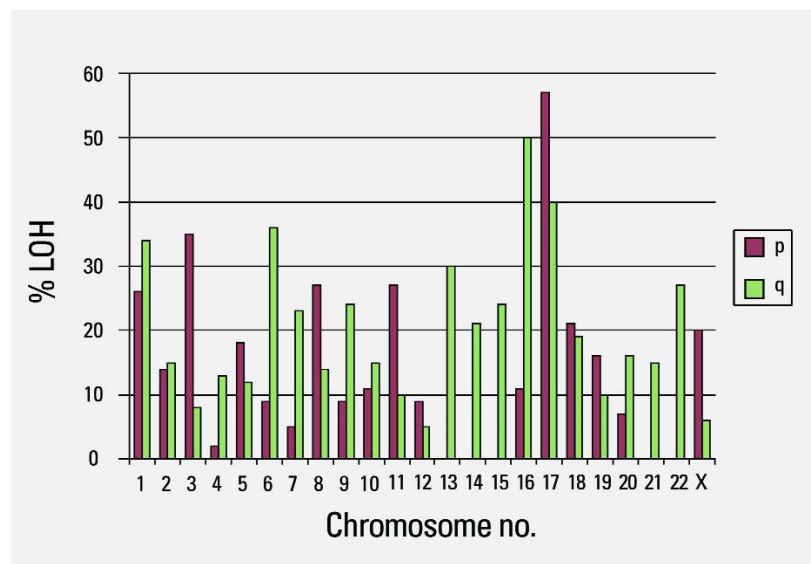


Fig. 1.68 Allelotyping of breast cancer. The percentage LOH is calculated as the ratio between the number of tumours with loss of an allele at a given chromosome arm and the total number of cases informative (i.e. heterozygous) for the analysis. Red bars: p-arm; green bars: q-arm.

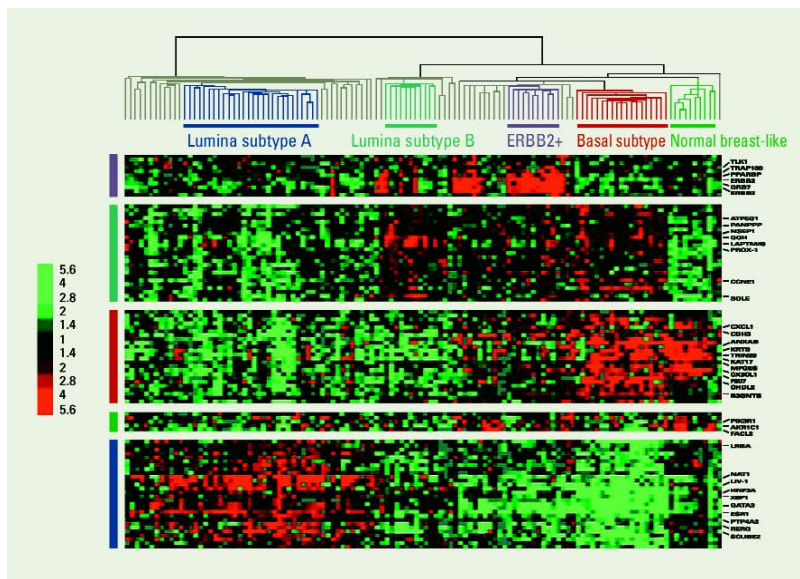


Fig. 1.69 Hierarchical clustering of 115 tumour tissues and 7 nonmalignant tissues using gene expression profiling. Experimental dendrogram showing the clustering of the tumours into five subgroups (top panel). Gene clusters associated with the ERBB2 oncogene, luminal subtype B, basal subtype, normal breast-like group, luminal subtype A with high estrogen receptor expression. Scale bar represents fold change for any given gene relative to the median level of expression across all samples. From T. Sorlie et al. [2757].

erogeneity is often present in their cognate lymph node metastases, suggesting that the generation of DNA ploidy diversity has taken place prior to metastasis [197]. LOH analysis of these DNA ploidy stemlines showed that all allelic imbalances observed in the diploid clones recurred in the cognate aneuploid clones, but were, in the latter, accompanied by additional allelic imbalances at other loci and/or chromosome arms [313]. This indicates that the majority of allelic imbalances in breast carcinomas are established during generation of DNA ploidy diversity. Identical allelic imbalances in both the diploid and aneuploid clones of a tumour suggests linear tumour progression. But the simultaneous presence of early diploid and advanced aneuploid clones in both primary and metastatic tumour sites suggested that acquisition of metastatic propensity can be an early event in the genetic progression of breast cancer. Intriguingly, single disseminated cancer cells have been detected in the bone marrow of 36% of breast cancer patients [339]. Using single-cell CGH, it was demonstrated that disseminated cells from patients without a clinically

detectable distant metastasis displayed significantly fewer chromosomal aberrations than primary tumours or cells from patients with manifest metastasis, and their aberrations appeared to be randomly generated [2560]. In contrast, primary tumours and disseminated cancer cells from patients with manifest metastasis harboured different and characteristic chromosomal imbalances. Thus, contrary to the widely held view that the precursors of metastasis are derived from the most advanced clone within the pri-

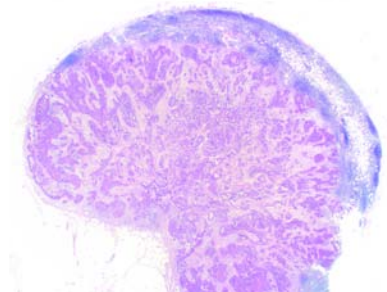


Fig. 1.70 Axillary lymph node. The nodal architecture is destroyed by massive metastatic ductal carcinoma.

mary tumour, these data suggest that breast tumour cells may disseminate in a far less progressed genomic state than previously thought, and that they acquire genomic aberrations typical of metastatic cells thereafter. These findings have two major clinical implications. First, all adjuvant therapies that do not target genetic or epigenetic events occurring early during tumourigenesis are unlikely to eradicate minimal residual disease, because disseminated cancer cells may not uniformly share mutations that are acquired later on. Second, because disseminated cells progress independently from the primary tumour, a simple extrapolation from primary tumour data to disseminated cancer cells is impossible.

Genetic susceptibility: familial risk of breast cancer

Introduction

Breast cancer has been recognized for over 100 years as having a familial component [349]. Epidemiological investigations have attempted to quantify the risks associated with a positive family history and to examine whether the pattern of related individuals is consistent with the effects of a single gene of large effect, shared environmental effects, many genes acting in an additive manner, or most likely, a combination of two or more of these. In addition a number of specific genes have been identified as playing a role. The most important ones are *BRCA1* and *BRCA2* which are discussed in Chapter 8. However, these two genes account for only about a fifth of overall familial breast cancer {107,592,2230} and explain less than half of all high risk, site-specific breast cancer families {898, 2631}.

Familial risk of breast cancer

Virtually every study has found significantly elevated relative risks of breast cancer for female relatives of breast cancer patients. However, the magnitude has varied according to the number and type of affected relatives, age at diagnosis of the proband(s), laterality, and the overall study design. Most studies have found relative risks between 2 and 3 for first-degree relatives selected without regard to age at diagnosis or laterality. A comprehensive study, using the Utah Population Database, of

first-degree relatives of breast cancer probands diagnosed before age 80 estimated a relative risk of 1.8 in the relatives [1029]. When the breast cancer was of early onset (diagnosed before age 50), the relative risk among first-degree relatives increased to 2.6 and the risk for early-onset breast cancer among these relatives was 3.7 (95% CI. 2.8—4.6). The risk to subsequent relatives in families with two affected sisters was increased to 2.7 with a particularly high risk of 4.9 of early onset breast cancer. A second registry-based study in Sweden found essentially identical results to the Utah study [715].

Perhaps the largest population-based study (the Cancer and Steroid Hormone (CASH) case-control study) of probands with breast cancer diagnosed between the ages of 20 and 54 estimated the risk of breast cancer in first-degree relatives compared with controls was 2.1 [501].

A study of cancer at a number of sites in a large set of twins in Scandinavia [1658], estimated the proportion of variance due to genetic (heritability), shared environment, and random (individual-specific) environmental effects for each cancer site. Based on this data, the authors calculated a co-twin relative risk of 2.8 in DZ and 5.2 in MZ twins, and estimated that 27% of breast cancer is due to inherited cause while only 6% could be attributed to shared environment.

The role of other factors with respect to family history has been examined. Larger familial effects among relatives of young bilateral probands compared with young probands with unilateral breast cancer have been found [93,1246,2129]. The relationship of histology to familial breast cancer is less clear [500,2989]. Another feature, which conveys strong familial risk of breast cancer, is the occurrence of breast cancer in a male. It has been estimated that female relatives of probands with male breast cancer have a two-fold to three-fold increased risk of breast cancer [94,2449].

Familial associations of breast and other cancers

A number of studies have found increased risks for other cancers among relatives of breast cancer probands. The most commonly reported are ovarian, uterine, prostate and colon cancers. In

Table 1.10

Estimates of relative risks for breast cancer.

Relative affected, status of proband	Estimate of relative risk	{Reference} (Study Type)
Mother	3.0	{1321a} (a)
Sister	3.0	{1321a} (a)
Mother	2.0	{2214} (a)
Sister	3.0	{2214} (a)
Sister, premenopausal proband	5.0	{92a} (b)
Sister, postmenopausal proband	2.0	{92a} (b)
First-degree relative (FDR)	2.0	{346a} (c)
Sister, bilateral proband	6.0	{2129} (c)
Sister	2.0	{412a} (d)
Mother	2.0	{412a} (d)
First-degree relative (FDR)	2.0	{2556a} (a)
FDR<45, proband<45	3.0	{2556a} (a)
FDR>45, proband>45	1.5	{2556a} (a)
First degree relative	2.1	{501} (c)
First degree relative, proband <55	2.3	{1246} (a)
First degree relative, proband >55	1.6	{1246} (a)
FDR, bilateral proband	6.4	{1246} (a)
First degree relative	2.3	{2720a} (c)
Second degree relative	1.8	{2720a} (c)
First degree relative	1.8	{896} (a)
FDR<50, proband<50	3.7	{896} (a)
FDR, 2 affected probands	2.7	{896} (a)
Mother	1.9	{715} (a)
Sister	2.0	{715} (a)

(a) Ratio of observed frequencies in cancer families to expected frequencies in the general population;
(b) Ratio of observed rate of cancer in relatives of cases to observed rate of cancer in relatives of cases to observed rate of cancer in relatives of selected controls;
(c) Odds ratio from case-control study with non-cancer controls
(d) Relative risk from prospective study.

the Utah Population Database, when risks to all other sites among such probands were examined statistically significant familial associations were found between breast cancer and cancers of the prostate (relative risk = 1.2, $P<0.0001$), colon (1.35, $P<0.0001$), thyroid (1.7, $P<0.001$) and non-Hodgkin lymphoma (1.4, $P<0.001$) [1029]. The Swedish registry study also found a significant familial relationship between breast and prostate cancer of similar magnitude.

Other studies have also shown relationships between breast cancer and ovarian, colon and uterine cancers, although the results have not been consistent across studies [95,1992,2172,2918]. Undoubtedly, the majority of the associa-

tions detected in these population studies is due to the *BRCA1* gene, known to be involved in a large proportion of extended kindreds with clearly inherited susceptibility to breast and ovarian cancer. It is likely that some of the discrepancies in results are linked to the frequency of *BRCA1* deleterious alleles in the respective datasets.

Possible models to explain the familial risk of breast cancer

BRCA1 and *BRCA2* explain only a minority (about 20%) of the overall familial risk of breast cancer although they may contribute much more substantially to the four-fold increased risk at younger ages. Assuming an overall two-fold increased risk among first-degree female relatives

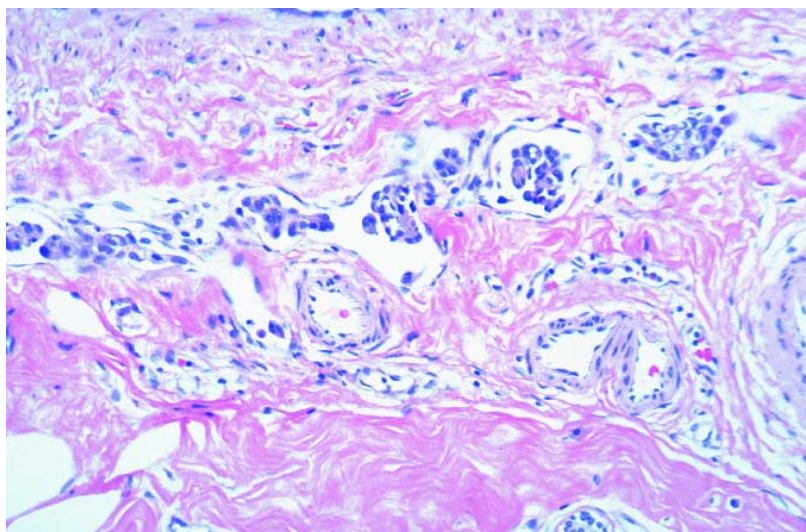


Fig. 1.71 Lymphatic vessel invasion. Several tumour cell nests are present in endothelial lined spaces.

of breast cancer cases and that, as is likely, these genes act in an additive manner with the other loci involved in familial aggregation, then we are left with a residual familial risk of 1.8 to be explained by other genes and/or correlated family environment. There could be several genes similar in action to *BRCA1* and *BRCA2*, with lower breast cancer risks, or a set of more common polymorphisms in biologically relevant genes, each associated with only a small increased risk, or something in-between. Genes are not the only factor which could cause the observed familial correlation. Shared lifestyle or environmental risk factors would also cause some degree of familial clustering, however it can be demonstrated that the known environmental risk factors for breast cancer are unlikely to contribute significantly to the overall familial risk [1238].

Based on a model of the contribution of genetic variation to the overall familial risk, it can be estimated that variation in as few as 70 of the 30,000 genes in the human genome may contribute to breast cancer susceptibility. Of course, this model is based on a number of unverifiable assumptions and does not include potential gene-gene and gene-environment interactions, so should be interpreted cautiously. However, it seems clear that there are not going to be hundreds of loci involved (or if there are, they will be impossible to find given

the weakness of the effects). Only until more of these loci are identified, and their interaction with known epidemiological risk factors assessed, will we be able to untangle the underlying causes of the observed familial risk.

Prognosis and predictive factors

Clinical features

Age

The prognostic significance of age and menopausal status in patients with breast carcinoma is controversial. Younger patients have been found to have a poor prognosis [59,2029], a favourable outcome [2500] or no correlation has been found with age at all [1207]. These discrepancies may be due to differences in patient selection, age grouping, and other factors, including high grade, vascular invasion, extensive in situ component, steroid receptor negativity, high proliferation, *TP53* abnormalities. An increased incidence of node positivity was found in two large studies of patients under 35 years.

Pregnancy

Breast cancer developing during pregnancy is generally considered to have an unfavourable prognosis. There is, however, conflicting data as to whether this is an independent factor. It may be partly, or entirely, due to the poor prognosis associated with young age and also the fact that the cancer is often

detected at a late stage as small tumours are not felt in the pregnant or lactating breast [91,311,1079]. Pregnancy in women who have been treated for breast cancer does not appear to affect prognosis [119].

Morphological factors

The traditional pathological factors of lymph node status, tumour size, histological type, and histological grade are the most useful prognostic factors in breast cancer patients [886,1763], although this is now challenged by gene expression profiling.

Lymph node status

The status of the axillary lymph nodes is the most important single prognostic factor for patients with breast cancer. Numerous studies have shown that disease-free and overall survival rates decrease as the number of positive nodes increases [886]. The clinical significance of micrometastases and isolated tumour cells in the nodes, particularly those identified exclusively by immunohistochemistry, remains a matter of debate [71,1655] although virtually all studies with more than 100 patients have shown that micrometastases are associated with a small but significant decrease in disease-free and/or overall survival [1655].

Approximately 10-20% of patients considered to be node-negative by routine pathological examination have identifiable tumour cells as determined by serial sectioning, immunohistochemical staining for epithelial markers, or both. However, at present, it appears premature to recommend the routine use of step sections and/or immunohistochemistry to evaluate sentinel or non-sentinel lymph nodes [71].

Tumour size

Tumour size is an important prognostic factor. Even among patients with breast cancers 1 cm and smaller (T1a and T1b), size is an important prognostic factor for axillary lymph node involvement and outcome [461]. However, the manner in which the pathological tumour size is reported varies. Some pathologists report the macroscopic size, some a microscopic size that includes both the invasive and in situ components, and others report the microscopic size of the invasive compo-

nent only. There is often poor correlation between the tumour size determined by gross pathological examination and the size of the invasive component as determined by histological measurement [27]. The size of the invasive component is clinically significant, and so the pathological tumour size for classification (pT) is a measurement of only the invasive component [51]. Therefore, when there is a discrepancy between the gross and the microscopic size of the invasive component, the microscopic size takes precedence, and should be indicated in the pathology report and used for pathological staging.

Histological type

Some special histological types of breast cancer are associated with a particularly favourable clinical outcome [771,2433]. These include tubular, invasive cribriform, mucinous, and adenoid cystic carcinomas. Some authors also include tubulolobular and papillary carcinomas. The 20-year recurrence-free survival of special type tumours 1.1 to 3.0 cm in size is similar to that of invasive ductal carcinomas of no special type 1 cm and smaller (87% and 86%, respectively) [2433]. The prognostic significance of medullary carcinoma remains controversial and is discussed elsewhere (see medullary carcinoma).

Histological grade

Grading is recommended for all invasive carcinomas of the breast, regardless of morphological type [1984, 2216,2905]. This practice has been criticized by some pathologists who feel that grading is not appropriate for the special histological types such as pure tubular, invasive cribriform, mucinous, medullary and infiltrating lobular carcinomas. For example, most infiltrating lobular carcinomas, especially those of classical subtype, are assessed as grade 2 and the overall survival curve of lobular carcinoma overlies that of all other types of grade 2 carcinoma. In mucinous carcinoma and in carcinoma of mixed morphological type, grading provides a more appropriate estimate of prognosis than type alone [2216]. In medullary carcinoma no additional prognostic value has been found. Higher rates of distant metastasis and poorer survival are seen in patients with higher grade (poorly differentiated) tu-

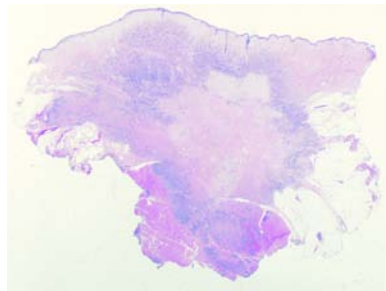


Fig. 1.72 Carcinoma with central fibrosis. There is extensive central fibrosis with only a rim of invasive carcinoma left around the fibrotic area.

mours, independent of lymph node status and tumour size [550,777,836, 868,886,1031,1763,2030,2434]. Tumour grading has prognostic value even in breast cancers 1 cm and smaller [461]. The optimal grading method [777] has been detailed earlier in this chapter. The combination of histological type and grade provides a more accurate assessment of prognosis than does histological type alone [2216].

Histological grade may also provide useful information with regard to response to chemotherapy and, therefore, be a predictive factor as well as a prognostic indicator. Several studies have suggested that high histological grade is associated with a better response to certain chemotherapy regimens than low histological grade [2254]. However, additional studies are required to define this relationship more clearly [612].

Tumour cell proliferation

Markers of proliferation have been extensively investigated to evaluate prognosis [886,1304]. Mitotic count is part of histological grading. Other methods include DNA flow cytometry measurement of S-phase fraction (SPF). Many studies indicate that high SPF is associated with inferior outcome.

Ki-67/MIB-1 is a labile, non-histone nuclear protein detected in the G1 through M phases of the cell cycle, but not in resting cells and is therefore a direct indicator of the growth fraction. The percentage of Ki-67 positive cells can be used to stratify patients into good and poor survivors. Quantitative RT-PCR in detecting the mRNA level has also been introduced as well as array based quantification of proliferation (see below).

Lymphatic and blood vessel invasion

Lymphatic vessel invasion has been shown to be an important and independent prognostic factor, particularly in patients with T1, node-negative breast cancers [461,1606,1623, 2433,2445,2452]. Its major value is in identifying patients at increased risk of axillary lymph node involvement [627,839,1592,2253,2415] and adverse outcome [186a,627,1623, 2415,2434]. As with histological grade, the ability of pathologists to reproducibly identify lymphatic vessel invasion has been challenged [998] but can be improved if stringent criteria are employed [627,2109,2253,2415, 2452]. Lymphatic vessel invasion must be distinguished from tumour cell nests within artifactual tissue spaces created by shrinkage or retraction of the stroma during tissue processing.

Blood vessel invasion has been reported to have an adverse effect on clinical outcome. However, there is a broad range in the reported incidence, from under 5% to almost 50% [1470,1592, 2444,2445,2452, 3083]. This is due to a variety of factors including the patient population, the criteria and methodology used, and difficulty in identifying blood vessels.

Perineural invasion

Perineural invasion is sometimes observed in invasive breast cancers, but it has not been shown to be an independent prognostic factor [2426].

Tumour necrosis

In most studies [2452], the presence of necrosis has been associated with an adverse effect on clinical outcome [414, 877,999,2175], although in one, necrosis was associated with a worse prognosis only within the first two years after diagnosis [999].

Inflammatory cell infiltrates

The presence of a prominent mononuclear cell infiltrate has been correlated in some studies with high histological grade [2030]. However, the prognostic significance of this finding is controversial, with some studies noting an adverse effect on clinical outcome [67,286,2785] and others observing either no significant effect or a beneficial effect [635,1601,2445,2785].

Extent of ductal carcinoma in situ

The presence of an extensive intraductal component is a prognostic factor for local recurrence in patients treated with conservative surgery and radiation therapy, when the status of the excision margins is unknown. However, this is not an independent predictor when the microscopic margin status is taken into consideration [2569]. Its relationship with metastatic spread and patient survival remains unclear [2176,2437,2689].

Tumour stroma

Prominent stromal elastosis has variously been reported to be associated with a favourable prognosis [2664,2858], an unfavourable prognosis [84,1016], and to have no prognostic significance [626,1266,2393]. The presence of a fibrotic focus in the centre of an invasive carcinoma has also been reported to be an independent adverse prognostic indicator [545,1153].

Combined morphologic prognostic factors

The best way to integrate histological prognostic factors is an unresolved issue [1833]. The Nottingham Prognostic Index takes into consideration tumour size, lymph node status and histological grade, and stratifies patients into good, moderate and poor prognostic groups with annual mortality rates of 3%, 7%, and 30%, respectively [954]. Another proposal for a prognostic index includes tumour size, lymph node status and mitotic index (morphometric prognostic index) [2993].

Molecular markers and gene expression

A large number of genetic alterations have been identified in invasive breast carcinomas, many of which are of potential prognostic or predictive value. Some provide treatment-independent information on patient survival, others predict the likelihood that a patient will benefit from a certain therapy. Some alterations may have both prognostic and predictive value.

Steroid hormone receptors (Estrogen receptor (ER) and Progesterone receptor PR)

Estrogen is an important mitogen exerting its activity by binding to its receptor (ER). Approximately 60% of breast carcinomas express the ER protein. Initially,

ER-positive tumours were associated with an improved prognosis, but studies with long-term follow-up have suggested that ER-positive tumours, despite having a slower growth rate, do not have a lower metastatic potential. Nonetheless, ER status remains very useful in predicting the response to adjuvant tamoxifen [4,368,1304,1833,2120]. Measurement of both ER and PR has been clinical practice for more than 20 years. PR is a surrogate marker of a functional ER. In estrogen target tissues, estrogen treatment induces PR. Both can be detected by ligand binding assay, or more commonly nowadays, by immunohistochemical (IHC) analysis using monoclonal antibodies. ER/PR-positive tumours have a 60-70% response rate compared to less than 10% for ER/PR-negative tumours. ER-positive/PR-negative tumours have an intermediate response of approximately 40%. Hormone receptor status is the only recommended molecular marker to be used in treatment decision [9,886,1030]. The impact of hormone receptor status on prognosis and treatment outcome prediction is complex. The finding, in cell lines, that tamoxifen can interact with the recently identified ER receptor (ERB) may provide new clues towards improvement of predicting tamoxifen responsiveness [1526,1925,3269]. Epidermal growth factor receptor (EGFR) and transforming growth factor alpha (TGF α), antiapoptotic protein bcl-2, cyclin dependent kinase inhibitor p27 are other potential prognostic markers that look promising. Elevated expression of EGFR, in the absence of gene amplification, has been associated with estrogen receptor negativity [2509].

The ERBB2 / HER2 oncogene

The prognostic value of ERBB2 over-expression, first reported in 1987 [2719], has been extensively studied [2962,3173]. ERBB2 over-expression is a weak to moderately independent predictor of survival, at least for node-positive patients. Gene amplification or over-expression of the ERBB2 protein can be measured by Southern blot analysis, FISH, differential PCR, IHC and ELISA [2958]. Studies of the predictive value of ERBB2-status have not been consistent. A recent review [3173] concluded that ERBB2 seems to be a weak to moderately strong negative

predictor for response to alkylating agents and a moderately positive predictive factor for response to anthracyclines. There was insufficient data to draw conclusions on the response to taxanes or radiotherapy. In an adjuvant setting, ERBB2 status should not be used to select adjuvant systemic chemotherapy or endocrine therapy. Conversely, when adjuvant chemotherapy is recommended, anthracycline-based therapy should be preferred for ERBB2 positive patients. A humanized anti-ERBB2 monoclonal antibody, trastuzumab (Herceptin), has been developed as a novel anti-cancer drug targeting overexpressed ERBB2 [529]. This has been shown to be effective in 20% of patients with ERBB2 amplified tumours.

TP53 mutations

Approximately 25% of breast cancers have mutations in the tumour suppressor gene *TP53*, most of which are missense mutations leading to the accumulation of a stable, but inactive protein in the tumour cells [1196,2759,2761]. Both DNA sequencing and IHC have been used to assess *TP53*-status in the tumour. However, some 20% of the mutations do not yield a stable protein and are thus not detected by IHC, while normal (wildtype) protein may accumulate in response to DNA damage or cellular stress signals. Studies using DNA sequencing all showed a strong association with survival whereas those using only IHC did not, or did so only weakly [5,886,1304,2237,2760]. Given the diverse cellular functions of the p53 protein and the location and type of alteration within the gene, specific mutations might conceivably be associated with a particularly poor prognosis. Patients with mutations in their tumours affecting the L2/L3 domain of the p53 protein, which is important for DNA binding, have a particularly poor survival [251,317,976,1523].

The role of p53 in the control of the cell cycle, DNA damage repair, and apoptosis, provides a strong biological rationale for investigating whether mutations are predictors of response to DNA damaging agents. Several studies using DNA sequencing of the entire gene have addressed this in relation to different chemotherapy and radiotherapy regimes [16,241,249,976]. A strong

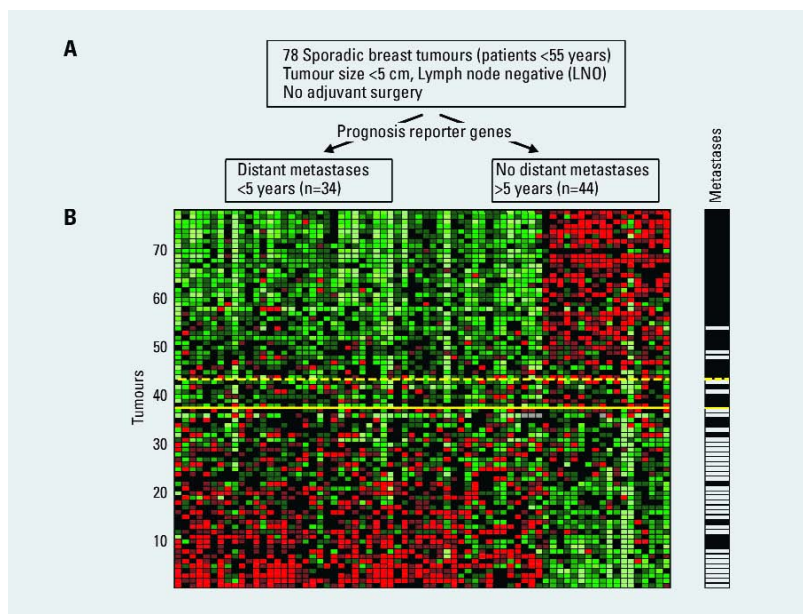


Fig. 1.73 **A** Supervised classification on prognosis signatures, using a set of prognostic reporter genes to identify optimally two types of disease outcome from 78 sporadic breast tumours into a poor prognosis and good prognosis group. **B** Each row represents a tumour and each column a gene. Genes are ordered according to their correlation coefficient with the two prognostic groups. Tumours are ordered by the correlation to the average profile of the good prognosis group. Solid line, prognostic classifier with optimal accuracy; dashed line, with optimized sensitivity. Above the dashed line patients have a good prognosis signature, below the dashed line the prognosis signature is poor. The metastasis status for each patient is shown in the right panel: white indicates patients who developed distant metastases within 5 years after the primary diagnosis; black indicates patients who continued to be disease-free for at least 5 years. From L.J. van't Veer et al. [2986].

association between specific mutations and short survival and poor response to treatment was seen, emphasizing the importance of DNA sequence analysis of the entire coding region of *TP53* when evaluating its prognostic and predictive value.

Loss of heterozygosity (LOH)

LOH at the *TP53* gene has been shown to be a marker for prognosis and predictor of response to certain therapies (see above). Other regions with LOH that appear to correlate to short survival include 11q23 and several regions on 3p [1216,1552]. Deletion of 9q13 is also associated with shorter survival. The target gene(s) in these areas have still to be identified [1326].

DNA amplification

Conventional as well as array-based CGH have identified a number of amplified regions containing putative oncogenes with prognostic potential. Ampli-

fication of the *FGFR1* gene on 8p12 has been correlated with reduced disease-free survival, especially if the gene is amplified together with the cyclin D1 gene [596]. The *MYC* gene on 8q24 is amplified in approximately 20% of breast carcinomas, which is associated with estrogen receptor negativity [596], locally advanced disease and poor prognosis [250]. On 11q13, cyclin D1 (*CCND1*) is amplified in 15-20% of breast tumours. In ER-positive tumours, *CCND1* amplification is associated with a relatively poor prognosis [596,2582], and is more frequent in lobular carcinomas compared to ductal carcinomas.

Expression profiling

Much recent work has been focused on the potential of gene expression profiles to predict the clinical outcome of breast cancer [257,1257,2328,2757,2986,2990]. These studies, although heterogeneous in patient selection and numbers of tumours analysed, have indi-

cated that gene expression patterns can be identified that associate with lymph node or distant metastasis, and that are capable of predicting disease course in individual patients with high accuracies (circa 90%). In the largest study to date [2990], analysing 295 tumours, the expression profile was a strong independent factor and outcompeted lymph node status as a predictor of outcome. These findings suggest that some primary tumours express a "metastasis signature", which is difficult to reconcile with the classic tumour progression model in which a rare subpopulation of tumour cells have accumulated the numerous alterations required for metastasis to occur. Interestingly, some of the genes in the signature seem to be derived from non-epithelial components of the tumour [2328], suggesting that stromal elements represent an important contributing factor to the metastatic phenotype. Survival differences were also noted between the different subtypes of breast tumours as defined by expression patterns [2756,2757]. The patients with basal-like and ERBB2+ subtypes were associated with the shortest survival, while a difference in the outcome for tumours classified as luminal A versus luminal B was also evident. The luminal subtype B may represent a class of ER-positive tumours with poor outcome, possibly not responding to tamoxifen. This strongly supports the idea that many of these breast tumour subtypes represent biologically distinct disease entities with different clinical outcome.

A remarkable feature of the expression signatures identified in these studies is that they usually involve fewer than 100 genes [257,2986], in one instance even only 17 genes [2328]. However, somewhat confusing is that the overlap between the different sets of genes thus defined is incomplete [1257,2757]. Further comparative studies are required to elucidate the critical components of the poor prognosis signature, while the clinical utility of this new diagnostic tool must now be demonstrated in a prospective trial setting. At a more fundamental level, it will be interesting to establish whether the observed association between expression signatures and survival reflects an intrinsic biological behaviour of breast tumour cells or a differential response to therapy.

Benign epithelial proliferations

G. Bussolati
F.A. Tavassoli
B.B. Nielsen
I.O. Ellis
G. MacGrogan

Localization

There is little data on location or laterality of most benign breast lesions. As with carcinoma, the majority arise within the terminal duct lobular unit (TDLU). A major exception is the benign solitary intraductal papilloma, approximately 90% of which occurs in the large ducts in the central region of the breast [1098]. Other benign lesions specific to the nipple areolar complex include nipple adenoma and syringoma and are discussed in the chapter on nipple.

Clinical features

The predominant presenting symptoms in women attending a breast clinic are described in the section on Invasive Carcinoma, where signs and symptoms most likely to be associated with a low risk of malignancy are described. The frequency of benign conditions varies considerably with the age of the patient. Fibroadenoma is most frequent in younger patients, other localized benign lesions and cysts occur most frequently in women between the ages of 30 and 50. This contrasts with carcinoma, which is rare below the age of 40. The mammographic appearances of benign epithelial lesions are varied but common lesions such as cysts are typically seen as well defined or lobulated mass lesions. Calcification is also a common feature of fibrocystic change and sclerosing adenosis. Other benign lesions such as radial scar, complex sclerosing lesion and fat necrosis can produce ill defined or spiculate mass lesions, which are indistinguishable from some forms of breast carcinoma.

Adenosis

Definition

A frequent, benign, proliferative process that affects mainly the lobular (acinar) component of the breast parenchyma. It can be accompanied by fibrosis causing considerable distortion of the glands simulating an invasive process.

Frequently it is a small and microscopic change, but it may be widespread. In some instances, it may form a palpable mass and has been called nodular adenosis or adenosis tumour. Several histological types have been described, but there is not complete agreement on their designation. Only the most frequent variants are discussed.

Radial scar/complex sclerosing lesion which incorporates a combination of benign changes including adenosis is also included in this section.

Epidemiology

This lesion occurs most frequently in women in their third and fourth decade.

Macroscopy

Adenosis may be non-distinctive, showing unremarkable fibrous or cystic breast tissue. A few cases assume the appearance of a firm rubbery grey mass.

Histopathology

Adenosis in its simplest form is characterized by a usually loosely structured proliferation of acinar or tubular structures, composed of an epithelial and myoepithelial cell layer and surrounded by a basement membrane.

Sclerosing adenosis

Sclerosing adenosis (SA) is characterized by a compact proliferation of acini with preservation of the luminal epithelial and the peripheral myoepithelial (ME) cell layers along with a surrounding basement membrane. These elements can easily be demonstrated by immunohistochemical staining for keratin, smooth-muscle actin and laminin, respectively. Although compression or attenuation of the acini by surrounding fibrosis may be marked, sclerosing adenosis nearly always retains an organic or lobulated configuration often best observed at low power view. Microcalcifications are common within

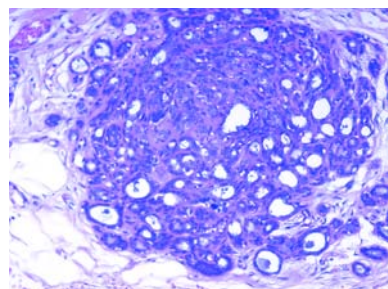


Fig. 1.107 Sclerosing adenosis. Typical organic configuration of the lesion.

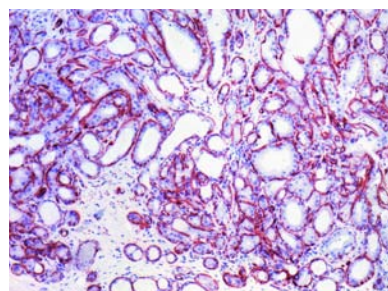


Fig. 1.108 Sclerosing adenosis. The myoepithelial cells are prominent with immunostain for smooth muscle actin.

the glands. Areas of apocrine metaplasia are also common. Rarely neural invasion is encountered and vascular invasion has been reported [149]. Lesions which form a mass show adenosis with a mixture of growth patterns [2015], the most frequent of which is sclerosing adenosis.

In rare cases sclerosing adenosis may be involved by DCIS or LIN [1046, 1275a, 1846a, 2015, 2336a, 3104a].

Differential diagnosis

Sclerosing adenosis can mimic invasive carcinoma. The overall lobulated architecture, persistence of ME cells, and lack of epithelial atypia help to exclude carcinoma [321, 1046]. In cases involved by in situ carcinoma, the immunohistochemical demonstration of persistent myoepithelial cells is crucial in excluding invasion.

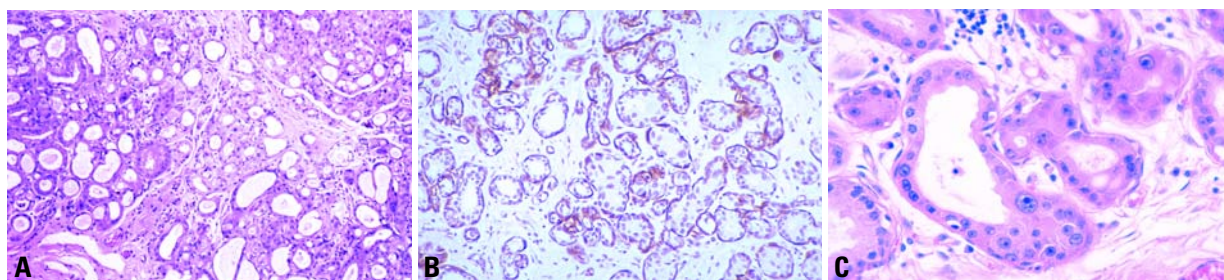


Fig. 1.109 **A** Apocrine adenosis/sclerosing adenosis with apocrine metaplasia and focal atypia. **B** Immunostain for actin demonstrating myoepithelial cells around the tubules. **C** Typical apocrine metaplasia in sclerosing adenosis, characterized by a three-fold nuclear size variation.

Apocrine adenosis

Synonym

Adenosis with apocrine metaplasia.

Apocrine adenosis (AA) is an ambiguous term, as it has been used for several different lesions [805,2698,2699]. In this context, it is used for adenosis, particularly sclerosing adenosis, with widespread apocrine metaplasia constituting at least 50% of the adenotic area [3093]. The apocrine epithelium may exhibit cytological atypia, so that the histological appearance mimics invasive carcinoma [2621,2698,2699].

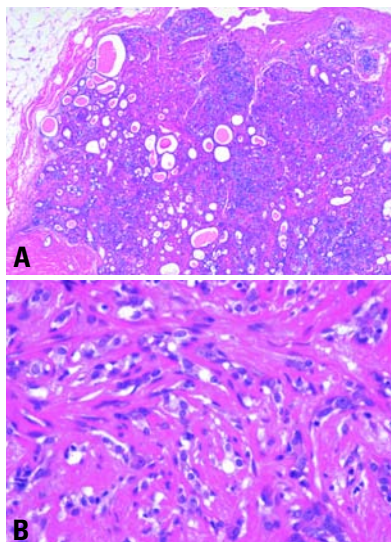


Fig. 1.110 **A** Nodular sclerosing adenosis. Note the well delineated margins. **B** High power view of the lesion in A, showing distorted and compressed tubular structures and intervening hyaline stroma. Such lesions may pose difficulties in the differential diagnosis to invasive lobular carcinoma.

Blunt duct adenosis

The term blunt duct adenosis (BDA) has been used for an organoid microscopic form of adenosis with variable distension of lumens showing columnar cell metaplasia [2015].

Microglandular adenosis

Microglandular adenosis (MGA) is a rare lesion, characterized by a diffuse haphazard proliferation of small round glands [507,692,2413,2884]. These may be clustered, but without sclerosis or compression [507,3081]. The surrounding collagenous stroma may be hypocellular or hyalinized. There is no elastosis. The glands have a round lumen, which frequently contains periodic acid-Schiff (PAS) positive, eosinophilic secretory material. The epithelium is cuboid and without snouts. The cytoplasm may be clear or eosinophilic and granular. There is no nuclear atypia. There are no myoepithelial cells [184,321,797,2884], but a surrounding basement membrane, not always recognizable without immunohistochemical staining for laminin or collagen IV [692,2884, 3081], is present. Electron microscopy shows a multilayered basement membrane surrounding the tubules of MGA [2884].

The epithelium of MGA is positive for S-100 in addition to cytokeratin [1372]. When carcinoma arises in association with MGA it may retain an alveolar pattern [1331] or be of ductal or one of the special types [2016]; the vast majority of these invasive carcinomas retain S-100 immunoreactivity regardless of their subtype [1484].

Adenomyoepithelial adenosis

Adenomyoepithelial adenosis (AMEA) is an extremely rare type of adenosis, which seems to be associated with adenomyoepithelioma [803,805,1454] (see section on adenomyoepithelial lesions).

Prognosis and predictive factors of adenosis

Most types of adenosis are not associated with increased risk of subsequent carcinoma. However, there are exceptions, as nearly one third of cases of MGA harbour an invasive carcinoma [803,1454], and apocrine adenosis has been found to be monoclonal and perhaps a putative precancerous lesion [3093].

Radial scar / Complex sclerosing lesion

Definition

A benign lesion that on imaging, grossly and at low power microscopy resembles invasive carcinoma because the lobular architecture is distorted by the sclerosing process. The term radial scar (RS) has been applied to small lesions and com-

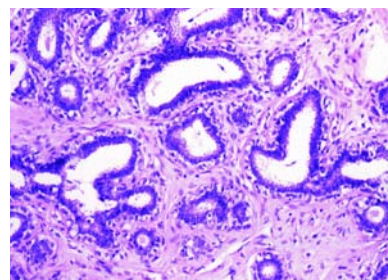


Fig. 1.111 Blunt duct adenosis, typical morphology.

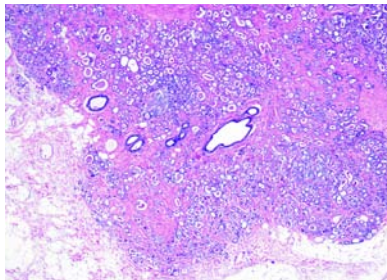


Fig. 1.112 Microglandular adenosis. An extensive lesion that presented as a palpable mass; the characteristic open lumens of the tubules and the colloid-like secretory material are apparent, providing clues to the nature of the process.

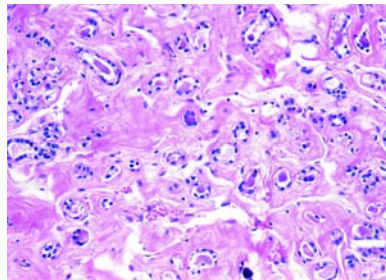


Fig. 1.113 Microglandular adenosis with diffusely arranged small uniform glands, separated by a densely collagenous background.

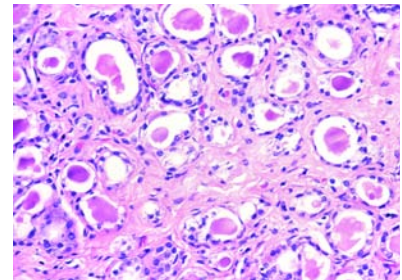


Fig. 1.114 Microglandular adenosis. The tubules are lined by a single layer of attenuated cuboidal epithelial cells with vacuolated cytoplasm; colloid-like secretory material is present within the lumen.

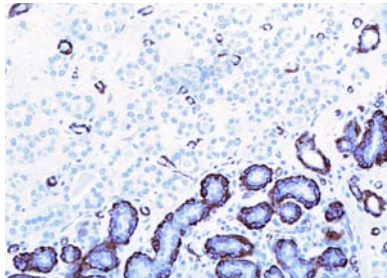


Fig. 1.115 Microglandular adenosis. Immunostain for smooth muscle actin confirms absence of a myoepithelial cell layer in MGA; the adjacent TDLUs show actin-positive myoepithelial cells.

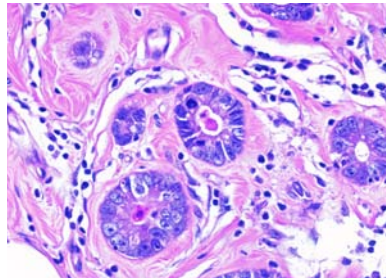


Fig. 1.116 Microglandular adenosis with atypia. There is diminished intraluminal colloid-like secretion, enlarged cells displaying mild to moderate nuclear pleomorphism and mitotic figures.

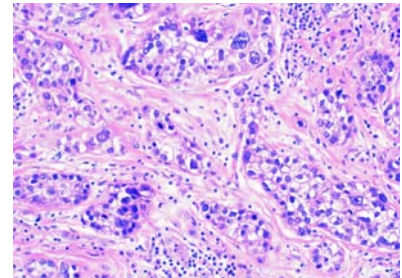


Fig. 1.117 Ductal carcinoma in situ arising in microglandular adenosis. Note the significant atypia of the cells proliferating within the obliterated tubules.

plex sclerosing lesion (CSL) to larger ones that contain a variety of ductal epithelial hyperplasia along with sclerosis.

Synonyms

Radial scar, sclerosing papillary lesion, radial sclerosing lesion, scleroelastotic scar, stellate scar, benign sclerosing ductal proliferation, non-encapsulated sclerosing lesion, infiltrating epitheliosis.

Epidemiology

The reported incidence varies depending on the mode of detection and how detected by mammography when the appearance mimics that of an infiltrating carcinoma producing an irregular stellate density. Very occasionally they are of sufficient size to produce a palpable mass [2725]. They are often multiple and frequently bilateral.

Macroscopy

These lesions may be undetected on gross examination or may be of sufficient size to produce an irregular area of firmness which can exhibit yellow streaks

reflecting the elastotic stroma. The appearance may be indistinguishable from that of a carcinoma.

Histopathology

RSs are composed of a mixture of benign changes of which adenosis forms a major part. They have a stellate outline with central dense hyalinized collagen and sometimes marked elastosis. Entrapped in the scar are small irregular tubules. The two cell layer is usually retained although this may not always be visible on haematoxylin and eosin staining and the myoepithelial layer is occasionally inapparent. The tubules sometimes contain eosinophilic secretions. Around the periphery of the lesion there are various degrees of ductal dilatation, ductal epithelial hyperplasia, apocrine metaplasia and hyperplasia. In the more complex larger CSLs, several of these lesions appear to combine and then converge with prominent areas of sclerosing adenosis, and small, frequently sclerosing, peripheral papillomas and various patterns of intraepithelial proliferation.

Differential diagnosis

Distinction from carcinoma depends on the characteristic architecture of a CSL, the lack of cytological atypia, the presence of a myoepithelial layer (in most cases) and basement membrane around the tubular structures (demonstration by immunohistochemistry may be necessary), the presence of a dense hyalinized stroma and lack of a reactive fibroblastic stroma.

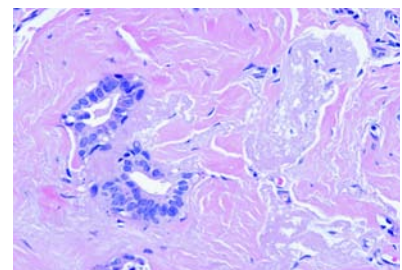


Fig. 1.118 Radial scar. Centre of a radial scar with two tubular structures, surrounded by hyalinized and elastotic tissue. Note the atrophic myoepithelial layer.




Fig. 1.119 Sclerosing adenosis with a radial scar.

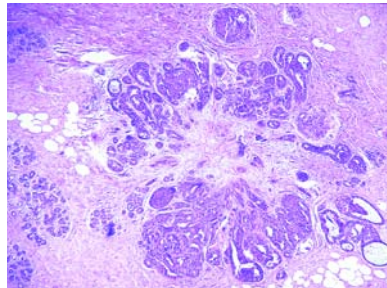


Fig. 1.120 Radial scar. A central fibrous scar is surrounded by epithelial proliferation.

Prognosis and predictive factors

It has been suggested that these lesions are pre-neoplastic or even represent early invasive carcinomas [1668] and also that they may represent a marker of risk for the subsequent development of carcinoma. Follow up studies, however, have been few and contradictory [843,1320] suggesting that an apparent risk is related to the various patterns of associated intra-ductal hyperplasia. It is doubtful that, without epithelial proliferation, there is a risk of the subsequent development of invasive carcinoma. In larger lesions the risk may be slightly higher as the increase in size is usually due to various forms of epithelial hyperplasia. A high incidence of atypical hyperplasia and carcinoma (both in situ and invasive) has been reported in CSLs detected by mammography, particularly in lesions measuring over 0.6 cm, and in women over 50 years old [719,2725].

Tubular adenoma

Definition

Benign, usually round, nodules formed by a compact proliferation of tubular structures composed of the typical epithelial and myoepithelial cell layers. The epithelial cells are similar to those of the normal resting breast, but adenoma variants have been described where these show apocrine or lactating features.

ICD-O code 8211/0

Epidemiology

Tubular adenomas occur mainly in young females [1202,1211,1919,2074]. They rarely occur before menarche or after menopause [1600,2025]. They reportedly account for 0.13 to 1.7% of benign breast lesions [1202,1211,2874]. Patients with lactating adenomas are nursing mothers who have noted an area of increased firmness, either during lactation or, earlier, during pregnancy.

Clinical features

The clinical and imaging features are usually those of fibroadenoma.

Macroscopy

The tumours are firm, well circumscribed and homogeneous with a uniform, yellowish, cut surface.

Histopathology

The lesion is composed entirely of small, round tubules with little intervening stroma. The latter may contain a few lymphocytes. The epithelial cells are uniform, Mitotic activity is usually low. The tubular lumen is small and often empty, but eosinophilic proteinaceous material can be present. Occasional larger tubules give rise to thin branches. Combined tubular adenoma and fibroadenoma has been described [1202,2874]. Rare cases have been described of in situ and/or invasive carcinoma involving adenomas (tubular or lactating) [561,1202,1211,2442], a phenomenon also known to occur in fibroadenomas.

Lactating adenoma

ICD-O code 8204/0

During pregnancy and lactation, the epithelial cells of a tubular type adenoma may show extensive secretory changes warranting a designation of lactating adenoma [1332,2074]. It has been suggested that such lesions represent focal accumulation of hyperplastic lobules.

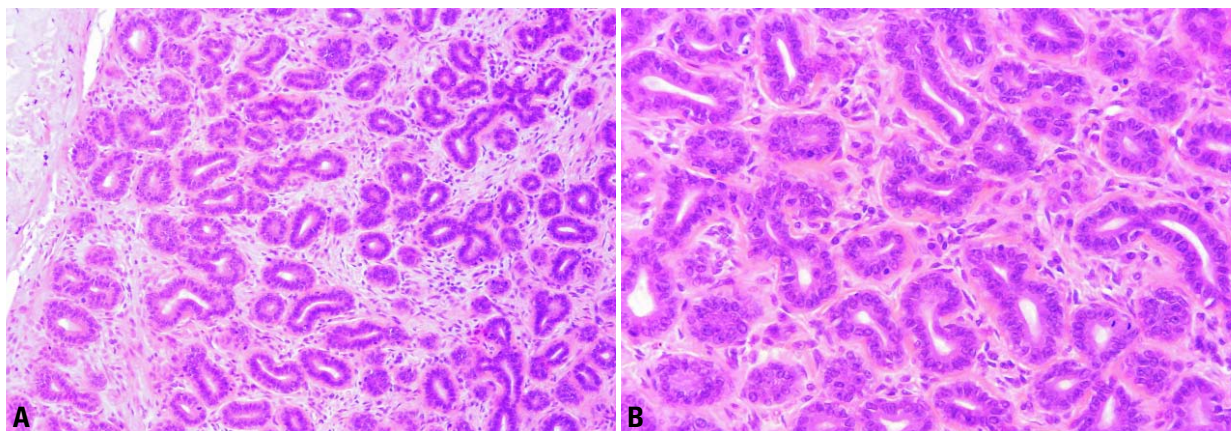


Fig. 1.121 Tubular adenoma. **A** The fibrous capsule is present in the left upper corner. **B** Higher magnification displays epithelial and myoepithelial cell lining of the tubules.

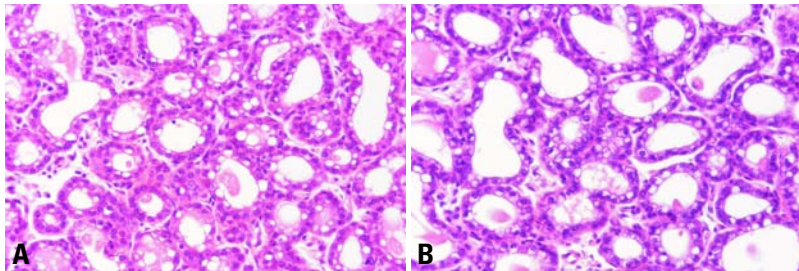


Fig. 1.122 Lactating adenoma. Epithelial cells show extensive secretory changes (A, B).

Apocrine adenoma

ICD-O code 8401/0

Synonym

Nodular adenosis with apocrine metaplasia.

Sometimes the epithelial cells of nodular adenosis show extensive apocrine metaplasia; these lesions may be termed apocrine adenoma [561,1713,2442].

Immunoprofile

The immunophenotype of adenomas is similar to normal breast and reflects the various metaplastic and/or secretory changes affecting them.

Differential diagnosis

Differentiation of adenomas from fibroadenomas is based on the prominent proliferating stromal component and the often elongated and compressed epithelial elements in the intracanalicular variant of the latter.

Pleomorphic adenoma

Definition

A rare lesion morphologically similar to pleomorphic adenoma (benign mixed tumour) of the salivary glands.

ICD-O code 8940/0

Epidemiology

These lesions have been reported in patients (mainly females) over a wide range of age [172,454]. Multiple tumours have been described [454,2874]. Calcification is common and gives a diagnostically important sign on mammography.

Histopathology

The histological picture is the same as that seen in pleomorphic adenomas of

salivary glands. Some authors [2442, 2730,2753] consider pleomorphic adenoma to be a form of intraductal papilloma with extensive cartilaginous metaplasia. Because of the presence of a chondroid stromal component, pleomorphic adenomas pose a difficult differential diagnosis from metaplastic carcinomas with a mesenchymal component and primary sarcomas of the breast. The presence of foci of intraductal or invasive carcinoma points to the diagnosis of metaplastic carcinoma, while extensive cellular anaplasia characterizes sarcomas.

Ductal adenoma

Definition

A well circumscribed benign glandular proliferation located, at least in part, within a duct lumen [151].

ICD-O code 8503/0

Synonym

Sclerosing papilloma.

Epidemiology

These lesions occur over a wide age range but are most frequent in women over 40 years [151,1577]. It is debatable whether these lesions represent the sclerotic evolution of an intraductal papilloma or are a distinct entity.

Clinical features

They may present as a mass or rarely as a nipple discharge. Imaging shows a density which can mimic a carcinoma.

Histopathology

Arranged mainly at the periphery are glandular structures with typical dual cell layer while in the centre there is dense scar-like fibrosis. The compact

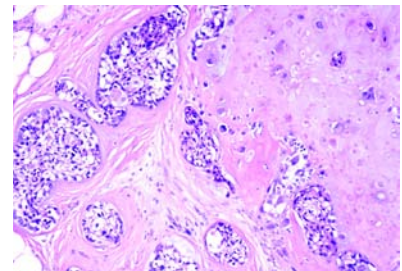


Fig. 1.123 Pleomorphic adenoma. Nests of clear myoepithelial cells proliferate around few, barely apparent darker epithelial cells; abundant cartilage is present on the right.

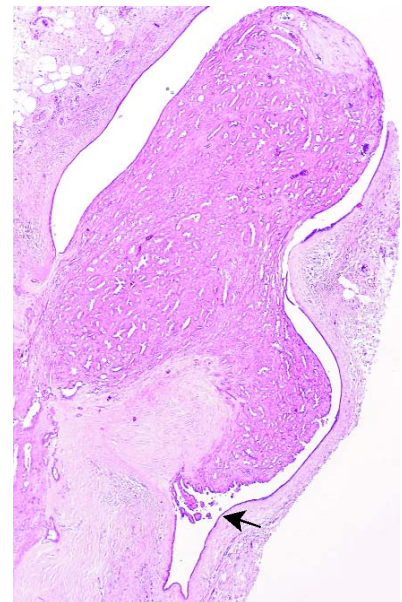


Fig. 1.124 Ductal adenoma, characterized by a "polypoid" protrusion into a distended duct; a few papillary projections are evident (arrow).

proliferating tubules, compressed or slightly dilated, and surrounded by fibrosis may impart a pseudoinfiltrative appearance. Epithelial and stromal changes similar to those observed in intraductal papillomas can occur; apocrine metaplasia is frequent. [1577]. Papillary fronds are not always detectable in a given plane of section.

Prognosis and predictive factors of mammary adenomas

All adenomas of the breast are benign lesions that do not recur if adequately excised and do not predispose to carcinoma.

Myoepithelial lesions

F.A. Tavassoli
J. Soares

Definition

Lesions either derived from, or composed of, a dominant to pure population of myoepithelial (ME) cells. They include adenoid cystic carcinoma, pleomorphic adenoma, myoepitheliosis, adenomyoepithelial adenosis, adenomyoepithelioma (benign or malignant) and malignant myoepithelioma (myoepithelial carcinoma). The first two lesions are discussed elsewhere. In this section, the focus will be on the others.

Immunohistochemical profile of myoepithelial cells

Myoepithelial cells show positive immunoreaction with alpha smooth muscle actin, calponin, caldesmon, smooth muscle myosin heavy chain (SMM-HC) maspin S-100 protein and high MW cytokeratins 34betaE12, CK5 and CK14. Nuclear immunoreactivity with p63 is also a feature of ME cells. Rarely there is staining with glial fibrillary acidic protein (GFAP). Myoepithelial cells are negative for low MW cytokeratins (CK 8/18), estrogen receptor (ER), progesterone receptor (PR), and desmin [191,1516,1573,1741,2418,2702,2738,2953,3099].

Epidemiology

Patients range in age from 22 to 87 years [2418,2868,2875,3192].

Clinical features

Apart from myoepitheliosis, which is rarely palpable, these lesions usually present as a palpable tumour and/or mammographic density without distinctive features.

Myoepitheliosis

Definition

A multifocal, often microscopic, proliferation of spindle to cuboidal myoepithelial cells growing into and/or around small ducts and ductules.

Macroscopy

Myoepitheliosis generally appears as a firm irregular area.

Histopathology

The intraductal proliferating spindle cells may develop a prominent palisading pattern. The cuboidal cells may have longitudinal nuclear grooves resembling transitional cells. Rarely atypia and mitotic activity appear, warranting a designation of atypical myoepitheliosis.

The periductal variant of myoepitheliosis is often associated with sclerosis and is considered by some to be a variant of sclerosing adenosis; the cells have varied phenotypes. When completely excised, recurrences do not develop.

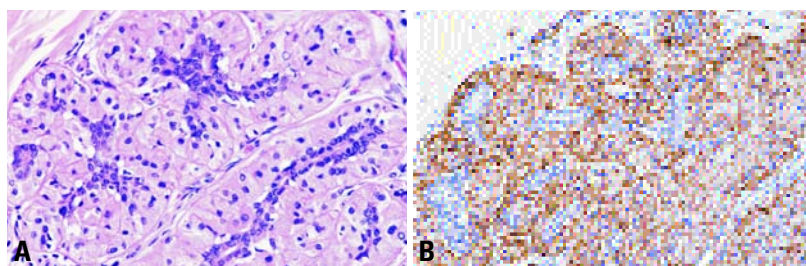


Fig. 1.125 Myoepitheliosis, periductal type. **A** The myoepithelial cells with abundant eosinophilic cytoplasm proliferate around the epithelial cells compressing the ductular lumens. This change is often multifocal. **B** Immunostain for actin is positive in the myoepithelial cells, but negative in the epithelial-lined compressed ductular spaces.

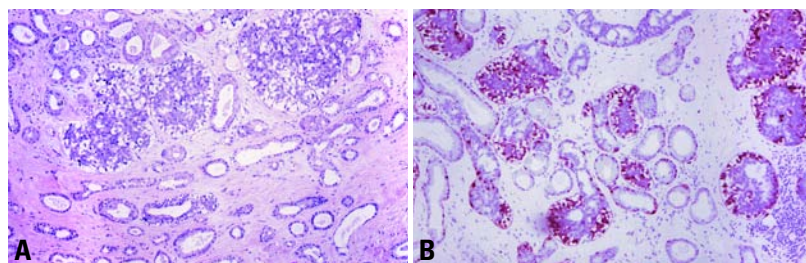


Fig. 1.126 Adenomyoepithelial adenosis. **A** Prominent clear myoepithelial (ME) cells are evident around several ductules. **B** Both the clear and normal ME cells are intensely immunoreactive for S-100 protein.

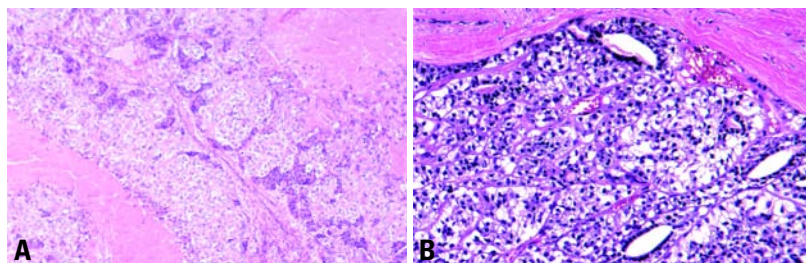


Fig. 1.127 Adenomyoepithelioma, lobulated type. **A** The lobulated nature of the tumour is apparent with massive central infarction in the two adjacent nodules. The lighter cells reflect the proliferating ME cells, while the darker cells represent the epithelial cells. **B** Adenomyoepithelioma. In this case, the proliferating ME cells have a clear cell phenotype and surround a few spaces lined by darker epithelial cells.

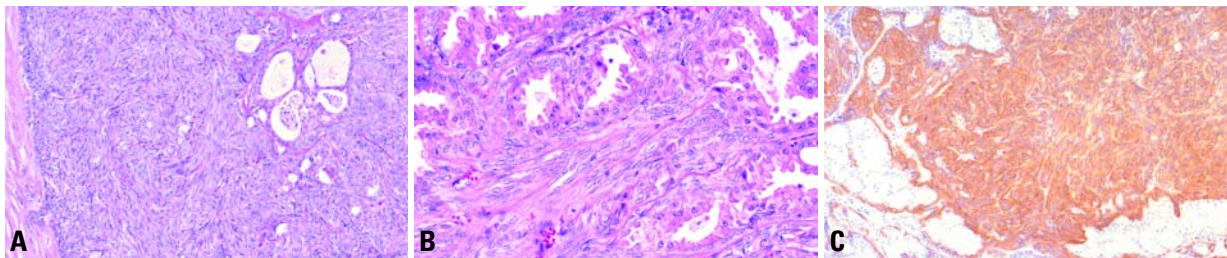


Fig. 1.128 Adenomyoepithelioma, spindle cell type. **A** There is a solid proliferation of spindled myoepithelial cells surrounding irregular epithelial lined spaces. **B** The epithelial spaces may show apocrine metaplasia. **C** Immunostain for S-100 protein shows positivity in the proliferating myoepithelial cells, while the epithelial cells fail to react.

Adenomyoepithelial adenosis

Definition

An extremely rare type of adenosis associated with adenomyoepithelioma {803, 805,1454}.

Histopathology

Adenomyoepithelial adenosis (AMEA) consists of a diffuse proliferation of round or irregular tubular structures lined by a cuboidal to columnar epithelium, which may show apocrine metaplasia. There is a prominent, focally hyperplastic myoepithelial cell layer with strikingly clear cytoplasm. There is no significant nuclear atypia or mitotic activity, but most described cases blend with or surround an adenomyoepithelioma {803,805,1454}.

Adenomyoepithelioma

Definition

Composed of a predominantly and usually solid proliferation of phenotypically variable myoepithelial cells around small epithelial lined spaces, in rare instances, the epithelial, the myoepithelial or both components of an adenomyoepithelioma (AME) may become malignant (malignant AME).

ICD-O codes

Benign	8983/0
Malignant	8983/3

Macroscopy

Well delineated, benign adenomyoepitheliomas are rounded nodules with a median size of 2.5 cm.

Histopathology

Histologically, AMEs they are characterized by a proliferation of layers or sheaths of ME cells around epithelial lined spaces. The tumour may display a spindle cell, a tubular, or, most often, a lobulated growth pattern. Fibrous septae with central hyalinization or infarction are common in the lobulated lesions. The ME cell phenotype is most variable in the lobulated pattern ranging from clear to eosinophilic and hyaline (plasmacytoid) types. Satellite nodules, seen adjacent to the lobulated variant in some cases reflect an intraductal extension of the lesion. The tubular variant has an ill defined margin. Mitotic activity of the proliferating myoepithelial cells in benign lesions is generally in the range of 1-2/10, always 2/10 high power field (hpf). Either the epithelial, the myoepithelial or both components of an adenomyoepithelioma may become malignant and

give rise to a carcinoma while the background lesion retains its adenomyoepitheliomatous appearance {793,900,903, 1695,2868,2953}. The aggressive myoepithelial component may assume a spindle configuration and develop into nodules resembling myofibroblastic lesions. A variety of epithelial derived carcinomas, sarcomas and carcinosarcomas occur in this setting (Table 1.16) [2868]. Rarely, both components develop into either separate malignancies or a single malignant infiltrative process composed of angulated tubules lined by both epithelial and myoepithelial cells.

Differential diagnosis

The tubular variant of AME should be distinguished from a tubular adenoma; the latter may have prominent ME cells, but lacks the myoepithelial proliferation typical of an AME. Furthermore, tubular adenoma is sharply circumscribed unlike the ill defined tubular AME.

The lobulated and spindle cell variants of AME should be distinguished from

Table 1.16
Classification of myoepithelial lesions.

1. Myoepitheliosis
 - a. Intraductal
 - b. Periductal
2. Adenomyoepithelial adenosis
3. Adenomyoepithelioma
 - a. Benign
 - b. With malignant change (specify the subtype)
 - Myoepithelial carcinoma arising in an adenomyoepithelioma
 - Epithelial carcinoma arising in an adenomyoepithelioma
 - Malignant epithelial and myoepithelial components
 - Sarcoma arising in adenomyoepithelioma
 - Carcinosarcoma arising in adenomyoepithelioma
4. Malignant myoepithelioma (ME carcinoma)

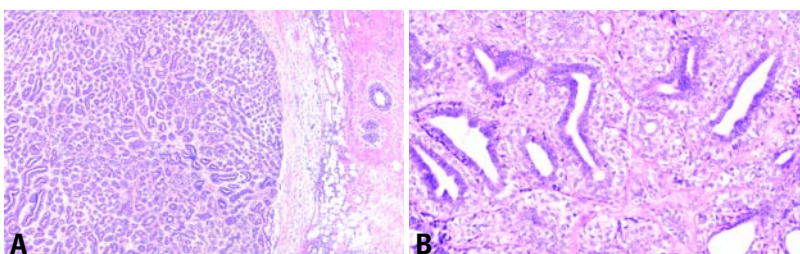


Fig. 1.129 Adenomyoepithelioma, adenosis type. **A** At least focally well delineated, these tumours superficially resemble a tubular adenoma. **B** Higher magnification shows proliferation of ME cells in the tubules beyond the normal single layer.

Table 1.17

Immunoprofile of various spindle cell tumours of the breast.

Tumour	Smooth muscle actin	Calponin	S-100	Kermix*	CAM5.2**	ER	Desmin	CD34	HMB45
Myoepithelioma	+	+	+	+	–	–	–	–	–
Spindle cell carcinoma	–	–	–	++	+	+/-	–	–	–
Smooth muscle cell tumours	+	+/-	–	+/-	+/-	+/-	+	–	–
Myofibroblastic lesions	+	+/-	+/-	–	–	–	–*	+	–
Melanoma	–	–	+	–	–	–	–	–	–

* Kermix a cocktail of AE1/AE3 (cytokeratin 1-19), and LP34 (CK5,6 & 18)
**Cam 5.2 (CK8 & 18)

pleomorphic adenoma; the latter generally has prominent areas of chondroid and/or osseous differentiation.

Prognosis and predictive factors

The majority of AME are benign {1573, 1695,2418,2581,2868}. Lesions that contain malignant areas, those with high mitotic rate, or infiltrating margins have a potential for recurrence and metastases. Local recurrence {1440, 2868,3192} as well as distant metastasis {2875} have been described, mainly among those with aggressive features.

significant atypia. Mitotic activity may not exceed 3-4 mf/10hpf. The spindle tumour cells appear to emanate from the myoepithelial cells of ductules entrapped in the periphery of the lesion. Aggregates of collagen and prominent central hyalinization may be evident.

Differential diagnosis

The differential diagnosis includes spindle cell carcinomas, fibromatosis and a variety of myofibroblastic lesions. The presence of a dominant nodule with

irregular and shallow infiltration at the margins is helpful in distinguishing this lesion from fibromatosis and myofibroblastic tumours. Immunohistochemistry is, and, rarely, electron microscopy may be, required to confirm the myoepithelial nature of the neoplastic cells.

Prognosis and predictive factors

Local recurrence or distant metastases have rarely been documented {1573, 2581,2875}. Complete excision with uninvolved margins is recommended.

Malignant myoepithelioma

Definition

An infiltrating tumour composed purely of myoepithelial cells (predominantly spindled) with identifiable mitotic activity.

Synonyms

Infiltrating myoepithelioma, myoepithelial carcinoma.

ICD-O code 8982/3

Macroscopy

Ranging from 1.0 to 21 cm in size, these tumours are generally well defined with focal marginal irregularity, although some are stellate. There may be foci of necrosis and haemorrhage on the firm rubbery cut surface in larger tumours and sometimes nodular areas of hyalinization even in smaller tumours.

Histopathology

Histologically, there is an infiltrating proliferation of spindle cells often lacking

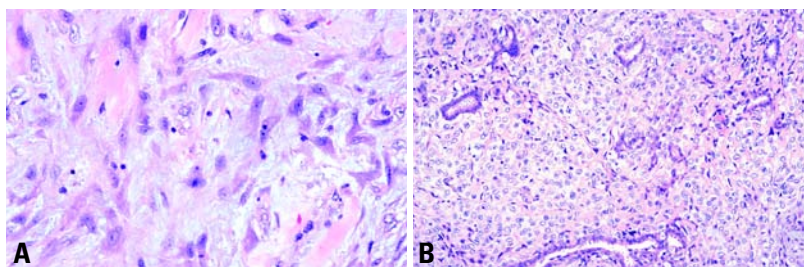


Fig. 1.130 Malignant myoepithelioma (myoepithelial carcinoma). **A** The lesion is composed of spindle cells lacking significant atypia or mitotic activity. **B** At the periphery of the same lesion, often a more epithelioid or plump cell population is evident emanating from the myoepithelial cell layer of the entrapped ductules.

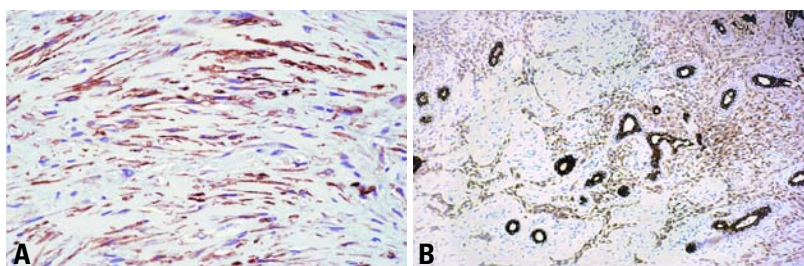


Fig. 1.131 Malignant myoepithelioma. **A** Immunostain for smooth muscle actin is positive in the neoplastic spindle cells. **B** Immunostain for kermix (AE1/AE3/LP34) shows intense staining of the entrapped normal ductules; a less intense immunoreaction is evident in the neoplastic spindle cells.

Mesenchymal tumours

M. Drijkoningen J.P. Bellocq
F.A. Tavassoli S. Lanzafame
G. Magro G. MacGrogan
V. Eusebi J.L. Peterse
M. Devouassoux-Shisheboran

Definition

Benign and malignant mesenchymal tumours morphologically similar to those occurring in the soft tissues as well as those occurring predominantly in the breast.

Benign vascular tumours

Haemangioma

Definition

A benign tumour or malformation of mature vessels.

ICD-O code 9120/0

Epidemiology

Haemangiomas of the breast have been described in both male and female patients from 18 months to 82 years old [1373,2874]. They rarely present as palpable lesions but an increasing number of non-palpable mammary haemangiomas are nowadays detected by breast imaging [3077]. Incidental "perilobular" haemangiomas are found in 1.2% of mastectomies and 4.5% of

benign breast biopsies [2443] and 11% in a series of post mortem cases (age range 29–82 years) [1633].

Macroscopy

Rarely palpable, the lesions are well circumscribed and vary from 0.5–2 cm with a reddish-brown spongy appearance.

Histopathology

Symptomatic haemangiomas may be of cavernous, capillary or venous subtypes [2435,2611]. Cavernous haemangioma is the most common type; it consists of dilated thin walled vessels lined by flattened endothelium and congested with blood. Thrombosis may be present with papillary endothelial hyperplasia (Masson's phenomenon) [1946]. Dystrophic calcification may be found in organizing thrombi as well as in the stroma between the vascular channels. Capillary haemangiomas are composed of nodules of small vessels with a lobular arrangement around a larger feeding vessel. The intervening stroma is fibrous. The endothelial lining cells may have prominent hyperchromatic nuclei but without tufting or a solid spindle cell

growth pattern. Venous haemangiomas consist of thick walled vascular channels with smooth muscle walls of varying thickness [2435].

In perilobular haemangiomas, the lobulated collections of thin-walled, wide vascular channels are seen within the intralobular stroma. Expansion into the extralobular stroma and adjacent adipose tissue is often present. The vascular channels are lined by flattened endothelium without a surrounding muscle layer [1373]. Occasional cases with prominent hyperchromatic endothelial nuclei have been described and designated atypical haemangiomas [1225]. An anastomosing growth pattern, papillary endothelial proliferations and mitoses are absent and their presence should arouse suspicion and careful exclusion of an angiosarcoma.

Prognosis and predictive factors

Recurrence, even after incomplete excision, has not been reported. Careful evaluation of the whole lesion to exclude a well differentiated angiosarcoma is indicated in all symptomatic vascular breast lesions.

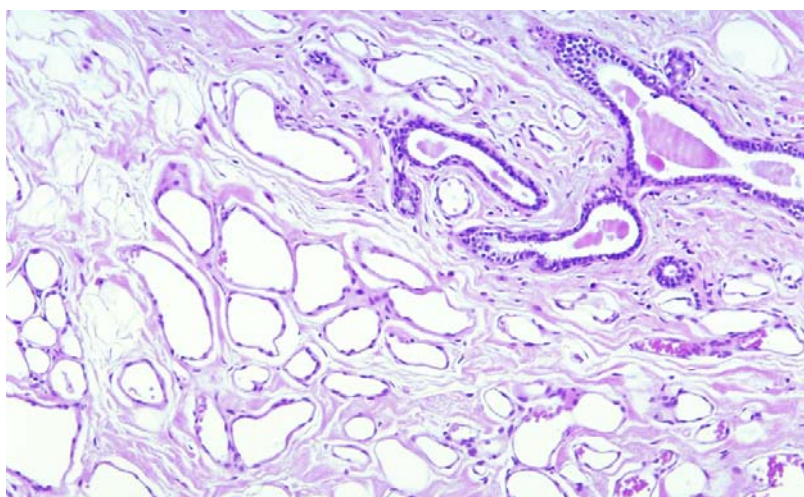


Fig. 1.132 Perilobular haemangioma. Thin walled vessels lined by flattened endothelium are seen within the intralobular stroma.

Angiomatosis

Definition

A diffuse excessive proliferation of well formed vascular channels affecting a large area in a contiguous fashion.

Synonym

Diffuse angioma.

Epidemiology

This very rare benign vascular lesion may be congenital. Most cases have been described in women between 19 and 61 years old [1921,2416]. One case was in a male.

Clinical features

Angiomatosis presents as a breast mass. Rapid increase in size has been described in a woman during pregnancy [76].

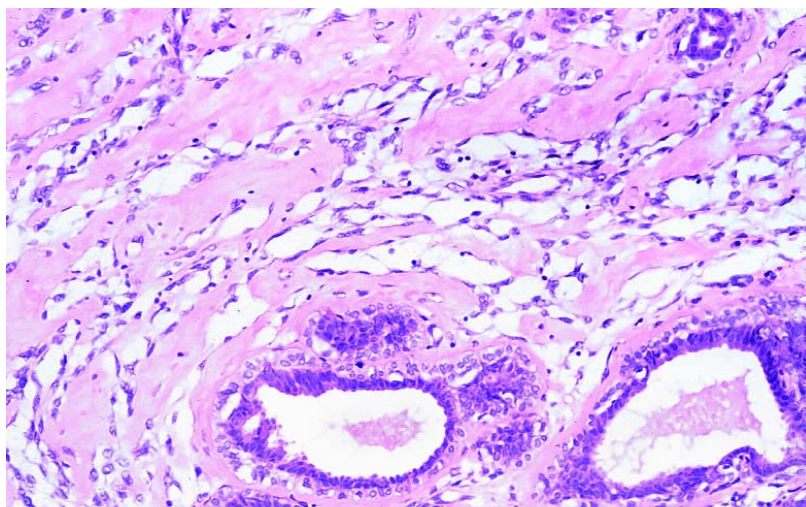


Fig. 1.133 Pseudoangiomatous stromal hyperplasia (PASH). Interanastomosing, empty, slit-like spaces within breast stroma are typical.

Pathology

Macroscopic and histopathological appearances are similar to angiomatosis at other sites. The haemorrhagic spongy lesions are composed of usually thin walled large blood or lymphatic vessels diffusely extending throughout the parenchyma of the breast.

Prognosis and predictive factors

Recurrence after incomplete excision has been reported, and may occur after a long disease-free interval [2416]. In many cases, complete excision requires a mastectomy.

Haemangiopericytoma

Definition

A circumscribed area of bland ovoid to spindled cells proliferating around branching and “stag-horn” vessels.

ICD-O codes

Benign	9150/0
NOS	9150/1
Malignant	9150/3

Epidemiology

This is a rare mesenchymal tumour. Around 20 primary haemangiopericytomas have been reported in the breast. The patients are mostly women aged 22–67, but a few cases have been reported in children (5 and 7 years old) and in men [118,2889].

Clinical features

Patients usually present with a mass that appears as a well circumscribed area of density on mammography.

Macroscopy

The tumours are round to oval, well circumscribed and range in size from 1 to 19 cm [118,1415,2855,2889]. They are firm with a solid, yellow-tan to grey-white cut surface. Myxoid areas alternate with small cysts filled with watery fluid. Haemorrhage and necrosis are evident in some larger tumours.

Histopathology

The histological and immunophenotype appearances are similar to haemangiopericytomas described elsewhere [2889]. They are composed of a compact proliferation of plump ovoid to spindle cells with indistinct cell margins arranged around an abundance of usually thin-walled, irregularly branching vascular channels. Some of the branching vessels assume a “stag-horn” configuration. Mammary ducts and ductules are often trapped focally in the periphery of the lesion.

Prognosis and predictive factors

Most cases of mammary haemangiopericytoma have been benign. There is no well documented example of metastatic disease or even recurrence [118, 1415,2855,2889]. Wide local excision rather than mastectomy is often sufficient for complete tumour excision.

Pseudoangiomatous stromal hyperplasia

Definition

A benign lesion consisting of complex anastomosing slit-like pseudovascular spaces, that are either acellular or lined by slender spindle-shaped stromal cells.

Epidemiology

The clinicopathological spectrum of mammary pseudoangiomatous stromal hyperplasia (PASH) extends from insignificant microscopic changes, often associated with either benign or malignant breast disease, to diffuse involvement of the breast or cases where a localized palpable or non-palpable breast mass is produced (nodular PASH) [1275,2270,3037]. The latter is uncommon and reported to occur in 0.4% of breast biopsies [2270]. Focal or multifocal PASH without mass formation has been reported in 23% of breast biopsies, usually as an incidental finding. PASH has been reported in at least 25% of cases of gynaecomastia [157,1865].

Aetiology

The immunophenotype of the proliferating cells confirms that PASH is of myofibroblastic origin [1113,2279,2510,3249]. The pseudoangiomatous spaces are also discernible in frozen sections, indicating that they are not a fixation artefact [157,3037].

Clinical features

Nodular PASH usually present as a painless, well circumscribed, mobile palpable mass, clinically indistinguishable from fibroadenoma [532,1275, 2270,2279,3037,3249]. Smaller lesions may be detected by mammography [532, 2270]. On imaging, nodular PASH is indistinguishable from fibroadenoma [2270]. Diffuse lesions are an incidental finding [1275]. Bilateral lesions may occur [157]. Rapid growth has been reported [532,2270,2765,3026].

Macroscopy

Macroscopically, nodular PASH is usually indistinguishable from fibroadenoma ranging in size from 1 to 17 cm. The cut surface is pale tan-pink to yellow [92, 1275,2279,2622,3037].

Histopathology

PASH may be present in normal breast tissue or in various benign lesions [867,

1113,1275}. There is a complex pattern of interanastomosing empty slit-like spaces, present within and between breast lobules with a perilobular concentric arrangement {1275,2279}. In gynaecomastia, a periductal pattern is found {157}. The spaces are formed by separation of collagen fibres and are either acellular or lined by spindle cells, simulating endothelial cells. Mitoses, tufting, atypia and pleomorphism are absent {92,1275,2279,3037,3249}. There is no destruction of normal breast tissue, no necrosis, nor invasion of fat {1275} and collagen IV cannot identify a basement membrane around the spaces {867}. The intervening stroma often consists of dense, hyalinized collagen and spindle cells with nuclei displaying pointed ends {1275,2510}. In rare more proliferative lesions, a fascicular pattern is found: the stroma is composed of bundles of plump spindle cells that may obscure the underlying pseudoangiomatous architecture {2279}. At low power, PASH may resemble low-grade angiosarcoma but can be distinguished by its growth pattern and cytological features. The immunohistochemical characteristics are also different.

Immunoprofile

The spindle cells adjacent to the clefts are positive for CD34, vimentin, actin, calponin, but negative for the endothelial cell markers Factor VIII protein, Ulex europaeus agglutinin-1 and CD31. They are also negative for S100, low and high MW cytokeratins, EMA and CD68. Desmin is usually negative, but may be positive in fascicular lesions {157,928,1865,2279,3037}.

Prognosis and predictive factors

PASH is not malignant but local recurrence has been rarely reported possibly attributable to growth after incomplete excision, or the presence of multiple lesions that were not all excised {2270,2279,3037}.

Myofibroblastoma

Definition

A benign spindle cell tumour of the mammary stroma composed of myofibroblasts.

ICD-O code 8825/0

Epidemiology

Myofibroblastoma (MFB) occurs in the breast of both women and men aged

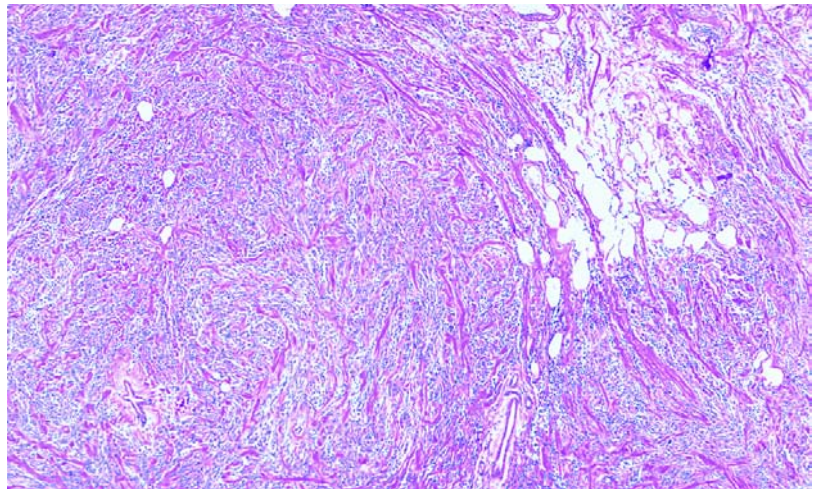


Fig. 1.134 Myofibroblastoma. An expansile tumour composed of spindle to oval cells arranged in intersecting fascicles interrupted by thick bands of collagen. Some adipose tissue is present in the right upper corner.

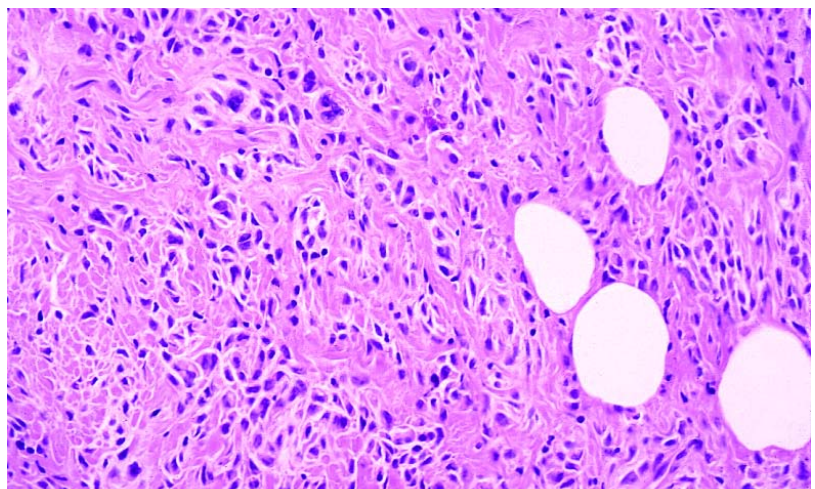


Fig. 1.135 Myofibroblastoma. A more epithelioid cell population may develop focally.

between 40 and 87 years {1023,1735}. In a few cases, an association with gynaecomastia has been documented.

Clinical features

MFB presents as a solitary slowly growing nodule. Synchronous bilaterality and unilateral multicentricity is rarely observed {1113}. Imaging shows a well circumscribed, homogeneously solid and hypoechoic mass devoid of microcalcifications {1113,1374,2252}.

Macroscopy

MFB is usually a well circumscribed encapsulated tumour ranging in size from 0.9 to 10 cm.

Histopathology

An expansile tumour with pushing borders, myofibroblastoma is composed of spindle to oval cells arranged in short, haphazardly intersecting fascicles interrupted by thick bands of brightly eosinophilic collagen. The cells have relatively abundant, ill defined, pale to deeply eosinophilic cytoplasm with a round to oval nucleus containing 1 or 2 small nucleoli. Necrosis is usually absent and mitoses are only rarely observed (up to 2 mitoses x 10 high power fields). There is no entrapment of mammary ducts or lobules within the tumour. Variable numbers of scattered mast cells may be seen in the stroma but otherwise inflammatory

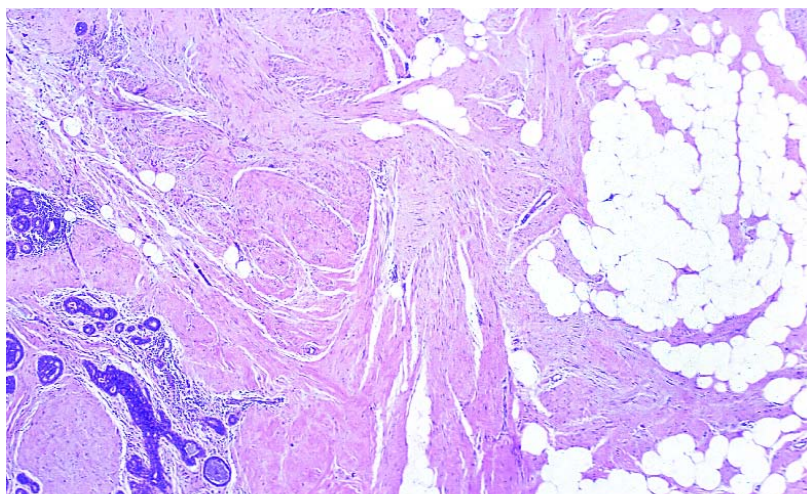


Fig. 1.136 Fibromatosis. Fascicles of spindle myofibroblast invade the adipose tissue and extend between lobules (on the left).

cells are absent. Variations include the occurrence of infiltrating margins, a prominent epithelioid cell component, mono- or multinucleated giant cells with a mild to severe degree of nuclear pleomorphism and extensive myxoid or hyaline change in the stroma. Occasionally, lipomatous, smooth muscle, cartilaginous or osseous components form additional integral parts of the tumour [934, 1734-1736]. MFB should be distinguished from nodular fasciitis, inflammatory myofibroblastic tumour, fibromatosis, benign peripheral nerve sheath tumours, haemangiopericytomas and leiomyomas [1736]. The differential diagnosis is based on immunophenotype but even so may be difficult in some cases.

Immunoprofile

The neoplastic cells react positively for vimentin, desmin, -smooth muscle actin and variably for CD34, bcl-2 protein, CD99 and sex steroid hormone receptors (estrogen, progesterone and androgen receptors) [1023, 1733, 1913].

Fibromatosis

Definition

This uncommon, locally aggressive, lesion without metastatic potential originates from fibroblasts and myofibroblasts within the breast parenchyma, excluding mammary involvement by extension of a fibromatosis arising from the pectoral fascia.

ICD-O code 8821/1

Synonym

Desmoid tumour.

Epidemiology

Fibromatosis accounts for less than 0.2% of all breast lesions [390,681,1083, 2432,3063]. It is seen in women from 13 to 80 years (average 46 and median 40) and is more common in the childbearing age than in perimenopausal or postmenopausal patients [681]. A few cases have been reported in men [378,2482].

Clinical features

The lesion presents as a solitary, painless, firm or hard palpable mass. Bilateral tumours are rare [681,2432,3063]. Skin or nipple retraction may be observed [294] and rarely nipple discharge [3063]. Mammographically, fibromatosis is indistinguishable from a carcinoma [681].

Macroscopy

The poorly demarcated tumour measures from 0.5 to 10 cm (average 2.5 cm) [681,2432,3063] with a firm, white-grey cut surface.

Histopathology

Mammary fibromatoses are histologically similar to those arising from the fascia or aponeuroses of muscles elsewhere in the body with the same immunophenotype. Proliferating spindled fibroblasts and myofibroblasts form sweeping and interlacing fascicles; the periphery of the

lesion reveals characteristic infiltrating finger-like projections entrapping mammary ducts and lobules [3063].

Fibromatosis must be distinguished from several entities in the breast.

Fibrosarcomas are richly cellular, with nuclear atypia and a much higher mitotic rate than fibromatosis. Spindle cell carcinomas disclose more typical areas of carcinoma and, in contrast to fibromatosis, the cells are immunoreactive for both epithelial markers and vimentin [1022]. Myoepithelial carcinomas are actin and/or S-100 protein positive. While CAM 5.2 positivity may be weak, pancytokeratin (Kermix) is strongly expressed in at least some tumour cells, and there is diffuse staining with CK34Beta E12 and CK 5,6. Lipomatous myofibroblastomas show a finger-like infiltrating growth pattern, reminiscent of fibromatosis [1736]. However, the cells are estrogen (ER), progesterone (PR) and androgen receptor (AR) positive in 70% of cases, while fibromatosis does not stain with these antibodies.

Nodular fasciitis is also composed of immature appearing fibroblasts but tends to be more circumscribed, and has a higher mitotic rate. The prominent inflammatory infiltrate is scattered throughout the lesion and is not limited to the periphery as in fibromatosis.

Reactive spindle cell nodules and scars at the site of a prior trauma or surgery demonstrate areas of fat necrosis, calcifications and foreign body granulomas, features that are not common in fibromatosis.

Immunoprofile

The spindle cells are vimentin positive and a small proportion of them are also actin positive, while they are invariably negative for cytokeratin and S-100 protein. In contrast to one-third of extramammary desmoid tumours [1662,1888, 2353], fibromatoses in the breast are ER, PR, AR, and pS2 (assessed as a measure of functional ER) negative [681,2335].

Prognosis and predictive factors

Mammary fibromatoses display a low propensity for local recurrence, with a reported frequency of 21% [1083], 23% [3063], and 27% [2432] of cases compared with that of 57% [790] for extramammary lesions. When it does occur, one or more generally develop within two to three years of initial surgery [1083, 3063], but local recurrence may develop after a 6-year interval [3063].

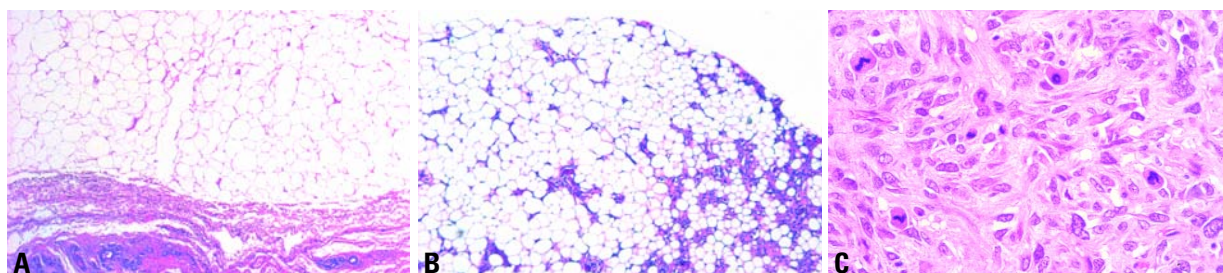


Fig. 1.137 **A** Lipoma. Intraparenchymal well circumscribed mature fat tissue. **B** Angiolipoma. Well circumscribed mature fat tissue separated by a network of small vessels. **C** Cellular angiolipoma. Patches of solid, spindle cell proliferation are typically present.

Inflammatory myofibroblastic tumour

Definition

A tumour composed of differentiated myofibroblastic spindle cells accompanied by numerous inflammatory cells.

ICD-O code 8825/1

Synonyms

Inflammatory pseudotumour, plasma cell granuloma.

Epidemiology

Inflammatory myofibroblastic tumour (IMT) is a heterogeneous clinicopathological entity [1845] that may occur at any anatomical location. There is uncertainty as to whether IMT is reactive or neoplastic in nature. Some authors regard IMT as a low grade sarcoma [1845]. Only rare cases of IMT have been reported in the breast [276,467,2235,3183].

Clinical features

IMT usually presents as a palpable circumscribed firm mass.

Macroscopy

Gross examination usually shows a well circumscribed firm white to grey mass.

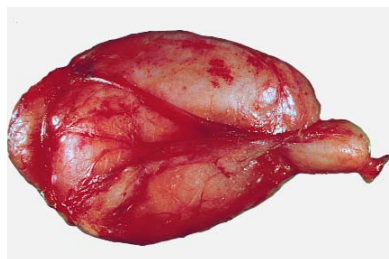


Fig. 1.138 Lipoma. Well circumscribed, lobulated mass of 11 cm.

Histopathology

The lesion consists of a proliferation of spindle cells with the morphological and immunohistochemical features of myofibroblasts, arranged in interlacing fascicles or in a haphazard fashion, and variably admixed with an inflammatory component of lymphocytes, plasma cells and histiocytes.

IMT should be distinguished from other benign and malignant spindle cell lesions occurring in the breast. The hallmark of IMT is the significant inflammatory cell component.

Prognosis and predictive factors

Although the clinical behaviour of IMT cannot be predicted on the basis of histological features, in the breast most reported cases have followed a benign clinical course after complete surgical excision [276,467,2235], with the exception of a bilateral case with local recurrence in both breasts after 5 months [3183]. Additional cases with longer follow-up are needed to define the exact clinical behaviour.

Lipoma

Definition

A tumour composed of mature fat cells without atypia.

ICD-O code 8850/0

Epidemiology

Although adipose tissue is quantitatively an important component of the normal breast tissue, pathologists rarely encounter intramammary lipomas. Subcutaneous lipomas are more often resected. Most common lipomas become apparent in patients 40-60 years of age.

Clinical features

Lipomas usually present as a slow growing solitary mass with a soft doughy consistency.

Macroscopy

Lipomas are well circumscribed, thinly encapsulated round or discoid masses; usually less than 5 cm in diameter.

Histopathology

Lipomas differ little from the surrounding fat. They may be altered by fibrous tissue, often hyalinized or show myxoid changes. Secondary alterations like lipogranulomas, lipid cysts, calcifications, may occur as a result of impaired blood supply or trauma.

Variants of lipoma

These include angiolipoma [1268,2876,3232] which, unlike angiolipomas at other sites, in the breast are notoriously painless. Microscopy reveals mature fat cells separated by a branching network of small vessels that is more pronounced in the sub capsular areas.

Characteristically, thrombi are found in some vascular channels. Some lesions rich in vessels are called cellular angiolipomas.

Other variants which have been described in the breast include spindle cell

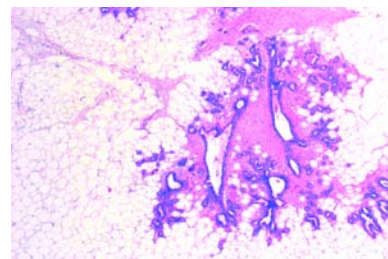


Fig. 1.139 Adenolipoma. Well circumscribed mature fat containing organoid glandular tissue.

lipoma {1645}, hibernoma {2425} and chondrolipoma {1774a}. Adenomas containing glandular breast tissue such as adenolipoma are considered as hamartomas by some and variants of lipoma by others.

Granular cell tumour

Definition

A tumour of putative schwannian origin consisting of cells with eosinophilic granular cytoplasm.

ICD-O code 9580/0

Epidemiology

Granular cell tumour (GCT) can occur in any site of the body. It is relatively uncommon in the breast {2114}. It occurs more often in females than in males {430} with a wide age range from 17-75 years {325, 617,668,3090} GCT is a potential mimicker of breast cancer, clinically, radiologically and grossly {608,617,995,2549}.

Clinical features

GCT generally presents as a single, firm, painless mass in the breast parenchyma but may be superficial causing skin retraction and even nipple inversion, whereas location deep in the breast parenchyma may lead to secondary involvement of the pectoralis fascia. Rarely, patients have simultaneous GCTs occurring at multiple sites in the body, including the breast {1920,1922}. Imaging typically shows a dense mass with stellate margin.

Macroscopy

GCT appears as a well circumscribed or infiltrative firm mass of 2–3 cm or less with a white to yellow or tan cut surface.

Histopathology

The histology is identical to that seen in GCT at other sites of the body. There is an infiltrating growth pattern, even in lesions, which appear circumscribed on gross examination. The cellular component is composed of solid nests, clusters or cords of round to polygonal cells with coarsely granular, eosinophilic periodic acid-Schiff (PAS) positive (diastase resistant) cytoplasm. due to the presence of abundant intracytoplasmic lysosomes. Awareness that GCT can occur in the breast is essential. Immunoreactivity with S-100 is important in confirming the diagnosis of GCT; lack of positivity for cytokeratins excludes breast carcinoma.

Prognosis and predictive factors

The clinical behaviour of GCT is usually benign following complete surgical excision. Rarely, lymph node metastases have been reported {668}. In contrast, a malignant course should be expected in the extremely rare malignant mammary GCTs which show nuclear pleomorphism, mitoses and necrosis {468}.

Benign peripheral nerve sheath tumours

Definition

Benign peripheral nerve sheath tumours (BPNST) include three distinct lesions usually occurring in the peripheral nerves or soft tissues: schwannomas composed of differentiated Schwann cells; neurofibromas consisting of a mixture of Schwann cells, perineurial like cells and fibroblasts and perineuromas composed of perineurial cells.

ICD-O codes

Schwannoma	9560/0
Neurofibroma	9540/0

Epidemiology

The breast is only rarely the primary site of BPNST. There are only a few case reports of schwannomas {881,953,1081} and neurofibromas {1223,1675,2645}, but to our knowledge primary perineuroma of the breast has not been recorded. Since neurofibromas may be part of neurofibromatosis type I (NF1), follow-up is needed because of the potential for malignant degeneration. The occurrence of breast cancer in the context of breast neurofibromas has been reported {1948}. The age of patients at diagnosis is wide, ranging from 15 to 80 years with a prevalence of females.

Clinical features

The lesions present as a painless nodule and the pathology and immunophenotype is identical to their counterparts at other sites of the body.

Angiosarcoma

Definition

A malignant tumour composed of neoplastic elements with the morphological properties of endothelial cells.

ICD-O code 9120/3

Synonyms

These tumours include lesions which were formerly termed haemangiosarcoma, haemangioblastoma, lymphangiosarcoma and metastasizing haemangioma. Lymphangiosarcomas probably exist as a specific sarcoma of lymphatic endothelium but, at present, there is no

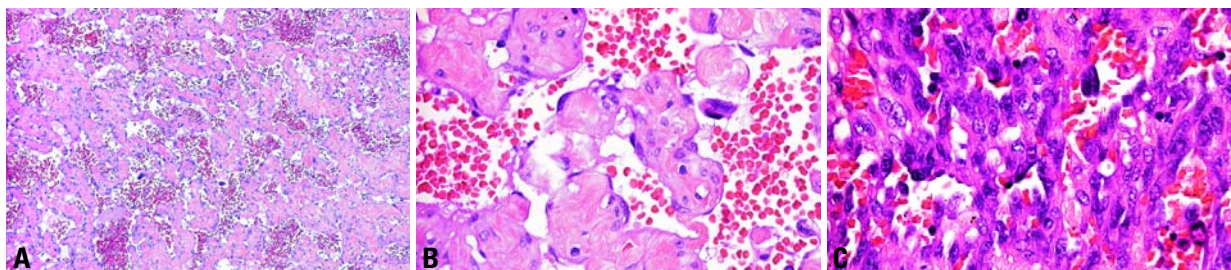


Fig. 1.140 Primary mammary angiosarcoma. **A, B** Grade I (well differentiated) angiosarcoma showing interanastomosing channels containing red blood cells. The endothelial nuclei are prominent and hyperchromatic, but mitotic figures are absent. **C** High grade (poorly differentiated) angiosarcoma. Solid aggregates of pleomorphic endothelial cells surround vascular channels.

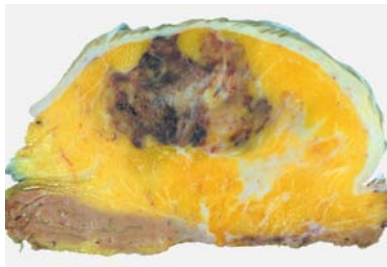


Fig. 1.141 Angiosarcoma after breast conserving treatment. The spongy, haemorrhagic mass contains occasional solid areas. In this case, the neoplasm involves the breast parenchyma as well as the skin.

reliable criterion upon which to make a histological distinction between tumours derived from endothelia of blood and lymphatic vessels.

Epidemiology

Mammary angiosarcoma can be subdivided into 1) Primary (de novo) forms in the breast parenchyma; 2) Secondary in the skin and soft tissues of the arm following ipsilateral radical mastectomy and subsequent lymphoedema - the Stewart Treves (S-T) syndrome; 3) Secondary in the skin and chest wall following radical mastectomy and local

radiotherapy; 4) Secondary in the skin or breast parenchyma or both following conservation treatment and radiotherapy. Angiosarcomas, as with other sarcomas of the breast, are rare and their incidence is about 0.05% of all primary malignancies of the organ [2876]. While the incidence of primary breast angiosarcomas has remained constant, the incidence of secondary forms has changed. S-T syndrome has dramatically declined in recent years in institutions in which more conservation surgical treatments have been adopted, while angiosarcomas of the breast developing after conserving surgery with supplementary radiation therapy have been diagnosed since the late 1980s [570].

Primary (de novo) angiosarcoma of breast parenchyma

In patients with primary angiosarcoma, the age ranges from 17 to 70 years (median 38 years) with no prevalence of laterality [2436]. The tumours are deeply located in the breast tissue [2784]. Approximately 12% of patients present with diffuse breast enlargement [2876]. When the tumour involves the overlying skin a bluish-red discoloration may ensue. Imaging is of little help [1656, 2564, 3118].

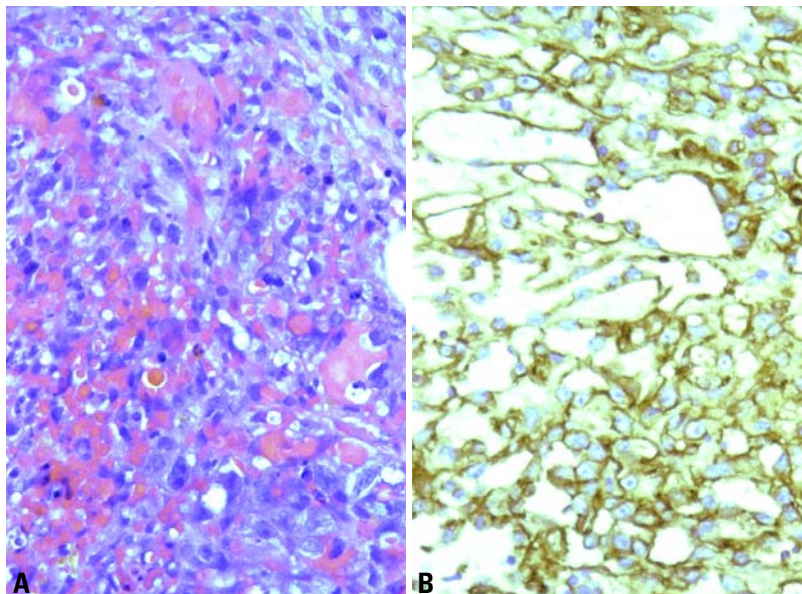


Fig. 1.142 Angiosarcoma after breast conserving treatment. **A** As in the majority of cases, this is a poorly differentiated angiosarcoma in which vascular channels are hard to see. **B** Immunostaining for the endothelial marker CD31 clearly demonstrates the solid areas of endothelial cells with occasional vascular channels.

Macroscopy

Angiosarcomas vary in size from 1 to 20 cm, averaging 5 cm [2425], have a spongy appearance and a rim of vascular engorgement which corresponds to a zone of well differentiated tumour. Poorly differentiated tumours appear as an ill defined indurated fibrous lesion similar to that of any other poorly differentiated sarcoma. Angiosarcomas must be sampled extensively to look for poorly differentiated areas that on occasion constitute the minority of a tumour.

Histopathology

Two systems have been used to grade angiosarcomas of the breast [717, 1847]. Although very similar, the one proposed by Donnell et al. [717] has gained wide impact as it was tested in a large number of patients with adequate follow up [2436].

Grade I (well differentiated) angiosarcomas consist of interanastomosing vascular channels that dissect the interlobular stroma. The neoplastic vessels have very wide lumina filled with red blood cells. The nuclei of the endothelium lining the neoplastic vessels are prominent and hyperchromatic. Care must be taken to differentiate grade I angiosarcoma from benign vascular tumours.

Grade III (poorly differentiated) angiosarcomas are easy to diagnose as interanastomosing vascular channels are intermingled with solid endothelial or spindle cell areas that show necrotic foci and numerous mitoses. In a grade III angiosarcoma, more than 50% of the total neoplastic area is composed of solid and spindle cell components without evident vascular channels [2425].

A tumour qualifies as grade II (intermediately differentiated) angiosarcoma when at least 75% of the bulk of the tumour is formed by the well differentiated pattern seen in grade I, but in addition there are solid cellular foci scattered throughout the tumour.

Clinical feature

The average age of patients with grade I angiosarcomas is 43 years while 34 and 29 years are the respective figures for grade II and III angiosarcomas [717].

Immunoprofile

Factor VIII, CD34 and CD31 are the most widely used antibodies that characterize endothelial differentiation. While present

in all grade I and most grade II angiosarcomas these markers may be lost in more poorly differentiated tumours or areas of tumour.

Prognosis and predictive factors

If well differentiated angiosarcomas (Grade I) were excluded, this breast tumour is usually lethal [457].

Grading systems highlight the relative benignity of well differentiated angiosarcomas. The survival probability for grade I tumours was estimated as 91% at 5 years and 81% at 10 years. For grade III tumours the survival probability was 31% at 2 years and 14% at 5 and 10 years. Grade II lesions had a survival of 68% at 5 and 10 years. Recurrence free survival at 5 years was 76% for grade I, 70% for grade II and 15% for grade III angiosarcomas [2436]. Metastases are mainly to lungs, skin bone and liver. Very rarely axillary lymph nodes show metastases at presentation [457]. The grade can vary between the primary tumour and its metastases [2876]. Radio and chemotherapy are ineffective.

Angiosarcoma of the skin of the arm after radical mastectomy followed by lymphoedema

Stewart and Treves in 1949 gave a lucid description of a condition subsequently named S-T syndrome [2793]. They reported six patients who had: 1) undergone mastectomy for breast cancer including axillary dissection; 2) developed an "immediate postmastectomy oedema" in the ipsilateral arm; 3) received irradiation to the breast area together with the axilla; 4) developed oedema which started in the arm and extended to the forearm and finally the dorsum of the hands and digits.

The patients ranged in age from 37-60 years, with a mean age of 64 years [3149]. The angiosarcomatous nature of S-T syndrome has been conclusively proved by ultrastructure and immunohistochemistry in most of the cases studied [1049, 1462, 1862, 2690].

The oedema is preceded by radical mastectomy for breast carcinoma including axillary dissection [275] and develops within 12 months. Nearly 65% of patients also had irradiation of the chest wall and axilla [2425]. The interval to tumour appearance varies from 1-49 years [2425], but most become evident about 10 years

following mastectomy [2752, 3149].

S-T syndrome is a lethal disease with a median survival of 19 months [3149]. Lungs are the most frequent site of metastasis.

Post-radiotherapy angiosarcoma

Angiosarcoma can manifest itself after radiotherapy in two separate settings.

1) In the chest wall when radiotherapy has been administered after mastectomy for invasive breast carcinoma with a latency time ranging from 30 to 156 months (mean 70 months). The age is more advanced than that of de novo angiosarcoma ranging from 61 to 78 years [2223]. In these cases the neoplastic endothelial proliferation is necessarily confined to the skin [392].

2) In the breast after conservation treatment for breast carcinoma. Fifty two cases had been reported as of December 1997. The first case was described in 1987 [1764]. This type of angiosarcoma involves only the skin in more than half the cases, while exclusive involvement of breast parenchyma is very rare. Most tumours (81%) are multifocal and a large majority of patients harbour grade II to III angiosarcomas. Radiotherapy and chemotherapy are ineffective [2876].

Liposarcoma

Definition

A variably cellular or myxoid tumour containing at least a few lipoblasts.

ICD-O code 8850/3

Epidemiology

Primary liposarcoma should be distinguished from liposarcomatous differentiation in a phyllodes tumour. It occurs predominantly in women ranging in age from 19-76 years (median, 47 years) [116, 138]. The tumour only rarely occurs in the male breast [3027]. Liposarcoma following radiation therapy for breast carcinoma has been reported.

Clinical features

Patients present most often with a slowly enlarging, painful mass. In general, skin changes and axillary node enlargement are absent. Rarely the tumour is bilateral [3027].

Macroscopy

Liposarcomas are often well circumscribed or encapsulated, about one-third have infiltrative margin. With a median size of 8 cm, liposarcomas may become enormous exceeding 15 cm [116, 138]. Necrosis and haemorrhage may be present on the cut surface of larger tumours.

Histopathology

The histopathology and immunophenotype is identical to that of liposarcoma at other sites. The presence of lipoblasts establishes the diagnosis. Practically every variant of soft tissue liposarcoma has been reported in the breast, including the pleomorphic, dedifferentiated and myxoid variants. Despite the well delineated gross appearance, many mammary liposarcomas have at least partial infiltrative margins on histological examination. Atypia is often present at least focally. The well differentiated and myxoid variants have a delicate arborizing vascular network and few lipoblasts. These may assume a signet-ring appearance in the myxoid variant. The pleomorphic variant is composed of highly pleomorphic cells and bears significant resemblance to malignant fibrous histiocytoma; the presence of lipoblasts identifies the lesion as a liposarcoma. Mitotic figures are readily identifiable in this variant.

Differential diagnosis

Vacuolated cells in a variety of lesions may be confused with lipoblasts. Typical lipoblasts have scalloped irregular nuclei with sharply defined vacuoles that contain lipid rather than glycogen or mucin. Clear nuclear pseudo-inclusions are a characteristic of the bizarre large cells in atypical lipomatous tumours and help distinguish these atypical cells from true lipoblasts that are diagnostic of a liposarcoma.

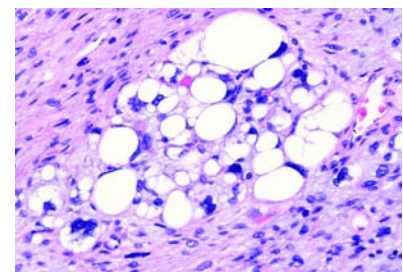


Fig. 1.143 Liposarcoma. Note the highly pleomorphic nuclei and multiple lipoblasts.

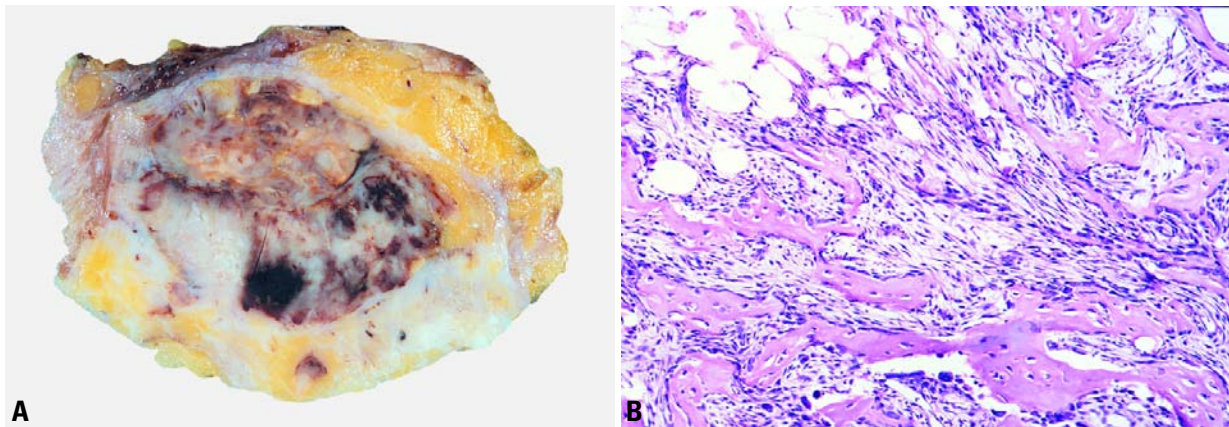


Fig. 1.144 Mammary osteosarcoma. **A** The sectioned surface shows a well delineated, solid mass with focal haemorrhage. **B** The spindle cell component of the tumour invades the adipose tissue and is admixed with abundant bony trabeculae.

Prognosis and predictive factors

Both the myxoid and pleomorphic variants of liposarcoma can recur and metastasize. Axillary node metastases are exceptionally rare. Recurrences generally develop within the first year and patients who die from their disease usually do so within a year of the diagnosis. Because of the high frequency of marginal irregularity, complete excision with tumour free margins is necessary. Liposarcomas behave particularly aggressively when associated with pregnancy.

Rhabdomyosarcoma

Definition

A tumour composed of cells showing varying degrees of skeletal muscle differentiation.

ICD-O codes

Rhabdomyosarcoma	8900/3
Alveolar type	8920/3
Pleomorphic type	8901/3

Epidemiology

Pure primary rhabdomyosarcoma of the breast is very uncommon, and, although primary mammary rhabdomyosarcoma has been described, it usually represents a metastasis from a soft tissue rhabdomyosarcoma occurring in children, young females or males [2402]. More frequently, rhabdomyosarcomatous differentiation may be observed in older women as an heterologous component of a malig-

nant phyllodes tumour or a metaplastic carcinoma.

Pathology

Primary rhabdomyosarcoma has been reported in adolescents [773,1166,1198,2402], when it is predominantly of the alveolar subtype; the pleomorphic subtype has been reported in older women over forty [2871].

Metastatic rhabdomyosarcoma to the breast is again predominantly of the alveolar subtype [1166,1248]. The primary lesion is usually located on the extremities, in the nasopharynx/paranasal sinuses or on the trunk [1166]. A metastasis from an embryonal rhabdomyosarcoma to the breast is less frequent [1166,2531].

Metastatic breast tumours may occur as part of disseminated disease or as an isolated lesion.

Mammary osteosarcoma

Definition

A malignant tumour composed of spindle cells that produce osteoid and/or bone together with cartilage in some cases.

ICD-O code 9180/3

Synonym

Mammary osteogenic sarcoma.

Epidemiology

Accounting for about 12% of all mammary sarcomas, pure osteosarcomas must be distinguished from those origi-

nating in phyllodes tumours or carcinosarcomas. Absence of connection to the skeleton, which should be confirmed by imaging studies, is required for a diagnosis of a primary mammary osteosarcomas.

Osteosarcomas occur mainly in older women with a median age of 64.5 years; the age range is 27–89 years [2681]. The vast majority of patients are women who are predominantly Caucasian. A prior history of radiation therapy or trauma has been noted in some women [331].

Clinical features

The tumour presents as an enlarging mass which is associated with pain in one-fifth of cases. Bloody nipple discharge or nipple retraction occurs in 12% of the women. Mammographically, osteosarcomas present as a well circumscribed mass with focal to extensive coarse calcification. Because of their predominantly circumscribed nature, they may be misinterpreted as a benign lesion [3072].

Macroscopy

Osteosarcomas vary in size from 1.4 to 13 cm; most are about 5 cm in size and are sharply delineated. The consistency varies from firm to stony hard depending on the proportion of osseous differentiation. Cavitation and necrosis are seen in larger tumours.

Histopathology

The histopathological appearance and immunophenotype are similar to that of

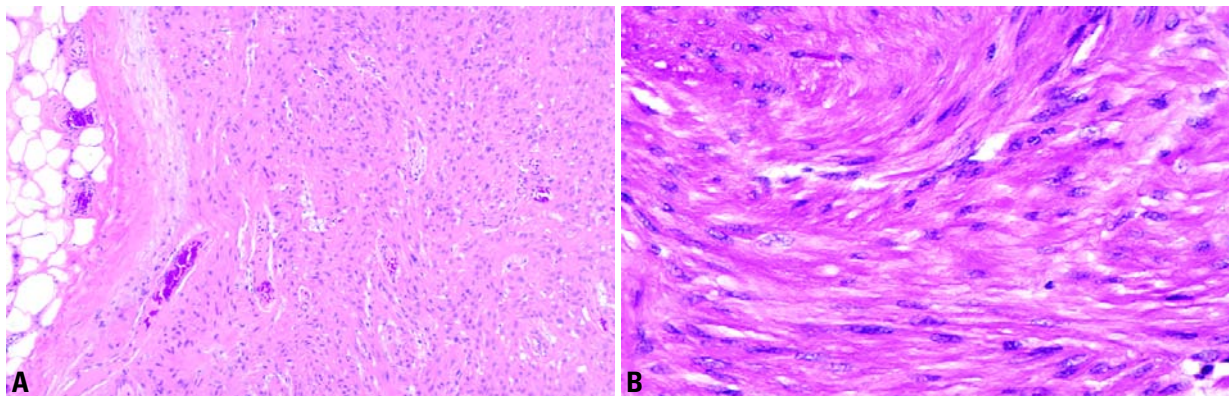


Fig. 1.145 Leiomyoma. **A** The well circumscribed margin (left) is apparent. **B** The bland smooth muscle cells proliferate in whorls and fascicles.

extraosseous osteosarcoma at other sites of the body. Despite the predominantly circumscribed margins, characteristically, at least focal infiltration is present. The tumour is composed of a spindle to oval cell population with variable amounts of osteoid or osseous tissue; cartilage is present in over a third of the cases [2681] but no other differentiated tissues.

The appearance of the tumours varies depending on the cellular composition (fibroblastic, osteoblastic, osteoclastic) as well as the type and amount of matrix (osteoid, osseous, chondroid).

The osteoclastic giant cells are immunoreactive with the macrophage marker CD68 (clone KP1) while the spindle cells fail to immunoreact with either estrogen receptor (ER) or progesterone receptor (PR) or epithelial markers.

Prognosis and predictive factors

Mammary osteosarcomas are highly aggressive lesions with an overall five-year survival of 38% [2681]. Recurrences develop in over two-thirds of the patients treated by local excision and 11% of those treated by mastectomy. Metastases to the lungs and absence of axillary node involvement are typical of osteosarcomas. Many of the patients who develop metastases die of the disease within 2 years of initial diagnosis [2681].

Fibroblastic osteosarcomas are associated with a better survival compared to the osteoblastic or osteoclastic variants. Large tumour size at presentation, prominent infiltrating margins and necrosis are associated with more aggressive behaviour.

Leiomyoma and leiomyosarcoma

Definition

Benign and malignant tumours composed of intersecting bundles of smooth muscle which is mature in benign lesions. Malignant lesions are larger in size and show more mitotic activity in the neoplastic cells.

ICD-O codes

Leiomyoma	8890/0
Leiomyosarcoma	8890/3

Epidemiology

Benign and malignant smooth muscle tumours of the breast are uncommon and represent less than 1% of breast neoplasms. The majority of leiomyomas originate from the areolar-nipple complex and a minority occur within the breast proper [1981]. Leiomyosarcomas arise mainly within the breast [821].

The age at presentation of leiomyomas and leiomyosarcomas overlaps, extending from the fourth to the seventh decades. However, cases of both have been reported in adolescents [2000] and patients over eighty years old [821].

Clinical features

Both leiomyomas and leiomyosarcomas usually present as a slowly growing palpable mobile mass that may be painful. Incidental asymptomatic leiomyomas discovered in mastectomy specimens have been reported [1981].

Macroscopy

These lesions appear as well circumscribed firm nodules with a whorled or

lobulated cut surface. Their size ranges from 0.5 to 15 cm [770,2000].

Histopathology

The histopathology and immunophenotype are identical to that seen in smooth muscle tumours elsewhere in the body. These neoplasms may be well circumscribed [1981] or show irregular infiltrative borders [2000]. Both are composed of spindle cells arranged in interlacing fascicles.

In leiomyomas, these cells have elongated cigar-shaped nuclei and eosinophilic cytoplasm without evidence of atypia. Mitoses are sparse and typically fewer than 3 per 10 high power fields [458]. In leiomyosarcomas, nuclear atypia and mitotic activity are more prominent [821]. Tumour necrosis may also be observed. Infiltrating margins may not be evident in some leiomyosarcomas.

Differential diagnosis

A diagnosis of a smooth muscle tumour of the breast should be considered only after excluding other breast lesions that may show benign or malignant smooth muscle differentiation i.e. fibroadenoma, muscular hamartoma and sclerosing adenosis should be distinguished from leiomyoma; spindle cell myoepithelioma and sarcomatoid carcinoma from leiomyosarcoma.

Prognosis and predictive factors

Leiomyomas are best treated by complete excision whereas, wide excision with tumour-free margins is recommended for leiomyosarcomas. Late local recurrence and metastasis have been reported in cases of mammary leiomyosarcoma [458,2014].

Fibroepithelial tumours

J.P. Bellocq
G. Magro

Definition

A heterogeneous group of genuine biphasic lesions combining an epithelial component and a quantitatively predominant mesenchymal component (also called stromal component) which is responsible for the gross appearance. Depending on the benign or malignant nature of each component, various combinations may occur. They are classified into two major categories: fibroadenomas and phyllodes tumours.

Hamartomas are not fibroepithelial tumours, but represent pseudotumoral changes. As they contain glandular and stromal tissue, and sometimes may resemble fibroadenomas, they have been included in this chapter.

Fibroadenoma

Definition

A benign biphasic tumour, fibroadenoma (FA) occurs most frequently in women of childbearing age, especially those under 30.

ICD-O code 9010/0

Aetiology

Usually considered a neoplasm, some believe FA results from hyperplasia of normal lobular components rather than being a true neoplasm.

Clinical features

FA presents as a painless, solitary, firm, slowly growing (up to 3 cm), mobile, well defined nodule. Less frequently it may occur as multiple nodules arising synchronously or asynchronously in the same or in both breasts and may grow very large (up to 20 cm) mainly when it occurs in adolescents. Such lesions, may be called "giant" fibroadenomas. With the increasing use of screening mammography, small, non-palpable FAs are being discovered.

Macroscopy

The cut surface is solid, firm, bulging, greyish in colour, with a slightly lobulated

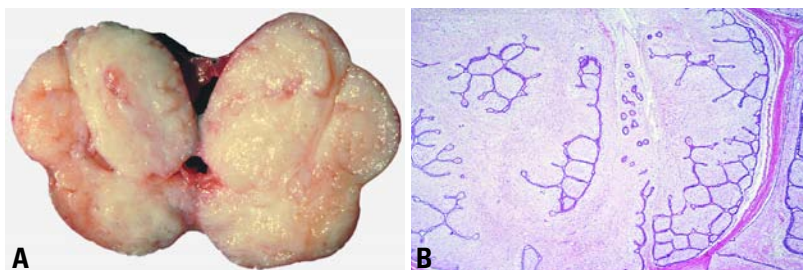


Fig. 1.146 **A** Fibroadenoma showing lobulated, bulging cut surface. **B** Fibroadenoma with intracanalicular growth pattern.

pattern and slit like spaces. Variations depend on the amount of hyalinization and myxoid change in the stromal component. Calcification of sclerotic lesions is common.

Histopathology

The admixture of stromal and epithelial proliferation gives rise to two distinct growth patterns of no clinical significance. The pericanalicular pattern is the result of proliferation of stromal cells around ducts in a circumferential fashion; this pattern is observed most frequently during the second and third decades of life. The intracanalicular pattern is due to compression of the ducts into clefts by the proliferating stromal cells. The stromal component may sometimes exhibit focal or diffuse hypercellularity (especially in women less than 20 years of age), atypical bizarre multinucleated giant cells [233,2278], extensive myxoid changes or hyalinization with dystrophic calcification and, rarely, ossification

(especially in postmenopausal women). Foci of lipomatous, smooth muscle [1040], and osteochondroid [1852,2762] metaplasia may rarely occur. Mitotic figures are uncommon. Total infarction has been reported, but rarely.

The epithelial component can show a wide spectrum of typical hyperplasia, mainly in adolescents [411,1525,1861,2250], and metaplastic changes such as apocrine or squamous metaplasia may be seen. Foci of fibrocystic change, sclerosing adenosis and even extensive myoepithelial proliferation can also occur in FA. In situ lobular, and ductal carcinoma occasionally develop within FAs [693,1525].

Juvenile (or cellular) fibroadenomas are characterized by increased stromal cellularity and epithelial hyperplasia [1861,2250]. The term giant FA has been used as a synonym for juvenile fibroadenoma by some, but is restricted to massive fibroadenomas with usual histology by others.

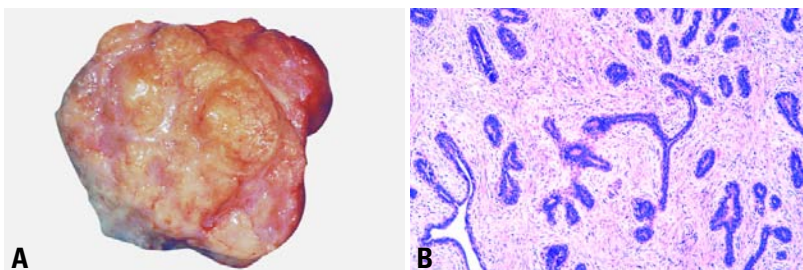


Fig. 1.147 Juvenile fibroadenoma. **A** Lobulated sectioned surface in a 8 cm tumour. Patient was 16 years old. **B** Periductal growth pattern with moderate stromal hypercellularity.

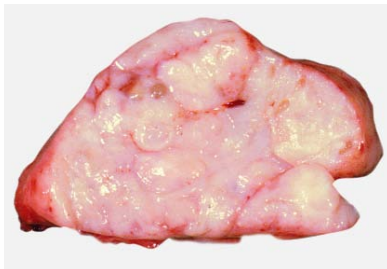

Fig. 1.148 Phyllodes tumour. A well circumscribed 6.5 cm mass with a few clefts was histologically benign.

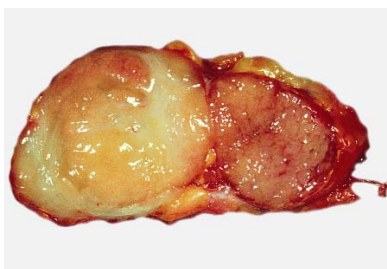


Fig. 1.149 Phyllodes tumour. A circumscribed 9 cm tumour contained a large yellow nodule of liposarcoma (yellow) adjacent to a nodule of malignant phyllodes tumour (pink).

Differential diagnosis

Most FAs, especially those of large size, cellular stroma and epithelial clefts need to be distinguished from phyllodes tumours (see below). Another breast lesion, which can simulate FA, is hamartoma.

Prognosis and predictive features

Most FAs do not recur after complete surgical excision. In adolescents, there is a tendency for one or more new lesions to develop at another site or even close to the site of the previous surgical treatment.

The risk of developing cancer within a FA or in breasts of patients previously treated for FA is low, although a slightly increased risk has been reported [734, 1640].

Phyllodes tumours

Definition

A group of circumscribed biphasic tumours, basically analogous to fibroadenomas, characterized by a double

layered epithelial component arranged in clefts surrounded by an overgrowing hypercellular mesenchymal component typically organized in leaf-like structures.

Phyllodes tumours (PTs) are usually benign, but recurrences are not uncommon and a relatively small number of patients will develop haematogenous metastases. Depending on the bland or overtly sarcomatous characteristics of their mesenchymal component (also called stromal component), PTs display a morphological spectrum lying between fibroadenomas (FAs) and pure stromal sarcomas.

Still widespread in the literature, the generic term "cystosarcoma phyllodes", is currently considered inappropriate and potentially dangerous since the majority of these tumours follow a benign course. It is highly preferable to use the neutral term "phyllodes tumour", according to the view already expressed in the WHO classification of 1981 [3154], with the adjunction of an adjective determining the putative behaviour based on histological characteristics.

ICD-O codes

Phyllodes tumour, NOS	9020/1
Phyllodes tumour, benign	9020/0
Phyllodes tumour, borderline	9020/1
Phyllodes tumour, malignant	9020/3
Periductal stromal sarcoma, low grade	9020/3

Epidemiology

In western countries, PTs account for 0.3-1% of all primary tumours and for 2.5% of all fibroepithelial tumours of the breast. They occur predominantly in middle-

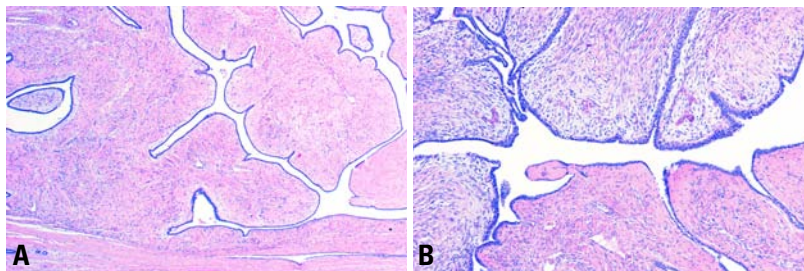


Fig. 1.150 Benign phyllodes tumour. **A** Leaf-like pattern and well defined interface with the surrounding normal tissue. **B** Higher magnification shows stromal cellularity.

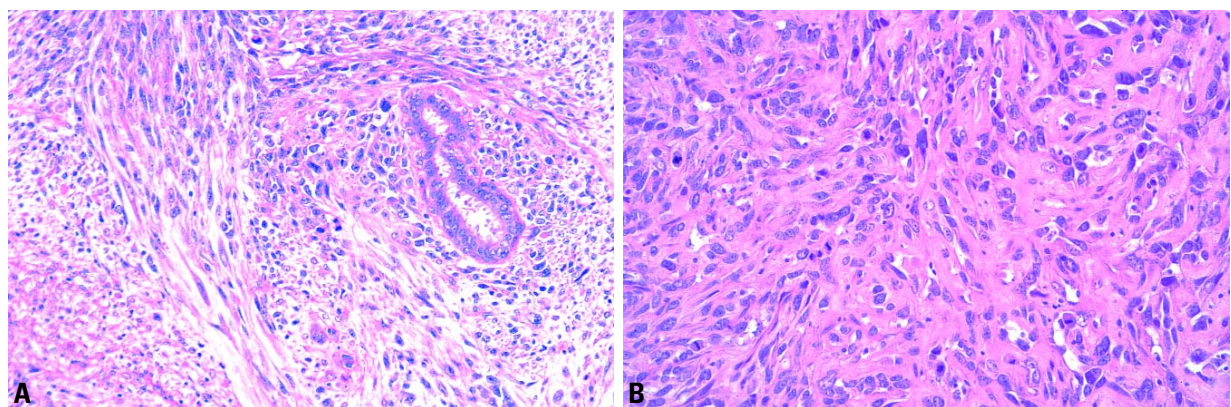


Fig. 1.151 Malignant phyllodes tumour. **A** Periductal stromal growth with malignant features. **B** Note severe stromal atypia and multiple mitoses.

aged women (average age of presentation is 40-50 years) around 15-20 years older than for FAs.

In Asian countries, PTs occur at a younger age (average 25-30 years) [487].

Malignant PTs develop on average 2-5 years later than benign PTs. Among Latino whites, especially those born in Central and South America, malignant phyllodes is more frequent [254].

Isolated examples of PTs in men have been recorded [1424a,2023].

Aetiology

PTs are thought to be derived from intralobular or periductal stroma. They may develop *de novo* or from FAs. It is possible, in rare cases, to demonstrate the presence of a pre-existing FA adjacent to a PT.

Clinical features

Usually, patients present with a unilateral, firm, painless breast mass, not attached to the skin. Very large tumours (>10 cm) may stretch the skin with striking distension of superficial veins, but ulceration is very rare. Due to mammographic screening, 2-3 cm tumours are becoming more common, but the average size remains around 4-5 cm [775,2425]. Bloody nipple discharge caused by spontaneous infarction of the tumour has been described in adolescent girls [1781, 2833]. Multifocal or bilateral lesions are rare [1932].

Imaging reveals a rounded, usually sharply defined, mass containing clefts or cysts and sometimes coarse calcifications.

Macroscopy

PTs form a well circumscribed firm, bulging mass. Because of their often clearly defined margins, they are often shelled out surgically.

The cut surface is tan or pink to grey and may be mucoid. The characteristic whorled pattern with curved clefts resembling leaf buds is best seen in large lesions, but smaller lesions may have an homogeneous appearance. Haemorrhage or necrosis may be present in large lesions.

Histopathology

PTs typically exhibit an enhanced intracanalicular growth pattern with leaf-like projections into dilated lumens. The epithelial component consists of luminal

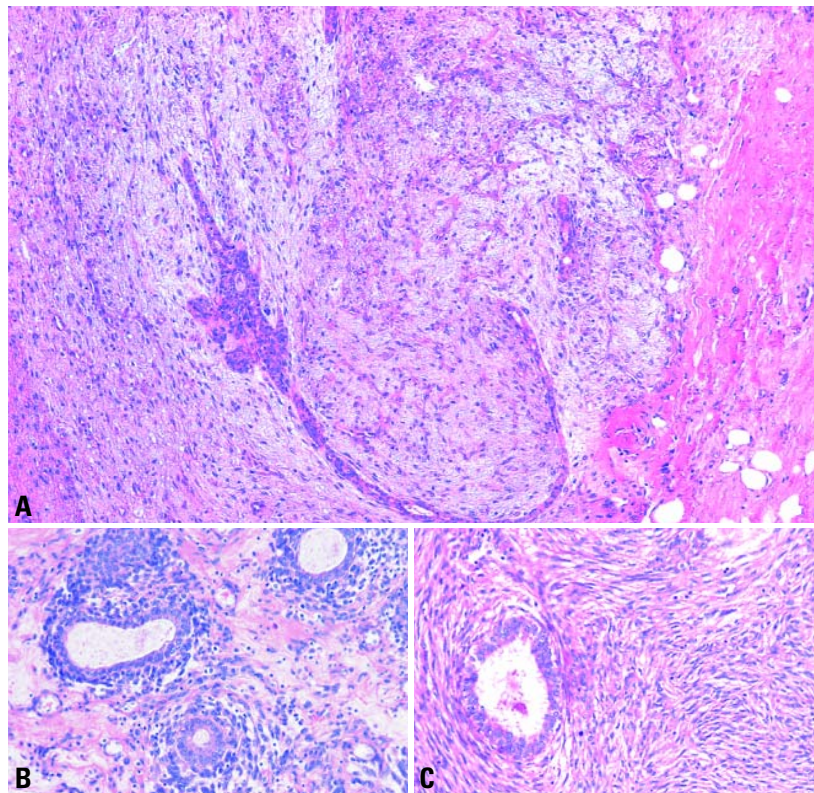


Fig. 1.152 Phyllodes tumour, borderline. **A** A predominantly pushing margin in a borderline tumour. **B** Periductal stromal condensation. **C** Dense spindle-cell stroma with a few mitotic figures.

epithelial and myoepithelial cells. Apocrine or squamous metaplasia is occasionally present and hyperplasia is not unusual. In benign phyllodes tumours, the stroma is more cellular than in FAs, the spindle cell nuclei are monomorphic and mitoses are rare. The stromal cellularity may be higher in zones in close contact with the epithelial component. Areas of sparse stromal cellularity, hyalinisation or myxoid changes are not uncommon. Necrotic areas may be seen in very large tumours. The presence of occasional bizarre giant cells should not be taken as a mark of malignancy. Lipomatous, cartilaginous and osseous metaplasia have been reported [2057,2730]. The margins are usually well delimited, although very small tumour buds may protrude into the surrounding tissue. Such expansions may be left behind after surgical removal and are a source of local recurrence.

Malignant PTs have infiltrative rather than pushing margins. The stroma shows frankly sarcomatous, usually fibrosarco-

matous changes. Heterologous differentiation such as liposarcoma, osteosarcoma, chondrosarcoma or rhabdomyosarcoma may occur [536,1161,2057,2249, 2308]. Such changes should be indicated in the diagnostic report. Due to overgrowth of the sarcomatous components, the epithelial component may only be identified after examining multiple sections.

Borderline PTs (or low grade malignant PTs) display intermediate features and the stroma often resembles low-grade fibrosarcoma.

Malignant epithelial transformation (DCIS or LIN and their invasive counterparts) is uncommon [2136].

Differential diagnosis

Benign PTs may be difficult to distinguish from fibroadenomas. The main features are the more cellular stroma and the formation of leaf-like processes. However, the degree of hypercellularity that is required to qualify a PT at its lower limit is difficult to define. Leaf-like

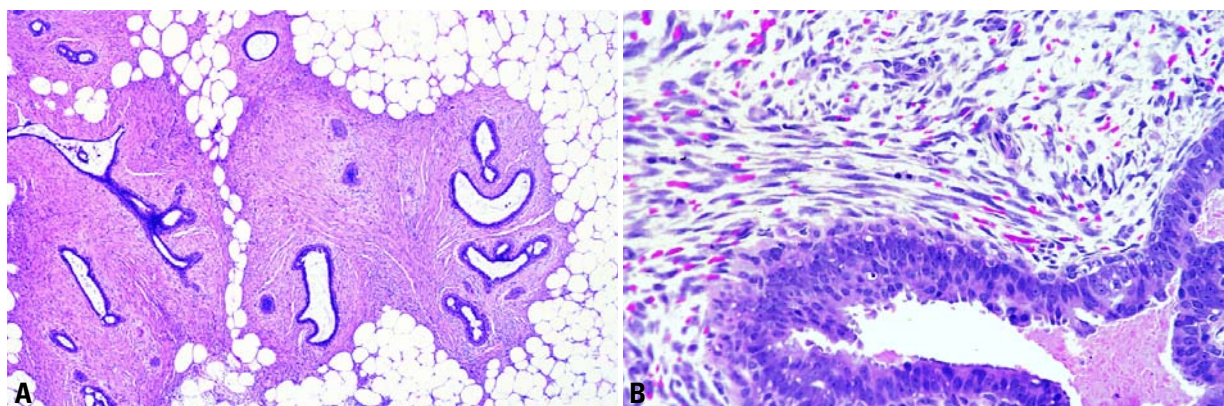


Fig. 1.153 Periductal stroma sarcoma, low grade. **A** An infiltrative hypercellular spindle cell proliferation surrounds ducts with open lumens. **B** At higher magnification, the neoplastic spindle cells contain at least three mitotic figures per 10 high power fields.

processes may be found in intracanalicular FAs with hypocellular and oedematous stroma, but the leaf-like processes are few in number and often poorly formed.

The term giant FA as well as juvenile (or cellular) FA have often been used inappropriately as a synonym for benign PT. Although the term periductal stromal sarcoma has been used as a synonym for PTs [2079], it is better restricted to a very rare non circumscribed biphasic lesion characterized by a spindle cell proliferation localized around tubules that retain an open lumen and absence of leaf-like processes [2876]. These often low grade lesions may recur and rarely progress to a classic PT.

Malignant PTs may be confused with pure sarcomas of the breast. In such case, diagnosis depends on finding residual epithelial structures. However, the clinical impact of these two entities appears to be similar [1887].

Grading

Several grading systems have been proposed with either two subgroups [1596,2876], or three subgroups [1473, 1887]. None is universally applied since prediction of the behaviour remains difficult in an individual case.

Grading is based on semi-quantitative assessment of stromal cellularity, cellular pleomorphism, mitotic activity, margin appearance and stromal distribution.

Because of the structural variability of PTs, the selection of one block for every 1 cm of maximal tumour dimension is appropriate [2876]. PTs should be subclassified according to the areas of highest cellular activity and most florid architectural pattern. The different thresholds of mitotic indices vary substantially from author to author. Since the size of high power fields is variable among different microscope brands, it has been suggested that the mitotic count be related to the size of the field diameter [1887]. Stromal overgrowth has been defined as stromal proliferation to the point where the epithelial elements are absent in at least one low power field (40x) [3058]. So defined, stromal overgrowth is not uncommon.

Table 1.18

Main histologic features of the 3 tiered grading subgroups for phyllodes tumours.

	Benign	Borderline	Malignant
Stromal hypercellularity	modest	modest	marked
Cellular pleomorphism	little	moderate	marked
Mitosis	few if any	intermediate	numerous (more than 10 per 10 HPF)
Margins	well circumscribed, pushing	intermediate	invasive
Stromal pattern	uniform stromal distribution	heterogeneous stromal expansion	marked stromal overgrowth
Heterologous stromal differentiation	rare	rare	not uncommon
Overall average distribution [1887]	60%	20%	20%

Prognosis and predictive factors

Local recurrence occurs in both benign and malignant tumours. Recurrence may mirror the microscopic pattern of the original tumour or show dedifferentiation (in 75% of cases) [1067]. Metastases to nearly all internal organs have been reported, but the lung and skeleton are the most common sites of spread. Axillary lymph node metastases are rare, but have been recorded in 10-15% in cases of systemic disease [1887,2876]. Recurrences generally develop within 2 years, while most deaths from tumour occur within 5 years of diagnosis, sometimes after mediastinal compression through direct chest wall invasion.

The frequency of local recurrence and metastases correlate with the grade of PTs but vary considerably from one series to another. The average in pub-

lished data suggests a 21% rate of local recurrence overall, with a 17%, 25% and 27% rate in benign, borderline and malignant PTs, respectively, and a 10% rate of metastases overall, with a 0%, 4% and 22% rate in benign, borderline and malignant PTs, respectively [1887]. Local recurrence after surgery is strongly dependent on the width of the excision margins [186].

Mammary hamartomas

Definition

A well demarcated, generally encapsulated mass, composed of all components of breast tissue.

Epidemiology

Hamartomas occur predominantly in the peri-menopausal age group, but may be found at any age, including teenagers and post-menopausal women.

Clinical features

Hamartomas are frequently asymptomatic and only revealed by mammography [3042]. They are detected in 0.16% of mammograms [1204]. Very large lesions can deform the breast. Due to their well defined borders they are easily enucleated.

Macroscopy

Hamartomas are round, oval, or discoid, ranging in size from 1 cm to more than 20 cm. Depending on the composition of the lesion the cut surface may resemble nor-

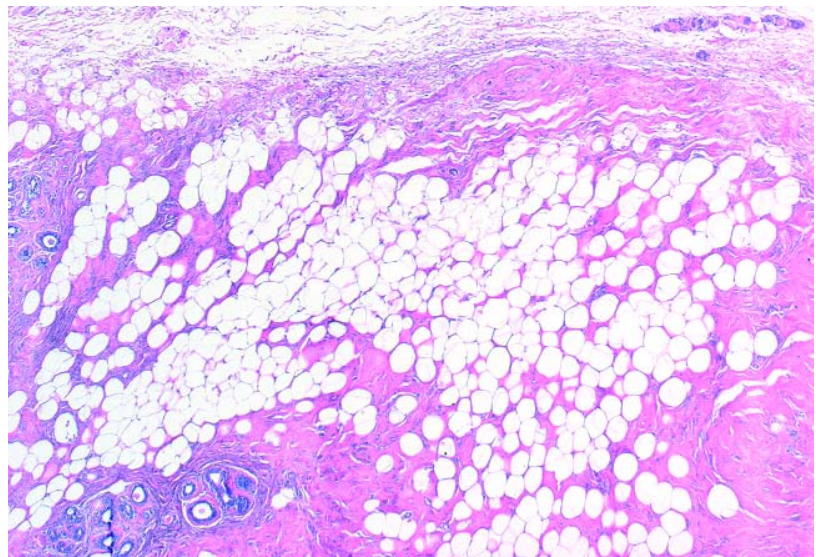


Fig. 1.154 Hamartoma. Intraparenchymal mass of common breast tissue with well defined margin.

mal breast tissue, a lipoma or may be rubbery and reminiscent of a FA.

Histopathology

Generally encapsulated, this circumscribed mass of breast tissue may show fibrocystic or atrophic changes; pseudoangiomatous hyperplasia (PASH) is frequent [446]. The lesion gives the impression of “breast within breast”. In adolescents, differentiation between the appearance of the normal adolescent breast and FAs or asymmetric virginal hypertrophy can be difficult. Rare exam-

ples resembling phyllodes tumours, have been observed [2876].

Variants of hamartoma

Adenolipoma [867], adenohibernoma [618], and myoid hamartoma [624] could all be considered variants of mammary hamartoma.

Prognosis

The lesion is benign with no tendency to recur.

Tumours of the nipple

V. Eusebi
K.T. Mai
A. Taranger-Charpin

Nipple adenoma

Definition

A compact proliferation of small tubules lined by epithelial and myoepithelial cells, with or without proliferation of the epithelial component, around the collecting ducts of the nipple.

ICD-O code 8506/0

Synonyms

Nipple duct adenoma; papillary adenoma; erosive adenomatosis; florid papillomatosis; papillomatosis of the nipple, subareolar duct papillomatosis.

Historical annotation

Under the designation of nipple adenoma (NA), several morphological lesions (some of which overlap) have been included {1356,2222,2429,2894}.

1. The largest group consists of cases showing an adenosis pattern in its classical form, with sclerosis and/or pseudoinvasive features, sclerosing papillomatosis {2429}, and infiltrative epitheliosis {149}.
2. Epithelial hyperplasia (papillomatosis {2429}; epitheliosis {149}) of the collecting ducts.
3. Lesions composed of a combination of epithelial hyperplasia and sclerosing adenosis.

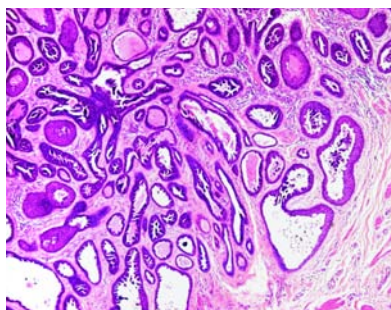


Fig. 1.156 Adenoma of the nipple. There is no significant epithelial proliferation in the tubules in this case.

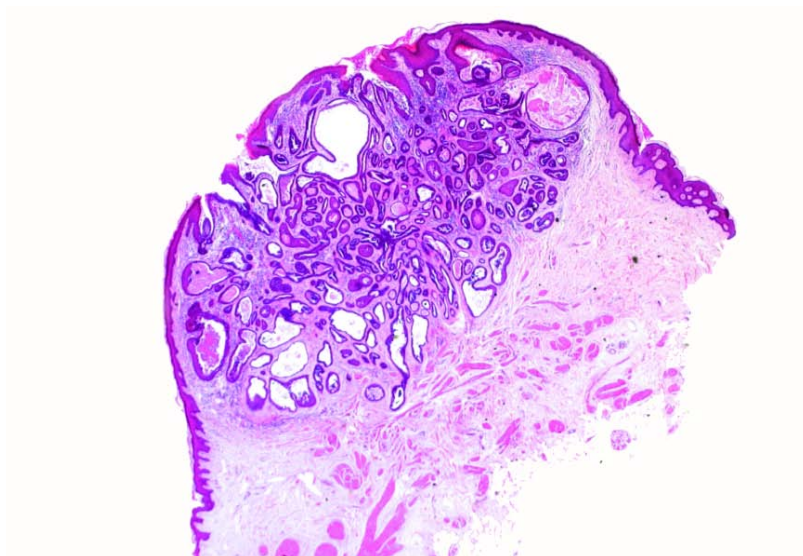


Fig. 1.155 Adenoma of the nipple. A compact aggregate of tubules replaces the nipple stroma.

Epidemiology

NA is rare with a wide age range from 20 to 87 years) {2894} and may occur in males {2429}.

Clinical features

Presenting symptoms are most frequently a sanguineous or serous discharge and occasionally erosion of the nipple or underlying nodule {2222}.

Histopathology

In the adenosis type, proliferating two cell layered glands sprout from and compress the collecting ducts {2222} resulting in cystic dilatation of the latter and formation of a discrete nodule. The epidermis may undergo hyperkeratosis. Rarely the adenosis expands to cause erosion of the epidermis {2429}. When the sclerosis and pseudoinfiltrative patterns are prominent, an invasive carcinoma is closely simulated. The background stroma shows loose myxoid features, large collagenous bands or elastosis {149}.

Epithelial hyperplasia may be florid within the tubules of adenosis or mainly within the collecting ducts. Enlargement of the galactophore ostia and exposure of the epithelial proliferation to the exterior in a fashion reminiscent of "ectropion" of the uterine cervix may occur.

Prognosis and predictive factors

Occasional recurrences have been described after incomplete excision {2425}. Association with carcinoma has been reported but is rare {1367, 2429}.

Syringomatous adenoma

Definition

A non metastasizing, locally recurrent, and locally invasive tumour of the nipple/areolar region showing sweat duct differentiation.

ICD-O code 8407/0

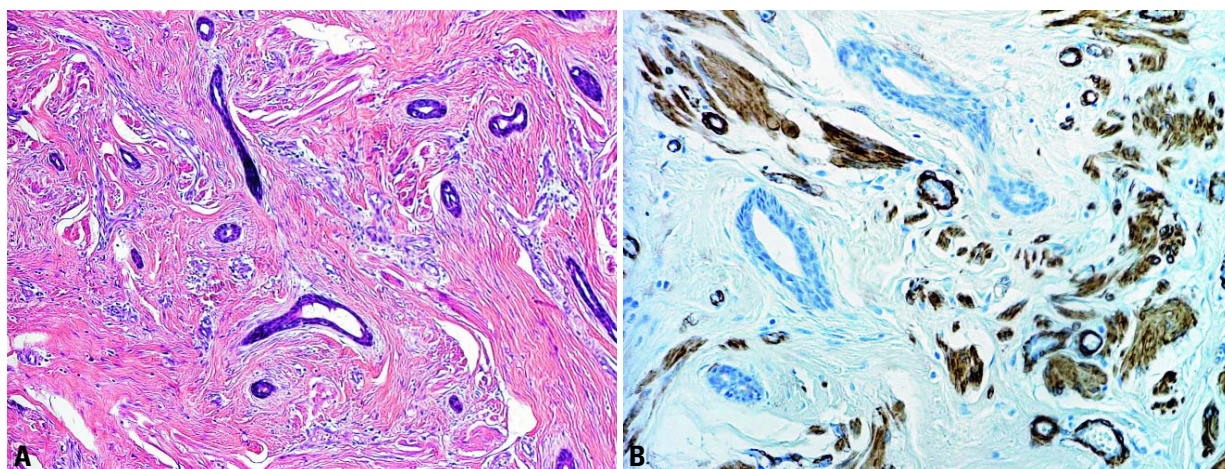


Fig. 1.157 Syringomatous adenoma of the nipple. **A** Irregular shaped glandular structures are present between smooth muscle bundles. **B** Actin stains the fascicles of smooth muscle but the syringoma is unstained.

Synonym

Infiltrating syringomatous adenoma.

Epidemiology

Syringomatous adenoma (SyT) is a rare lesion [1365,2414,2816]. While only 24 cases have been reported under this designation [98], other cases have been reported as examples of low grade adenosquamous carcinoma [2431,2816, 2995]. The age range is from 11 to 67 years with an average age of 40 years.

Clinical features

SyA presents as a firm discrete mass (1–3 cm) situated in the nipple and sub-areolar region [269,1365].

Macroscopy

The lesion appears as a firm, ill defined nodule.

Histopathology

SyA consists of nests and branching cords of cells, glandular structures and small keratinous cysts permeating the nipple stroma in between bundles of muscle as well as in perineural spaces [1365,3056]. Extensions of the tumour may be present at a great distance from the main mass with intervening normal tissue. Cytologically, most of the proliferating elements appear bland with scant eosinophilic cytoplasm and regular round nuclei. The cells lining the gland lumina are cuboidal or flat. Frequently the glandular structures display two layers of cells: i.e. inner luminal and outer

cuboidal basal cells occasionally containing smooth muscle actin. Mitoses are rare and necrotic areas are absent. The stroma is usually sclerotic, but myxoid areas containing spindle cells are frequent.

Differential diagnosis

This includes tubular carcinoma (TC) which rarely involves the nipple and low grade adenosquamous carcinoma which occurs in the breast parenchyma [2431].

Prognosis and predictive factors

Recurrence has been reported [269]. Optimal treatment is excision with generous margins.

Paget disease of the nipple

Definition

The presence of malignant glandular epithelial cells within the squamous epithelium of the nipple, is almost always associated with underlying intraductal carcinoma, usually involving more than one lactiferous duct and more distant ducts, with or without infiltration, deep in the underlying breast. Paget disease (PD) of the nipple without an underlying carcinoma is rare.

ICD-O code 8540/3

Epidemiology

PD may be bilateral and may occur in either gender but at a relatively higher

rate in men. The incidence is estimated at 1–4.3% of all breast carcinomas.

Aetiology

The glandular nature of the neoplastic cells in PD is confirmed by electron microscopic studies that show intracytoplasmic lumen with microvilli [2505]. Immunohistochemical studies confirm that Paget cells have the same phenotype as the underlying intraductal carcinoma cells [530,1423]. Suggested mechanisms of development are: a) intraepithelial epidermotropic migration of malignant cells of intraductal carcinoma to the epidermis; b) direct extension of underlying intraductal carcinoma to the nipple and overlying skin; and c) in situ neoplastic transformation of multi-potential cells located in the basal layer of the lactiferous duct and epidermis.

Clinical features

Depending on the extent of epidermal involvement, the skin may appear unremarkable or show changes ranging from focal reddening to a classical eczematous appearance, which may extend to the areola and adjacent epidermis. There is sometimes retraction of the nipple.

Histopathology

In the epidermis, there is proliferation of atypical cells with large nuclei and abundant clear or focally dense cytoplasm. They are disposed in small clus-

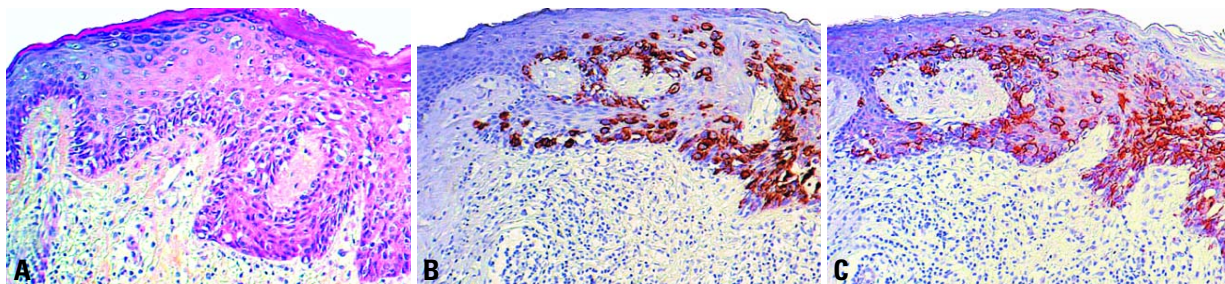


Fig. 1.158 Paget disease of the nipple. **A** Atypical cells with clear cytoplasm admixed with those with dense cytoplasm. **B, C** Immunostaining for cytokeratin 7 (**B**) and ERBB2 (**C**) decorate the neoplastic cells predominantly located in the lower portion of the epidermis.

ters which are often closely packed in the centre of the lesion and lower portion of the epidermis but tend to be dispersed in single cells at the periphery and upper portion of the epidermis. The underlying lactiferous ducts contain a usually high grade DCIS that merges with the PD. Rarely, lobular intraepithelial neoplasia is encountered. Even when the in situ carcinoma is in the deep breast tissue, an involved lactiferous duct with or without skip areas can almost always be identified by serial sectioning.

An associated infiltrating carcinoma occurs in one-third of patients who present without a palpable mass and in more than 90% of those with a palpable mass. Special stains reveal the presence of mucin in the Paget cells in a large number of cases. Paget cells occasionally

contain melanin pigment granules as a result of phagocytosis.

Immunoprofile

Immunohistochemically, Paget cells demonstrate similar properties to the underlying intraductal carcinoma cells with positive immunoreactivity for carcinoembryonic antigen, low molecular weight cytokeratin and ERBB2. On occasion, one of these antisera may be negative. Squamous carcinoma is commonly non-reactive for these antisera, but rarely may be immunoreactive for cytokeratin 7 [3128]. Contrary to malignant melanoma, PD is usually S-100 protein and HMB45 negative. In PD, TP53 and estrogen receptor may be negative or positive, depending on the immunoprofile of the corresponding underlying carcinoma.

Differential diagnosis

PD occasionally poses differential diagnostic problems with malignant melanoma due to the pagetoid pattern of spread and the presence of pigment granules and also with squamous cell carcinoma in situ, due to the proliferation of atypical dark cells. The application of histochemical techniques and the use of immunostains will solve the question in most cases.

Prognosis and predictive factors

The prognosis is dependent on the presence or absence of underlying intraductal carcinoma and associated invasive carcinoma in the deep breast tissue.

Malignant lymphoma and metastatic tumours

J. Lamovec
A. Wotherspoon
J. Jacquemier

Malignant lymphoma

Definition

Malignant lymphoma of the breast may present as a primary or secondary tumour; both are rare. There is no morphological criterion to differentiate between the two [117,1792].

The criteria for defining and documentation of primary breast lymphoma, first proposed by Wiseman and Liao [3136] and, with minor modifications, accepted by others, are as follows:

1. Availability of adequate histological material.
2. Presence of breast tissue in, or adjacent to, the lymphoma infiltrate.
3. No concurrent nodal disease except for the involvement of ipsilateral axillary lymph nodes.
4. No previous history of lymphoma involving other organs or tissues.

As such criteria seem too restrictive and leave no room for primary breast lymphomas of higher stages, some authors include cases in which the breast is the first or major site of presentation, even if, on subsequent staging procedures, involvement of distant nodal sites or bone marrow is discovered [359,1261,1753].

Epidemiology

Primary breast lymphoma may appear at any age, but the majority of patients are postmenopausal women. A subset of patients is represented by pregnant or lactating women with massive bilateral breast swelling; most of these cases were reported from Africa [2643] although non-African cases are also on record [1753]. The disease is exceedingly rare in men [2540].

Clinical features

Clinical presentation of primary breast lymphoma usually does not differ from that of breast carcinoma. It usually presents with a painless lump sometimes multinodular, which is bilateral in approximately 10% of cases. Imaging usually reveals no feature which helps to distinguish primary from secondary lymphoma [1657,2199]. The value of MR imaging in breast lymphomas has not been clearly determined [1952,1961].

Macroscopy

Primary and secondary breast lymphomas most commonly appear as a well circumscribed tumour of varying size, up to 20 cm in largest diameter. On cut surface, the neoplastic tissue is white

to white-grey, soft or firm, with occasional haemorrhagic or necrotic foci [994, 1580,1753,3136].

Histopathology

Microscopically, the majority of primary breast lymphomas are diffuse large B cell lymphomas, according to the most recent WHO classification [352,1144]. In older literature, cases designated as reticulum cell sarcoma, histiocytic lymphoma and at least some lymphosarcoma cases would nowadays most probably be included in the above category. More recently, such lymphomas were diagnosed as centroblastic or immunoblastic by the Kiel classification or diffuse large cell cleaved or noncleaved and immunoblastic lymphomas by the Lukes-Collins classification and Working Formulation [18,296,534,706,994,1261, 1346,1580,1665].

A minor proportion of primary lymphomas of the breast reflect Burkitt lymphoma, extranodal marginal-zone B-cell lymphoma of mucosa associated lymphoid tissue (MALT) type, follicular lymphoma, lymphoblastic lymphoma of either B or T type, and, extremely rarely, T-cell lymphomas of variable subtypes by the current WHO classification.

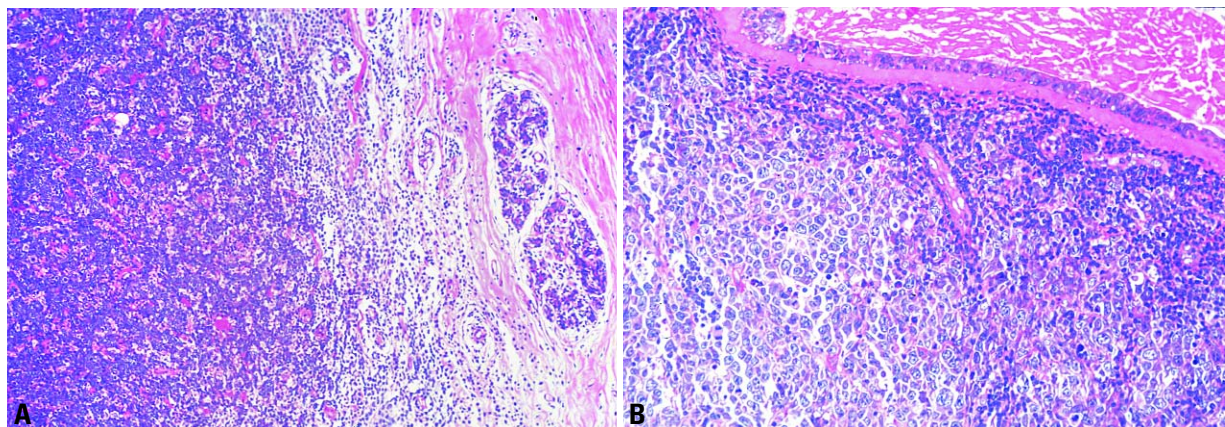


Fig. 1.159 Diffuse large B-cell lymphoma. **A** Medullary carcinoma-like appearance. **B** Circumscribed mass, composed of large pleomorphic neoplastic lymphoid cells.

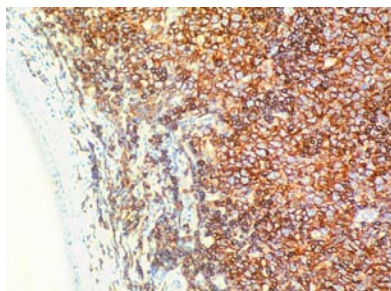


Fig. 1.160 CD20 immunoexpression in diffuse large B-cell lymphoma.

The relationship of the surrounding mammary tissue to the lymphomatous infiltration differs from case to case. In some, the bulk of the lesion is located in the subcutaneous tissue, and breast parenchyma is found only peripherally. In others, numerous ducts and lobules are embedded in the infiltrate but clearly separated from it. Sometimes lymphoma cells infiltrate the ducts to different degrees and, in rare cases, the latter are overgrown by lymphoma cells and barely visible, sometimes revealed only by using keratin immunostaining. The stroma may be scant or abundant and the infiltrates may have a “medullary” appearance. In some cases, lymphoma cells form cords and ribbons simulating an infiltrating lobular carcinoma.

Diffuse large B-cell lymphoma

ICD-O code 9680/3

Lymphoma of this type is characterized by a diffuse pattern of infiltration of breast tissue by large lymphoma cells varying in appearance from quite uniform to pleomorphic. Generally, the lymphoma cells resemble centroblasts or immunoblasts. The nuclei are oval, indented or even lobated, usually with distinct, single or multiple nucleoli, and the amount of cytoplasm is variable. Mitoses are usually numerous, various numbers of cells are apoptotic and necrotic foci may be found. Lymphoma cells are often admixed with smaller reactive lymphocytes of B or T type; macrophages may be prominent, imparting a “starry sky” appearance to the tumour. In some cases, pseudofollicular structures are seen due to selective infiltration of ductal-lobular units [18]. Adjacent mammary tissue may exhibit lobular atrophy or lymphocytic lobulitis

[18, 113]; the latter may be prominent and widespread, featuring lymphocytic mastopathy [113].

Lymphoma cells are immunoreactive for CD20, CD79a, and CD45RB and negative for CD3 and CD45RO. Cases with immunoblastic features may demonstrate light chain restriction. Exceptionally, lymphoma cells express CD30 antigen [18].

Burkitt lymphoma

ICD-O code 9687/3

The morphological features of Burkitt lymphoma of the breast are identical with those seen in such a lymphoma in other organs and tissues: the infiltrate is composed of sheets of uniform, primitive looking, cells of medium size, with round nuclei, multiple nucleoli, coarse chromatin and a rather thick nuclear membrane. The cells are cohesive and the cytoplasm is moderate in amount with fine vacuoles containing lipids; it squares off with the cytoplasm of adjacent cells. Mitoses are very numerous. Numerous tingible-body macrophages are evenly dispersed among the neoplastic cells producing the characteristic, but by no means pathognomonic, “starry sky” appearance of the lymphoma. The breast tissue is usually hyperplastic and secretory.

Patients are usually pregnant or lactating women, particularly from tropical Africa where Burkitt lymphoma is endemic [2643]. Less frequently, non-endemic, sporadic cases, primarily presenting in the breasts, have been observed [1378]. Tumours typically present with massive bilateral breast swelling [2643].

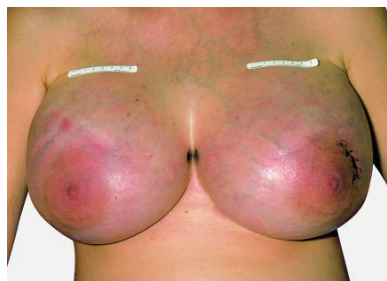

Fig. 1.161 Burkitt lymphoma. Bilateral breast involvement may be the presenting manifestation during pregnancy and puberty. BL cells have prolactin receptors.

Immunohistochemically, pan-B markers are positive, surface Ig, usually of IgM type, is also positive. In addition, CD10 and bcl-6 are commonly positive, while CD5, bcl-2 and TdT are negative. EBV is frequently demonstrated in endemic but not in sporadic cases. IgH and IgL genes are rearranged.

Extranodal marginal-zone B-cell lymphoma of MALT type

ICD-O code 9699/3

At least some breast lymphomas appear to belong to the category of MALT lymphomas although the data on their frequency vary substantially. The breast was suggested to be one component of a common mucosal immune system [268] and may acquire lymphoid tissue as a part of an autoimmune process [2585] within which the lymphoma may develop. A number of recent series on breast lymphoma include examples of MALT lymphoma [534,994,1261,1580,1792]; they were not encountered in other series [117, 296,1346,1665].

Classically, MALT lymphomas are composed of small lymphocytes, marginal zone (centrocyte-like) and/or monocytoid B-cells, often interspersed with larger blastic cells. Monotypic plasma cells may be numerous and sometimes predominant. The infiltrate is diffuse and neoplastic colonization of pre-existent reactive follicles may be seen. A lymphoepithelial lesion, defined originally as an infiltration of glandular epithelium by clusters of neoplastic centrocyte-like cells [1305], is rarely seen. Neoplastic infiltration and destruction of mammary ducts by lymphoma cells, most commonly encountered in large B-cell lymphomas or infiltration of ductal epithelium by non-neoplastic T cells should not be confused with a true lymphoepithelial lesion. However, the presence of such a lesion is not a prerequisite for a diagnosis of MALT lymphoma.

Inflammatory reactive conditions may mimic MALT lymphomas; perhaps many cases previously described as pseudolymphoma were in reality MALT lymphomas given enough time to follow their evolution.

Immunohistochemically, MALT lymphoma expresses pan-B cell markers

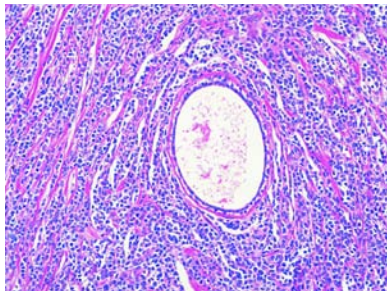


Fig. 1.162 Lymphoblastic T-cell lymphoma, secondary with lobular carcinoma-like appearance.

such as CD20 and CD79a; it is usually bcl-2 positive but negative for CD10, CD5 and CD23.

The translocation t(11;18)(q21;q21) has been identified in many MALT lymphomas although not in the few analysed breast cases [2125]. Furthermore, trisomy 3 has been identified in a number of MALT lymphomas at different sites but breast cases were not included in the study [3157].

Follicular lymphoma

ICD-O code 9690/3

Follicular lymphoma is another type of lymphoma, which is included in recent primary breast lymphoma series [113, 296,534,994,1261,1346,1580,1665,1792]. It features neoplastic follicles composed of centrocytes and centroblasts in different proportions and may be either grade 2 or 3, depending on the number of centroblasts inside the neoplastic follicles.

Immunohistochemically, the lymphoma cells show positivity for pan B antigens, CD10 and bcl-2 but are negative for CD5 and CD23. Follicular dendritic cells in tight clusters positive for CD21 delineate neoplastic follicles

Differential diagnosis

Malignant lymphoma of the breast may, on routine haematoxylin and eosin stained slides without using immunohistochemical methods, be misdiagnosed as carcinoma, particularly infiltrating lobular or medullary carcinoma [18]. In addition, some cases of granulocytic sarcoma (myeloid cell tumour) may be confused with T cell lymphomas if only a limited number of immunoreactions are

used. Inflammatory conditions in the breast may mimic MALT lymphoma.

Prognosis and predictive factors

Primary breast lymphomas behave in a way similar to lymphomas of corresponding type and stage in other sites.

Metastasis to the breast from extramammary malignancies

Epidemiology

Metastatic involvement of the breast is uncommon as an initial symptom of a non-mammary malignant neoplasm [2424] accounting for 0.5-6% of all breast malignancies [982,3029]. Women are affected five to six times more frequently than men are [982,3029].

The clinically reported incidence is lower than that found at autopsy. It is also higher when lymphoma and leukaemia are included [2940,3029]. Metastases within the breast are more frequent in patients with known disseminated malignancy (25-40%) [2424].

After lymphoma and leukaemia, malignant melanoma [2135,2424,2872,3020,3163] is the most common source from an extramammary site followed by rhabdomyosarcoma in children or adolescents [393,1129], and tumours of lung, ovary, kidney, thyroid, cervix, stomach and prostate [344,393,982,1111,1129,1530,1758,2134,2481,3020,3029,3038].

Clinical features

The patient usually presents with a palpable lesion, generally well circumscribed and rapidly growing to a size of 1-3 cm. Tumours are solitary in 85% of cases [2424], usually situated in the upper outer quadrant [778] and located superficially. The lesions may be bilateral (8-25%) [982] or multinodular. They can rarely simulate an inflammatory breast carcinoma [3020]. Axillary lymph node involvement is frequent [3029]. Mammographically, metastatic lesions are well circumscribed and without calcification excluding those from ovarian lesions, making mammographic differentiation from medullary or intracystic carcinoma difficult [1758,2134,3038].

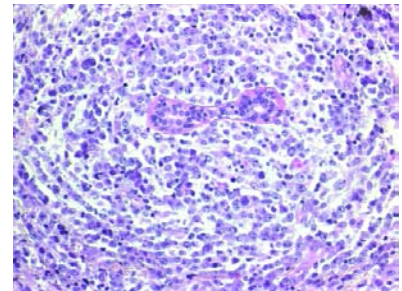


Fig. 1.163 Diffuse large cell lymphoma, secondary to the breast.

Macroscopy

Typically the tumour is nodular, solitary and well circumscribed.

Multinodularity, when is present, would be an important feature favouring a metastatic carcinoma.

Histopathology

It is important to recognize that the morphology is not that of a primary mammary carcinoma and to consider the possibility of a metastasis from an extramammary primary. This is particularly crucial with the increasing use of fine needle and tissue core biopsies [982].

However, some metastatic tumours may have some similarities to primary breast neoplasms such as squamous, mucinous, mucoepidermoid, clear cell or spindle cell neoplasms, but they lack an intraductal component and are generally well circumscribed [2424].

Differential diagnosis

Immunohistochemistry is useful in separating metastatic from primary carcinoma. The expression of hormonal receptor and GCFDP-15 is in favour of a breast primary carcinoma. A panel of antibodies such as those to cytokeratin 7, 20, CA19-9, CA125, S100, vimentin and HMB45 can be helpful depending on the morphological appearance of the lesion [778,2424].

Prognosis and predictive factors

Metastatic involvement of the breast is a manifestation of generalized metastases in virtually all cases [2424,3020]. The prognosis of patients with metastatic disease in the breast is dependent on the site of the primary and the histological type [3029].

Tumours of the male breast

K. Prechtel
F. Levi
C. La Vecchia
A. Sasco
B. Cutuli

P. Pisani
H. Hoeffler
D. Prechtel
P. Devilee

Definition

Breast tumours occur much less frequently in men than in women. The most common male breast lesions are gynaecomastia, carcinoma, and metastatic cancers. Other benign or malignant lesions also occur, but much more rarely.

Gynaecomastia

Definition

Gynaecomastia is a non-neoplastic, often reversible, enlargement of the rudimentary duct system in male breast tissue with proliferation of epithelial and mesenchymal components resembling fibroadenomatous hyperplasia of the female breast.

Synonym

Fibrosis mammae virilis (no longer used).

Epidemiology

There are three typical, steroid dependent, age peaks; neonatal, adolescent (2nd/3rd decade) and the so-called male climacteric phase (6th/7th decade). There is always relative or absolute endogenous or exogenous oestrogenism. Gynaecomastia is frequent in Klinefelter syndrome and also occurs in association with liver cirrhosis, endocrine tumours and certain medications [1263, 2572].

Clinical features

Gynaecomastia generally involves both breasts but is often clinically more distinct in one. Nipple secretion is rare. There is a palpable retroareolar nodule or plaque like induration. Occasionally there is aching pain.

Macroscopy

There is generally circumscribed enlargement of breast tissue which is firm and grey white on the cut surface.

Histopathology

There is an increased number of ducts lined by epithelial and myoepithelial

cells. The surrounding cellular, myxoid stroma contains fibroblasts and myofibroblasts, intermingled with lymphocytes and plasma cells. Lobular structures, with or without secretory changes, are rare and mostly occur in response to exogenous hormonal stimulation such as transsexual estrogen therapy. This florid phase is followed by an inactive fibrous phase with flat epithelial cells and hyalinized periductal stroma. An intermediate phase with a combination of features also occurs. Occasionally, duct ectasia, apocrine or squamous metaplasia develop. An increase in the amount of adipose breast tissue alone may be called lipomatous pseudogynaecomastia.

Immunoprofile

Patients with Klinefelter syndrome exhibit elevated amounts of estrogen (ER) and progesterone (PR) receptors but other examples of gynaecomastia do not demonstrate significant elevation [2215, 2666].

In gynaecomastia induced by antiandrogen therapy, but not in carcinoma of the breast, there may be strong focal prostate specific antigen (PSA) immunoreactivity in normal or hyperplastic duct epithelium, while PSAP activity is negative. These findings should not be misinterpreted as indicating a metastasis from a prostatic carcinoma [968].

Prognosis and predictive factors

Recurrence of gynaecomastia is possible. Atypical ductal epithelial hyperplasia and carcinoma in situ are rarely seen in cases of gynaecomastia but there is no convincing evidence that gynaecomastia, per se, is precancerous.

Carcinoma

Definition

Carcinoma of the male breast is a rare malignant epithelial tumour histologically identical to that seen in the female breast. Both in situ and invasive carcinoma occur, at a ratio of about 1:25 [713].

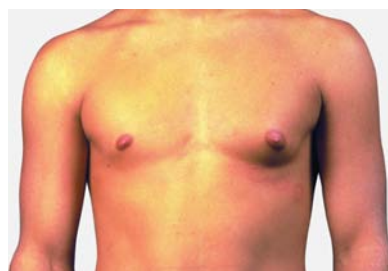

Fig. 1.164 Gynaecomastia of the male breast (left > right).

ICD-O code 8500/3

Epidemiology

Male breast cancer is extremely rare, representing less than 1% of all breast cancers, and less than 1% of all cancer deaths in men. Not surprisingly, therefore, little is known about its epidemiology. The incidence of and mortality from male breast cancer have been reported to be rising. Reviews of incidence trends in Scandinavia [814] and mortality trends in Europe [1551] give no support to the existence of such upward trends. Mortality rates, for most countries, in the late 1980s and 1990s tended to be lower than those registered three decades earlier, suggesting that advances in diagnosis and treatment may have improved the prognosis [1551].

In the 1990s, mortality rates from male breast cancer were around 2 per million

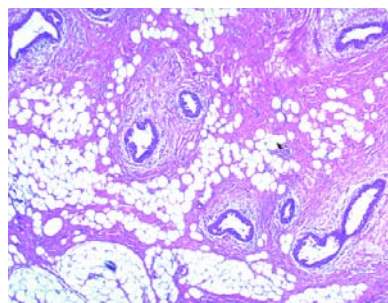


Fig. 1.165 Gynaecomastia of the male breast, with proliferating ducts and periductal stroma.

male population both in the USA and the European Union (EU). A higher incidence with a lower average age and more cases in an advanced stage is reported in native Africans and Indians {39,1281,1329,1330,2539,2985}. This is reinforced by the consistently higher incidence rates for the black compared to the white male population in the US cancer registries {2189}.

Aetiology

Some aspects of the aetiology of male breast cancer are similar to those of the much more common female counterpart. Thus, a direct association has been suggested with socio-economic class (i.e. increased risk in higher socio-economic classes) {607,1551,2539}, although this remains controversial {1627,2906}. Likewise, it has been reported that both never married men and Jewish men are at higher risk {1726,2539,2906}.

Family history of breast cancer in female and male first degree relatives has repeatedly been associated with male breast cancer risk, although quantification of relative and attributable risks on a population level remains undefined {418, 607,1185,1551,2449, 2539,2799}. It has been estimated that there is a family history in about 5% of male breast cancer patients, but these patients do not present at a younger age {1210,2297}. Hereditary factors are discussed elsewhere (see genetic chapter).

Again, as for female breast cancer, anthropometric characteristics have been investigated, and body mass index (BMI) was directly associated with male breast cancer risk {418,607, 1551,2539}. In a large case-control study {1253}, the relative risk was 2.3 for the highest quartile of BMI. This study also suggested an association with height but the relative risk was only 1.5 and of borderline significance {1253}.

Previous breast or testicular disease and gynaecomastia have been related to male breast cancer, and associations have been reported with an undescended testis {2231,2577,2906}, orchiectomy, orchitis, testicular injury, late puberty and infertility {2539}.

Male breast cancer is more common among those with Klinefelter syndrome {418,2539} and infertility or low fertility,

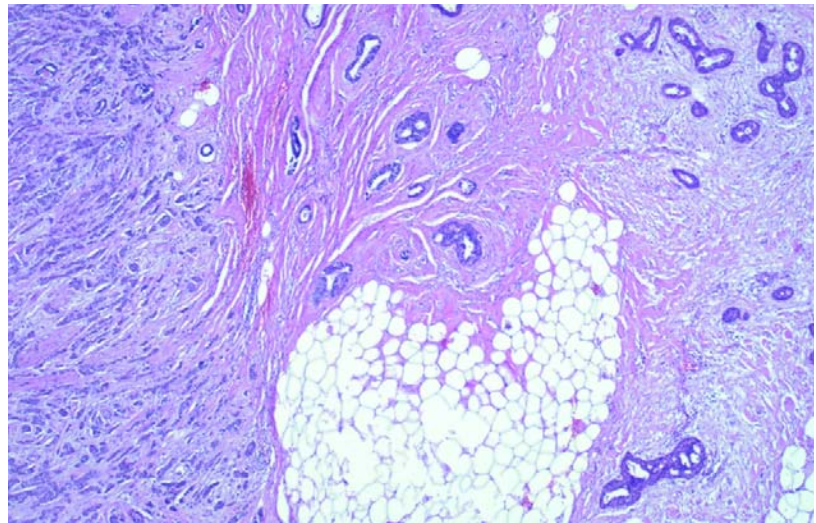


Fig. 1.166 Invasive ductal carcinoma and gynaecomastia of the male breast. Invasive carcinoma is present in the left third of the field.

possibly as a consequence of Klinefelter syndrome or other hormonal abnormalities {607,1551,2539,2906}. Similar to the role of estrogen in female breast cancer {36,225,540,1128}, high estrogen and prolactin levels have been reported as risk factors for male breast cancer {2539}, and several small studies have found higher serum or urinary estrogen levels in cases than in controls {386,2024,2107,2363}. This is supported by retrospective cohort studies in Denmark, indicating an excess occurrence of breast cancer among men with cirrhosis and relative hyperestrogenism {2755}. However, not all the results were consistent with this pattern of hormonal influence {173,3110}.

Other endocrine factors may play an important role in the aetiology {815, 1253,2539}. It has been suggested that diabetes mellitus may increase risk, possibly through hormonal mechanisms {815,1253,2539}.

Reports on lifestyle factors have shown in general no material association with smoking, alcohol or coffee consumption {1253,2231,2449}, although one study found a significant protective effect of smoking {2231}. A higher risk was associated with limited physical exercise and frequent consumption of red meat, while consumption of fruit and vegetables was related to a decreased risk, although the trends were not significant

{1253}. In another large study from ten population-based cancer registries {2449}, no trends in risk were observed with increased dietary intakes of several foods and nutrients, and no association was found with the use of any dietary supplement. Dietary factors are unlikely to be strong determinants of breast cancer in men {2449}, though moderate associations, as described for female breast cancer {1636,1639}, remain possible.

Although an association with electromagnetic field exposure has been suggested in the past {669,1784,2791}, the Report of an Advisory Group on Non-ionising Radiation to the National Radiological Protection Board (2001) concluded that there is no evidence that electromagnetic fields are related to adult male breast cancer {2355}.

Invasive carcinoma

Clinical features

The most frequent sign is a palpable sub-areolar mass. Nipple ulceration or sanguineous secretion is seen in 15–30%. In 25–50% of patients, there is fixation to or ulceration of the overlying skin. A quarter of patients complain of pain.

Male breast cancer is usually unilateral and occurs more frequently in the left breast. Synchronous bilateral tumours are found in less than 5% of cases.

Macroscopy

The majority of male breast cancers measure between 2 and 2.5 cm. Multiple separate nodules are rare as is involvement of the entire breast.

Histopathology

The histological classification and grading of male and female invasive breast carcinoma are identical, but lobular carcinoma does not usually occur in men even in those exposed to endogenous or exogenous hormonal stimulation [1855,2521,2552] and should only be diagnosed if E-cadherin expression is absent [34].

Immunoprofile

Compared to breast carcinoma in women, male breast carcinomas have a somewhat higher frequency of ER positivity in the 60-95% range, while PR positivity occurs in 45-85% of cases [315, 578,1836,1917]. The concentrations are independent of patient age and similar to those found in postmenopausal women [2297]. Androgen receptors are expressed in up to 95% of cases.

Prognosis and predictive factors

The prognosis and predictive factors are the same as for female breast cancer at comparative stages.

Metastasis to the breast

The ratio of primary breast cancer and a metastasis from another primary site to the breast is about 25:1. The most fre-

quent primaries are prostatic carcinoma, adenocarcinoma of the colon, carcinoma of the urinary bladder, malignant melanoma and malignant lymphoma.

Carcinoma and sarcoma secondary to previous treatment

As in women, carcinoma following previous chemotherapy and/or irradiation has been reported [326,601], as has post irradiation sarcoma [2644].

Carcinoma in situ

ICD-O code 8500/2

Clinical features

In the absence of mammographic screening in men, the two most frequent symptoms are sero-sanguineous nipple discharge and/or subareolar tumour.

Histopathology

The histological features are in general similar to those in the female breast but two major studies have found that the most frequent architectural pattern is papillary, while comedo DCIS occurs rarely [602,1221]. Lobular intraepithelial neoplasia is also extremely rare. Paget disease may be relatively more common among men compared to women due to the shorter length of the duct system in male breast.

Other tumours

Almost all breast tumours which occur in women have also, been reported in men, albeit rarely.

Genetics in male breast cancer

Very little is currently known about the molecular events leading to the development and progression of sporadic breast cancer in males. Loss of heterozygosity (LOH) and comparative genomic hybridisation (CGH) studies and cytogenetic analysis have shown that somatic genetic changes in sporadic male breast carcinomas are quantitatively and qualitatively similar to those associated with sporadic female breast cancer [2532,2927,3134,3265]. Tumour phenotypic markers, such as ERBB2 and TP53 expression, are also

quite similar between the sexes [3129]. Ki-ras mutations are not significantly increased in male breast cancer [636]. LOH on chromosome 8p22 and 11q13 are frequently identified in male breast cancer [490,1073] suggesting that the presence of one or more tumour suppressor genes in these regions may play a role in the development or progression of the disease. LOH at 11q13 is found more often in carcinomas with positive nodal status than in carcinomas without lymph node metastasis [1073]. Frequent allelic losses on chromosome 13q are reported in familial, as well as in sporadic, male breast cancer [2296, 3134]. Chromosome 13q is the region containing the *BRCA2*, *BRUSH-1*, and retinoblastoma gene. Depending on the population, studies demonstrated that 4-38% of all male breast cancers are associated with *BRCA2* alterations [918,1550, 2921]. Other putative target genes are also situated here, including protocadherin 9 and EMK (serine/threonine protein kinase). Possibly, multiple tumour suppressor genes may influence the observed pattern of loss of heterozygosity [1383].

The role of aberrant hormone secretion or hormone receptor function in the development or progression of the disease remains controversial. Hormonal imbalances, such as those in Klinefelter syndrome or Reifenstein syndrome (mutation of the androgen receptor gene: Xq11-12) are known risk factors for breast cancer in males [427, 1213,2484]. In three men, germline mutations in the androgen receptor gene was reported including two brothers with Reifenstein syndrome [1686,3152]. However it has been shown that mutations of the androgen receptor are not obligatory for the development of male breast cancer [1213].

Cytogenetic studies reveal clonal chromosomal anomalies: Loss of the Y chromosome and gain of an X chromosome, as well as the gain of chromosome 5, are all frequently observed [1213,2484]. Taken together with previous data, the present findings suggest close similarities between the molecular pathogenesis of male and female breast cancers.

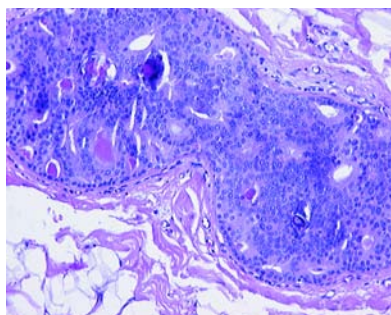


Fig. 1.167 Male breast carcinoma, DCIS. The in situ carcinomas are generally of the non-necrotic cribriform or papillary types. Though necrosis develops in some cases composed of either micropapillary or the cribriform types, true comedo DCIS is rare.