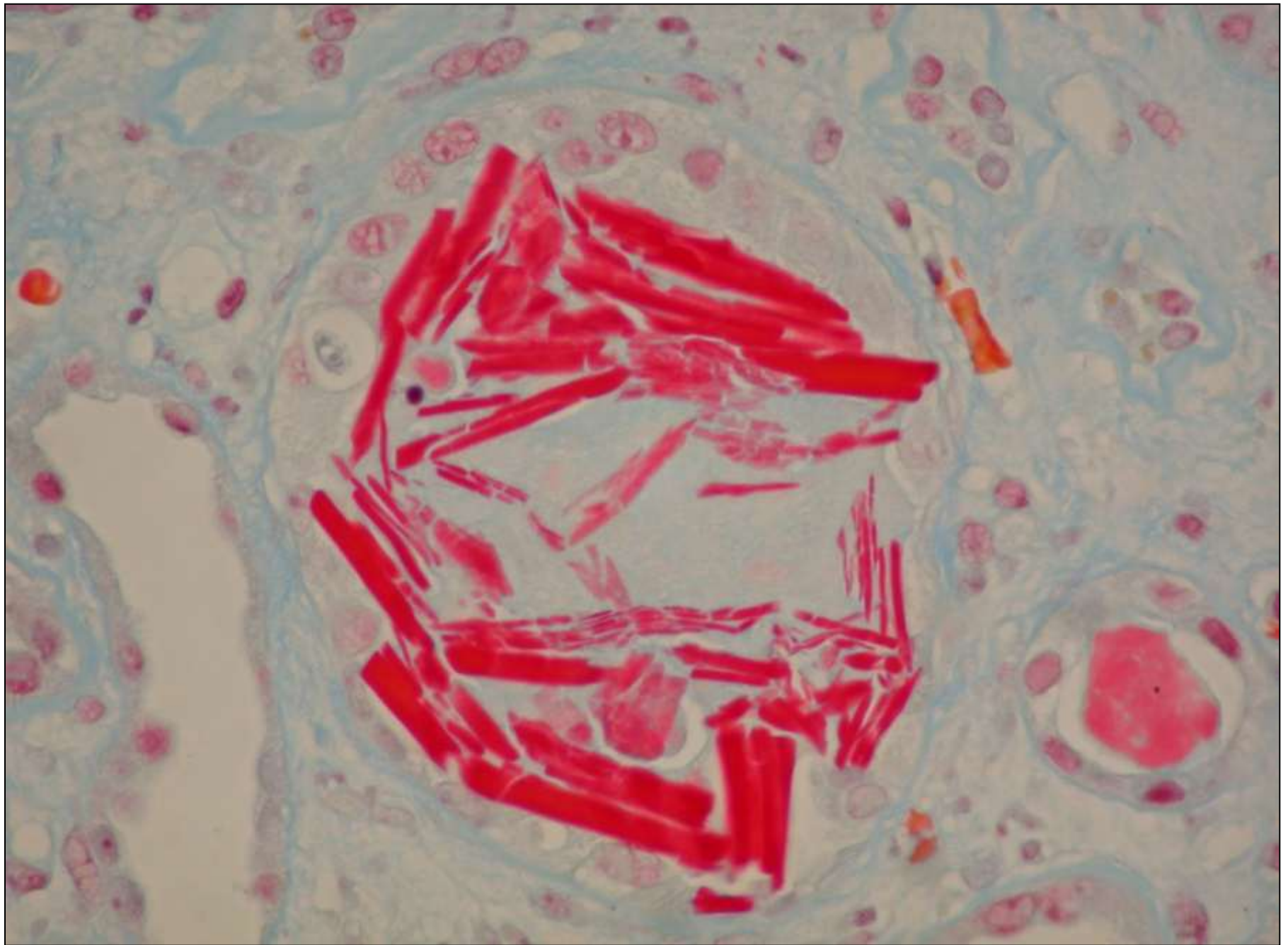


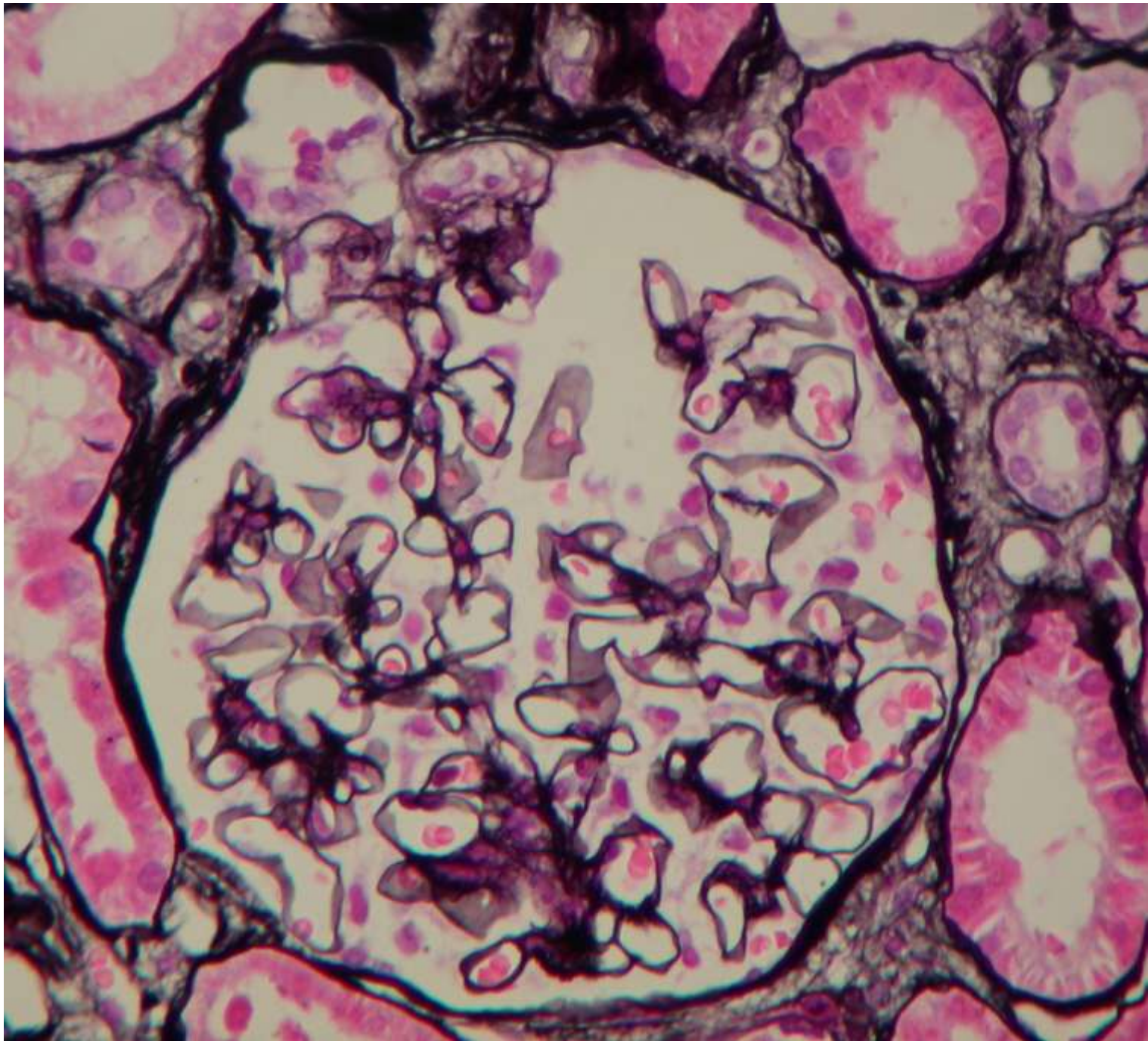
# Renal Pathology

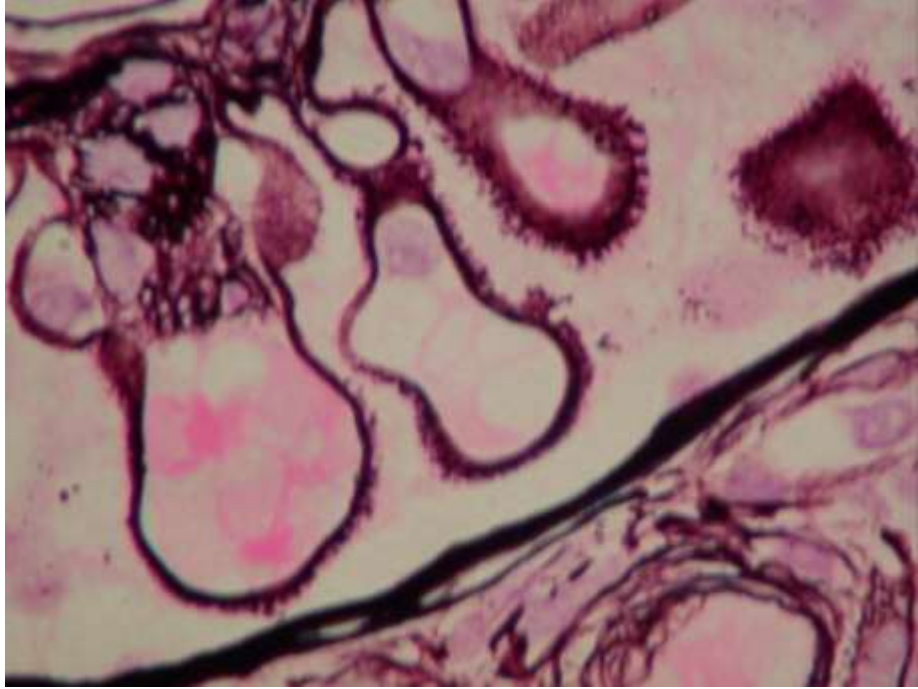
Tibor Toth

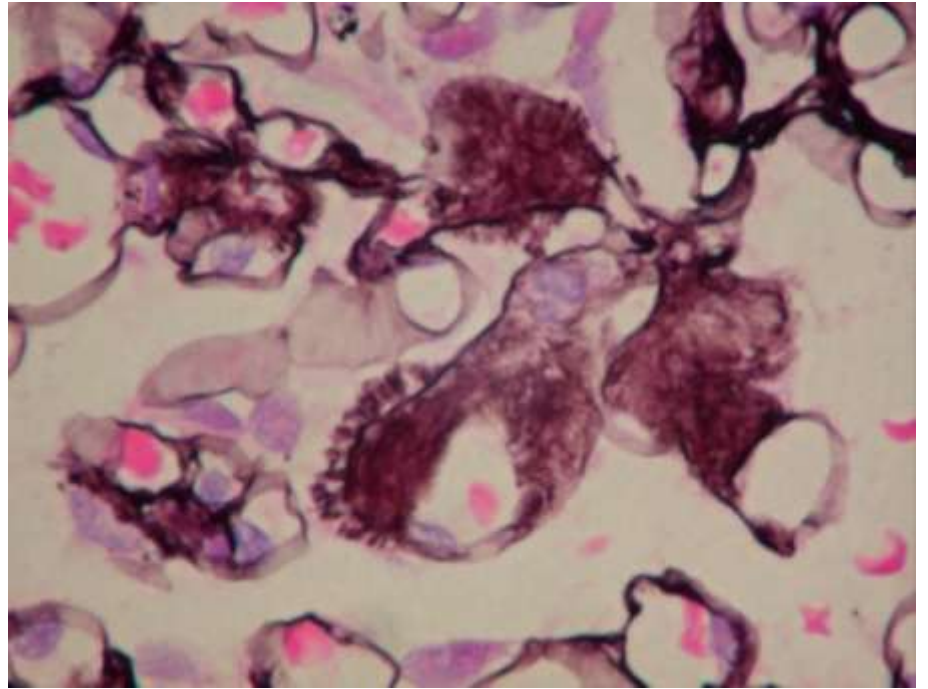
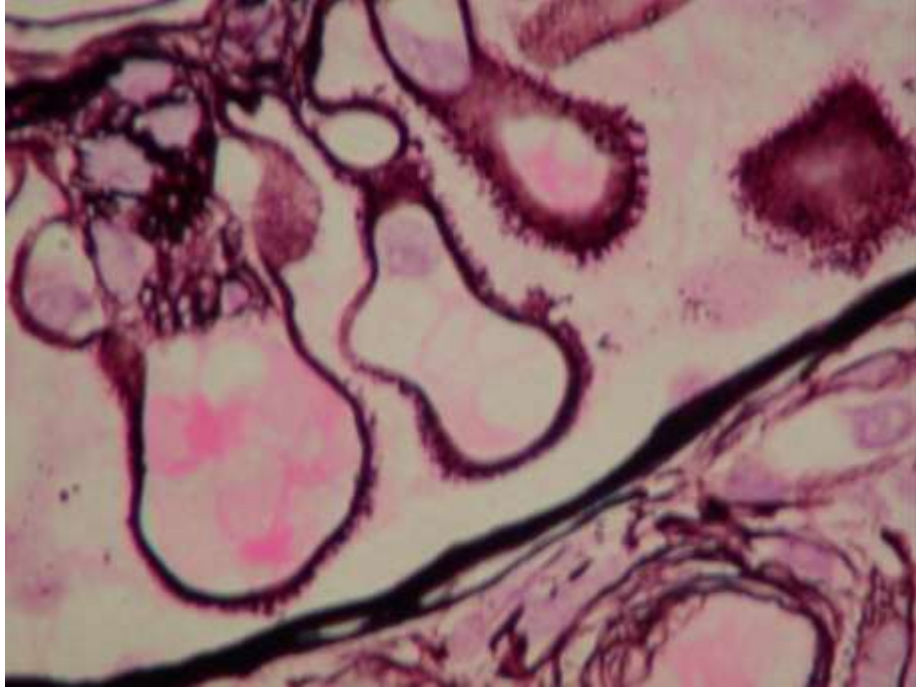
2011

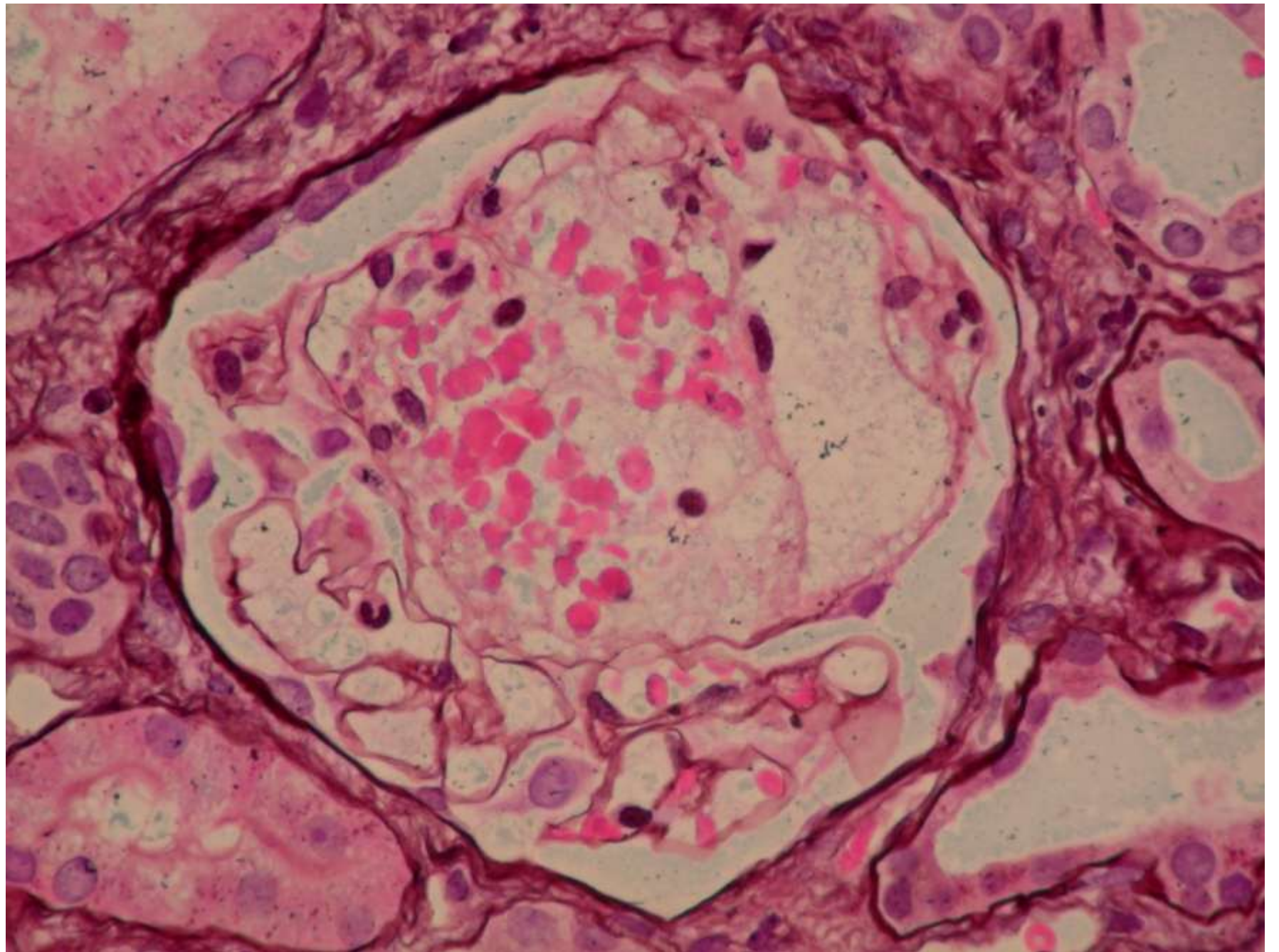
BUDAPEST

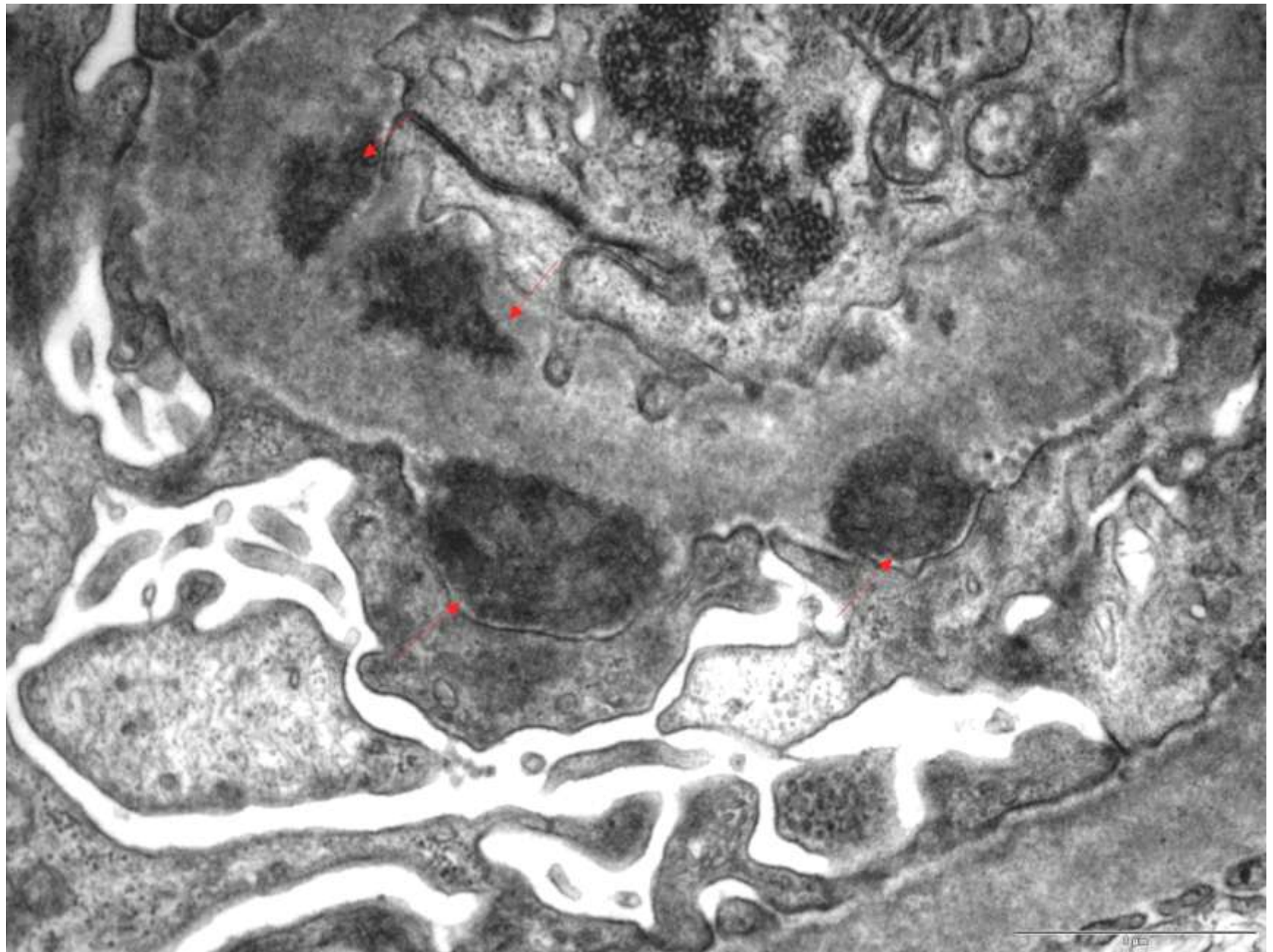


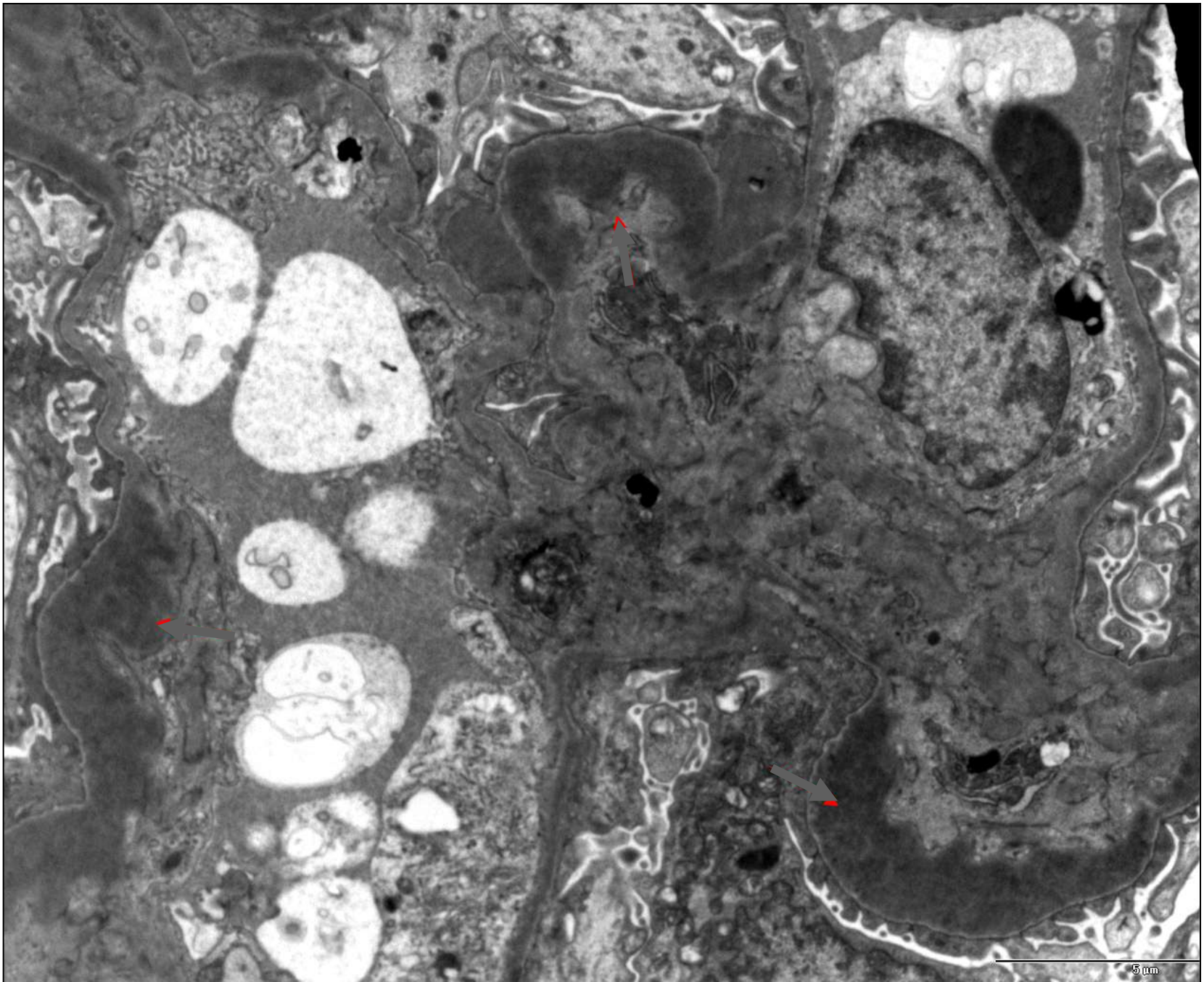
















- I. Anatomy, Histology
- II. Glomerular lesions
  - important morphologic terms
- III. Diagnostic algorithm



Your tests reveal that  
you are retaining fluids!



2 biopsy cylinders, minimal length 1 cm



Electronmicroscopy

Electronmicroscopy

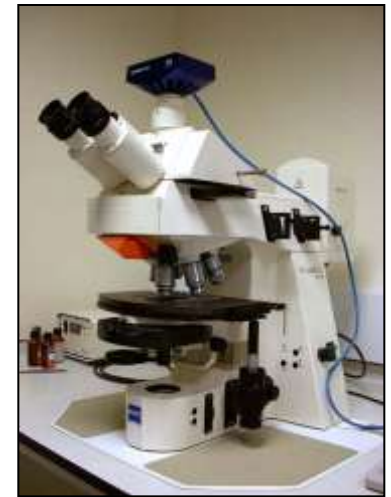Light microscopy

Immune microscopy




- HxE
- PAS
- PAAG
- Congo red
- E v Gieson
- MSB

- IgA
- IgG
- IgM
- C3
- C1q
- Kappa
- Lambda



© Original Artist  
Reproduction rights obtainable from  
[www.CartoonStock.com](http://www.CartoonStock.com)



search ID: jna0299

"Good, our side's winning!"

# Renal biopsy - Interpretation

## **Categorisation of**

glomerulonephritis,  
glomerulopathies

(*eg* diabetes mellitus, amyloid, hereditary renal disease),

interstitial nephritis,  
renal vascular disease,  
toxic nephropathy

## **Detect Acute (reversible) vs chronic (irreversible) changes**

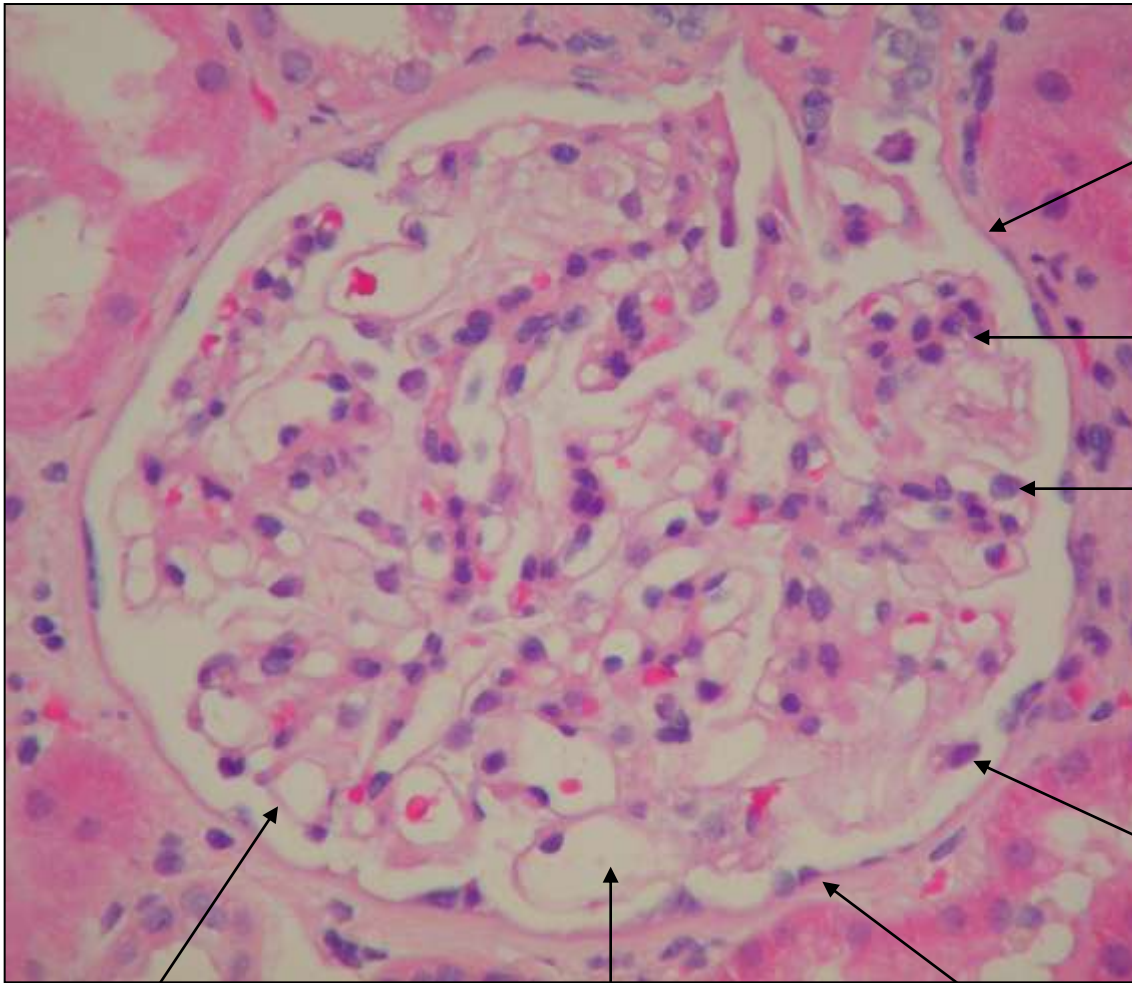
(*e.g. aggressive immune suppression yes/no*)

## **Diagnosis of superimposed second kidney disease, *e.g.***

*IgA-GN after Wegener's granulomatosis,*

*Wegener's granulomatosis + Goodpasture, etc.*

## **Monitoring transplant rejection.**



**Bowman's capsule**

**Mesangium**

**Endothelial cell**

**Podocyte**

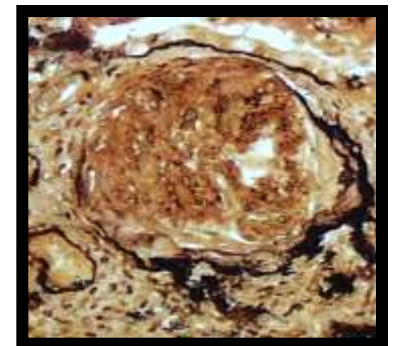
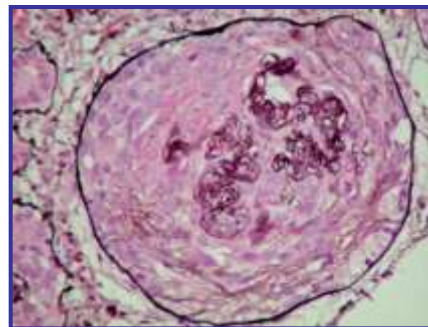
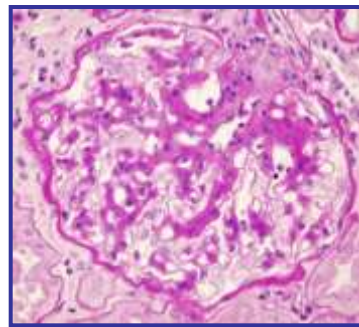
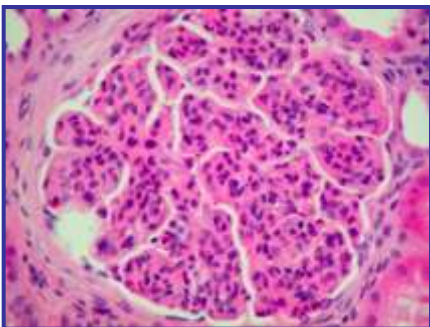
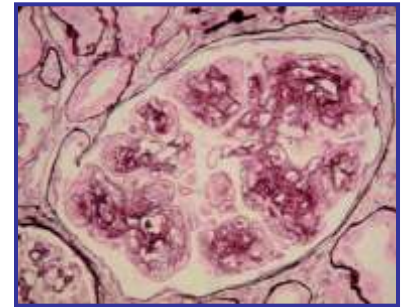
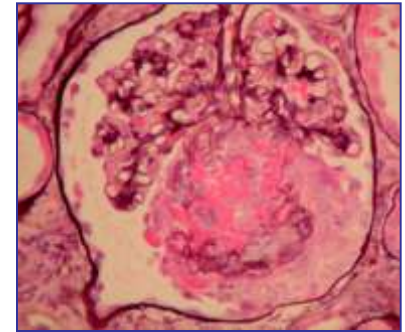
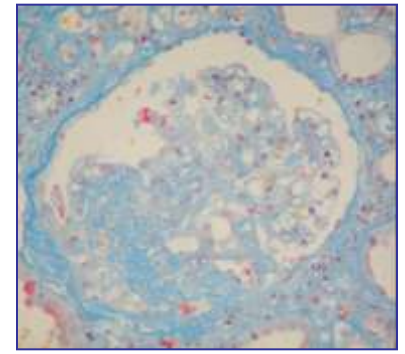
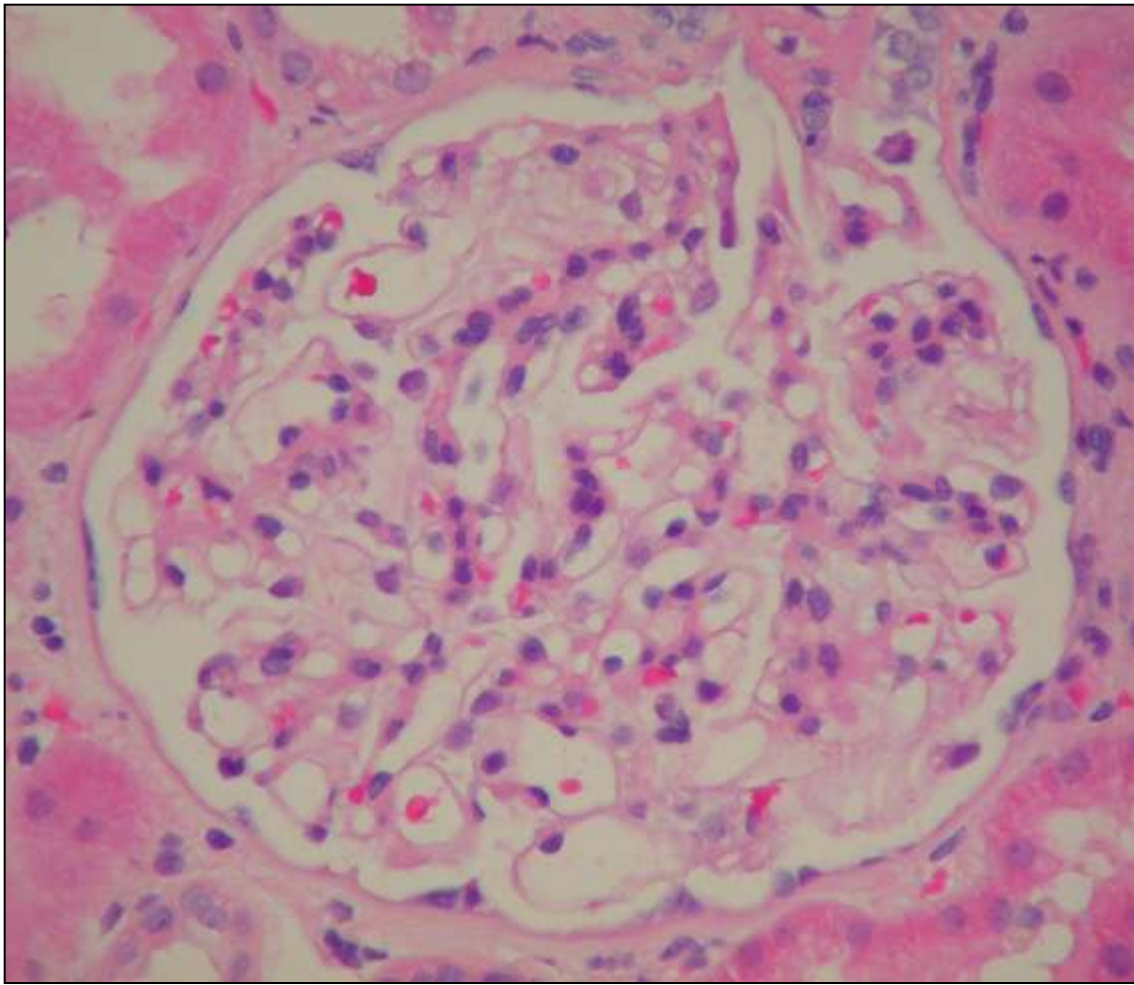
**GBM**

**Parietal  
epithelial cell**

**Capillary loop**







# Analysis of the renal biopsy sample

# Routine stains

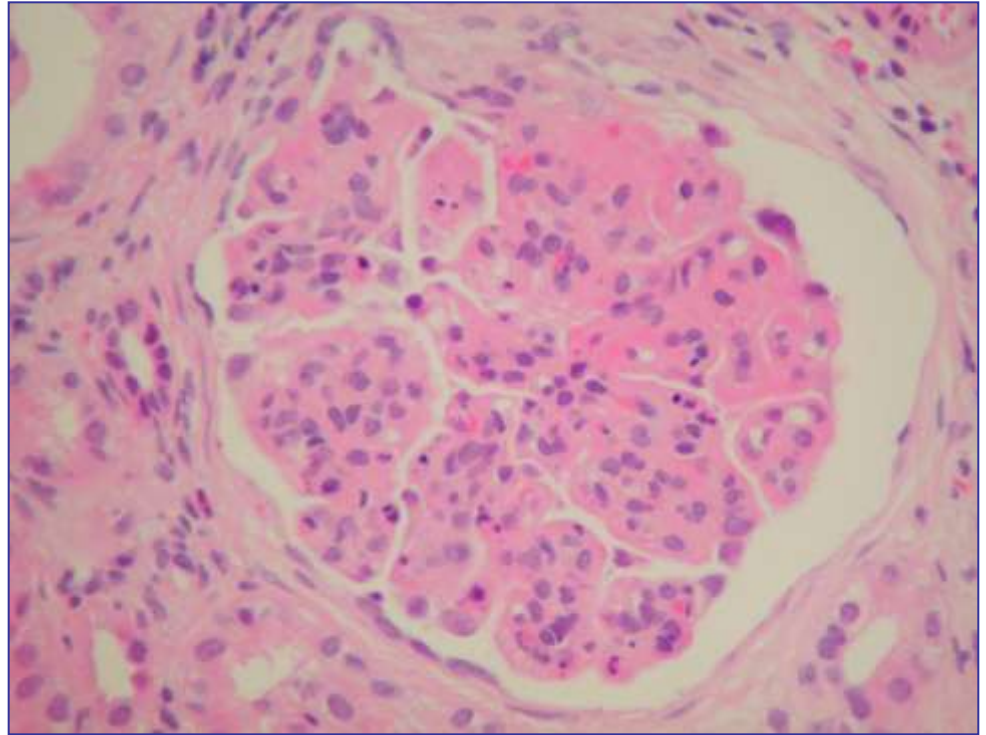
## HE-stain (*hematoxylin-eosin*)

### composition of tissue:

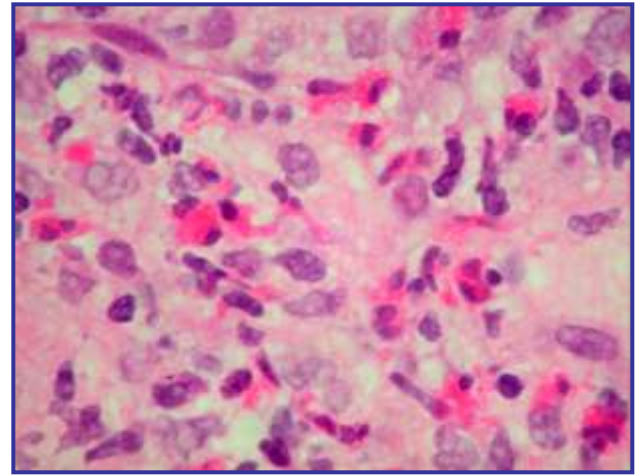
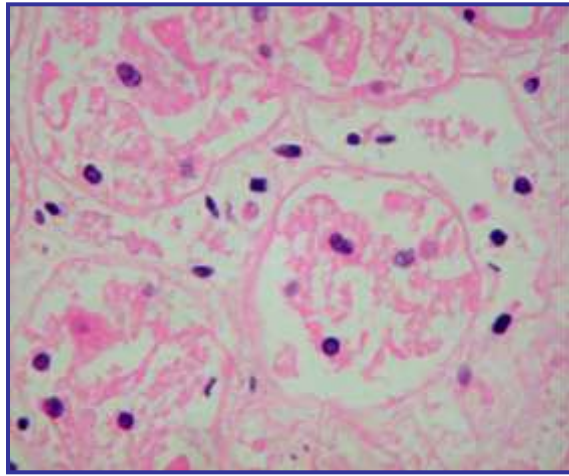
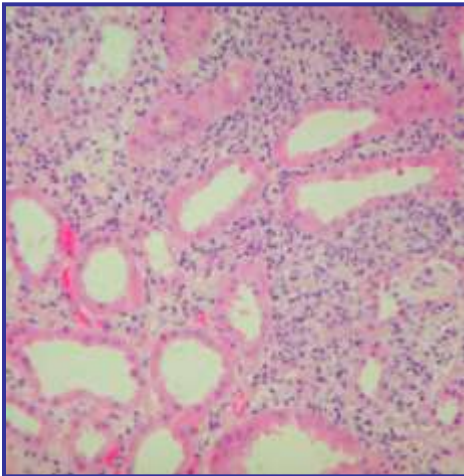
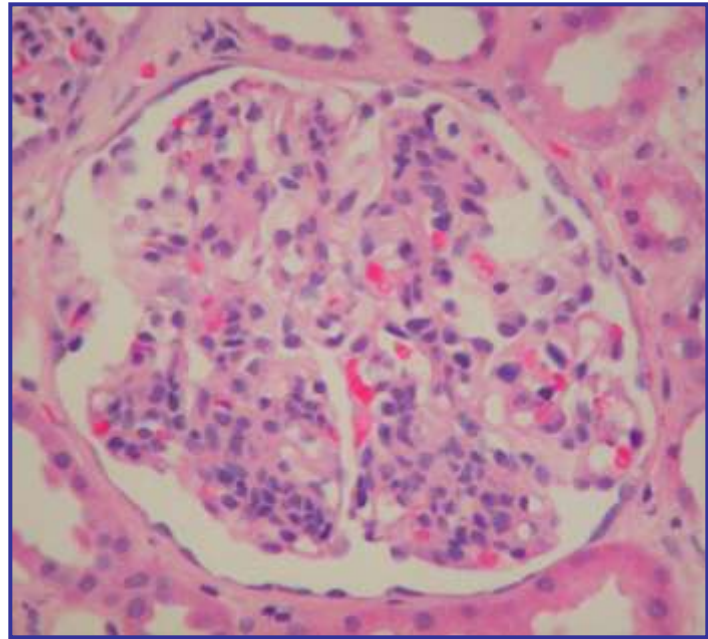
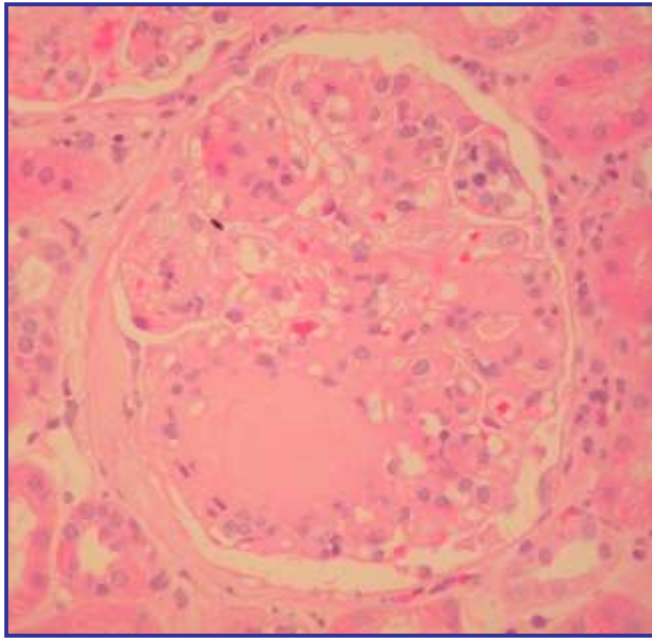
cortex vs medulla,  
number of glomeruli  
cellular infiltrates ..

### analysis of glomerulus and vessels:

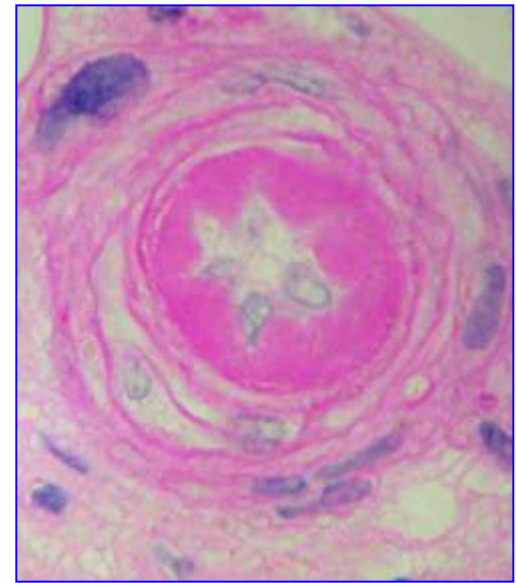
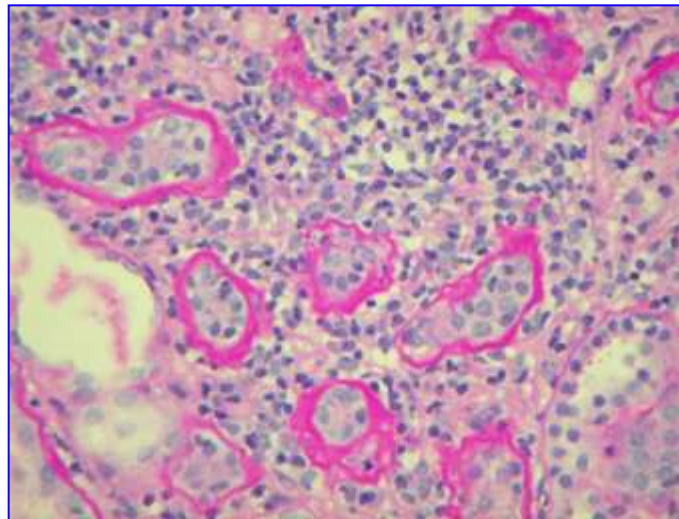
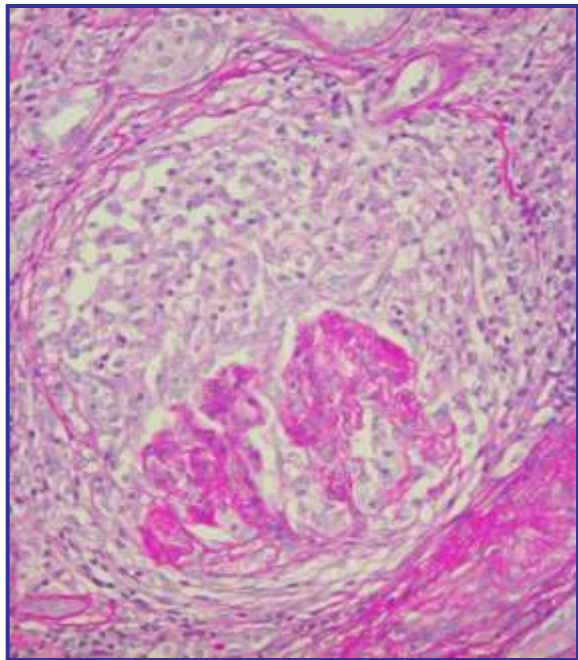
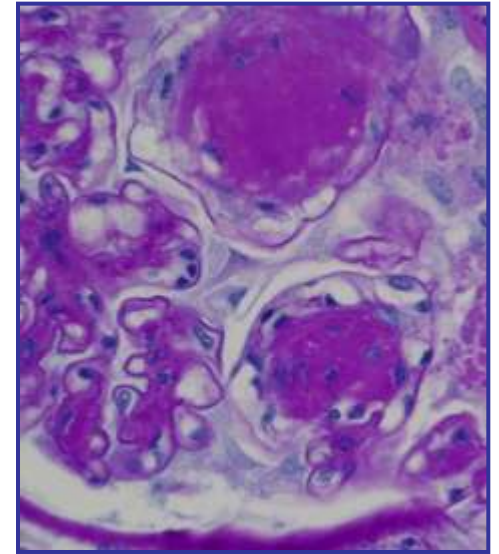
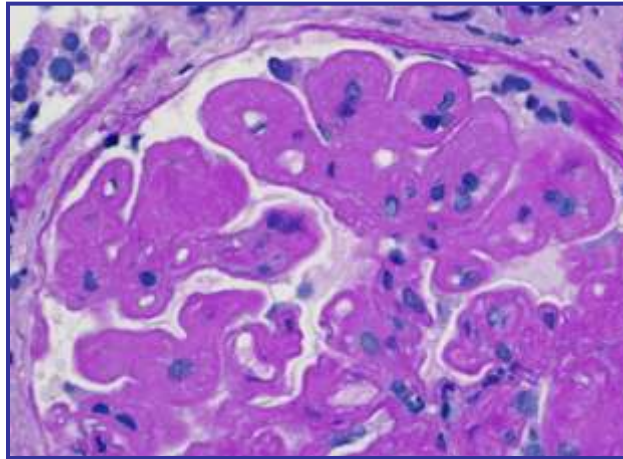
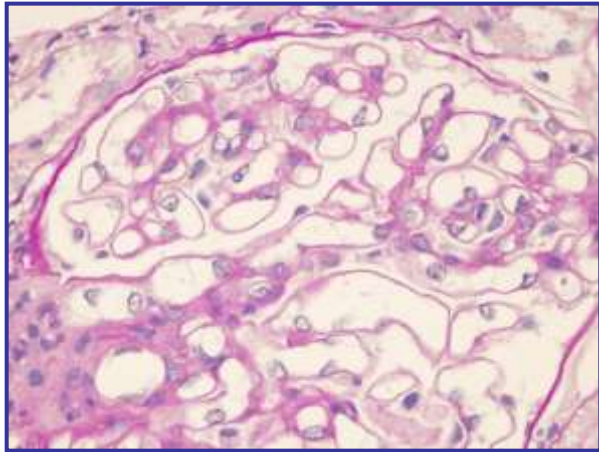
glomerular cells,  
mesangial matrix  
glomerular basement membrane



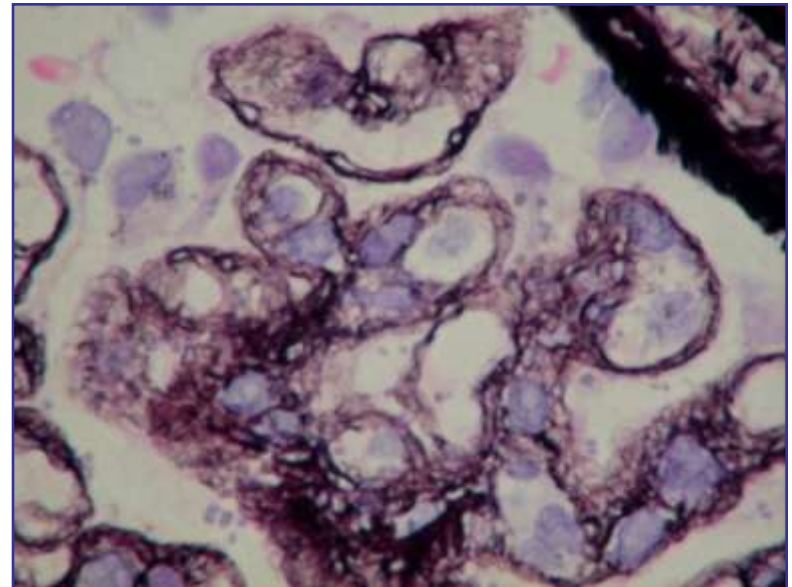
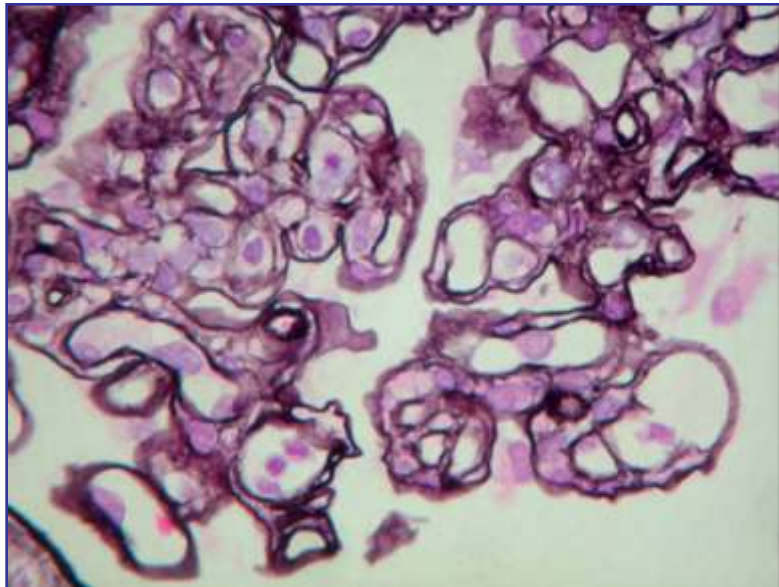
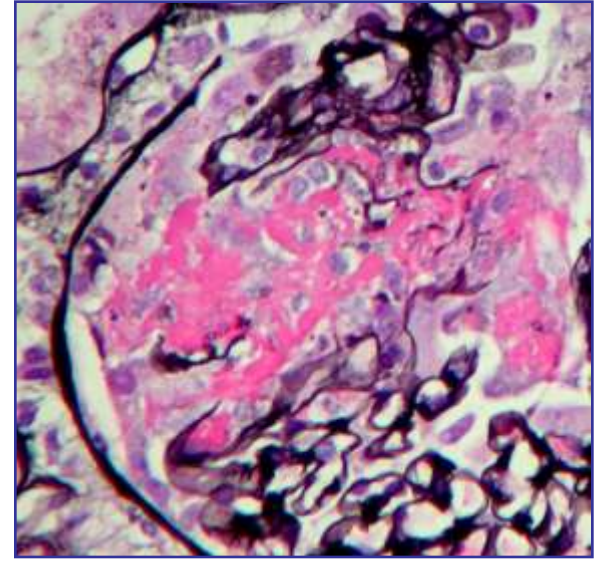
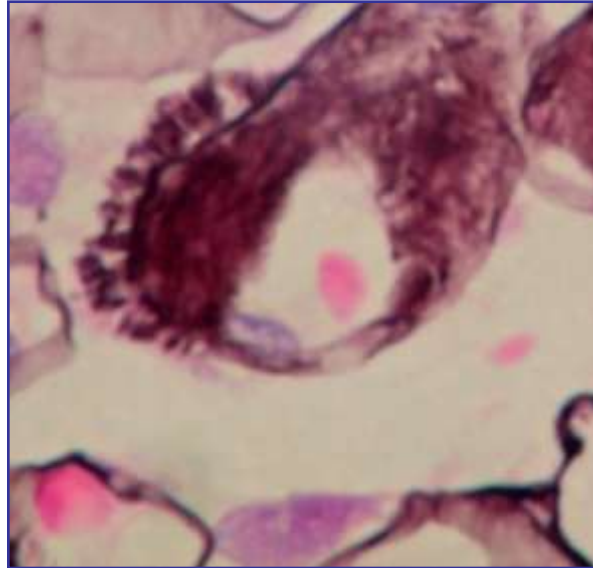
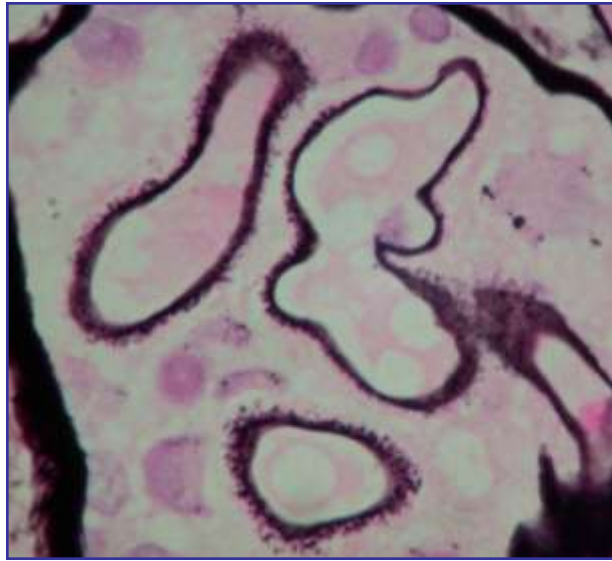# Hematoxylin and eosin(H&E)



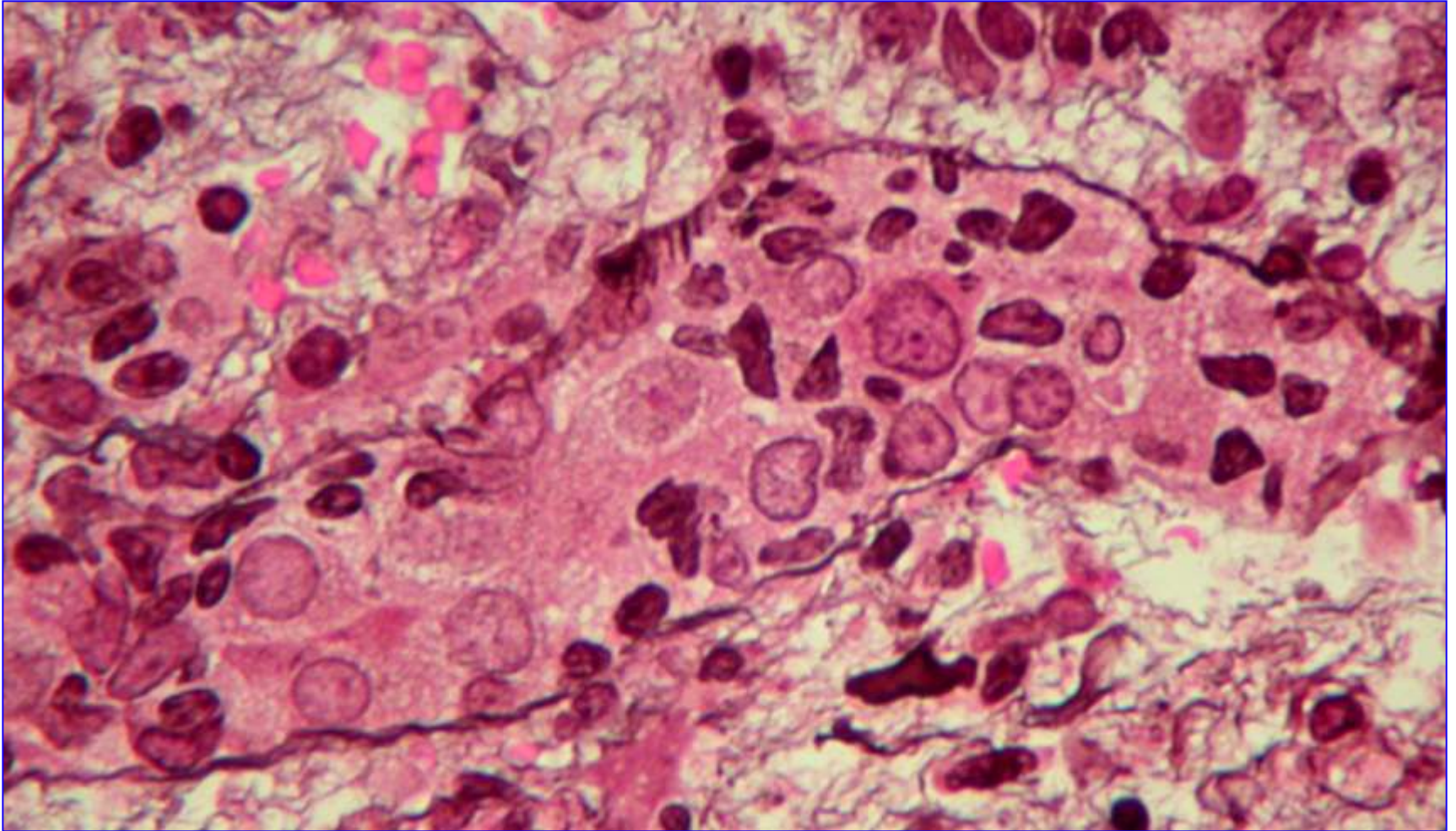
# Periodic Acid Schiff reaction



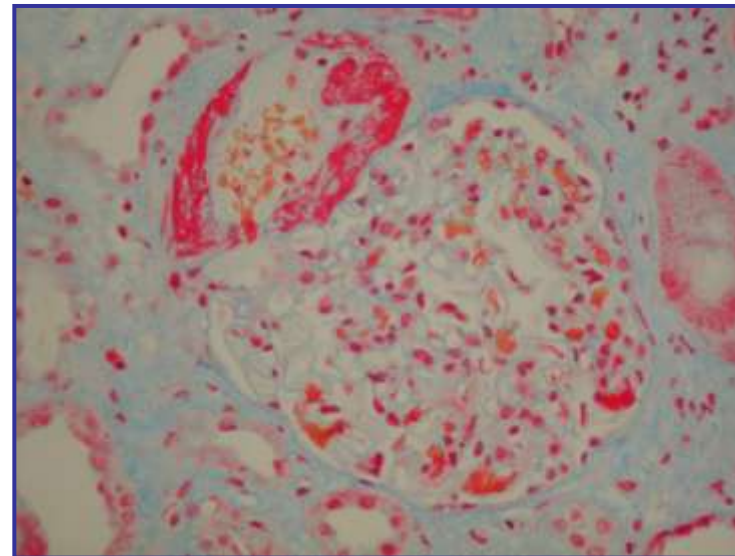
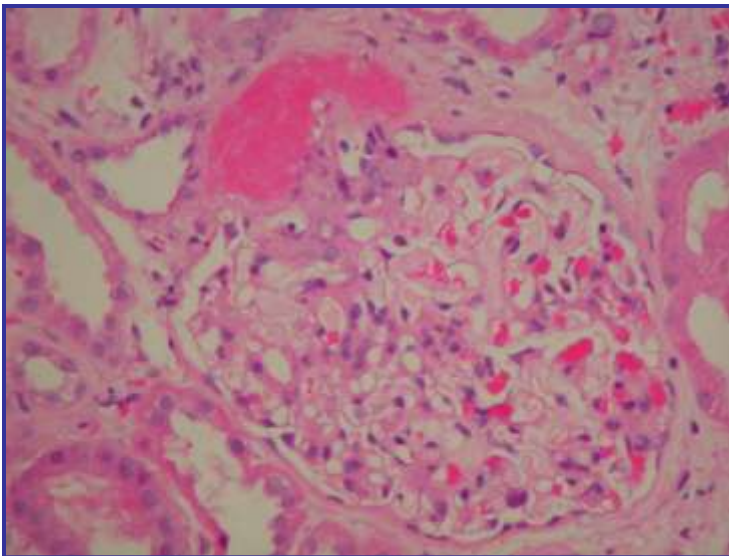
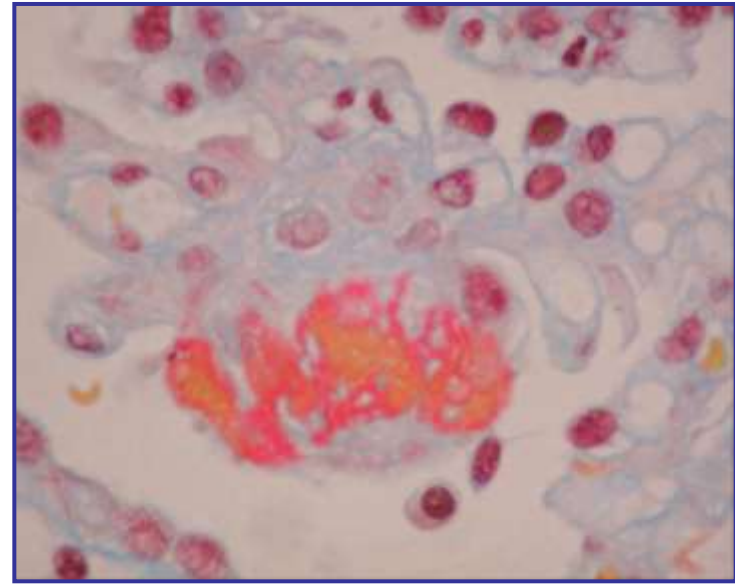
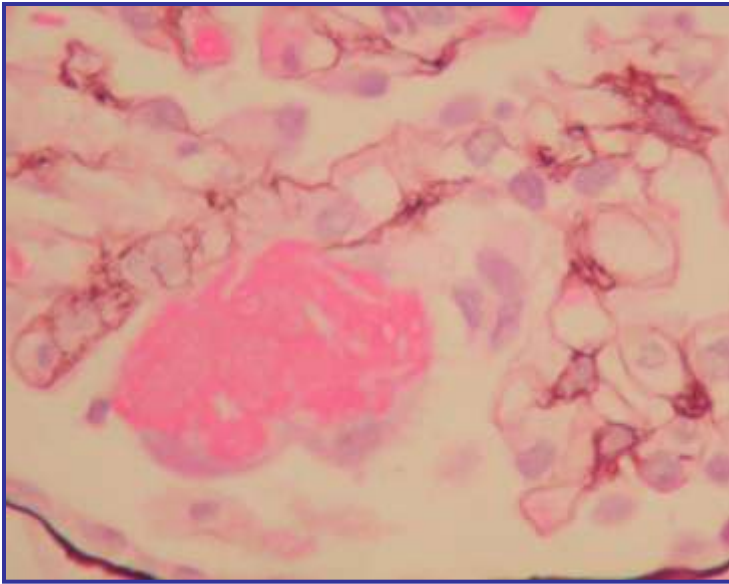
# PAAG, PA-Methenamine –silver



# PAAG, PA-Methenamine –silver

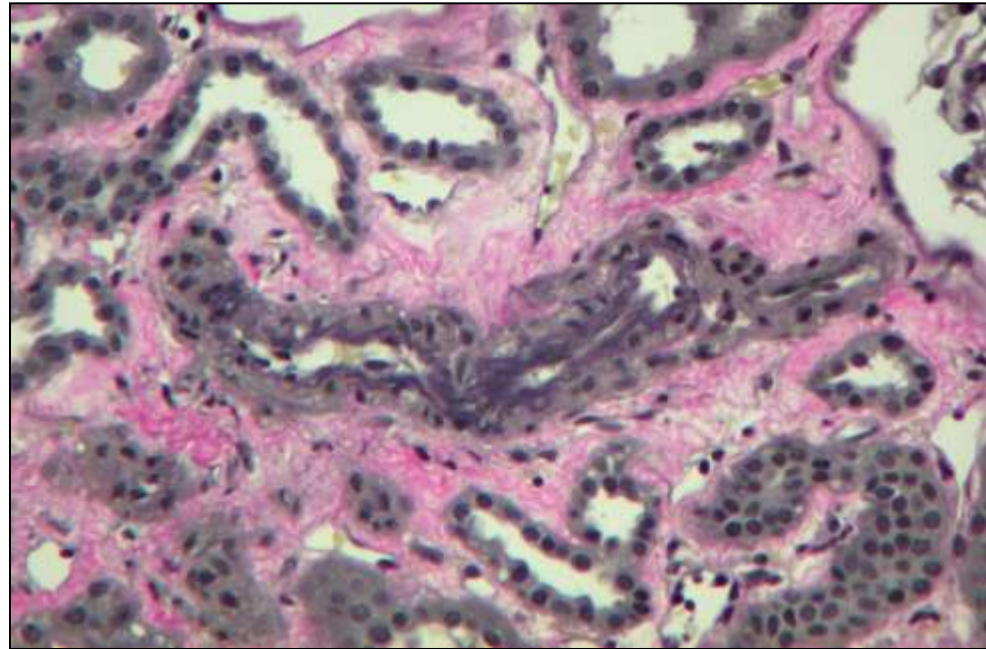
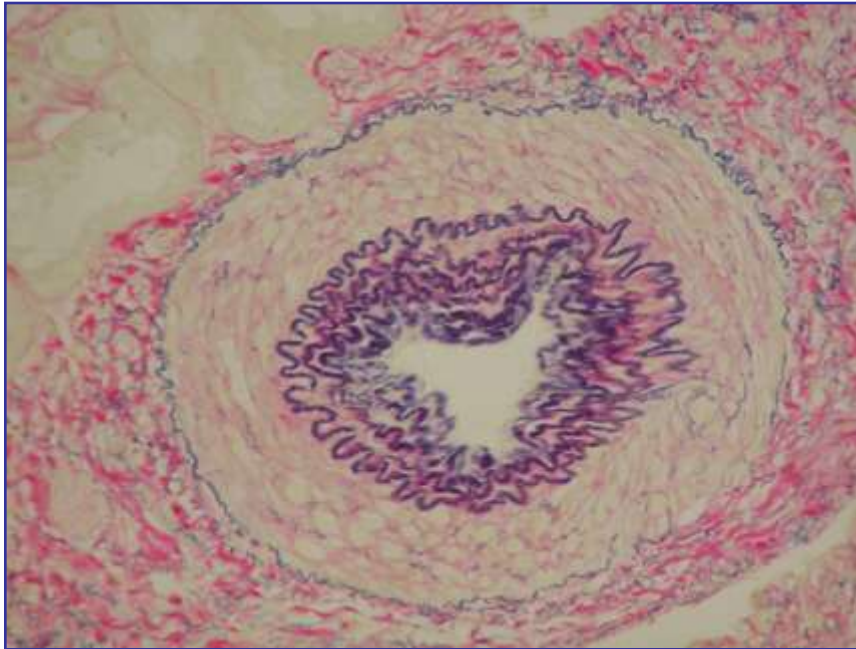


# Trichrome- stain

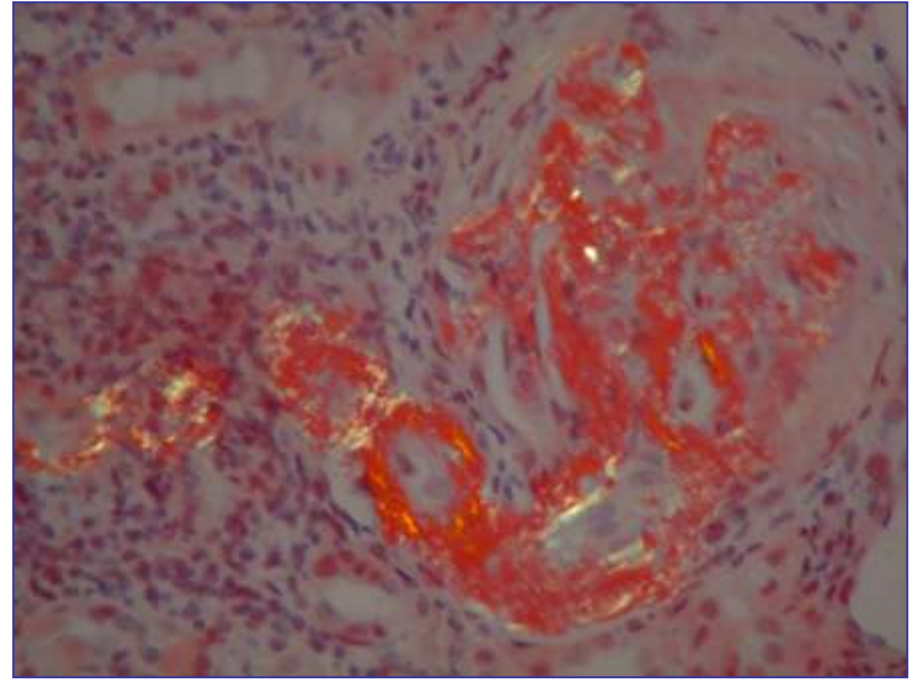
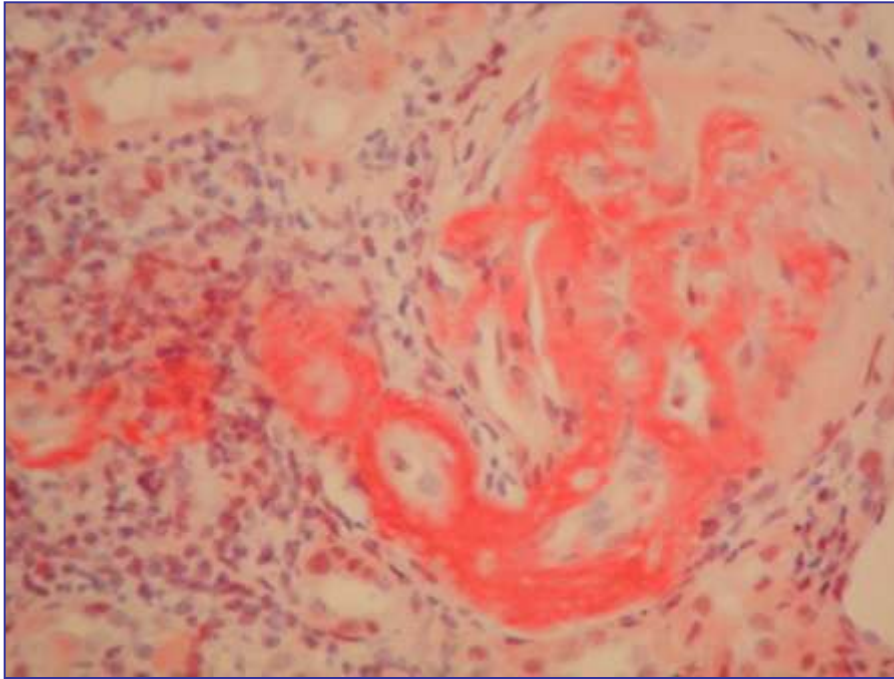




# Elastica-van Gieson- stain



# Congo red staining

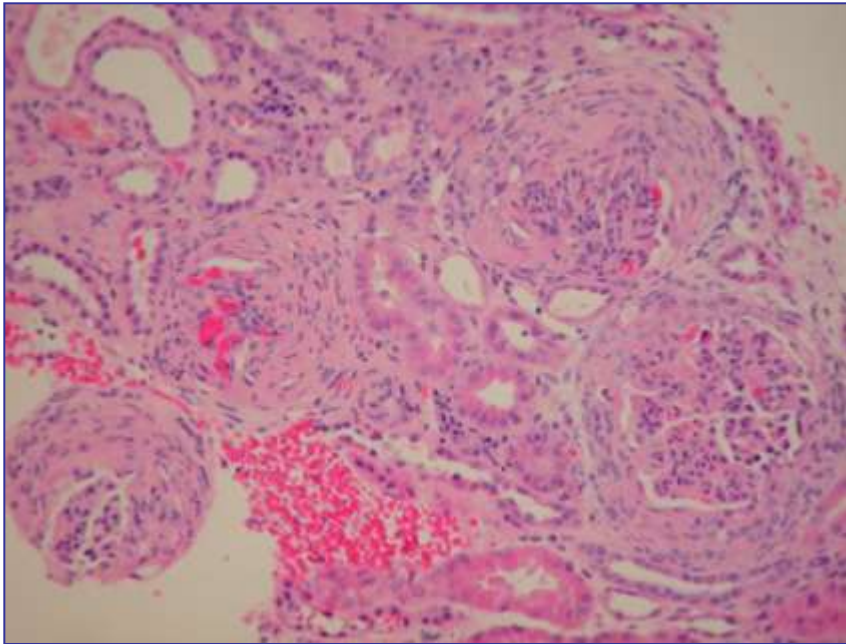


Under polarizing light

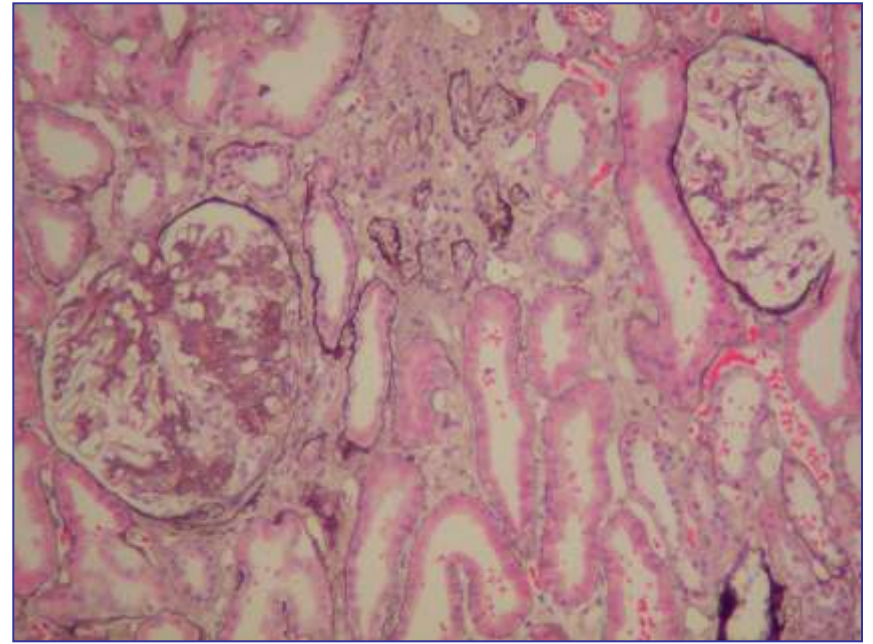
# **IMPORTANT TERMS**

# Glomerular changes

Diffuse

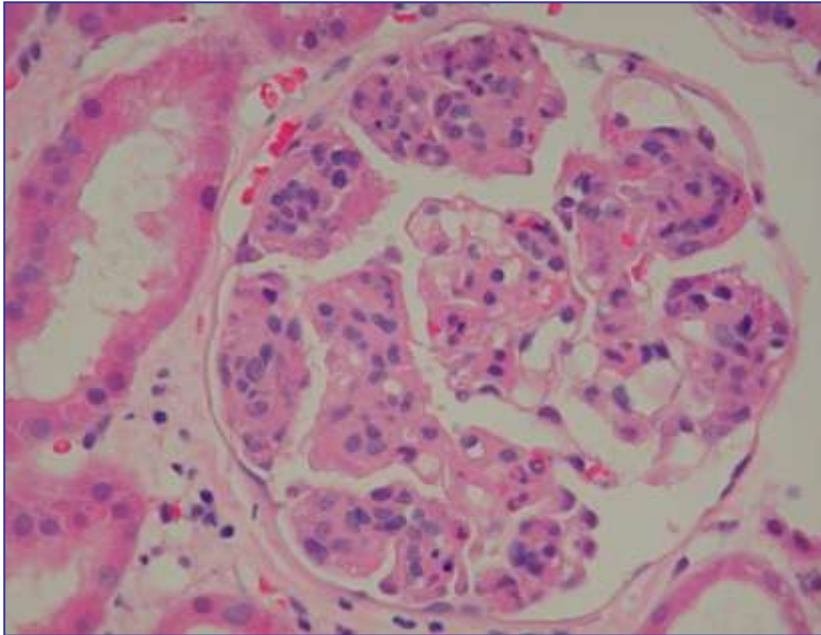


Focal

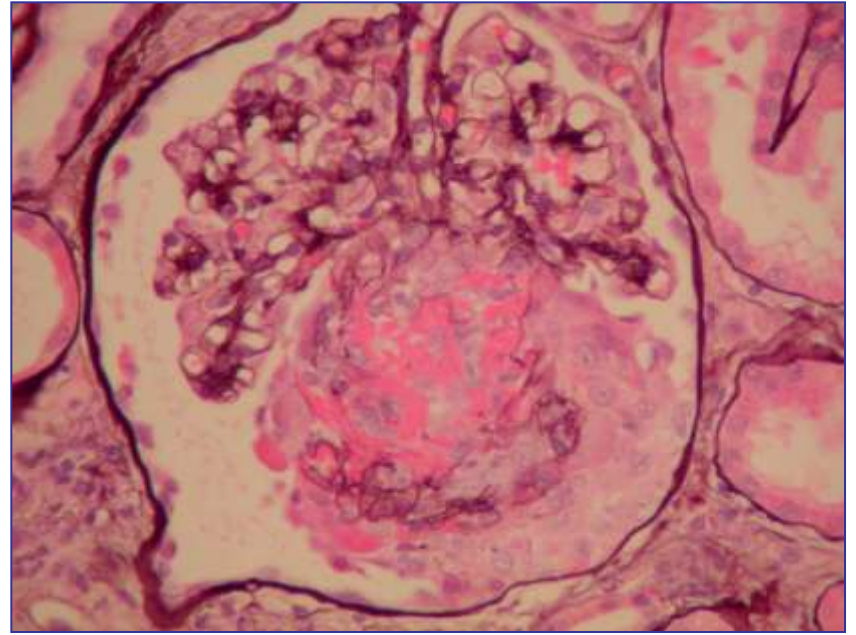


# Glomerular changes

Global



Segmental

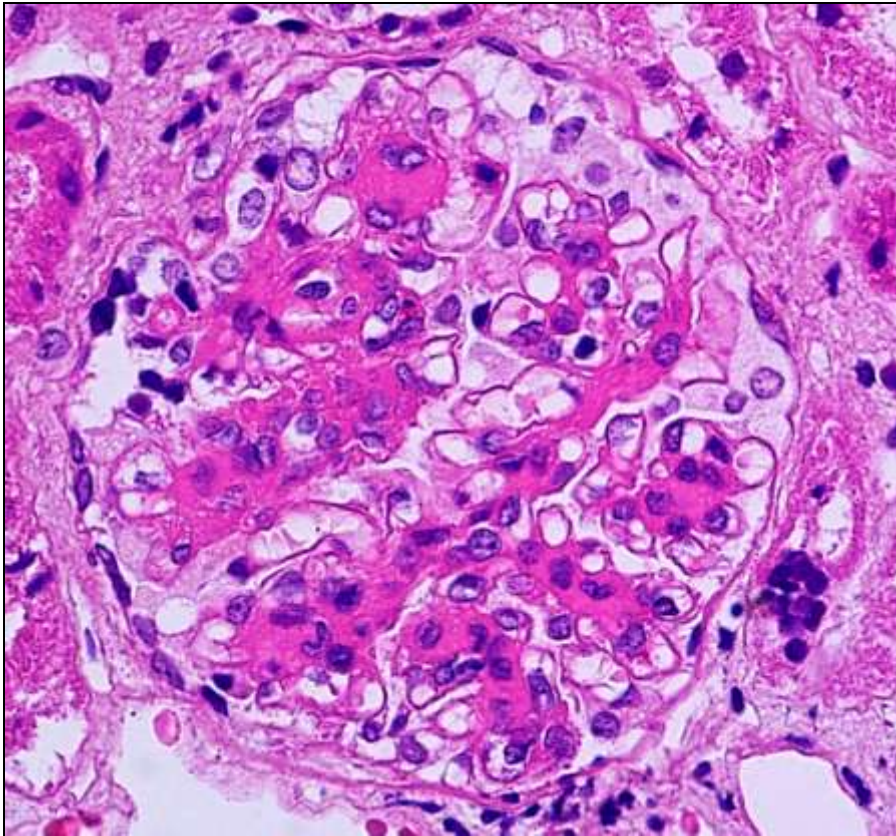


# Hypercellularity

More cells than normal in glomerulus.

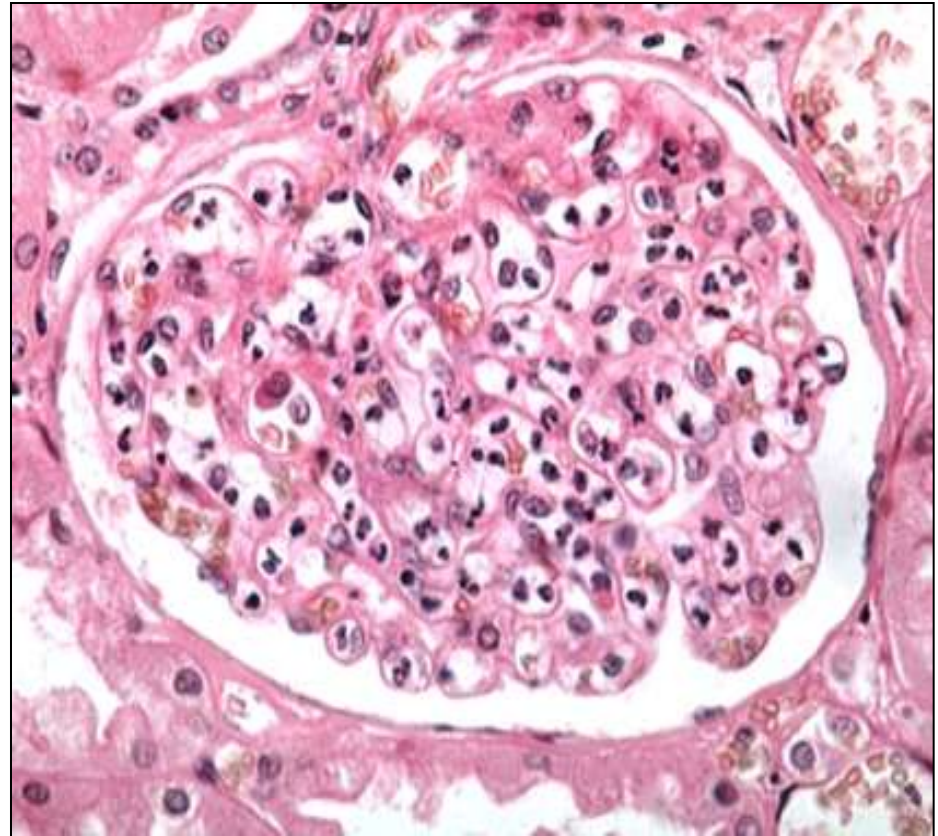
## Proliferative

Implies multiplication in loco resident glomerular cells.

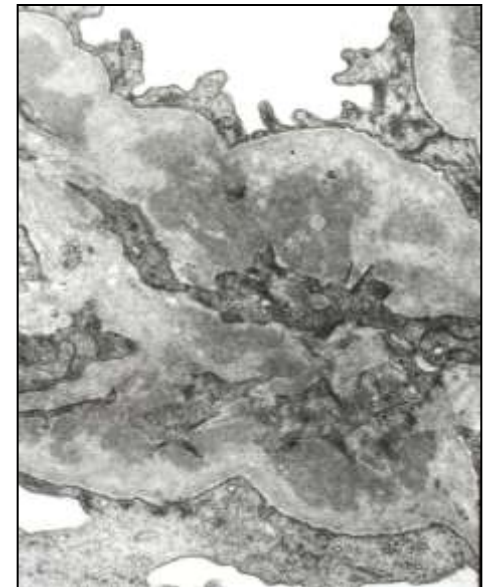
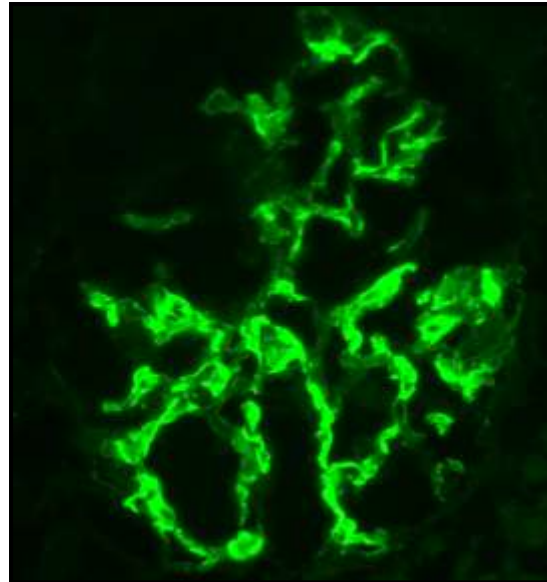
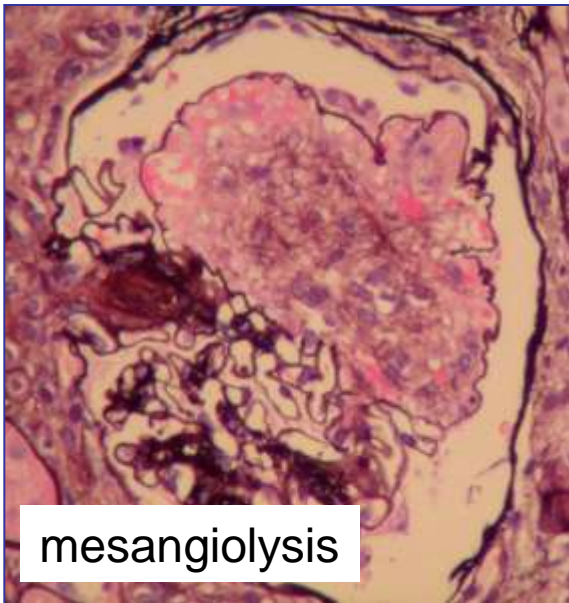
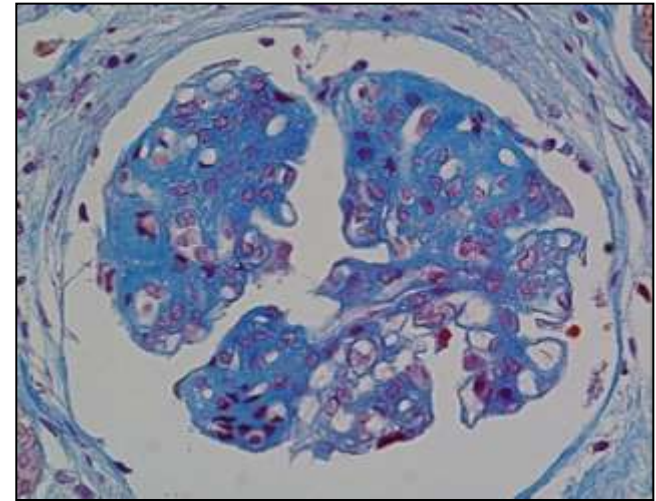
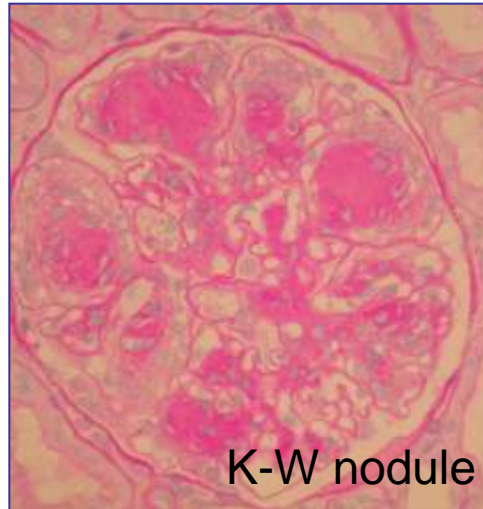
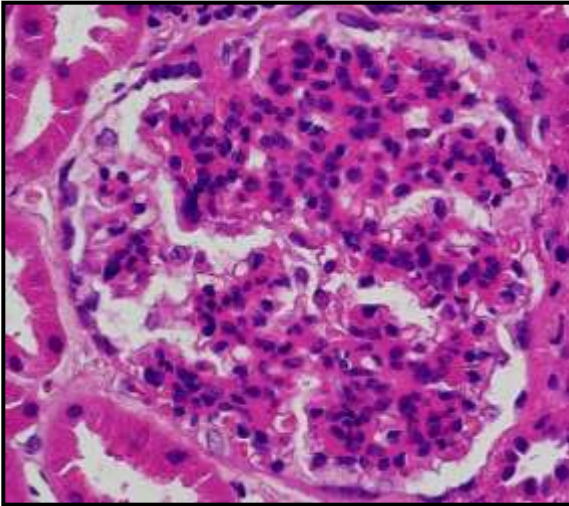


## Exudative

Implying inflammatory cells neutrophils and monocytes

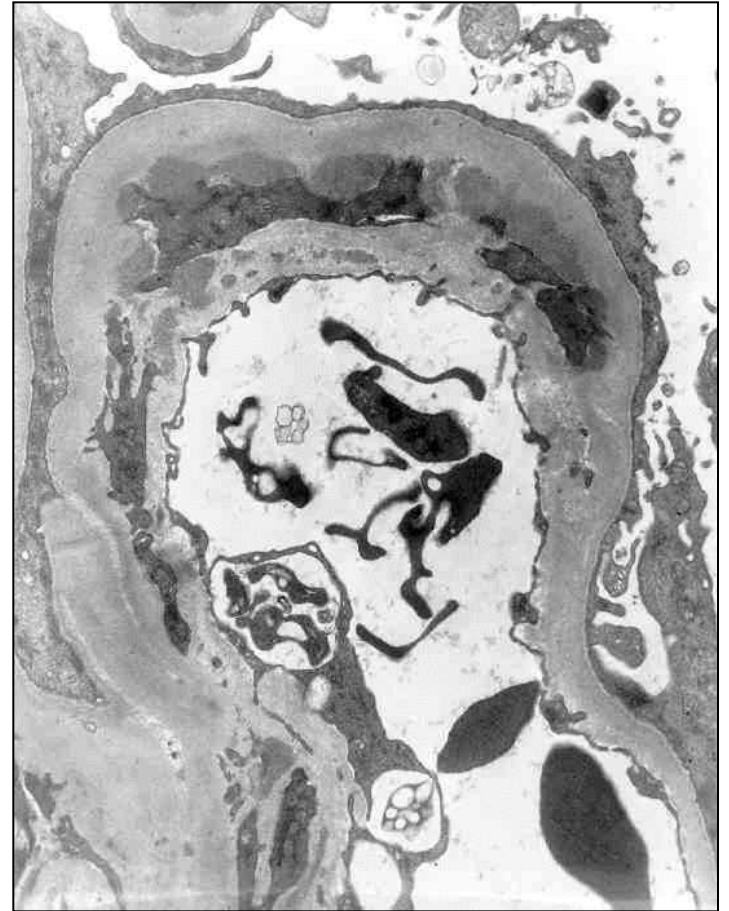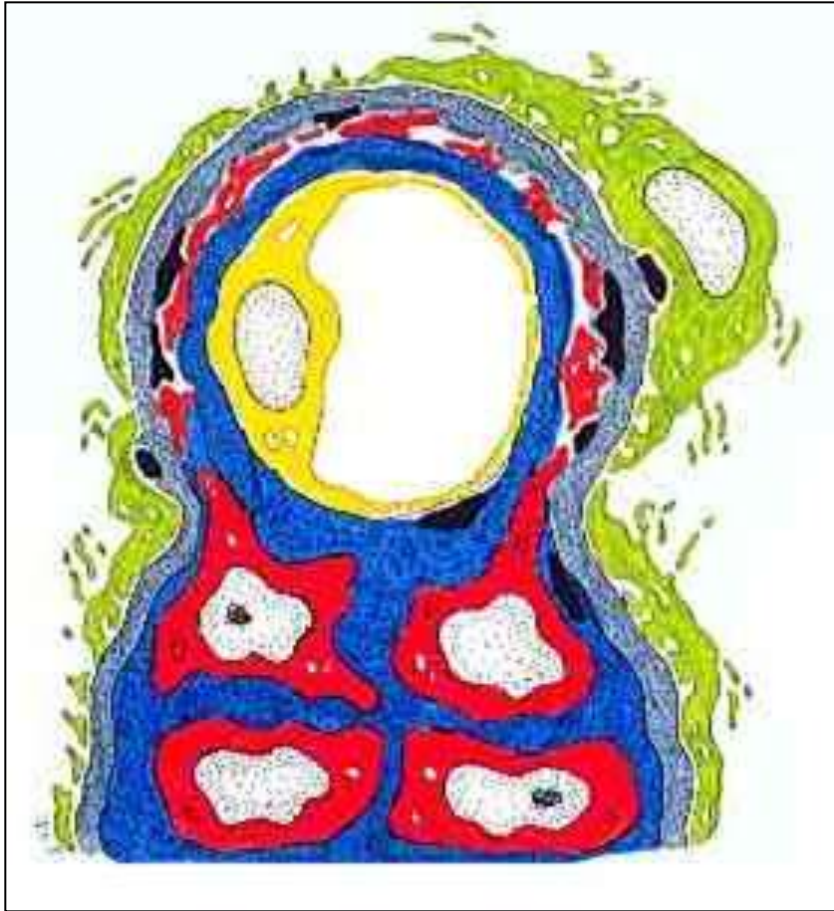


# Mesangial



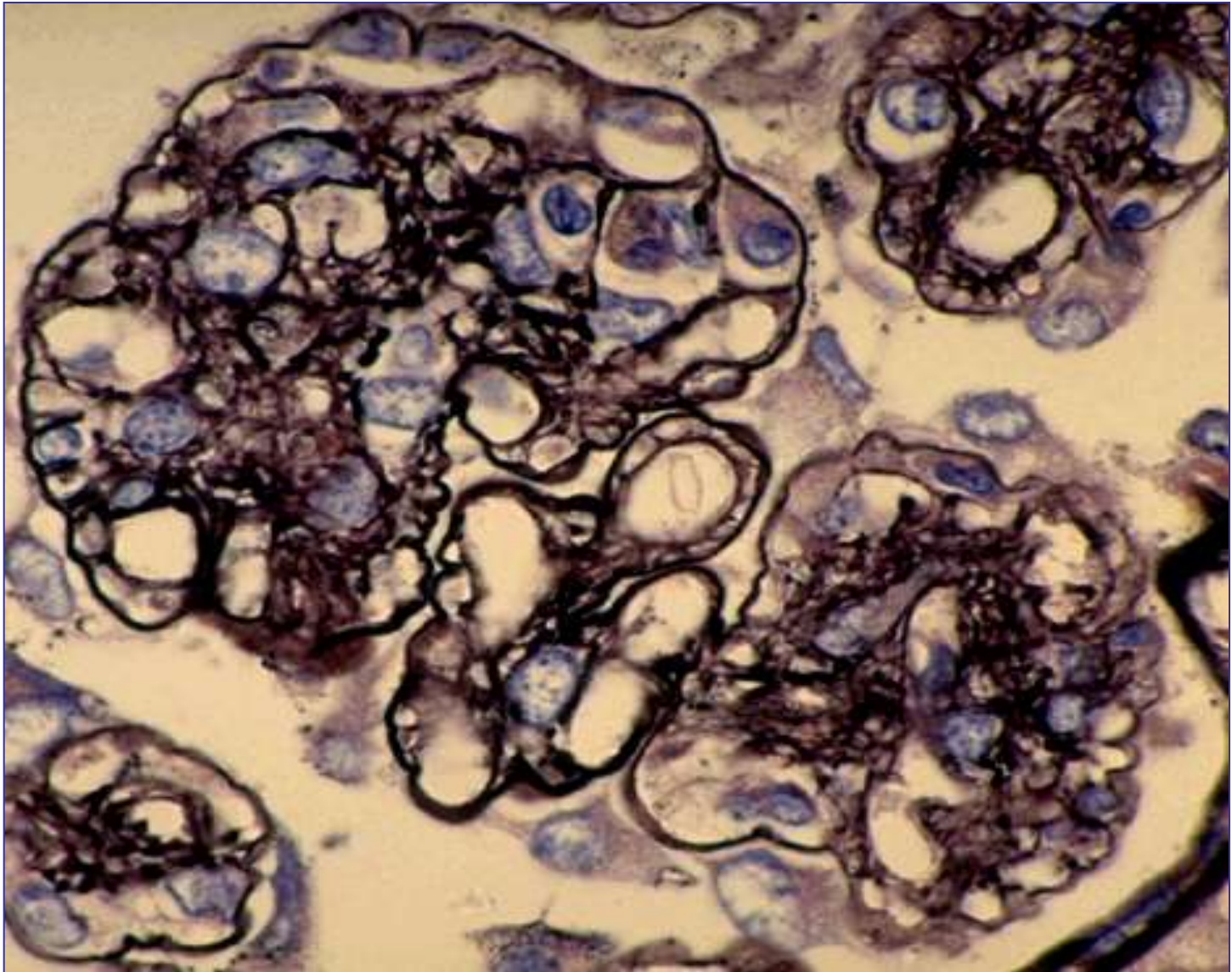
# Mesangialisation

## Mesangial cell interposition

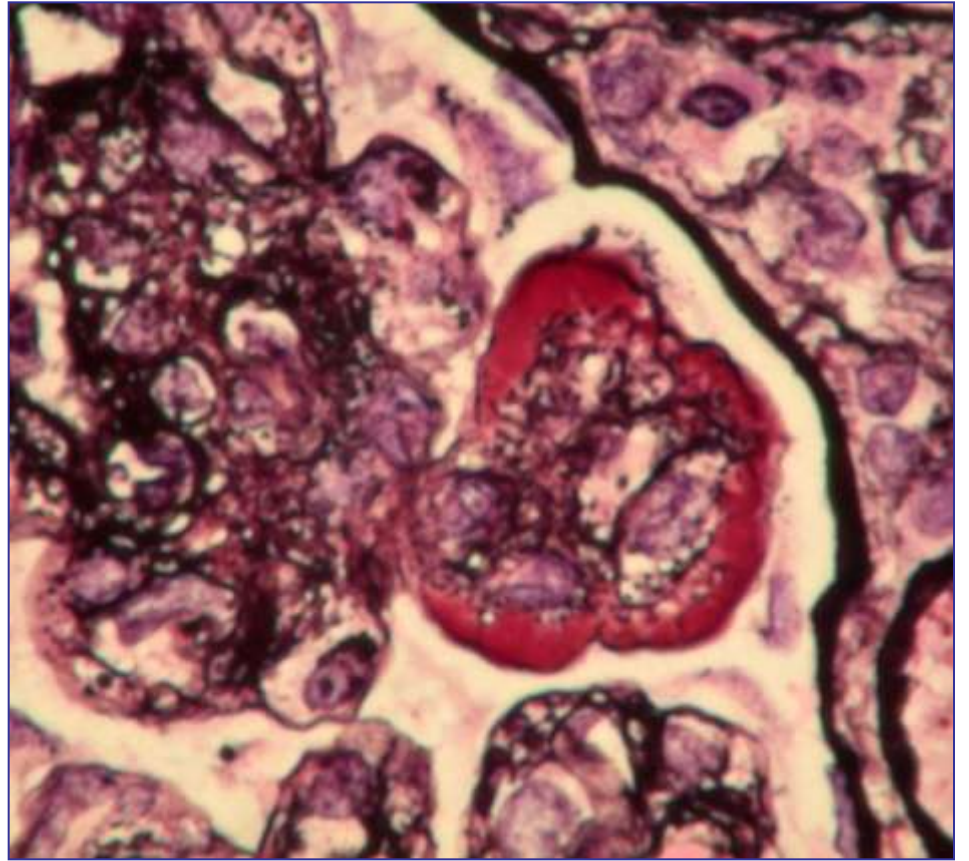
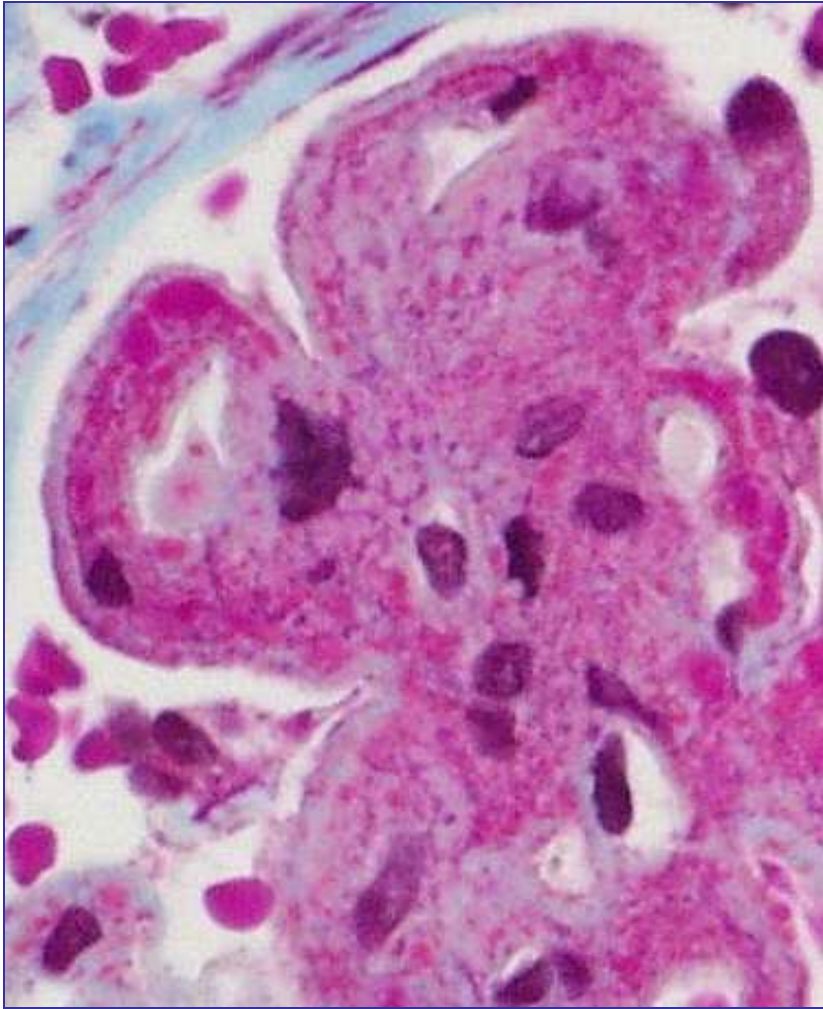




# Tram tracking

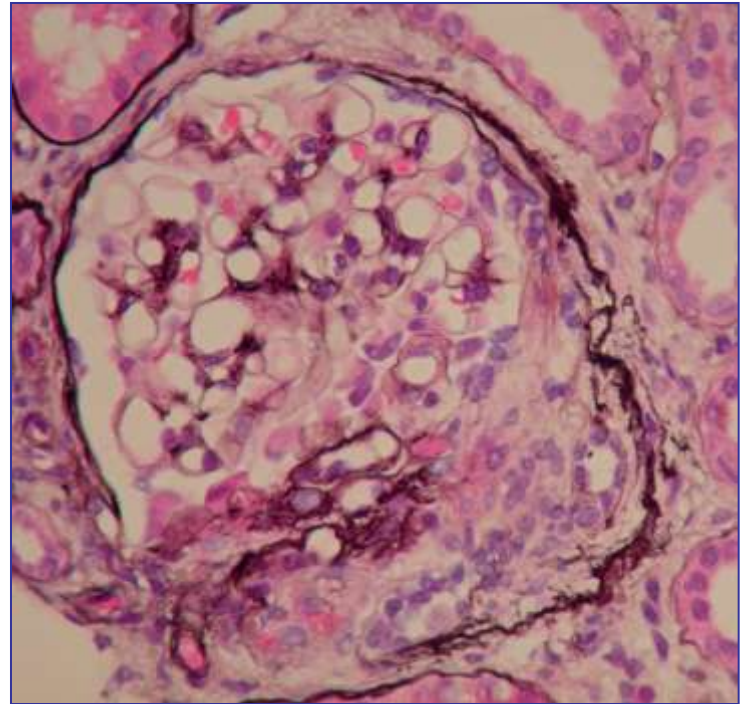
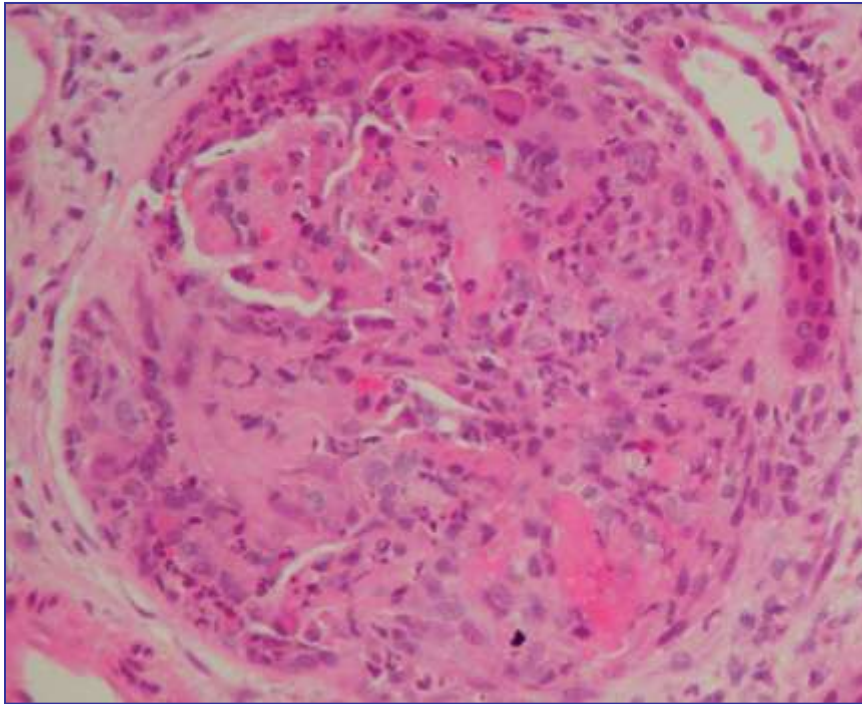


# Wire-loops



# Glomerular crescent

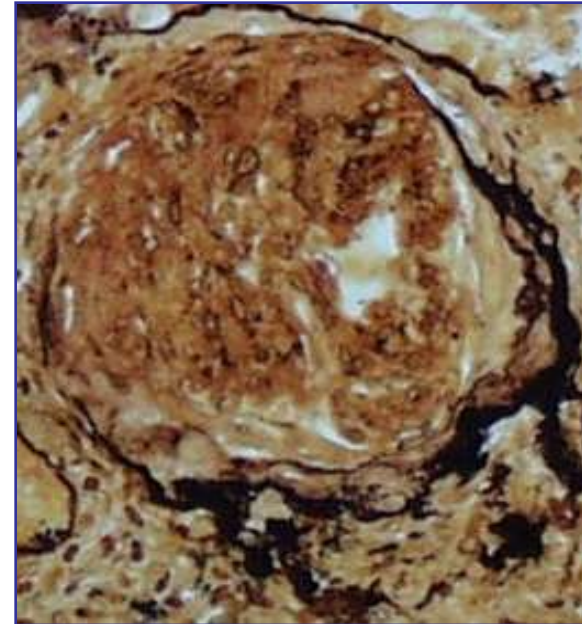
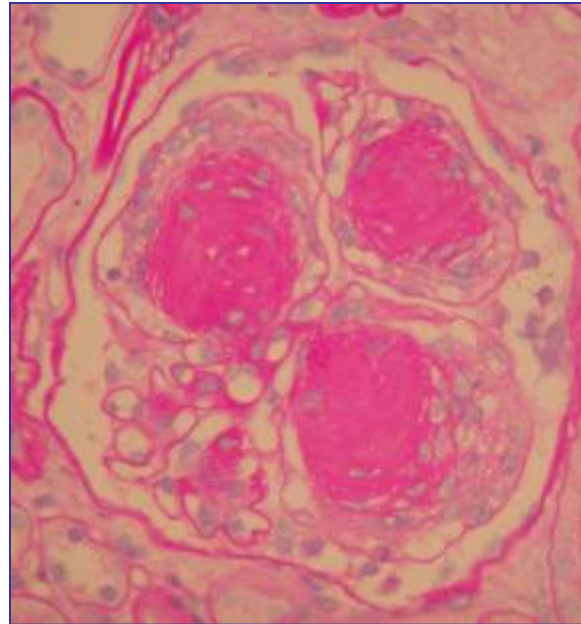
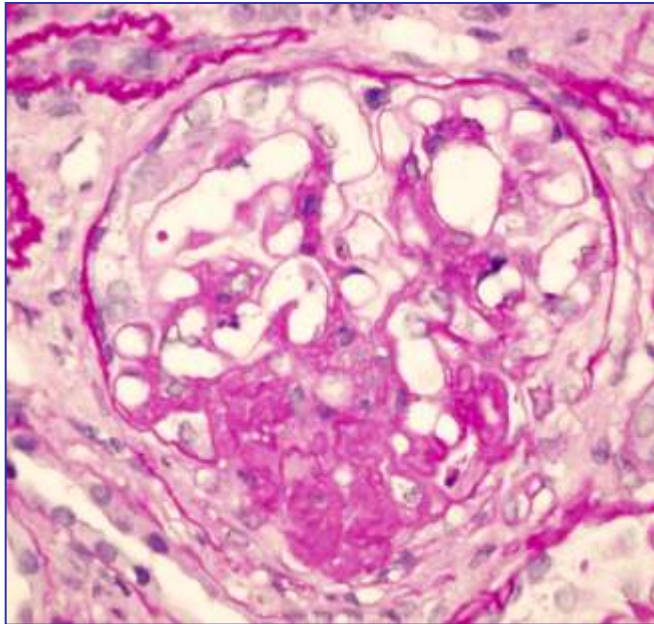
A lesion composed of cellular and/or fibrous tissue proliferation which fills all or part of Bowman's space.



Cellular and fibrocellular

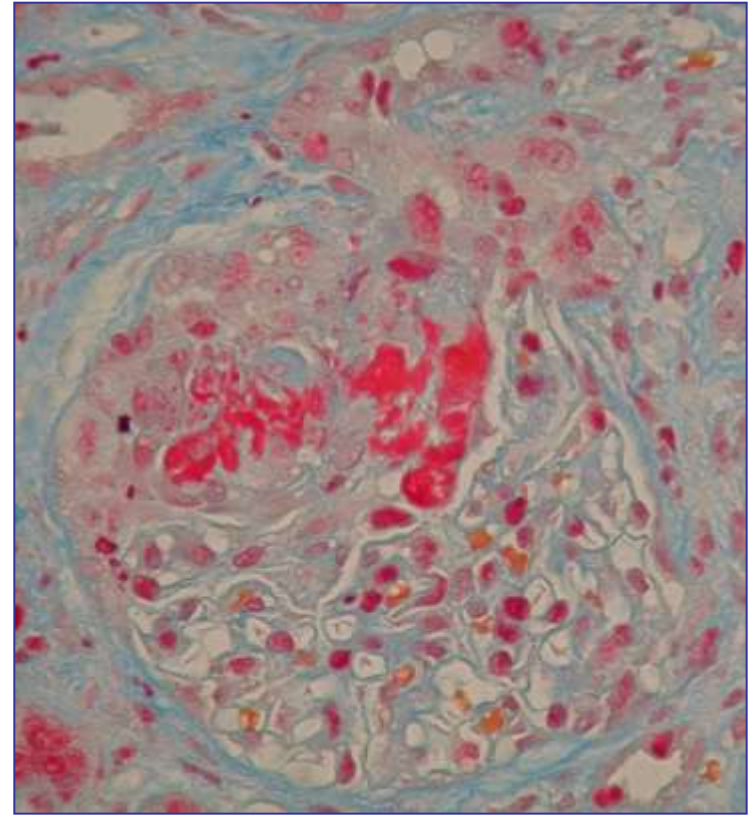
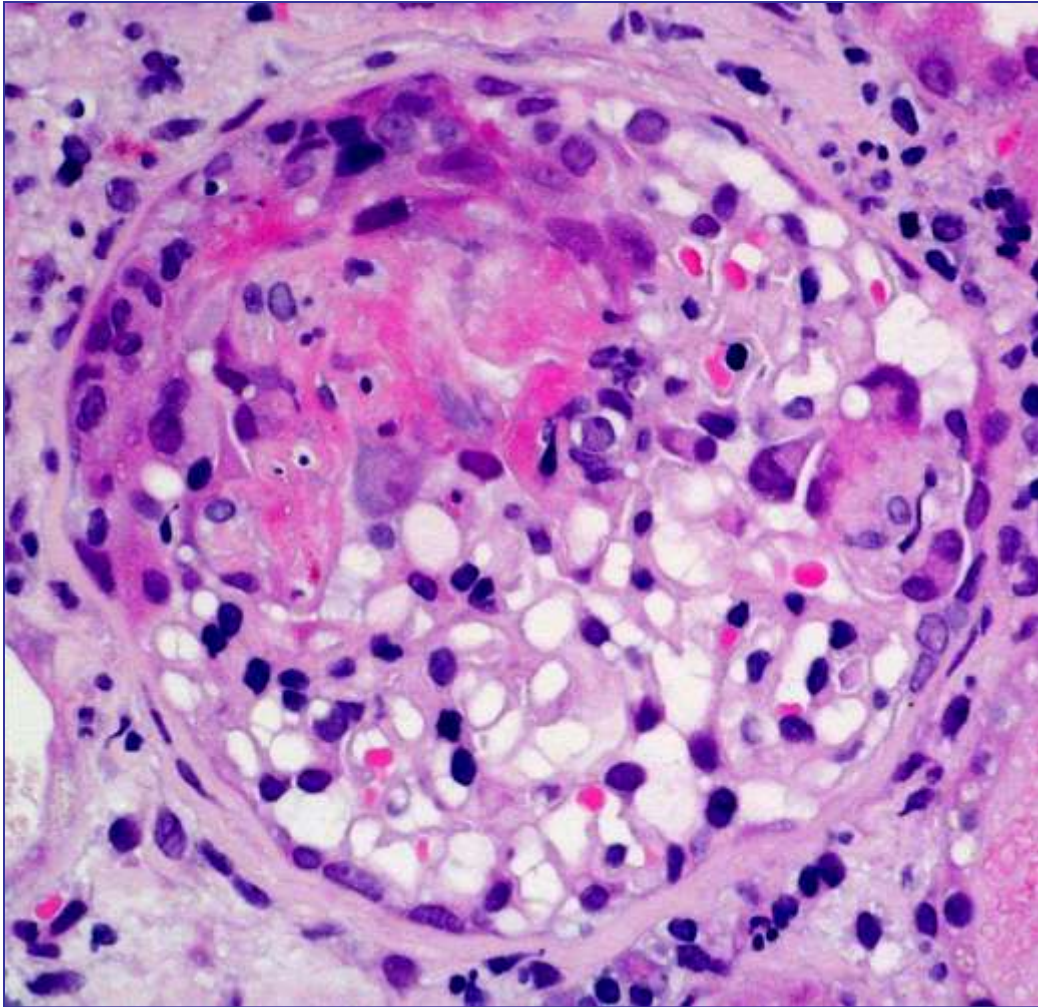
# Glomerulosclerosis

Scarring of a glomerulus due to any chronic process.



# Necrosis

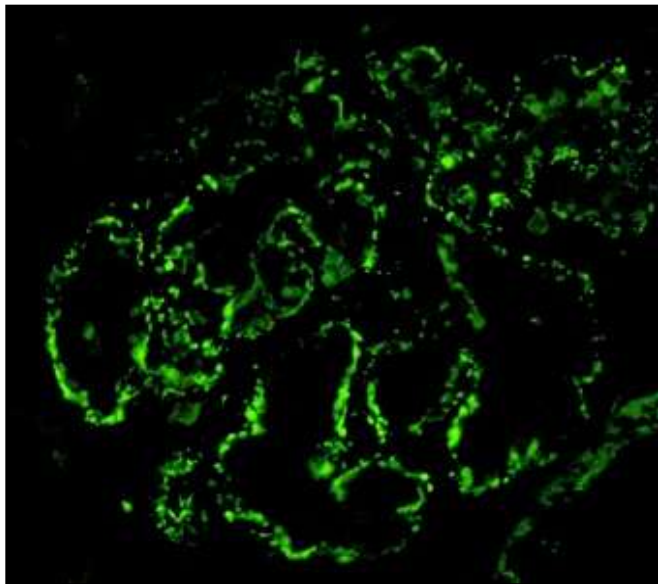
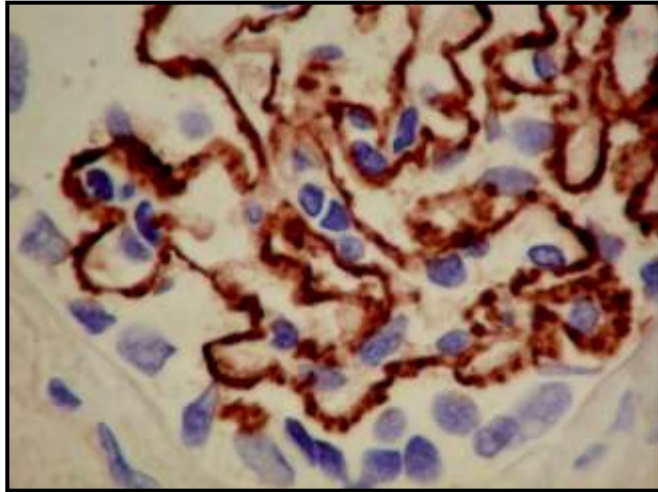
acute process, including vascular disease.



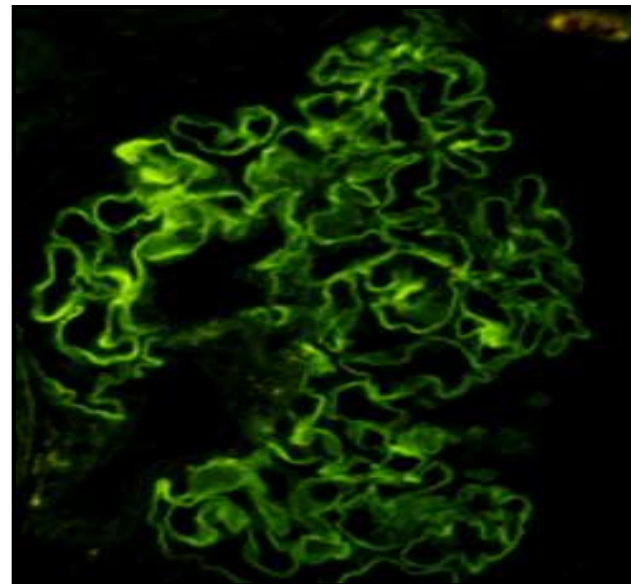
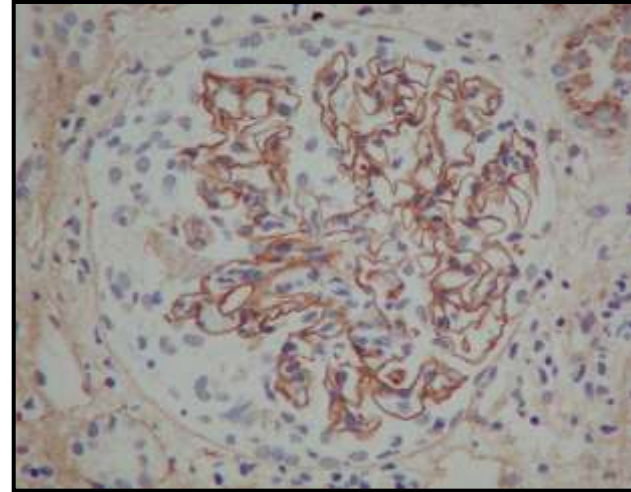
# Immune reaction

# Immune reaction

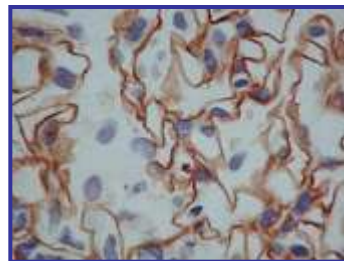
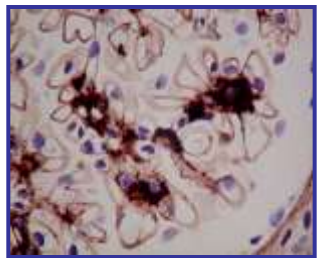
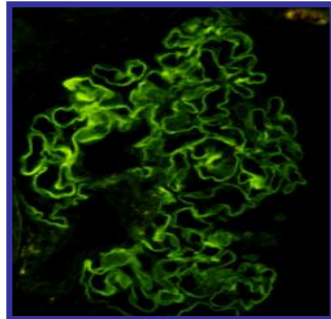
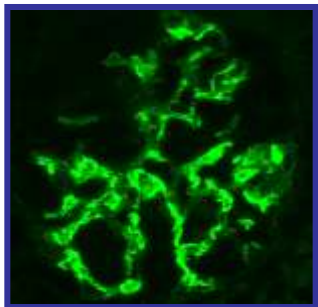
**Granular pattern**



**Linear pattern**



- Some diseases, such as **IgA nephropathy** and anti-GBM-glomerulonephritis can only be diagnosed by IH, whereas
- the diagnosis of other diseases is confirmed or refined by IH.



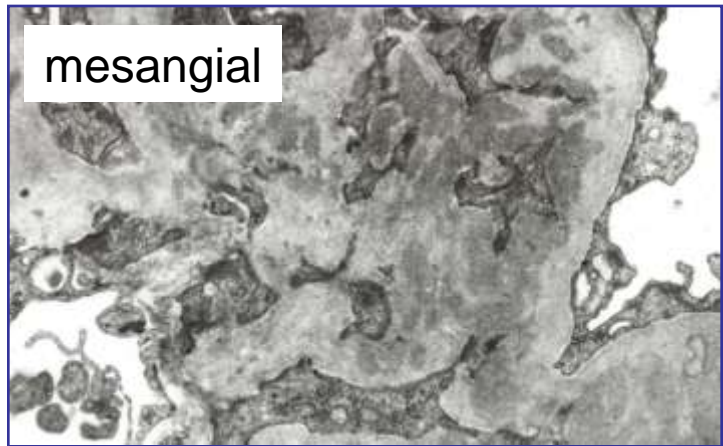
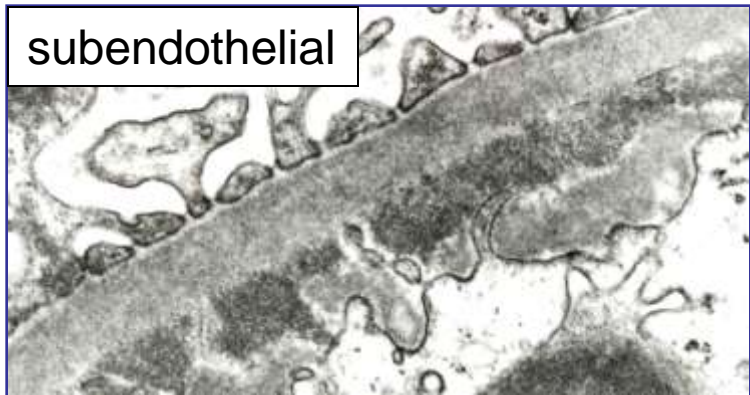
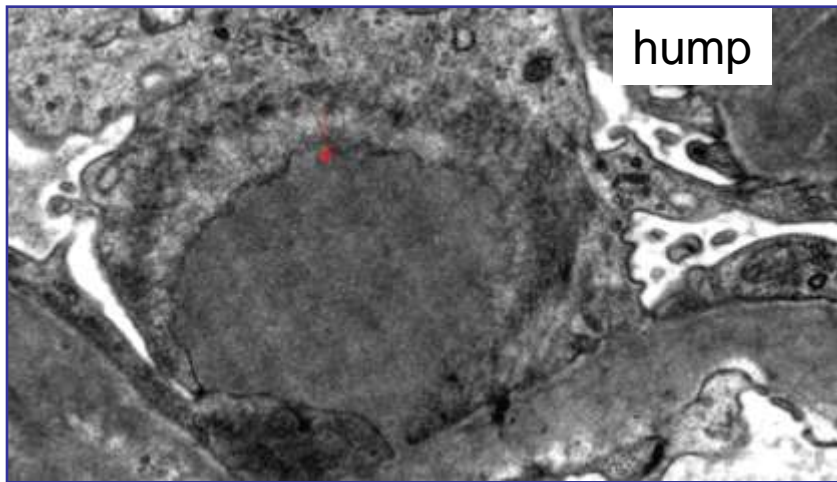
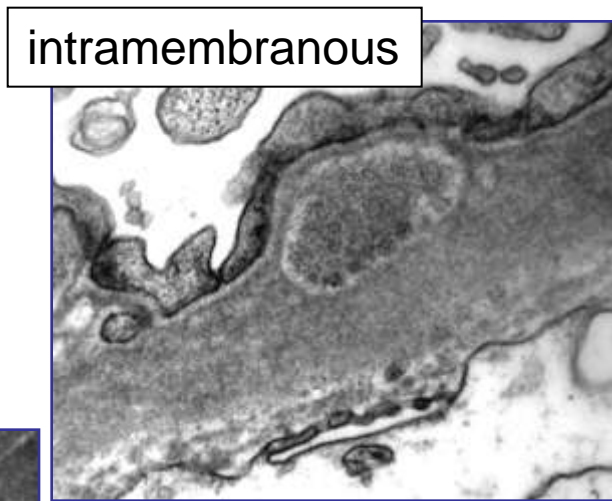
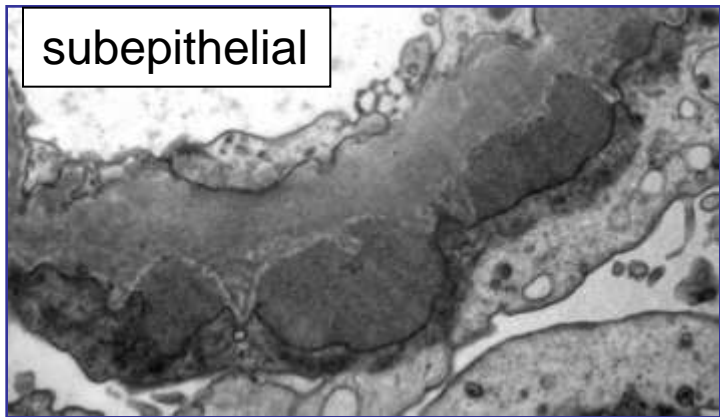


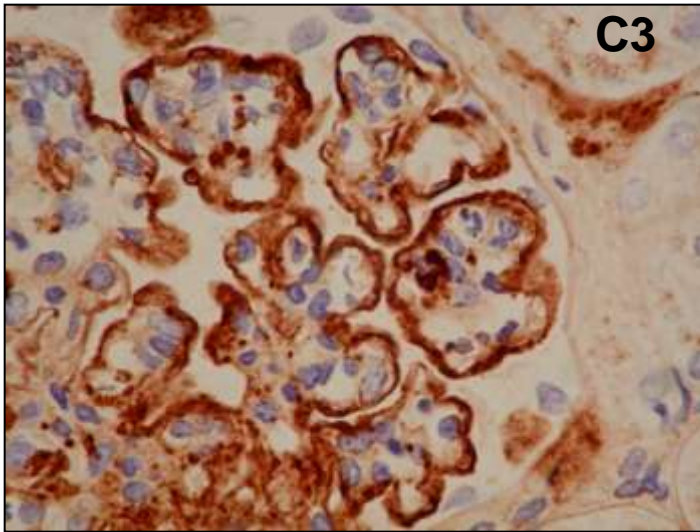
# ELECTRONMICROSCOPY

# ELECTRONMICROSCOPY

**Protein deposits**

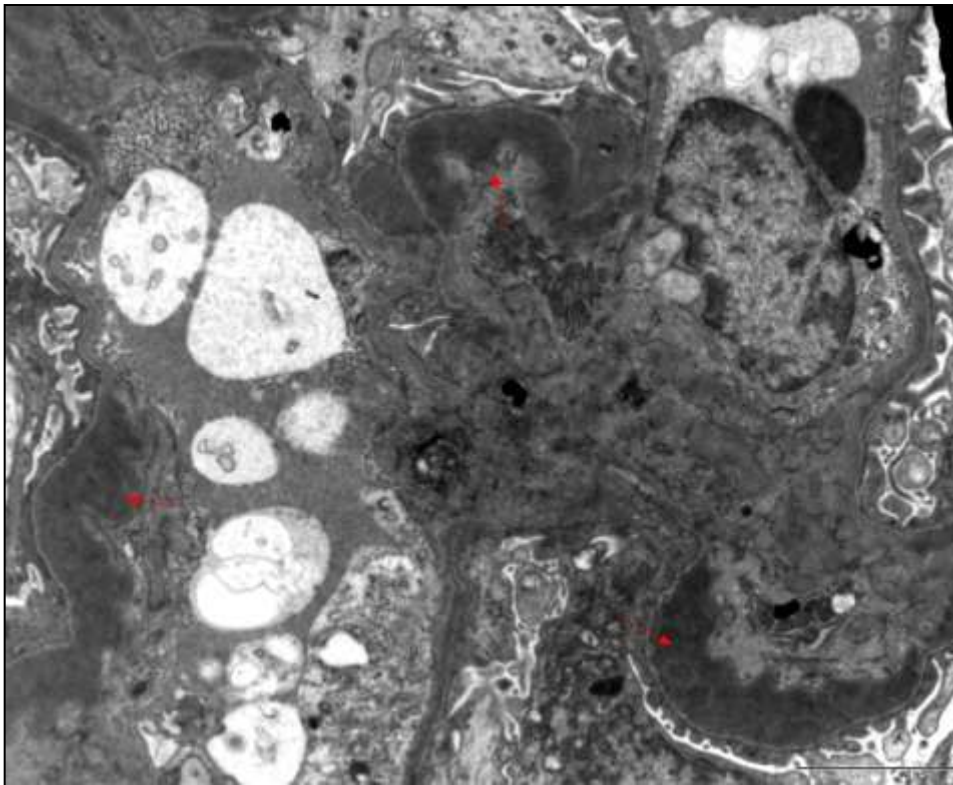
**intraglomerular localisation**

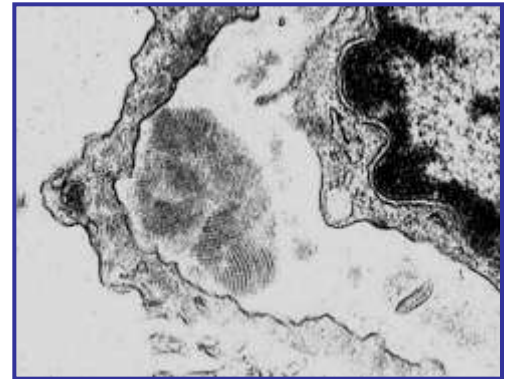
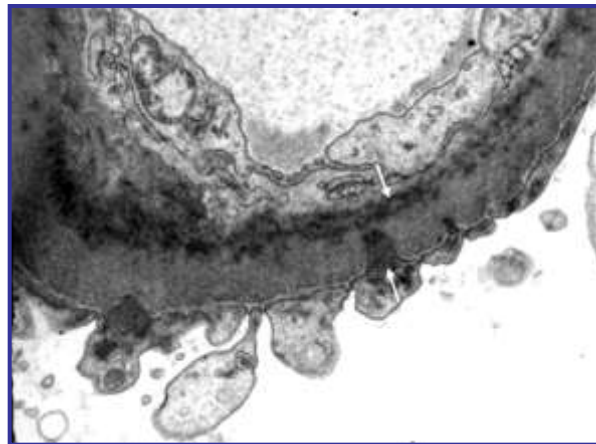
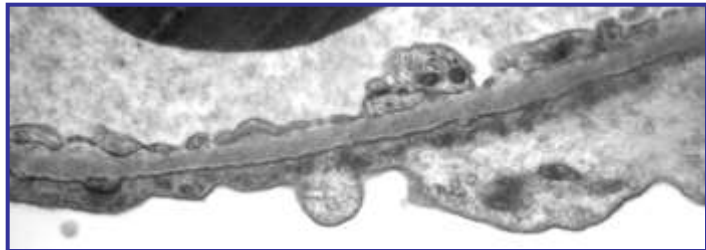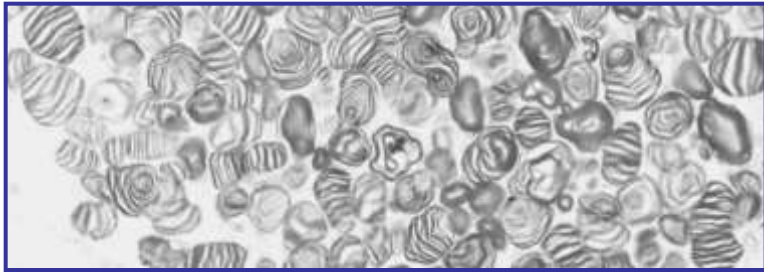
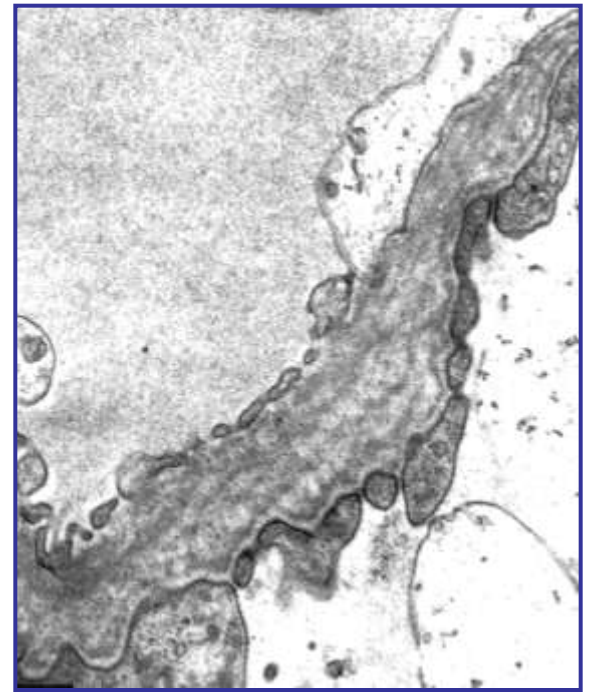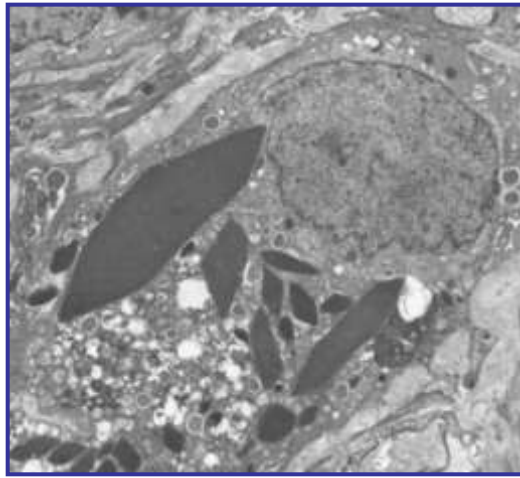
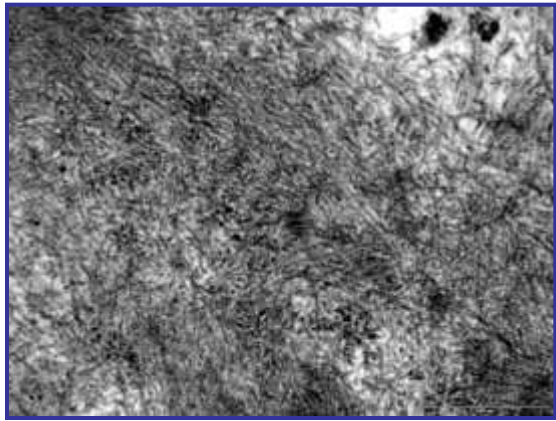




dense deposit disease

Transplant recurrence: 100%





# Renal biopsy (Glomeruli)

**There is more information in the biopsy  
than the diagnosis**

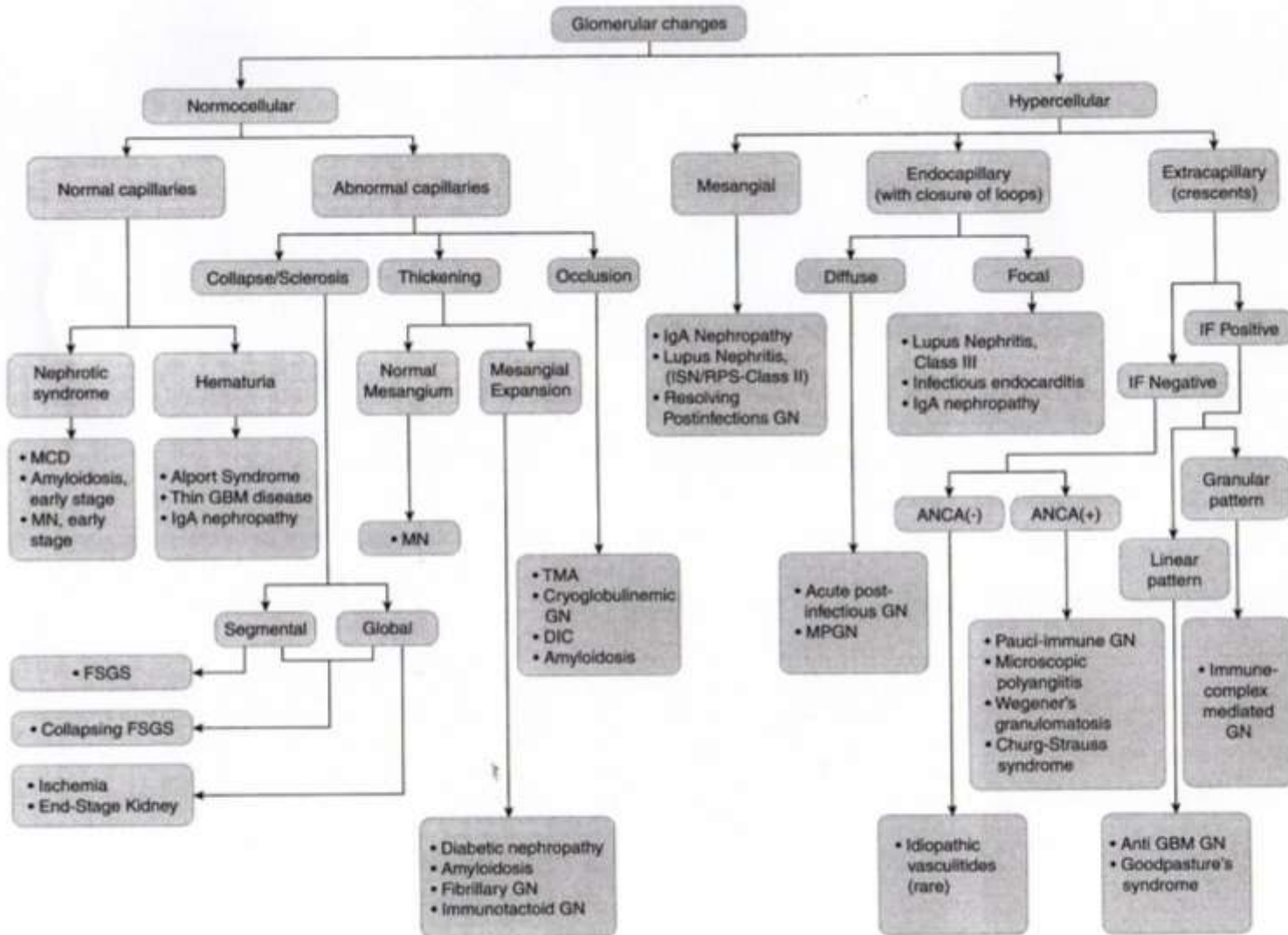
**The biopsy can provide:**

- 1. Prognostic information**
- 2. An indication of what treatment should be given and the likely response**
- 3. Give a measurement of activity and chronicity**

# Algorhythmic approach to the interpretation of renal biopsy

Based on the work of  
**Zhou, XJ, Laszik, Z, Silva, FG**

Silva's Diagnostic Renal Pathology  
Cambridge Univ. Press 2009



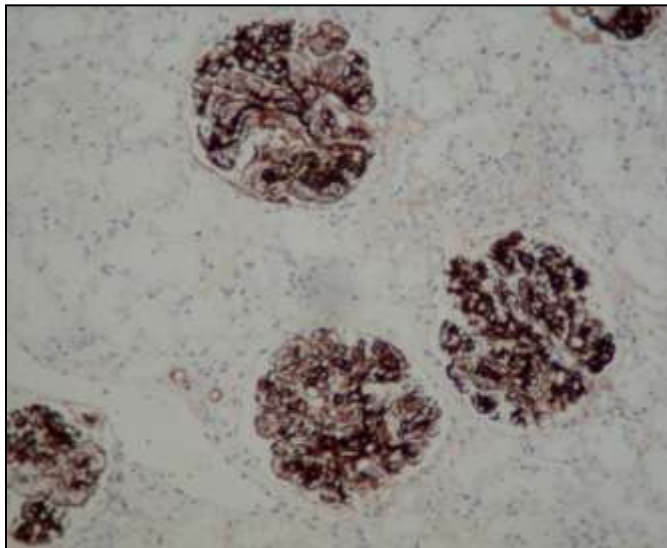
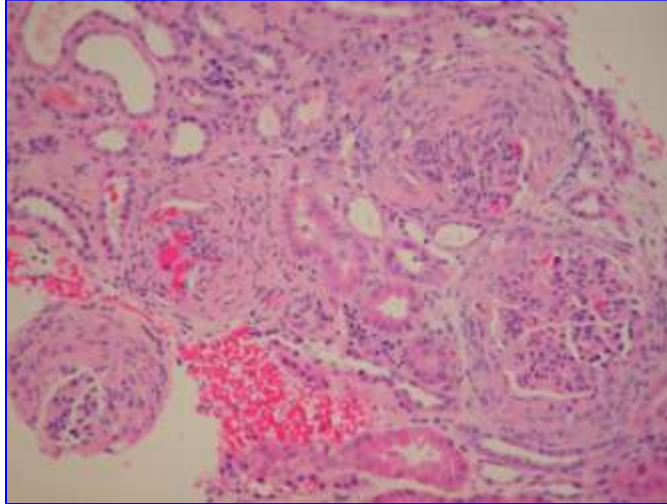
**MCD:** minimal change disease; **MN:** membranous nephropathy; **GBM:** glomerular basement membrane; **FSGS:** focal segmental glomerulosclerosis; **TMA:** thrombotic microangiopathy; **GN:** glomerulonephritis; **DIC:** disseminated intravascular coagulation; **ANCA:** anti-neutrophil cytoplasmic antibody; **MPGN:** membranoproliferative glomerulonephritis

**FIGURE 3.4:** Algorithmic approach to the interpretation of glomerular injury by light microscopy.

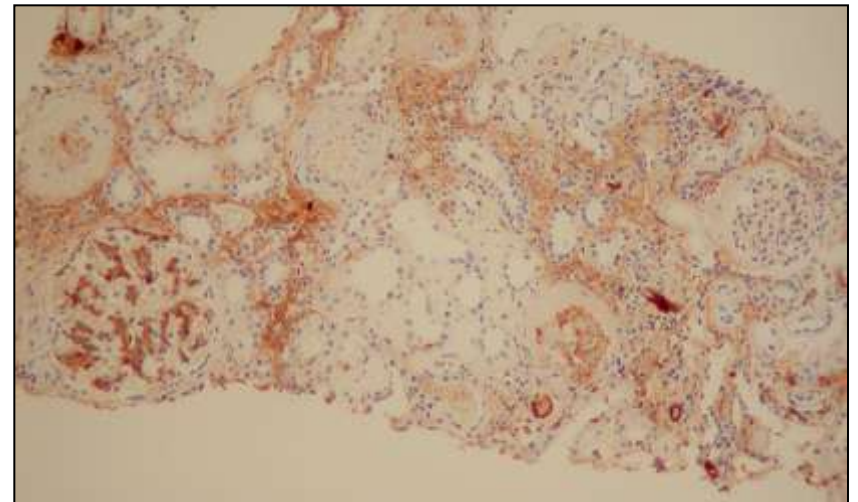
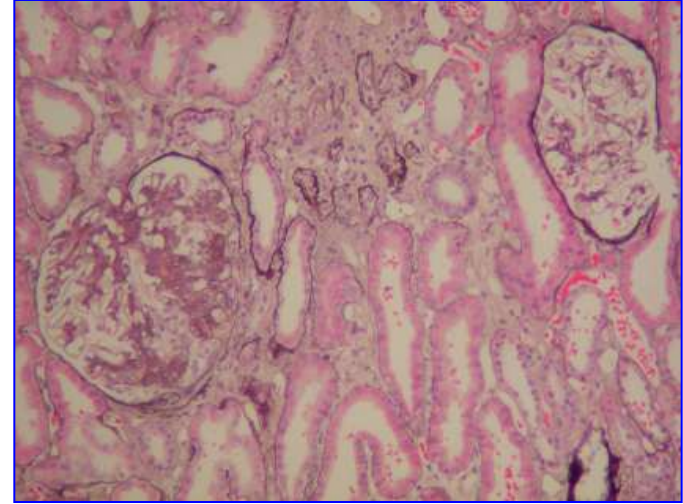


# Glomerular changes

**Diffuse**

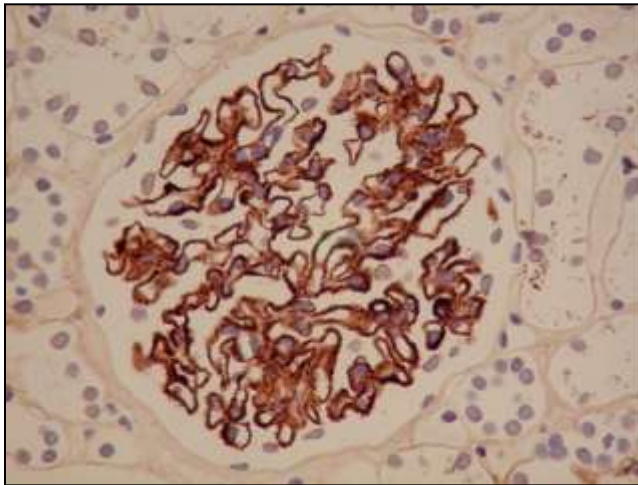
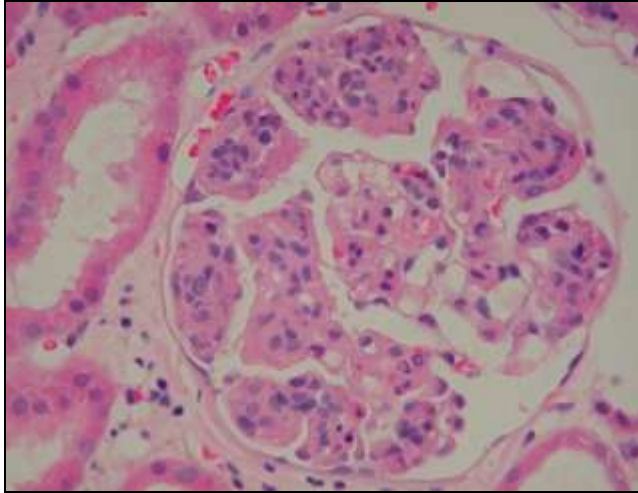


**Focal**

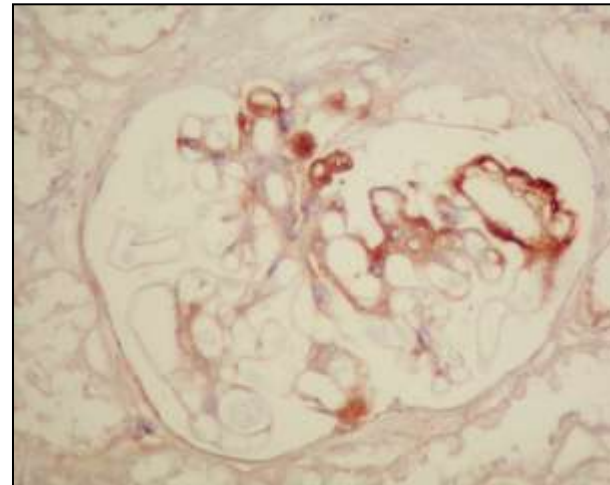
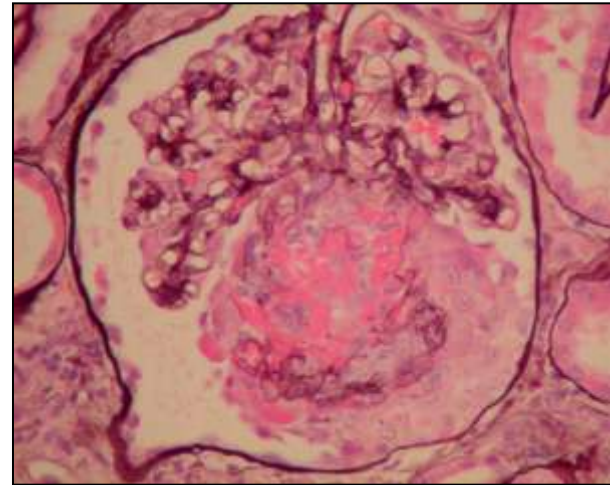


# Glomerular changes

**Global**



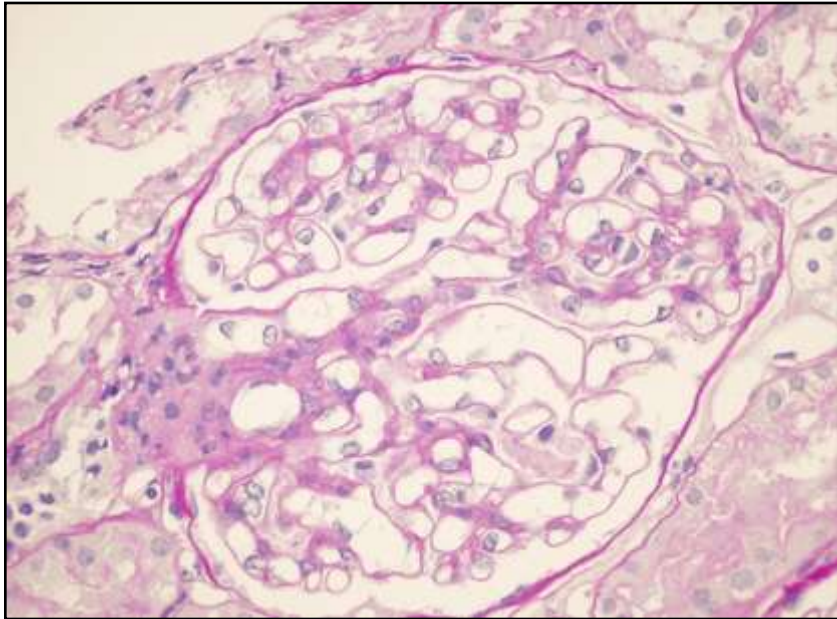
**Segmental**



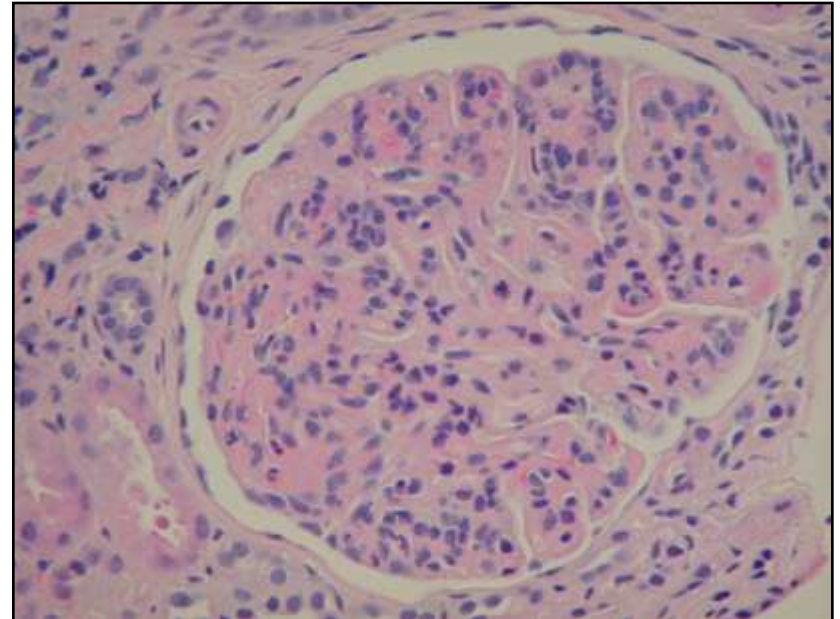
# Glomerular changes

# Glomerular changes

**NORMOCELLULAR**



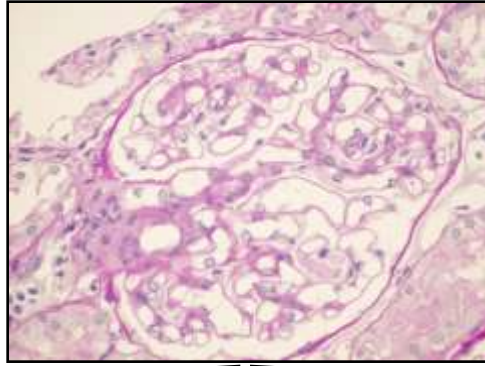
**HYPERCELLULAR**



# Glomerular changes



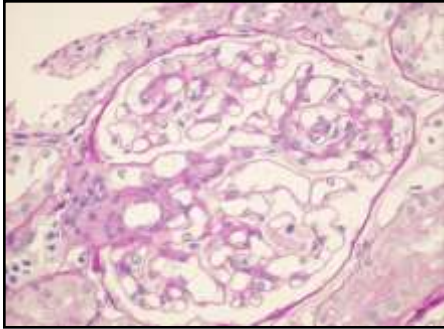
**NORMOCELLULAR**



**Normal capillaries**

**Abnormal capillaries**

# Glomerular changes



**NORMOCELLULAR**

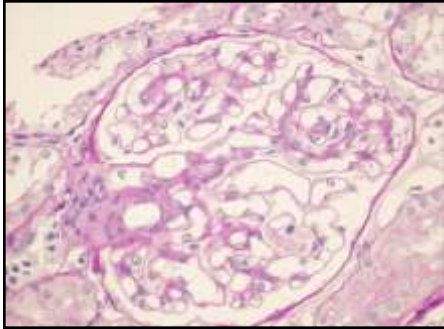
**Normal capillaries**

**Nephrotic  
syndrome**

**Haematuria**

**Electronmicroscope  
Immunohistology  
Specials staining**

# Glomerular changes



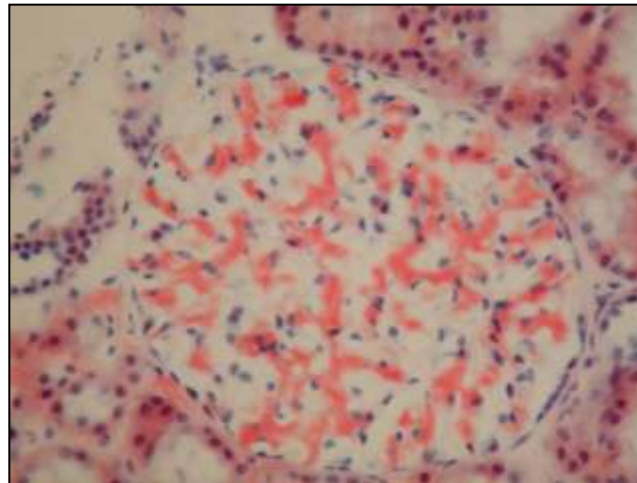
**NORMOCELLULAR**

**Normal capillaries**

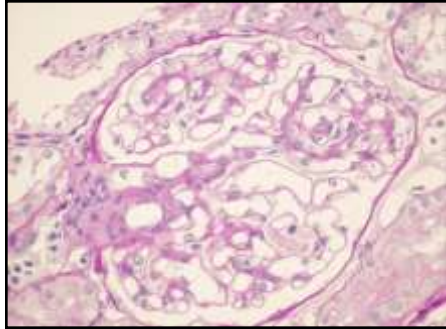
**Nephrotic  
syndrome**

*Special staining (Congo red+ Polarizing)*

**Amyloidosis**



# Glomerular changes



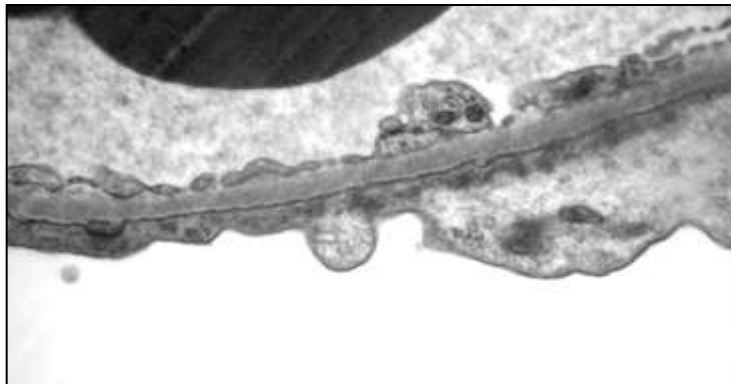
**NORMOCELLULAR**

**Normal capillaries**

**Nephrotic  
syndrome**

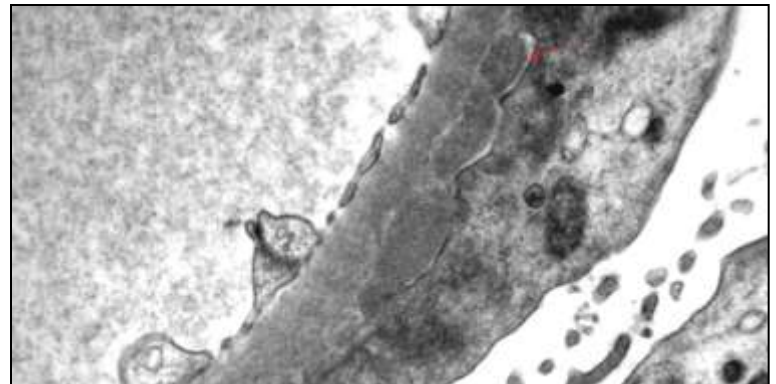
**IH negative**

**Minimal change nephropathy  
Membranous GN Stage IV**



**IH: granular IgG, C3 deposits  
EM: subepithelial e.d.deposits**

**Membranous GN Stage I**





# Glomerular changes



**NORMOCELLULAR**



**Normal capillaries**



Haematuria

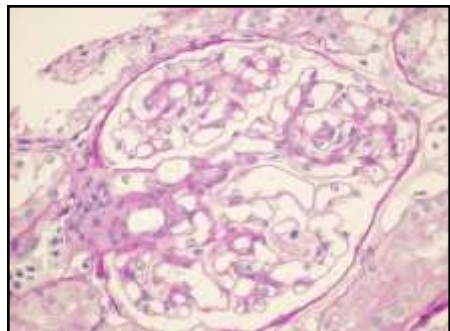
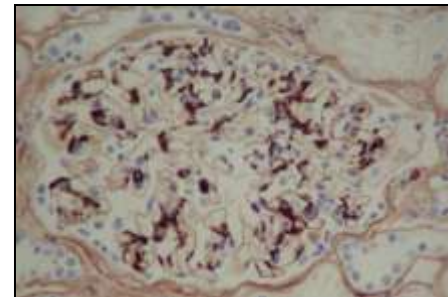
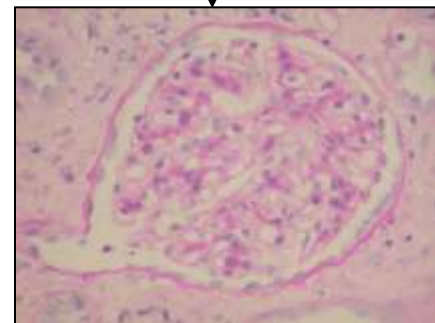
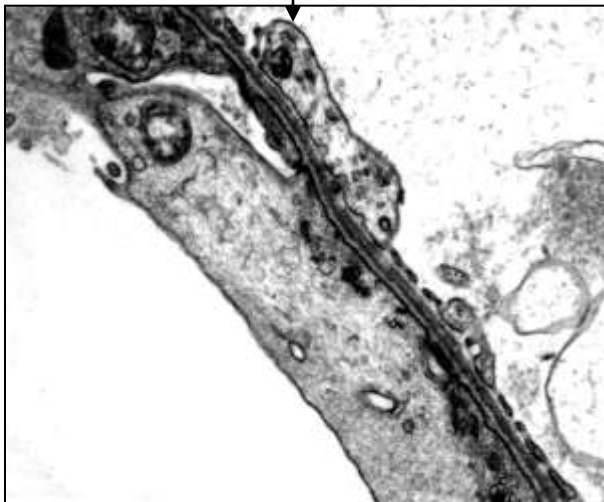
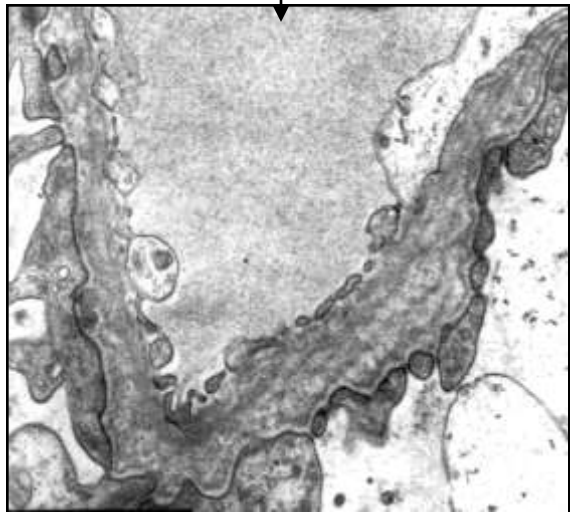
**Alport sy.**

**EM**

**Thin GBM D**

**IH**

**IgA N**



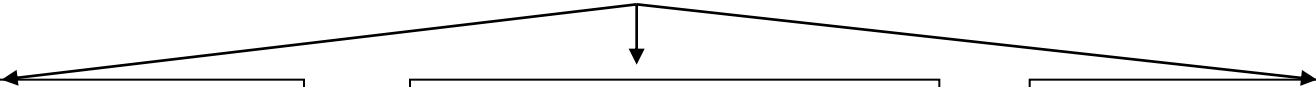
**Glomerular changes**



**NORMOCELLULAR**



**Abnormal capillaries**



**Collapse/sclerosis**

**Thickening**

**Occlusion**

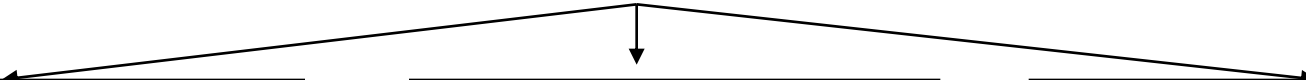
**Glomerular changes**



**NORMOCELLULAR**



**Abnormal capillaries**



**Collapse/sclerosis**

**Thickening**

**Occlusion**

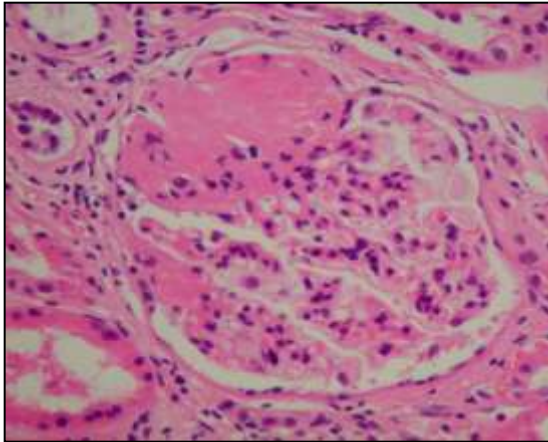
# Glomerular changes

**NORMOCELLULAR**

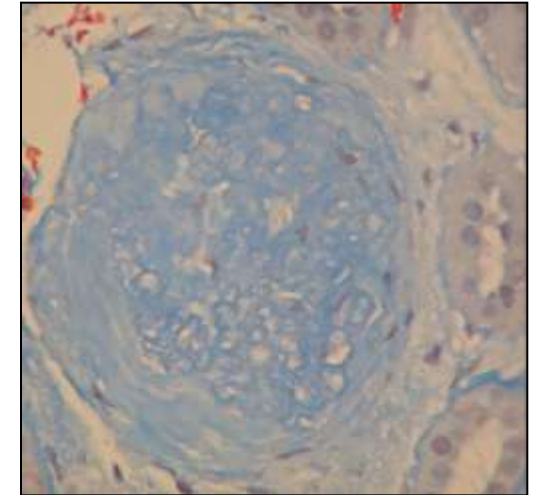
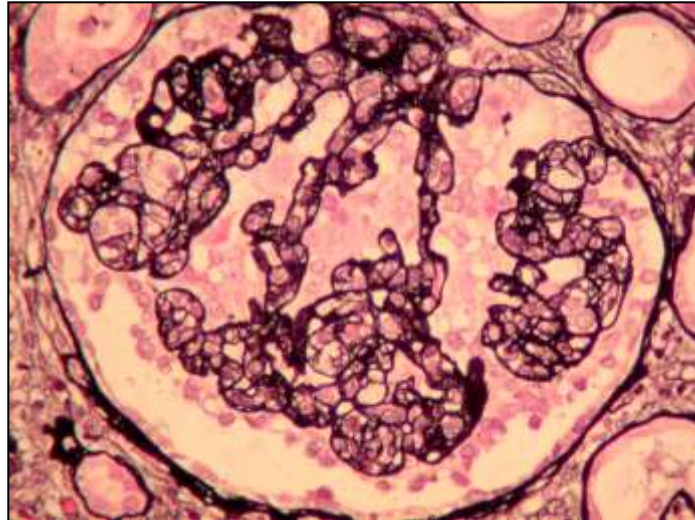
**Abnormal capillaries**

**Collapse/sclerosis**

**Segmental**



**Global**



# Glomerular changes

**NORMOCELLULAR**

**Abnormal capillaries**

**Collapse/sclerosis**

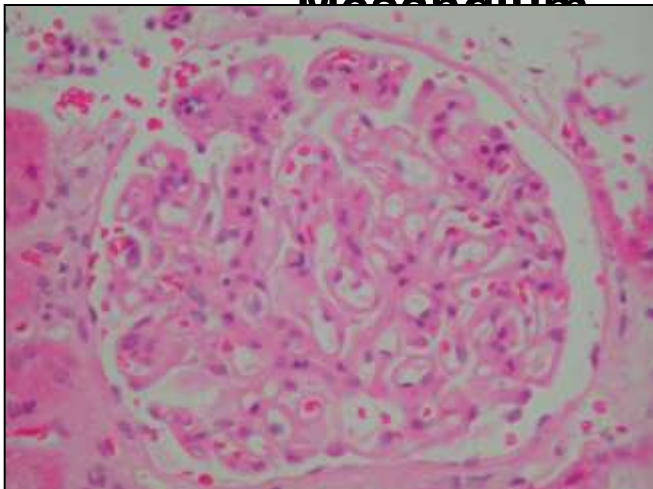
**Thickening**

**Occlusion**

**Normal**

**Mesangium**

**Mesangial expansion**



**Membranous glomerulopathy**

# Glomerular changes

**NORMOCELLULAR**

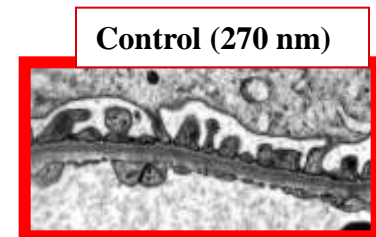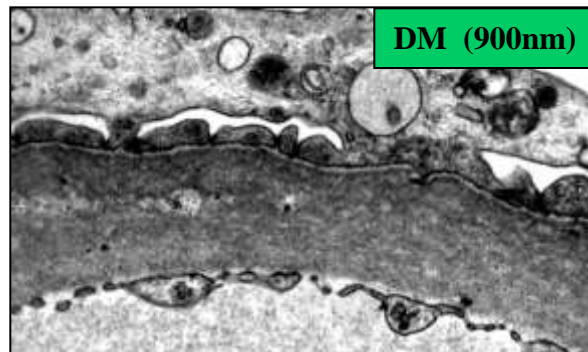
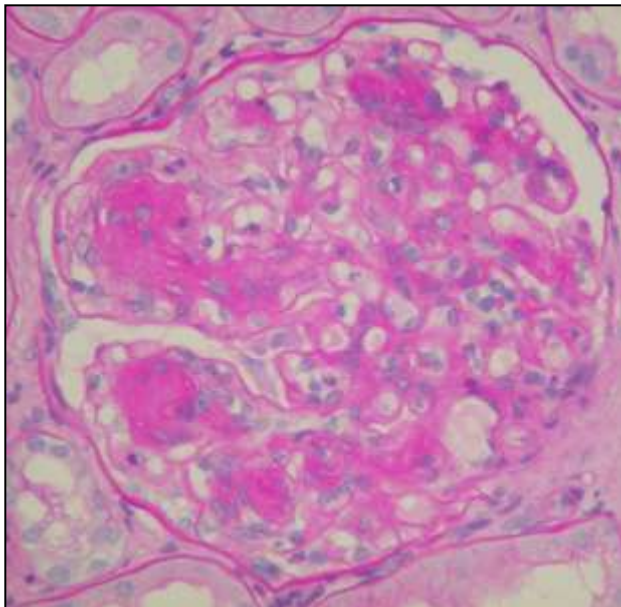
**Abnormal capillaries**

**Collapse/sclerosis**

**Thickening**

**Occlusion**

**Mesangial expansion**



**Diabetes glomerulopathy**

# Glomerular changes

**NORMOCELLULAR**

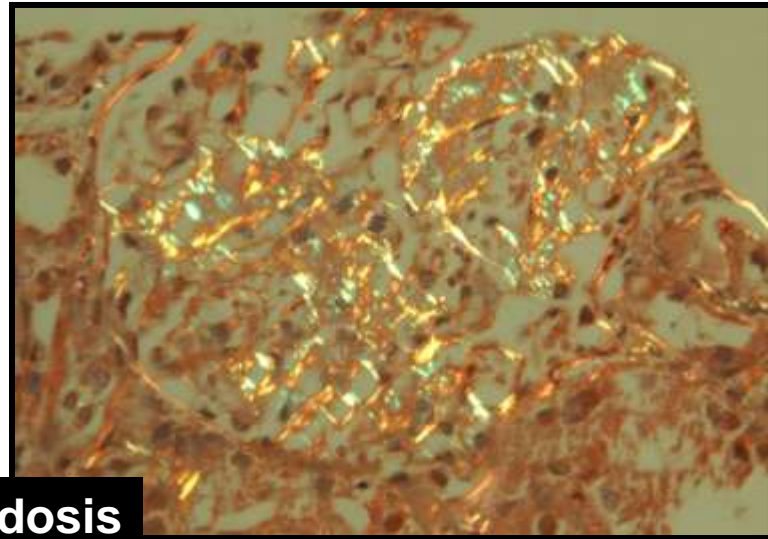
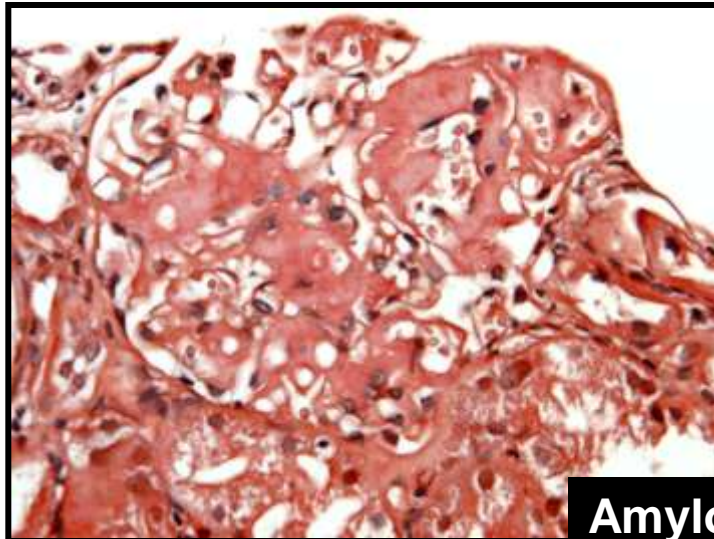
**Abnormal capillaries**

**Collapse/sclerosis**

**Thickening**

**Occlusion**

**Mesangial expansion**



**Amyloidosis**

# Glomerular changes

**NORMOCELLULAR**


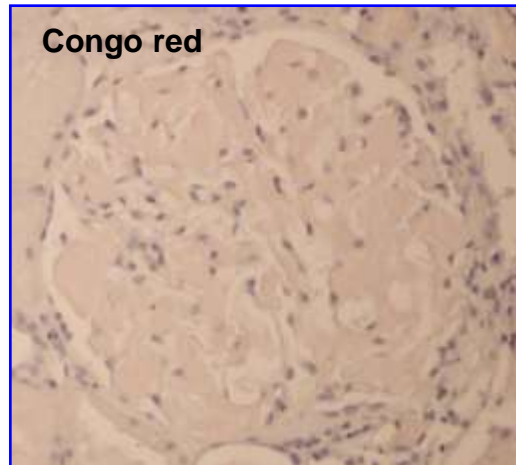
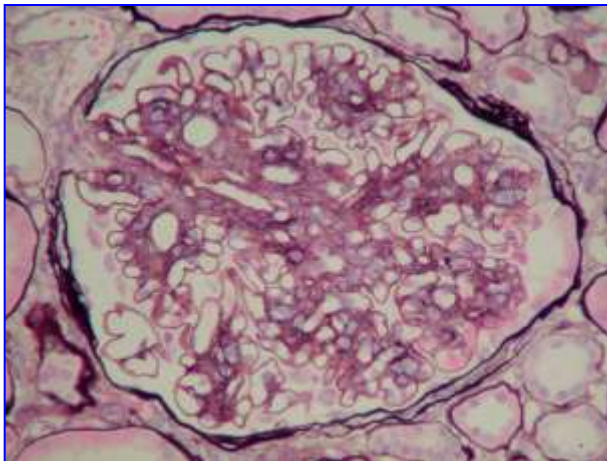
**Abnormal capillaries**

**Collapse/sclerosis**

**Thickening**

**Occlusion**

**Mesangial expansion**



**Fibrillary glomerulopathy**



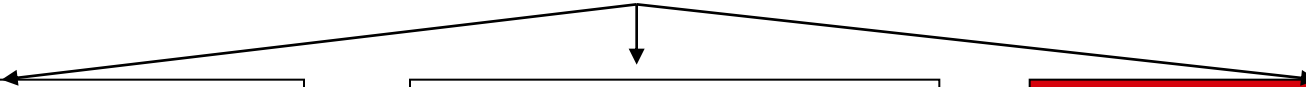
**Glomerular changes**



**NORMOCELLULAR**



**Abnormal capillaries**



**Collapse/sclerosis**

**Thickening**

**Occlusion**

# Glomerular changes



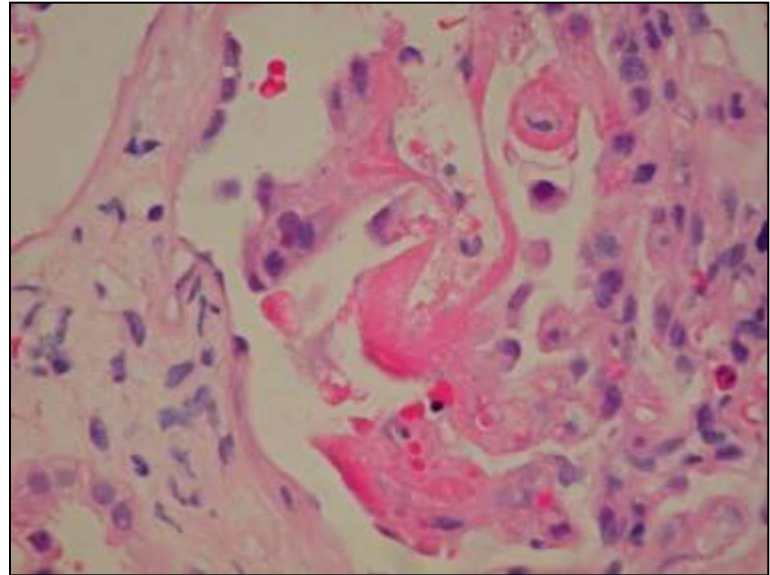
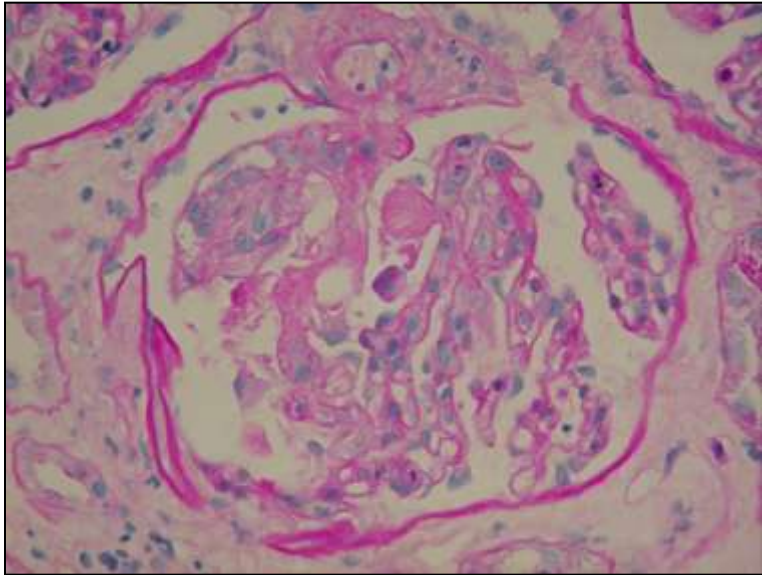
**NORMOCELLULAR**



**Abnormal capillaries**



**Occlusion**



**TTP (TMA)**

# Glomerular changes



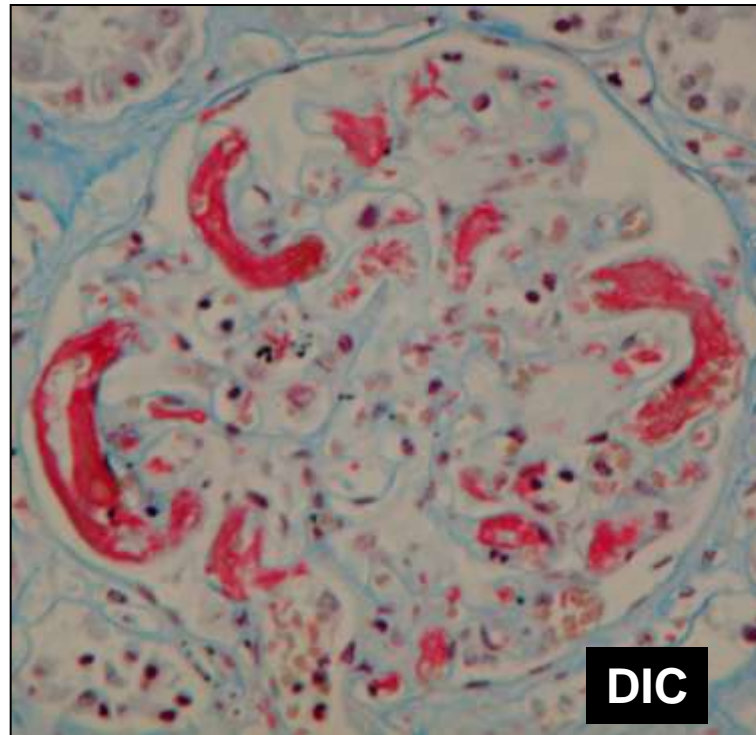
**NORMOCELLULAR**



**Abnormal capillaries**



**Occlusion**



# Glomerular changes



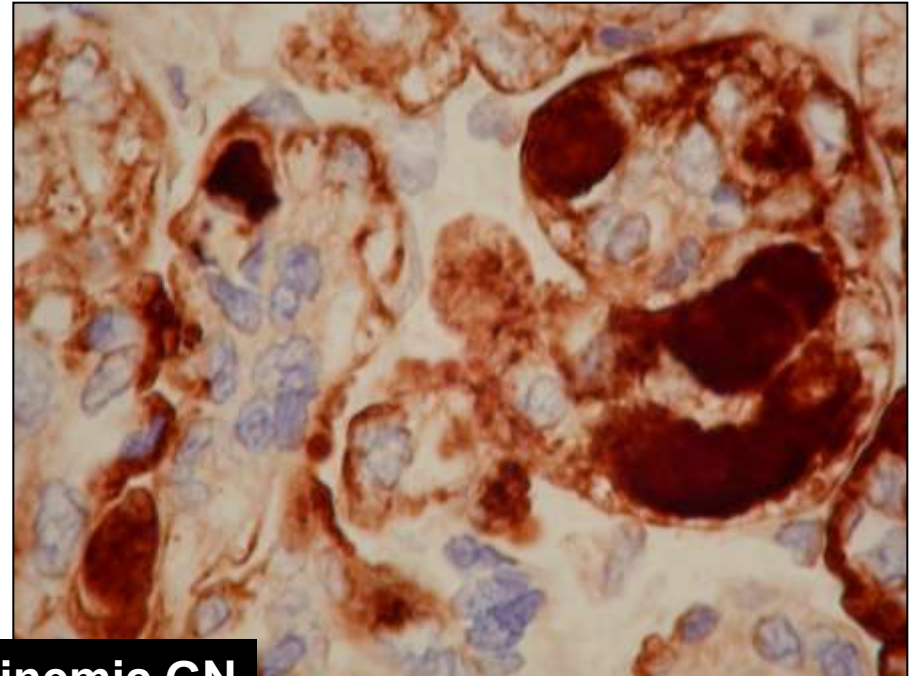
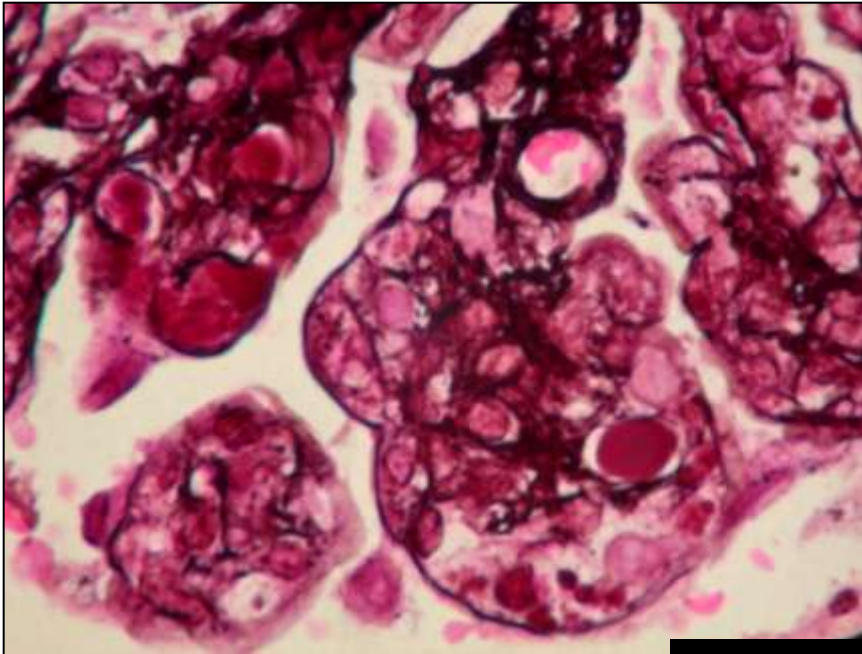
**NORMOCELLULAR**



**Abnormal capillaries**



**Occlusion**



**Cryoglobulinemic GN**

# Glomerular changes



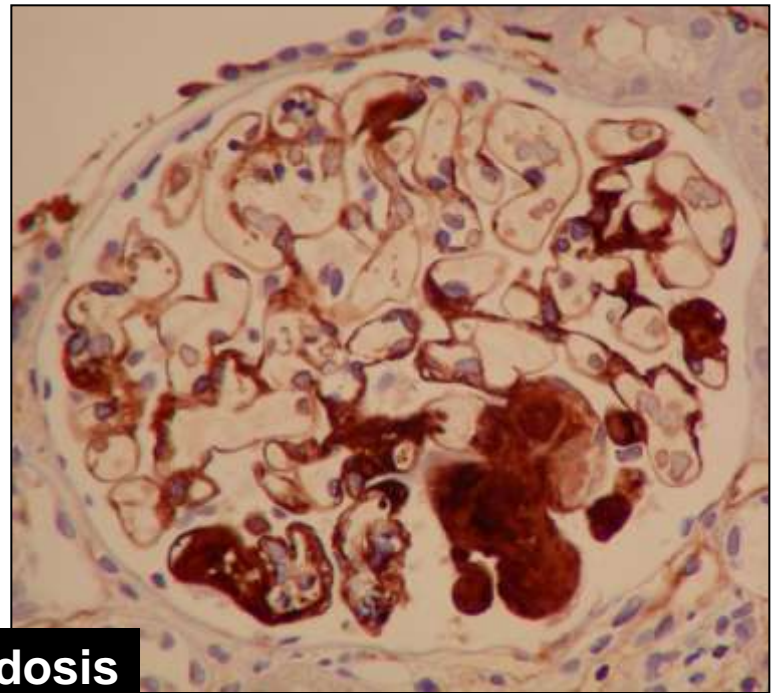
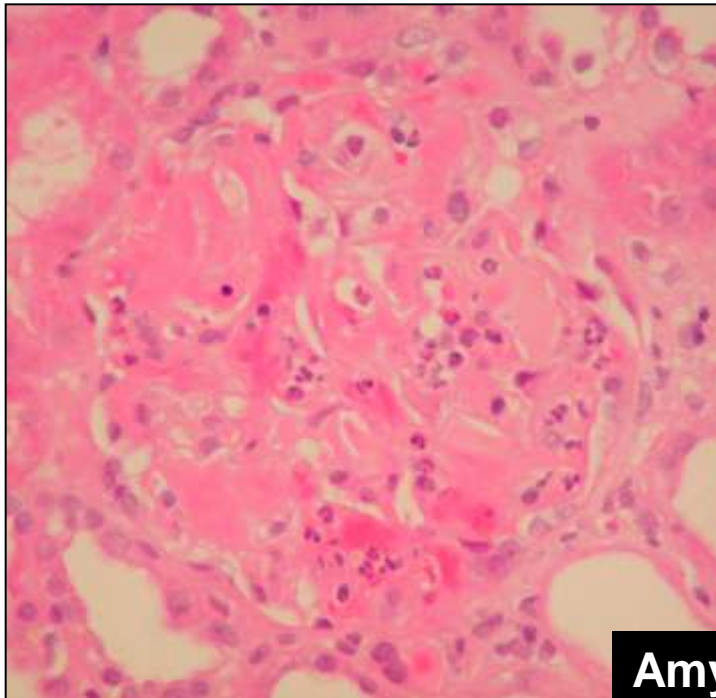
**NORMOCELLULAR**



**Abnormal capillaries**



**Occlusion**



**Amyloidosis**

# Glomerular changes

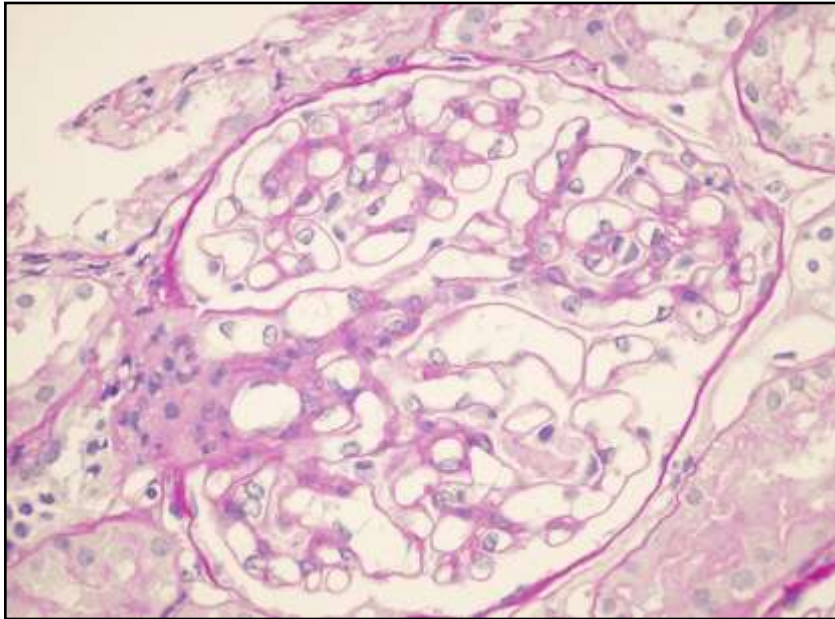
```
graph TD; A[Glomerular changes] --> B[NORMOCELLULAR]; A --> C[HYPERCELLULAR]
```

**NORMOCELLULAR**

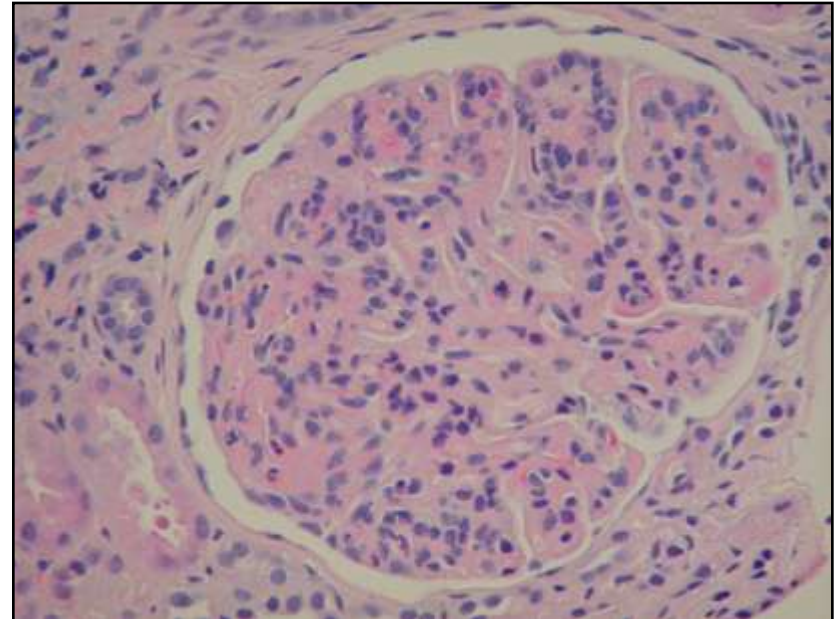
**HYPERCELLULAR**

# Glomerular changes

**NORMOCELLULAR**



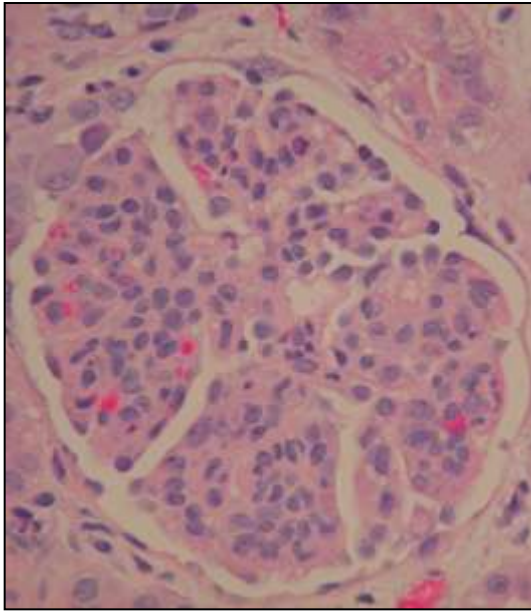
**HYPERCELLULAR**



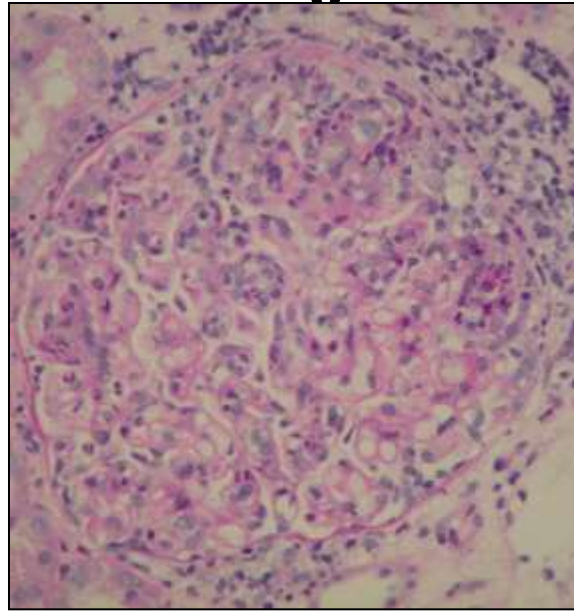
# Glomerular changes

## HYPERCELLULAR

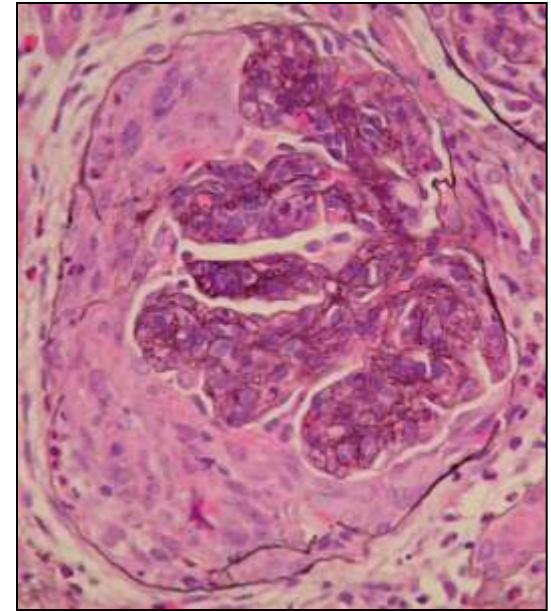
**Mesangial**



**Endocapillar**



**Extracapillary**

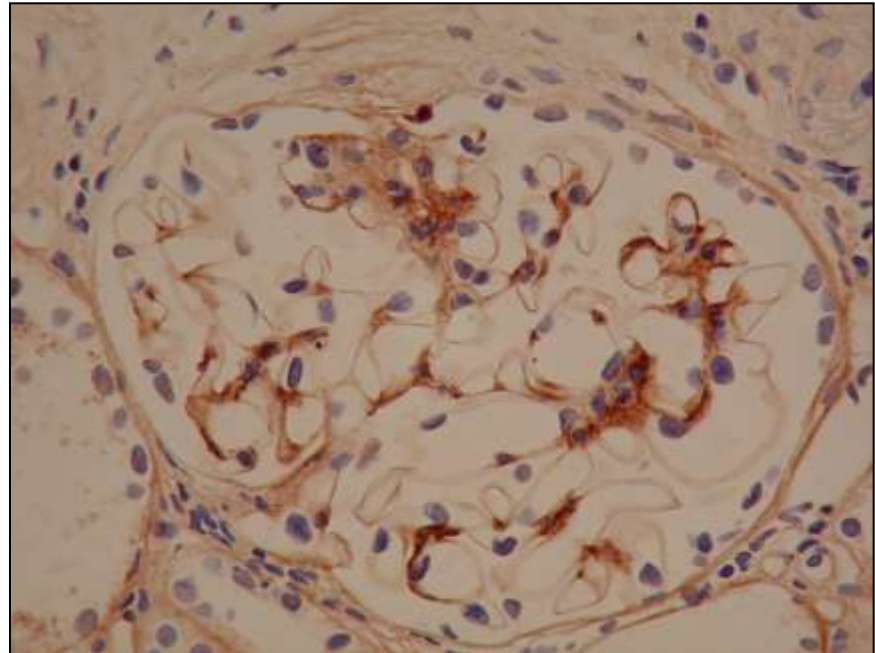
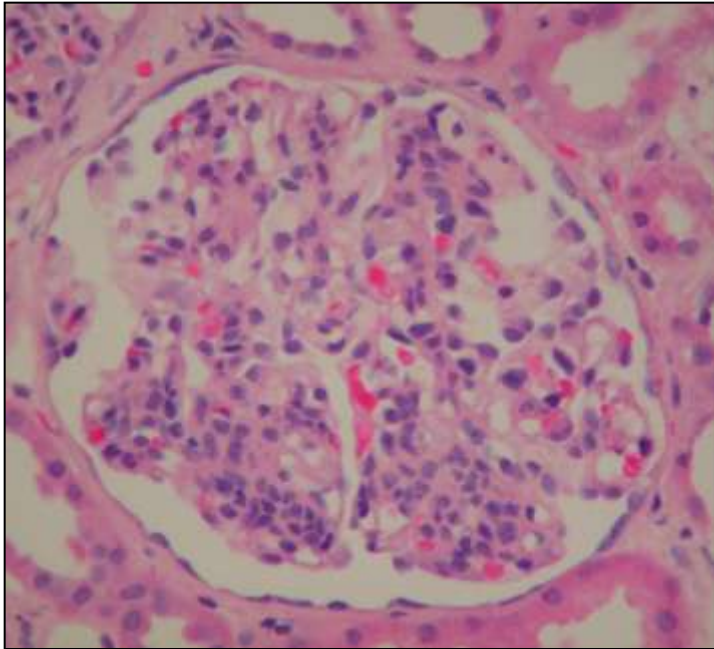




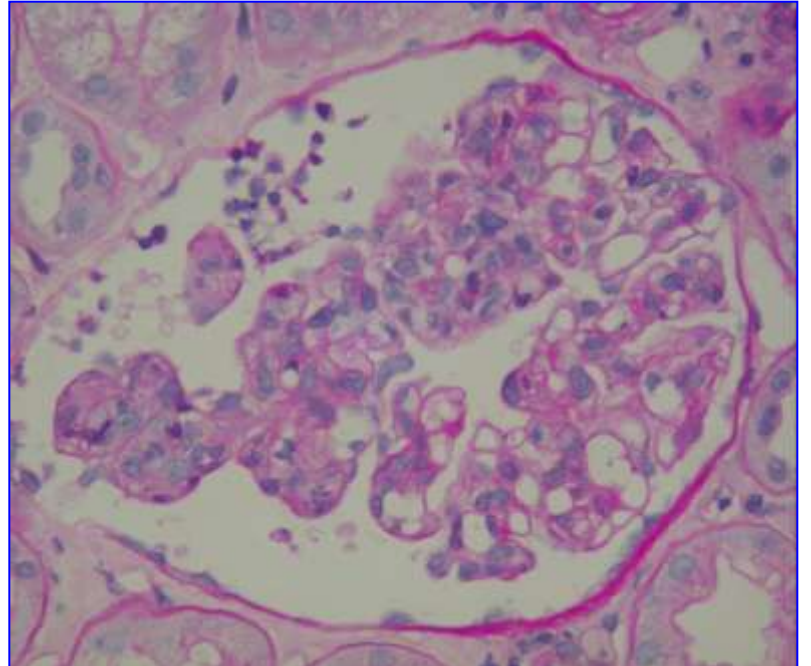
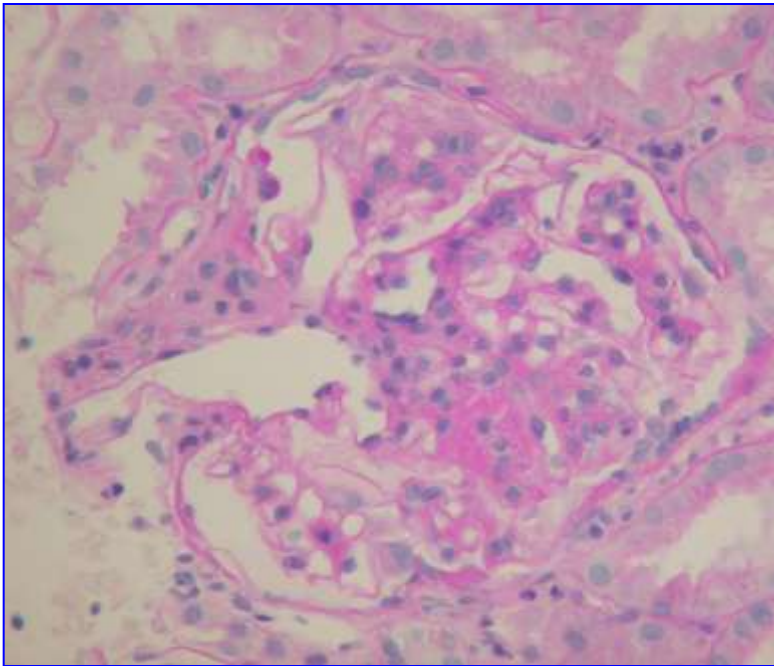
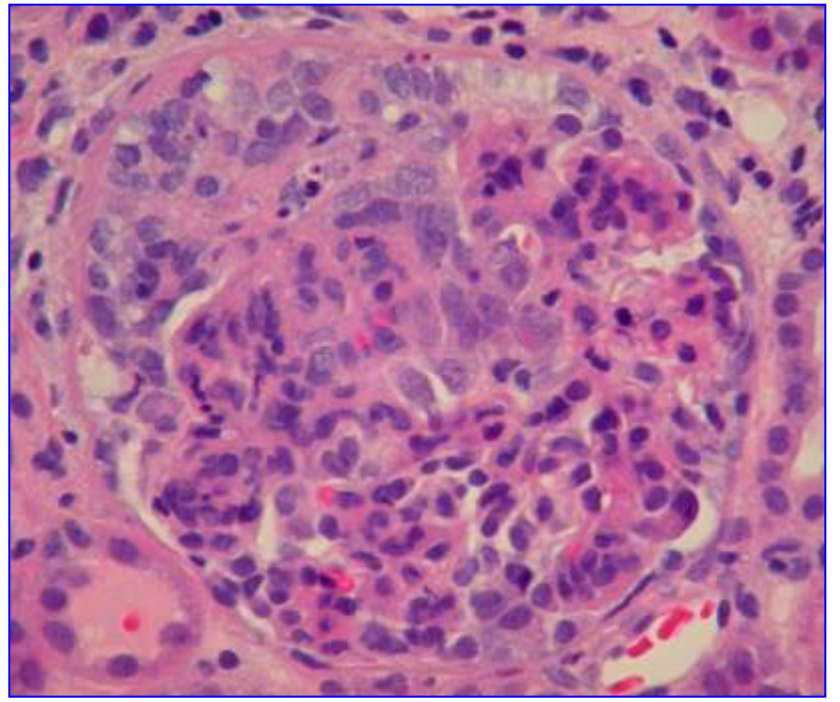
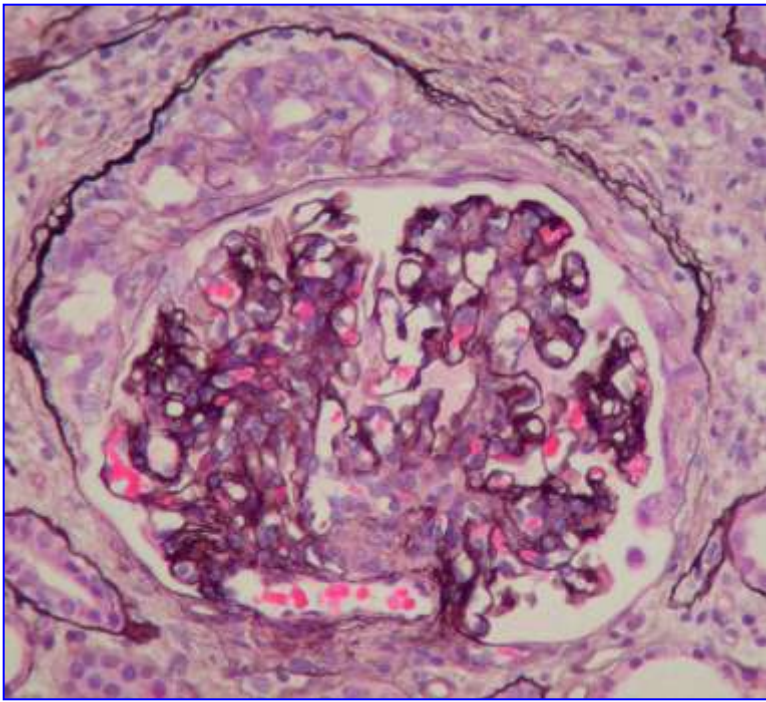
**Glomerular changes**

**HYPERCELLULAR**

**Mesangial**



**IgAN and HSPN**

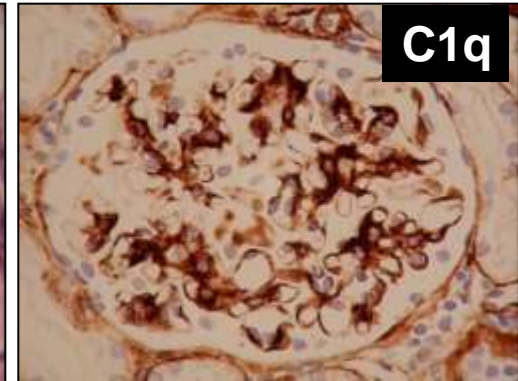
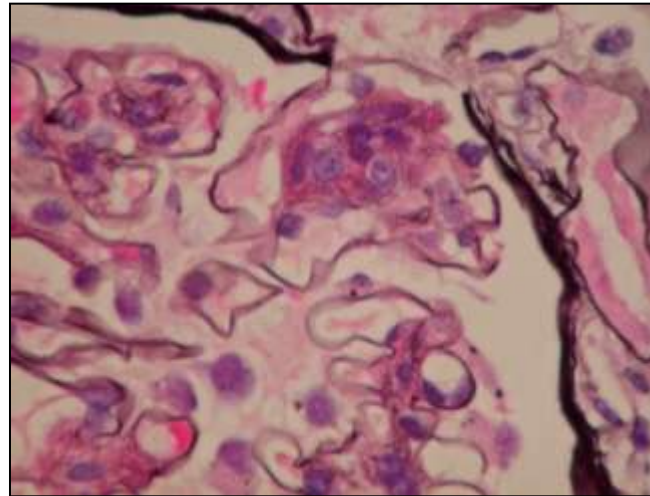
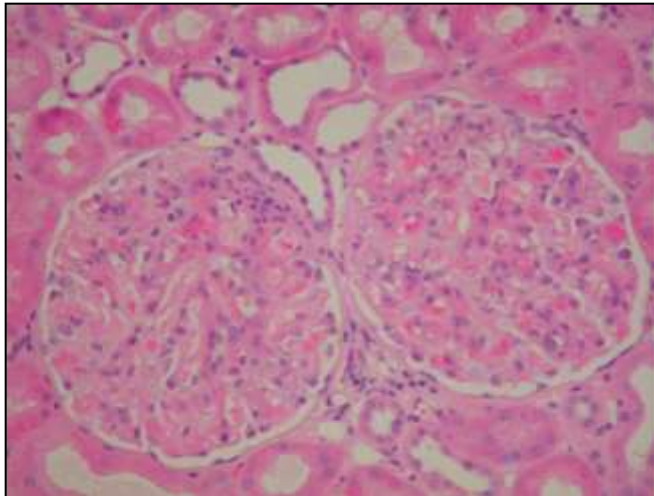


# Glomerular changes

↓  
**HYPERCELLULAR**

↓  
**Mesangial**

↓  
**Lupus Nephritis Class II.**



**Glomerular changes**



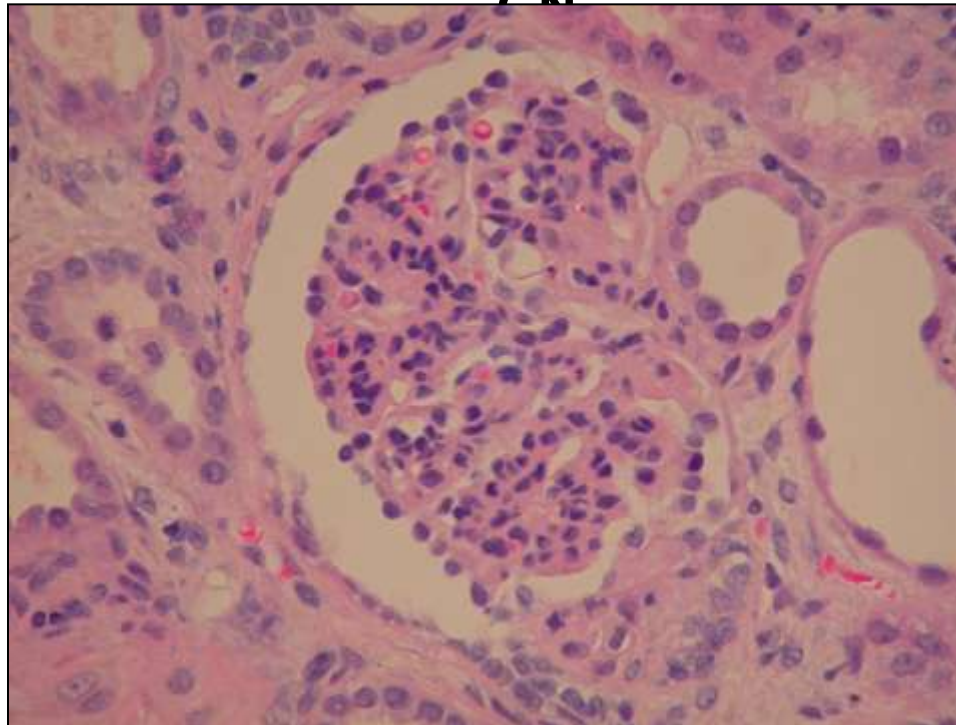
**HYPERCELLULAR**



**Mesangial**

**Resolving postinfectious**

**CN**



**Glomerular changes**



**HYPERCELLULAR**



**Endocapillary**



**Diffuse**



**Focal**

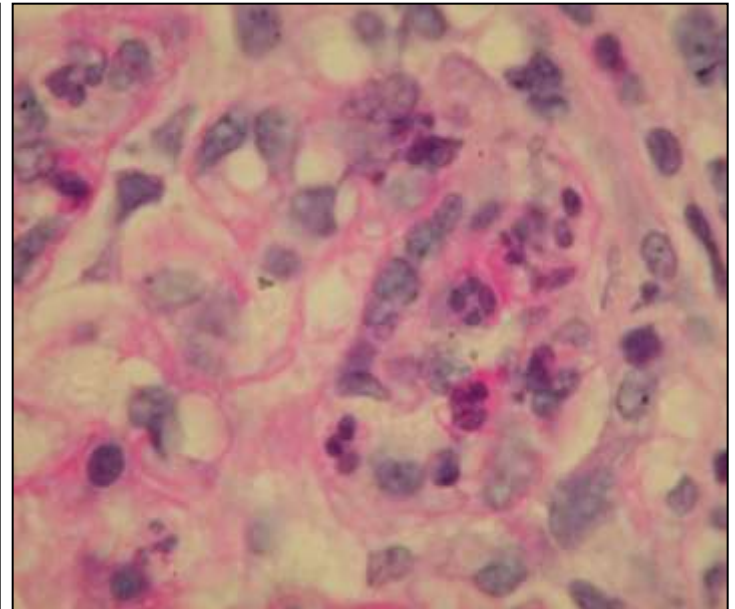
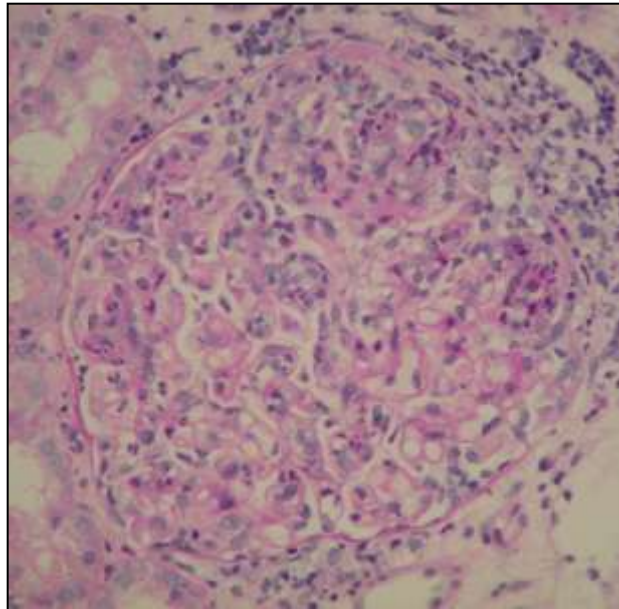
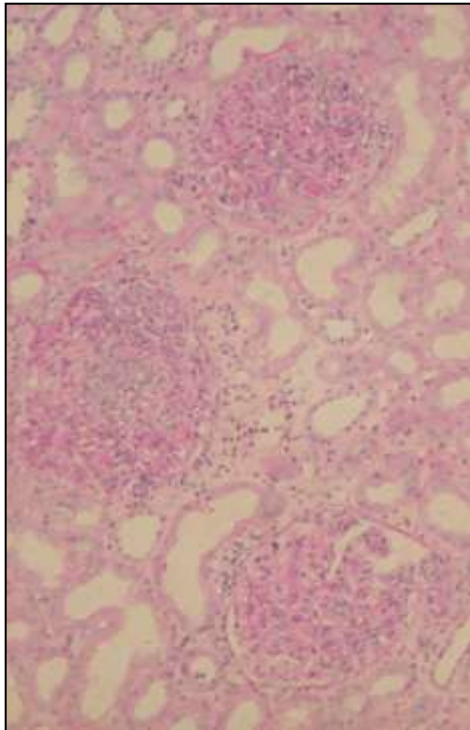
# Glomerular changes

**HYPERCELLULAR**

**Endocapillary**

**Diffuse**

**Acute postinfectious GN**



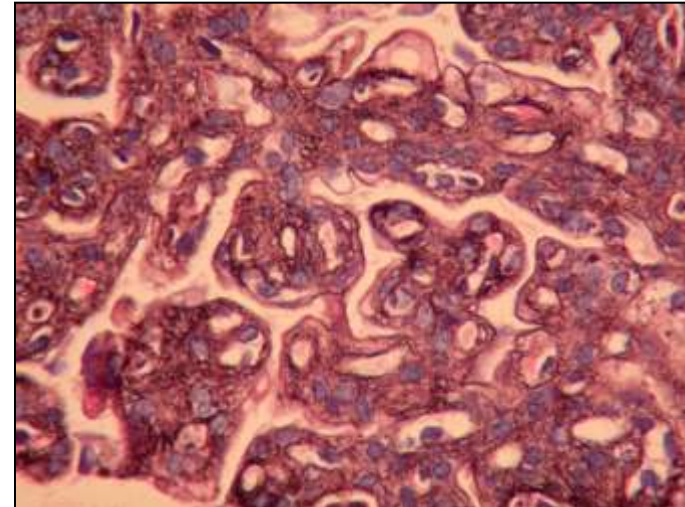
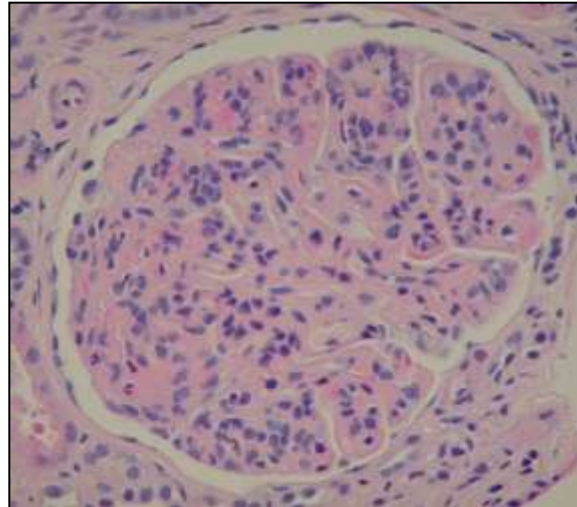
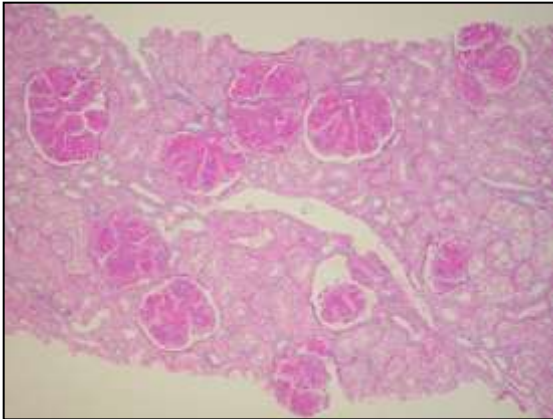
# Glomerular changes

**HYPERCELLULAR**

**Endocapillary**

**Diffuse**

**MPGN**



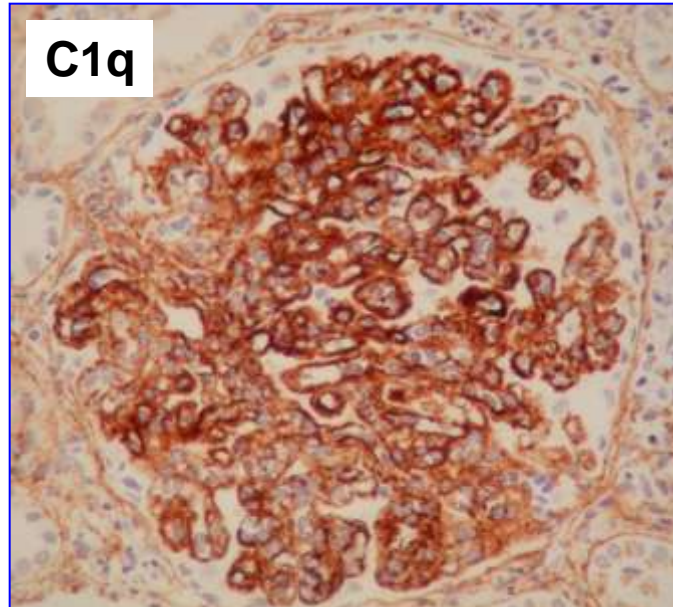
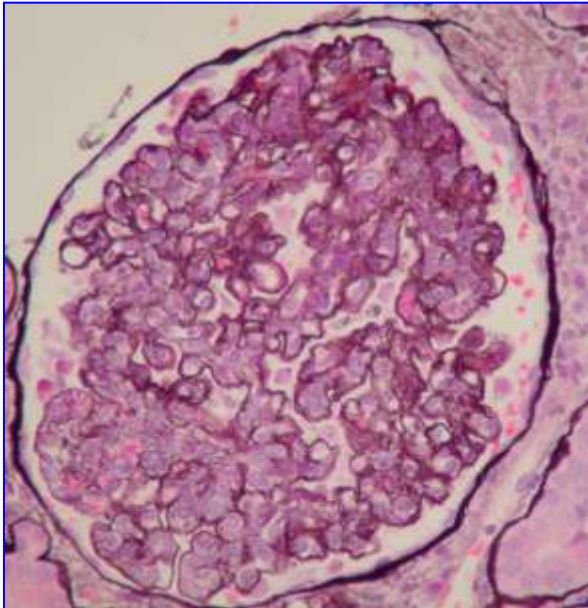
# Glomerular changes

**HYPERCELLULAR**

**Endocapillary**

**Diffuse**

**LN Class IV.**





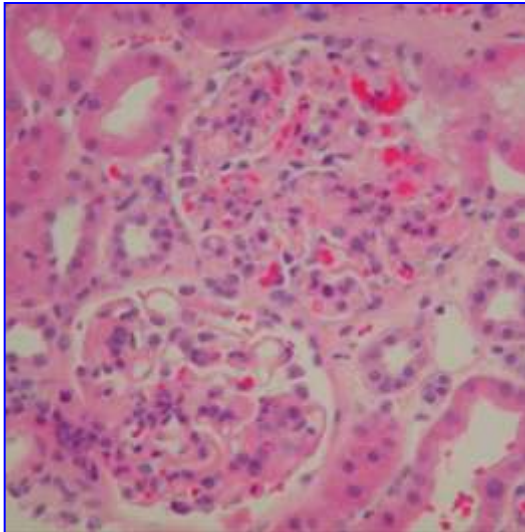
# Glomerular changes

**HYPERCELLULAR**

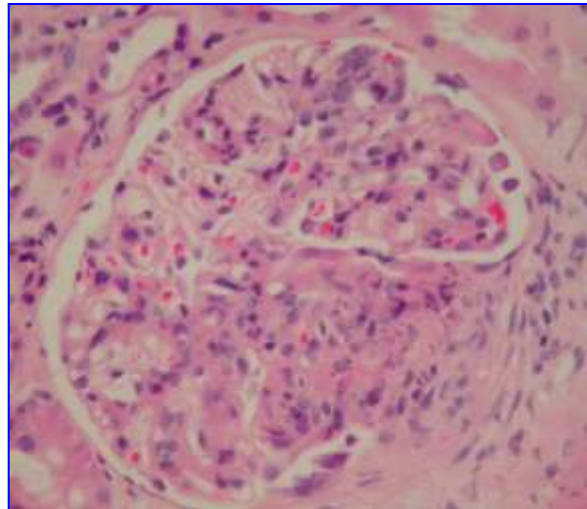
**Endocapillary**

**Focal**

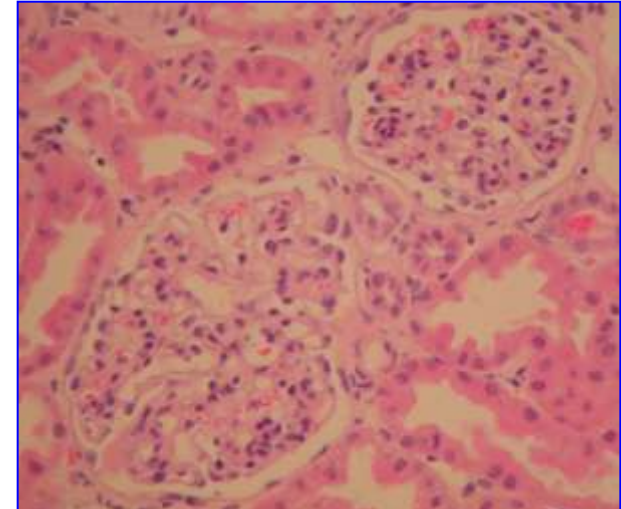
**Lupus N Class III.**



**Infectious endocarditis**



**IgA N**



**Glomerular changes**



**HYPERCELLULAR**



**Extracapillary**



**IF negative**



**IF positive**



**ANCA+**



**ANCA-**



**Idiopathic  
vasculitide**

**s**

# Glomerular changes

**HYPERCELLULAR**

**Extracapillary**

**IF negative**

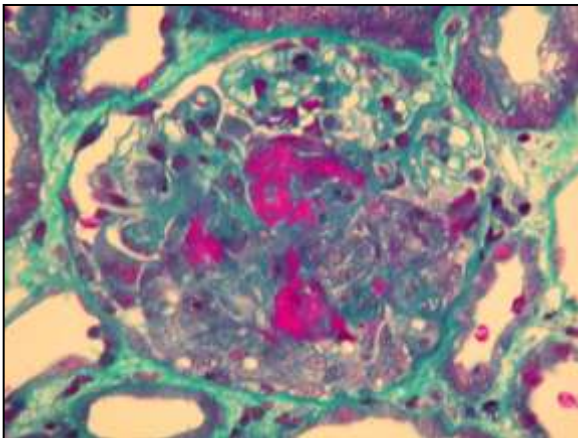
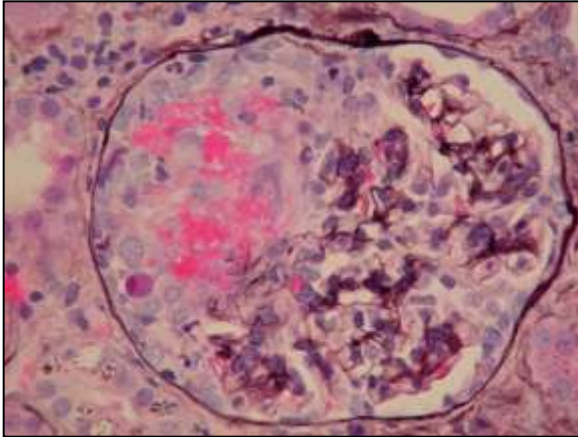
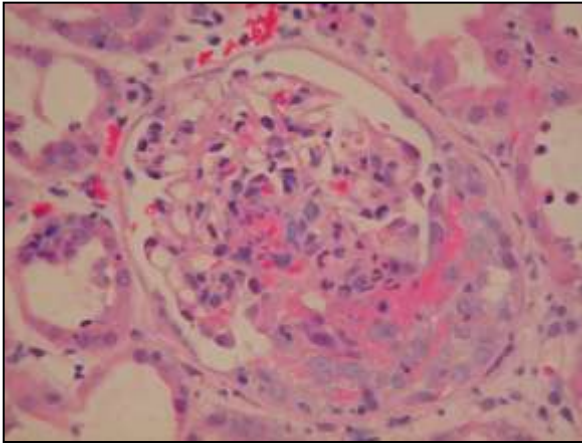
**ANCA+**

**Pauci immune GN**

**Microscopic polyangiitis**

**Wegener's granulomatosis**

**Churg-Strauss syndrome**



# Glomerular changes

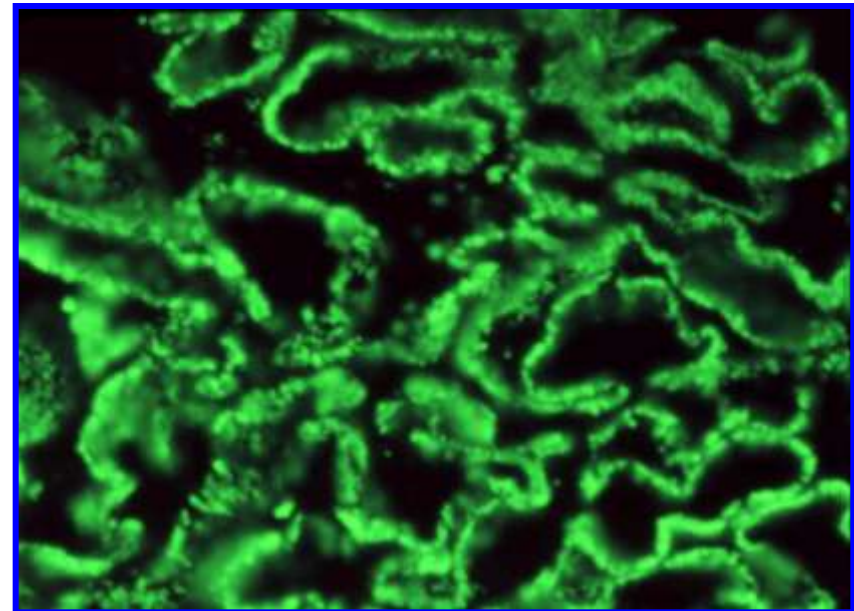
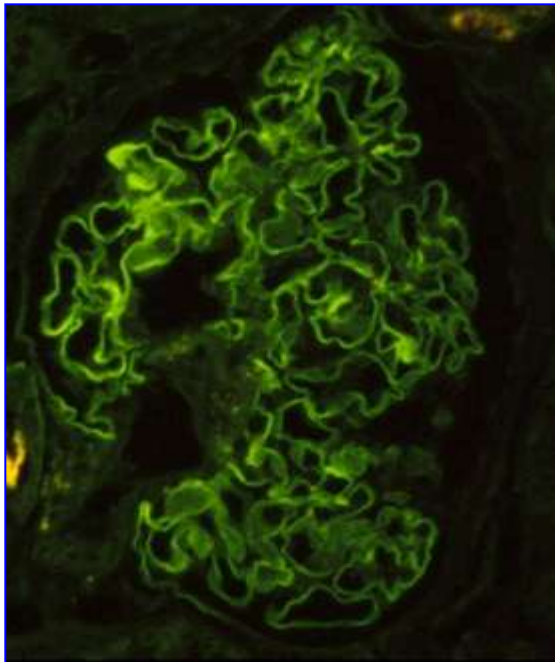
**HYPERCELLULAR**

**Extracapillary**

**IF positive**

**Linear pattern**

**Granular pattern**



# Glomerular changes

**HYPERCELLULAR**

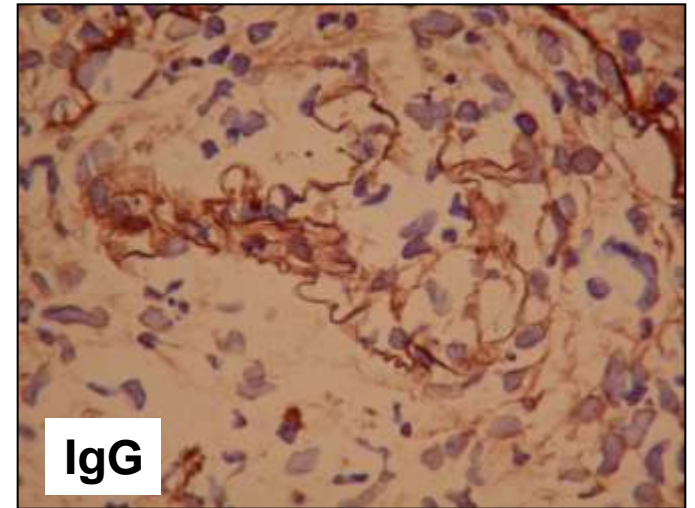
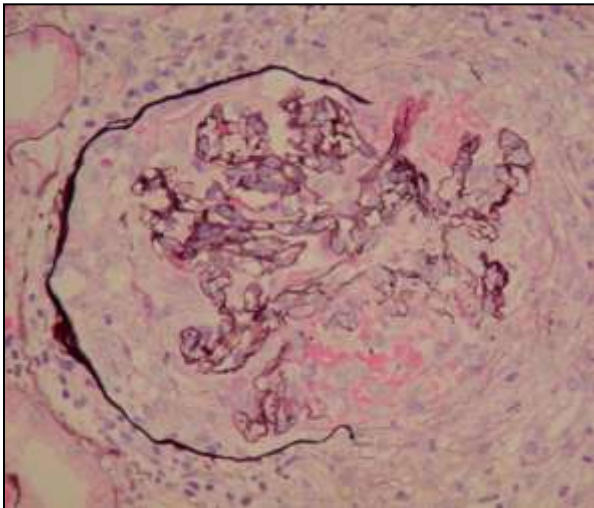
**Extracapillary**

**IF positive**

**Linear pattern**

**Anti-GBM GN**

**Goodpasture's  
syndrome**



# Glomerular changes

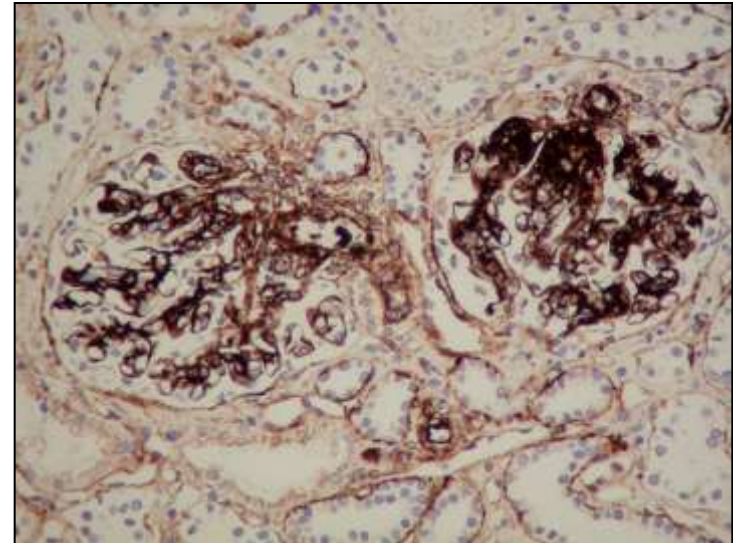
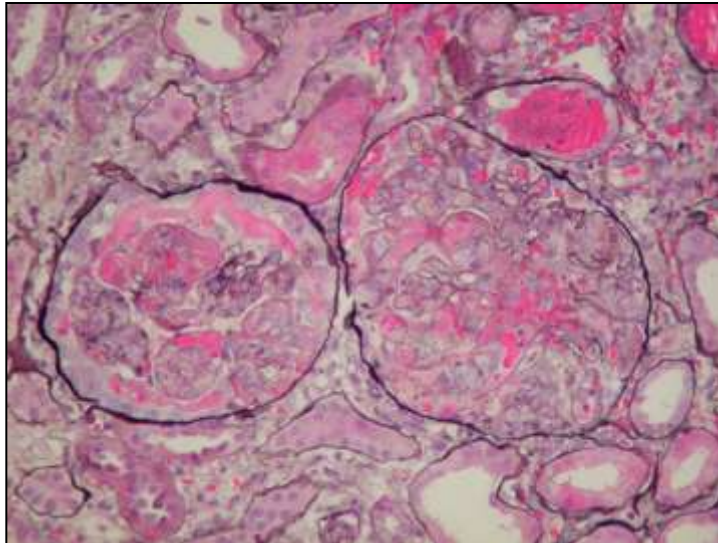
**HYPERCELLULAR**

**Extracapillary**

**IF positive**

**Granular  
pattern**

**IC mediated GN**



# Thank you for your attention

