

A microscopic image of ovarian tissue, likely a histological section stained with hematoxylin and eosin (H&E). The image shows several glandular structures, possibly representing the surface epithelium of the ovary or the fallopian tube. The glands are lined by a single layer of cuboidal cells, and the lumens are filled with secretory material. The surrounding stroma is composed of a dense population of small, blue-stained nuclei, likely representing the nuclei of the epithelial cells and the underlying connective tissue.

CHAPTER 2

Tumours of the Ovary and Peritoneum

Tumours of the ovary represent about 30% of all cancers of the female genital system. Age-adjusted incidence rates are highest in the economically advanced countries where they are almost as common as cancers of the corpus uteri and invasive cancer of the cervix. Carcinomas of surface epithelial-stromal origin account for 90% of these cancers in North America and Western Europe. In some Asian countries, including Japan, germ cell tumours account for a significant proportion (20%) of ovarian malignancies. High parity and the use of oral contraceptives are consistently associated with a reduced risk of developing surface epithelial-stromal tumours while long-term estrogen replacement therapy appears to increase the risk in postmenopausal women.

WHO histological classification of tumours of the ovary

Surface epithelial-stromal tumours		Metaplastic variant	9000/0
Serous tumours		Squamous cell tumours	
Malignant		Squamous cell carcinoma	8070/3
Adenocarcinoma	8441/3	Epidermoid cyst	
Surface papillary adenocarcinoma	8461/3	Mixed epithelial tumours (specify components)	
Adenocarcinofibroma (malignant adenofibroma)	9014/3	Malignant	8323/3
Borderline tumour	8442/1	Borderline	8323/1
Papillary cystic tumour	8462/1	Benign	8323/0
Surface papillary tumour	8463/1	Undifferentiated and unclassified tumours	
Adenofibroma, cystadenofibroma	9014/1	Undifferentiated carcinoma	8020/3
Benign		Adenocarcinoma, not otherwise specified	8140/3
Cystadenoma	8441/0		
Papillary cystadenoma	8460/0	Sex cord-stromal tumours	
Surface papilloma	8461/0	Granulosa-stromal cell tumours	
Adenofibroma and cystadenofibroma	9014/0	Granulosa cell tumour group	
Mucinous tumours		Adult granulosa cell tumour	8620/1
Malignant		Juvenile granulosa cell tumour	8622/1
Adenocarcinoma	8480/3	Thecoma-fibroma group	
Adenocarcinofibroma (malignant adenofibroma)	9015/3	Thecoma, not otherwise specified	8600/0
Borderline tumour	8472/1	Typical	8600/0
Intestinal type		Luteinized	8601/0
Endocervical-like		Fibroma	8810/0
Benign		Cellular fibroma	8810/1
Cystadenoma	8470/0	Fibrosarcoma	8810/3
Adenofibroma and cystadenofibroma	9015/0	Stromal tumour with minor sex cord elements	8593/1
Mucinous cystic tumour with mural nodules		Sclerosing stromal tumour	8602/0
Mucinous cystic tumour with pseudomyxoma peritonei	8480/3	Signet-ring stromal tumour	
Endometrioid tumours including variants with squamous differentiation		Unclassified (fibrothecoma)	
Malignant		Sertoli-stromal cell tumours	
Adenocarcinoma, not otherwise specified	8380/3	Sertoli-Leydig cell tumour group (androblastomas)	
Adenocarcinofibroma (malignant adenofibroma)	8381/3	Well differentiated	8631/0
Malignant müllerian mixed tumour	8950/3	Of intermediate differentiation	8631/1
(carcinosarcoma)		Variant with heterologous elements (specify type)	8634/1
Adenosarcoma	8933/3	Poorly differentiated (sarcomatoid)	8631/3
Endometrioid stromal sarcoma (low grade)	8931/3	Variant with heterologous elements (specify type)	8634/3
Undifferentiated ovarian sarcoma	8805/3	Retiform	8633/1
Borderline tumour		Variant with heterologous elements (specify type)	8634/1
Cystic tumour	8380/1	Sertoli cell tumour	8640/1
Adenofibroma and cystadenofibroma	8381/1	Stromal-Leydig cell tumour	
Benign		Sex cord-stromal tumours of mixed or unclassified cell types	
Cystadenoma	8380/0	Sex cord tumour with annular tubules	8623/1
Adenofibroma and cystadenofibroma	8381/0	Gynandroblastoma (specify components)	8632/1
Clear cell tumours		Sex cord-stromal tumour, unclassified	8590/1
Malignant		Steroid cell tumours	
Adenocarcinoma	8310/3	Stromal luteoma	8610/0
Adenocarcinofibroma (malignant adenofibroma)	8313/3	Leydig cell tumour group	
Borderline tumour		Hilus cell tumour	8660/0
Cystic tumour	8310/1	Leydig cell tumour, non-hilar type	8650/1
Adenofibroma and cystadenofibroma	8313/1	Leydig cell tumour, not otherwise specified	8650/1
Benign		Steroid cell tumour, not otherwise specified	8670/0
Cystadenoma	8310/0	Well differentiated	8670/0
Adenofibroma and cystadenofibroma	8313/0	Malignant	8670/3
Transitional cell tumours			
Malignant		Germ cell tumours	
Transitional cell carcinoma (non-Brenner type)	8120/3	Primitive germ cell tumours	
Malignant Brenner tumour	9000/3	Dysgerminoma	9060/3
Borderline		Yolk sac tumour	9071/3
Borderline Brenner tumour	9000/1	Polyvesicular vitelline tumour	
Proliferating variant	9000/1	Glandular variant	
Benign		Hepatoid variant	
Brenner tumour	9000/0	Embryonal carcinoma	9070/3

Polyembryoma	9072/3	Germ cell sex cord-stromal tumours	
Non-gestational choriocarcinoma	9100/3	Gonadoblastoma	9073/1
Mixed germ cell tumour (specify components)	9085/3	Variant with malignant germ cell tumour	
Biphasic or triphasic teratoma		Mixed germ cell-sex cord-stromal tumour	
Immature teratoma	9080/3	Variant with malignant germ cell tumour	
Mature teratoma	9080/0		
Solid		Tumours of the rete ovarii	
Cystic		Adenocarcinoma	9110/3
Dermoid cyst	9084/0	Adenoma	9110/0
Fetiform teratoma (homunculus)		Cystadenoma	
Monodermal teratoma and somatic-type tumours associated with dermoid cysts		Cystadenofibroma	
Thyroid tumour group		Miscellaneous tumours	
Struma ovarii		Small cell carcinoma, hypercalcaemic type	8041/3
Benign	9090/0	Small cell carcinoma, pulmonary type	8041/3
Malignant (specify type)	9090/3	Large cell neuroendocrine carcinoma	8013/3
Carcinoid group		Hepatoid carcinoma	8576/3
Insular	8240/3	Primary ovarian mesothelioma	9050/3
Trabecular	8240/3	Wilms tumour	8960/3
Mucinous	8243/3	Gestational choriocarcinoma	9100/3
Strumal carcinoid	9091/1	Hydatidiform mole	9100/0
Mixed		Adenoid cystic carcinoma	8200/3
Neuroectodermal tumour group		Basal cell tumour	8090/1
Ependymoma	9391/3	Ovarian wolffian tumour	9110/1
Primitive neuroectodermal tumour	9473/3	Paraganglioma	8693/1
Medulloepithelioma	9501/3	Myxoma	8840/0
Glioblastoma multiforme	9440/3	Soft tissue tumours not specific to the ovary	
Others		Others	
Carcinoma group		Tumour-like conditions	
Squamous cell carcinoma	8070/3	Luteoma of pregnancy	
Adenocarcinoma	8140/3	Stromal hyperthecosis	
Others		Stromal hyperplasia	
Melanocytic group		Fibromatosis	
Malignant melanoma	8720/3	Massive ovarian oedema	
Melanocytic naevus	8720/0	Others	
Sarcoma group (specify type)		Lymphoid and haematopoietic tumours	
Sebaceous tumour group		Malignant lymphoma (specify type)	
Sebaceous adenoma	8410/0	Leukaemia (specify type)	
Sebaceous carcinoma	8410/3	Plasmacytoma	9734/3
Pituitary-type tumour group			
Retinal anlage tumour group	9363/0		
Others			
		Secondary tumours	

¹ Morphology code of the International Classification of Diseases for Oncology (ICD-O) {921} and the Systematized Nomenclature of Medicine (<http://snomed.org>). Behaviour is coded /0 for benign tumours, /3 for malignant tumours, and /1 for borderline or uncertain behaviour.

WHO histological classification of tumours of the peritoneum

Peritoneal tumours		Tumour of uncertain origin	
Mesothelial tumours		Desmoplastic small round cell tumour	8806/3
Diffuse malignant mesothelioma	9050/3	Epithelial tumours	
Well differentiated papillary mesothelioma	9052/0	Primary peritoneal serous adenocarcinoma	8461/3
Multicystic mesothelioma	9055/1	Primary peritoneal borderline tumour (specify type)	
Adenomatoid tumour	9054/0	Others	
Smooth muscle tumour			
Leiomyomatosis peritonealis disseminata			

¹ Morphology code of the International Classification of Diseases for Oncology (ICD-O) {921} and the Systematized Nomenclature of Medicine (<http://snomed.org>). Behaviour is coded /0 for benign tumours, /3 for malignant tumours, and /1 for borderline or uncertain behaviour.

TNM and FIGO classification of tumours of the ovary

TNM and FIGO classification ^{1,2,3}			T3c and/or N1	IIIC	Peritoneal metastasis beyond pelvis more than 2 cm in greatest dimension and/or regional lymph node metastasis	
T – Primary Tumour			M1	IV	Distant metastasis (excludes peritoneal metastasis)	
TNM Categories	FIGO Stages		Note: Liver capsule metastasis is T3/stage III, liver parenchymal metastasis M1/stage IV. Pleural effusion must have positive cytology for M1/stage IV.			
TX		Primary tumour cannot be assessed	N – Regional Lymph Nodes ⁴			
T0		No evidence of primary tumour	NX		Regional lymph nodes cannot be assessed	
T1	I	Tumour limited to the ovaries	N0		No regional lymph node metastasis	
T1a	IA	Tumour limited to one ovary; capsule intact, no tumour on ovarian surface; no malignant cells in ascites or peritoneal washings	N1		Regional lymph node metastasis	
T1b	IB	Tumour limited to both ovaries; capsule intact, no tumour on ovarian surface; no malignant cells in ascites or peritoneal washings	M – Distant Metastasis			
T1c	IC	Tumour limited to one or both ovaries with any of the following: capsule ruptured, tumour on ovarian surface, malignant cells in ascites or peritoneal washings	MX		Distant metastasis cannot be assessed	
T2	II	Tumour involves one or both ovaries with pelvic extension	M0		No distant metastasis	
T2a	IIA	Extension and/or implants on uterus and/or tube(s); no malignant cells in ascites or peritoneal washings	M1		Distant metastasis	
T2b	IIB	Extension to other pelvic tissues; no malignant cells in ascites or peritoneal washings	Stage Grouping			
T2c	IIC	Pelvic extension (2a or 2b) with malignant cells in ascites or peritoneal washings	Stage IA	T1a	N0	M0
T3 and/or N1	III	Tumour involves one or both ovaries with microscopically confirmed peritoneal metastasis outside the pelvis and/or regional lymph node metastasis	Stage IB	T1b	N0	M0
T3a	IIIA	Microscopic peritoneal metastasis beyond pelvis	Stage IC	T1c	N0	M0
T3b	IIIB	Macroscopic peritoneal metastasis beyond pelvis	Stage IIA	T2a	N0	M0
		2 cm or less in greatest dimension	Stage IIB	T2b	N0	M0
			Stage IIC	T2c	N0	M0
			Stage IIIA	T3a	N0	M0
			Stage IIIB	T3b	N0	M0
			Stage IIIC	T3c	N0	M0
				Any T	N1	M0
			Stage IV	Any T	Any N	M1

¹ {51,2976}.

² A help desk for specific questions about the TNM classification is available at <http://tnm.uicc.org>.

³ The classification applies to malignant surface epithelial-stromal tumours including those of borderline malignancy. Non-epithelial ovarian cancers may also be classified using this scheme.

⁴ The regional lymph nodes are the hypogastric (obturator), common iliac, external iliac, lateral sacral, para-aortic, and inguinal nodes.

¹ {51,2976}.

² A help desk for specific questions about the TNM classification is available at <http://tnm.uicc.org>.

³ The classification applies to malignant surface epithelial-stromal tumours including those of borderline malignancy.

Non-epithelial ovarian cancers may also be classified using this scheme.

⁴ The regional lymph nodes are the hypogastric (obturator), common iliac, external iliac, lateral sacral, para-aortic, and inguinal nodes.

Surface epithelial-stromal tumours

K.R. Lee
F.A. Tavassoli
J. Prat
M. Dietel
D.J. Gersell
A.I. Karseladze
S. Hauptmann
J. Rutgers

P. Russell
C.H. Buckley
P. Pisani
P. Schwartz
D.E. Goldgar
E. Silva
R. Caduff
R.A. Kubik-Huch

Definition

Surface epithelial-stromal tumours are the most common neoplasms of the ovary. They originate from the ovarian surface epithelium or its derivatives and occur in women of reproductive age and beyond. They are histologically composed of one or more distinctive types of epithelium, admixed with a variable amount of stroma. Their biological behaviour varies with histological type.

Epidemiology

Cancer of the ovary represents about 30% of all cancers of the female genital organs. In developed countries it is about as common as cancers of the corpus uteri (35%) and invasive cancer of the cervix (27%). The age-adjusted incidence rates vary from less than 2 new cases per 100,000 women in most of Southeast Asia and Africa to over 15 cases in Northern and Eastern Europe. The economically advanced countries of North America, Europe, Australia, New Zealand and temperate South America show the highest rates. In the United States more women die from ovarian cancer today than from all other pelvic gynaecological cancer sites combined {1066}. Incidence rates have been either stable or have shown slow increases in most western countries, whereas they have risen steadily in parts of Eastern Asia.

Aetiology

Two factors consistently associated with a reduced risk of the disease are high parity and the use of oral contraceptives {1295,2474}. Three recent studies have shown an increased risk of ovarian cancer in postmenopausal women treated with high-dose estrogen replacement therapy for 10 years or greater {963, 2373,2399}. Very little is known of the aetiology of non-familial cases. The protective effects of pregnancies and of oral contraception suggest a direct role for ovulation in causing the disease, but no

convincing mechanism linking the risk factors with malignant transformation has been proposed.

Several dietary factors have been related to ovarian cancer {819}. There is emerging evidence that the Western lifestyle, in particular, obesity, is associated with an increased risk {388}.

Clinical features

Signs and symptoms

Women with ovarian cancer have a poor prognosis. The mean 5-year survival rate in Europe is 32% {256}. This unfavourable outcome is largely ascribed to a lack of early warning symptoms and a lack of diagnostic tests that allow early detection. As a result, approximately 70% of patients present when this cancer is in an advanced stage, i.e. it has metastasized to the upper abdomen or beyond the abdominal cavity {394}. It is now recognized that the overwhelming majority of women diagnosed with ovarian cancer actually have symptoms, but they are subtle and easily confused with

those of various benign entities, particularly those related to the gastrointestinal tract {1024,2106}.

Physical signs associated with early stage ovarian cancer may be limited to palpation by pelvic examination of a mobile, but somewhat irregular, pelvic mass (stage I). As the disease spreads into the pelvic cavity, nodules may be found in the cul-de-sac, particularly on bimanual rectovaginal examination (stage II). Ascites may occur even when the malignancy is limited to one or both ovaries (stage IC). As the disease involves the upper abdomen, ascites may be evident. A physical examination of the abdomen may demonstrate flank bulging and fluid waves associated with the ascites. Metastatic disease is commonly found in the omentum, such that the latter may be readily identified in the presence of advanced stage (stage III) ovarian cancer as a ballottable or palpable mass in the mid-abdomen, usually superior to the umbilicus and above the palpable pelvic mass. Finally, the

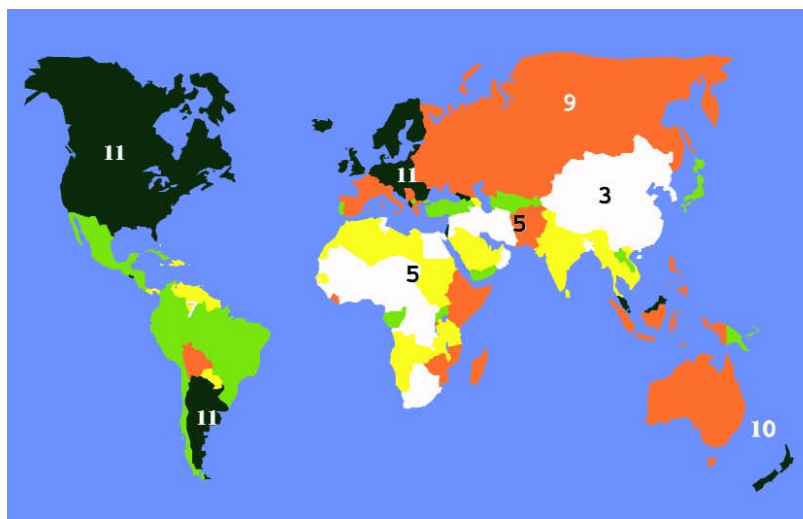


Fig. 2.01 Global incidence rates of ovarian cancer. Age-standardized rates (ASR) per 100,000 population and year. From Globocan 2000 {846}.

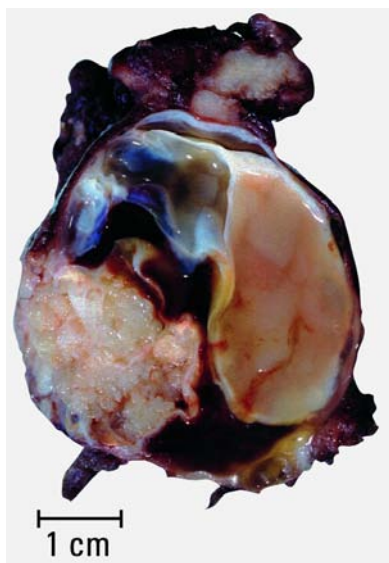


Fig. 2.02 Serous adenocarcinoma. The sectioned surface of the tumour shows two solid nodules within a multiloculated cyst.

disease may spread through lymphatics to either the inguinal or left supraclavicular lymph nodes, which may be readily palpable. It may advance into the pleural cavity as a malignant effusion, usually on the right side or bilateral, in which case the lung bases exhibit dullness to percussion and decreased breath sounds and egophony to auscultation (stage IV). Advanced intra-abdominal ovarian carcinomatosis may also present with signs of intestinal obstruction including nausea, vomiting and abdominal pain.

Imaging

Due to its wide availability, ultrasound (US) is the imaging method of choice to assess an ovarian lesion and to determine the presence of solid and cystic elements. The distinction between benign, borderline and malignant tumours is generally not possible by US, either alone or in combination with magnetic resonance imaging (MRI) or computed tomography (CT). None of these methods has a clearly established role in pre-operative tumour staging. Surgical exploration remains the standard approach for staging [1116,1417,1522,1795,2898].

Tumour spread and staging

About 70-75% of patients with ovarian cancer have tumour spread beyond the pelvis at the time of diagnosis [1770]. Ovarian cancers spread mainly by local extension, by intra-abdominal dissemination and by lymphatic dissemination, but rarely also through the blood stream. The International Federation of Gynecology and Obstetrics (FIGO) Committee on Gynecologic Oncology is responsible for the staging system that is used internationally today [217]. The pTNM-system is based on the postoperative pathological staging for histological control and confirmation of the disease. [51,2976].

Histogenesis

The likely origin of ovarian surface epithelial-stromal tumours is the mesothelial surface lining of the ovaries and/or invaginations of this lining into the superficial ovarian cortex that form inclusion cysts [838].

Genetic susceptibility

Familial clustering

Numerous epidemiological investigations of ovarian cancer have attempted to quantify the risks associated with a positive family history. Whereas ovarian cancer has not been as extensively studied as breast cancer, several studies point to familial clustering. The relative risk of ovarian cancer for first degree relatives varies from 1.94 to 25.5, the latter if both a mother and sister are affected [1029,2557,2801].

BRCA1/2

A number of specific genes have been identified as playing a role. The most important of these, BRCA1 and BRCA2, are discussed in chapter 8. In contrast to breast cancer in which only a minority of the familial clustering could be explained by known major susceptibility loci such as BRCA1 and BRCA2, it is likely that the majority of the familial risk of ovarian cancer is explained by BRCA1 and to a lesser extent BRCA2, MLH1 and MSH2. Using statistical modelling and the results from BRCA1 and BRCA2 mutation testing in 112 families with at least two cases of ovarian cancer (allowing for insensitivity of the mutation detection assay), BRCA1 and BRCA2 accounted for nearly all of the non-chance familial aggregation [973].

HNPCC

Ovarian cancer is a minor feature of the hereditary nonpolyposis colon cancer syndrome caused by mutations in genes associated with DNA base mismatch repair, the most frequent of which are *MLH1* and *MSH2*.

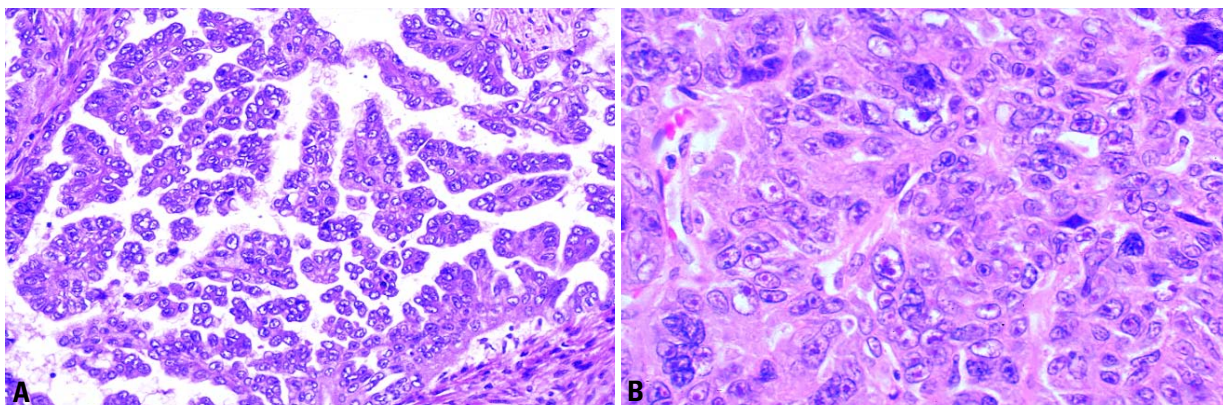


Fig. 2.03 Serous adenocarcinoma. **A** The tumour is composed of closely packed papillae most of which lack fibrous cores lined by cells with atypical nuclei and high nuclear to cytoplasmic ratios. **B** This poorly differentiated tumour shows relatively solid papillary aggregates without fibrovascular cores and scattered bizarre, pleomorphic nuclei. Cherry red nucleoli are apparent in some nuclei.

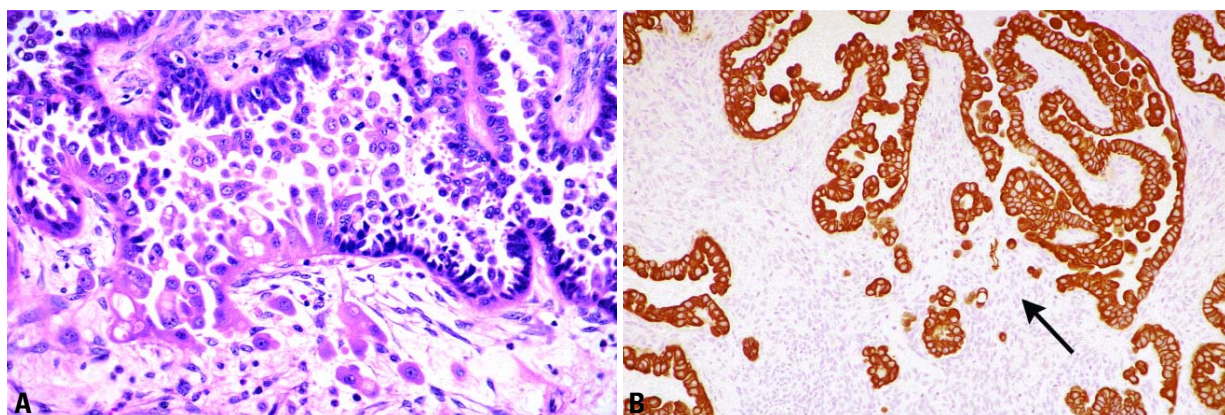


Fig. 2.04 **A** Serous borderline tumour with microinvasion. There is a transition from the typical small serous cells to cells with more abundant eosinophilic cytoplasm associated with disruption of the epithelial/stromal interface; the latter cell population invades the underlying stroma as isolated cells and small cell clusters in the lower part of the field. **B** Small clusters of cells and single cells within the stroma indicating microinvasion (arrow) in the lower central part of the field are demonstrated by cytokeratin immunohistochemistry.

Association with endometrial cancer

Several studies provide evidence of associations between ovarian and other cancers, particularly endometrial [715, 1029]. The relative risk of developing endometrial cancer is about 1.5 among mothers and sisters of ovarian cancer cases, although in both studies the risk fell just short of statistical significance.

Serous tumours

Definition

Ovarian tumours characterized in their better-differentiated forms by cell types resembling those of the fallopian tube.

ICD-O codes

Serous adenocarcinoma	8441/3
Serous borderline tumour	8442/1
Benign serous tumours	
Serous papillary cystadenoma	8460/0
Serous cystadenoma	8441/0
Serous surface papilloma	8461/0
Serous adenofibroma, cystadenofibroma	9014/0

Serous adenocarcinoma

Definition

An invasive ovarian epithelial neoplasm composed of cells ranging in appearance from those resembling fallopian tube epithelium in well differentiated tumours to anaplastic epithelial cells with severe nuclear atypia in poorly differentiated tumours.

Macroscopy

The tumours range from not being macroscopically detectable to over 20-cm in diameter and are bilateral in two-thirds of all cases, but only in one-third of stage I cases. Well differentiated tumours are solid and cystic with soft papillae within the cystic spaces or on the surface. The papillae tend to be softer and more confluent than in cases of borderline tumours. Rare tumours are confined to the ovarian surface. Poorly differentiated tumours are solid, friable, multinodular masses with necrosis and haemorrhage.

Histopathology

The architecture of the tumour varies from glandular to papillary to solid. The glands are typically slit-like or irregular. The papillae are usually irregularly branching and highly cellular. In poorly differentiated tumours solid areas are usually extensive and composed of poorly differentiated cells in sheets with small papillary clusters separated by myxoid or hyaline stroma. Psammoma bodies may be present in varying numbers. The stroma may be scanty or desmoplastic. Serous carcinomas may contain a variety of other cell types as a minor component (less than 10%) that may cause diagnostic problems but do not influence the outcome. Serous psammocarcinoma is a rare variant of serous carcinoma characterized by massive psammoma body formation and low grade cytological features. The epithelium is arranged in small

nests with no areas of solid epithelial proliferation, and at least 75% of the epithelial nests are associated with psammoma body formation [1001].

Immunoprofile

Serous carcinomas are always cytokeratin 7 positive and cytokeratin 20 negative. They are also positive for epithelial membrane antigen, CAM5.2, AE1/AE3, B72.3 and Leu M1 and for CA125 in 85% of the cases, but negative for calretinin and other mesothelial markers.

Grading

Various grading systems have been proposed for serous carcinomas. The utilization of a three-tiered grading system is recommended since the tumour grade has important prognostic and therapeutic implications [2687].

Somatic genetics

The prevailing view of the pathogenesis of serous adenocarcinoma is that it arises directly from the ovarian surface epithelium, invaginations or epithelial inclusions and progresses rapidly [205]. At present, serous carcinoma is regarded as a relatively homogeneous group of tumours from the standpoint of pathogenesis. Thus, although these neoplasms are graded as well, moderately and poorly differentiated, they are thought to represent a spectrum of differentiation reflecting progression from a low grade to a high grade malignancy. Whereas in colorectal carcinoma a

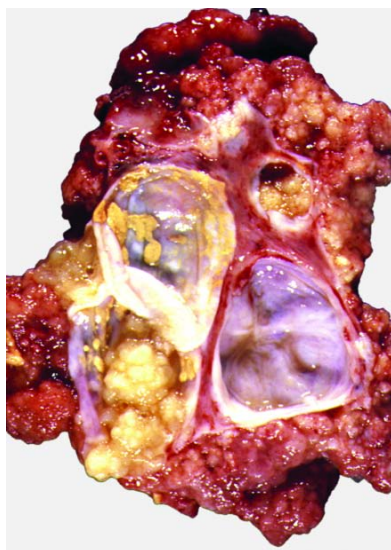


Fig. 2.05 Serous borderline tumour. The sectioned surface shows a solid and cystic neoplasm with numerous papillary excrescences.

tumour progression model in which sequential accumulation of molecular genetic alterations leading to morphologically recognizable stages is well established [1468], a similar model for ovarian serous carcinoma has not been proposed because well defined precursor lesions have not been identified.

It has been reported that even the earliest histological serous carcinomas are already high grade and morphologically resemble their advanced stage counterparts [205]. The histological similarities are paralleled by recent molecular genetic findings demonstrating *TP53* mutations in very small stage I serous carcinomas and in the adjacent "dysplastic" surface epithelium [2275]. Most studies have shown that approximately 60% of advanced stage ovarian serous carcinomas have mutant *TP53* [230,3095]. Thus, although the molecular genetic findings in these early carcinomas are preliminary, they suggest that serous carcinoma in its very earliest stage of development resembles advanced stage serous carcinoma at the molecular level. This would support the view that there are no morphologically recognized intermediate steps in the progression of the conventional type of ovarian serous carcinoma. Serous borderline tumours (SBTs), non-invasive and invasive micropapillary types, frequently display *KRAS* mutations but rarely mutant *TP53*. Increased allelic

imbalance of chromosome 5q is associated with the progression from typical SBT to micropapillary SBT and increased allelic imbalance of chromosome 1p with the progression from micropapillary SBT to invasive serous carcinoma [2706]. In contrast, *KRAS* mutations are very rare in conventional serous carcinoma, but *TP53* mutations occur in approximately 60%.

Recently, mutations were also identified in the *BRAF* gene, a downstream mediator of *KRAS*. *BRAF* and *KRAS* mutations appear to be mutually exclusive. These mutations were only detected in low grade ovarian serous carcinomas [2707]. Thus, there appears to be more than one pathway of tumorigenesis for serous carcinoma. In one pathway, conventional serous carcinoma, a high grade neoplasm, develops "de novo" from the surface epithelium of the ovary, grows rapidly and is highly aggressive [205]. These tumours, even at their earliest stage, display *TP53* mutations but not *KRAS* mutations. In the other pathway a SBT progresses in a "stepwise" fashion through a non-invasive micropapillary stage before becoming invasive [2706] or through microinvasion in a background of typical SBT. The indolent micropapillary tumours frequently display *KRAS* mutations, but *TP53* mutations are only rarely detected.

Genetic susceptibility

The neoplasms that develop in women with germline *BRCA1* mutations are mostly serous carcinomas of the ovary, fallopian tube and peritoneum.

Prognosis and predictive factors

The overall 5-year survival is approximately 40%; however, many of those alive at 5 years are alive with disease. Up to 85% of cases present with widespread metastatic disease. Survival at 5 years in this group is 10-20%. Patients with disease confined

to the ovary or pelvis have a 5-year survival of 80%. Patients with serous psammocarcinoma have a protracted clinical course and a relatively favourable prognosis; their clinical behaviour more closely resembles that of SBT than serous carcinoma of the usual type.

Serous borderline tumour with microinvasion

Definition

An ovarian serous tumour of low malignant potential exhibiting early stromal invasion characterized by the presence in the stroma of individual or clusters of neoplastic cells cytologically similar to those of the associated non-invasive tumour. One or more foci may be present; none should exceed 10 mm².

Synonyms

Serous tumour of low malignant potential with microinvasion, serous tumour of borderline malignancy with microinvasion.

Epidemiology

Present in about 10-15% of SBTs, microinvasion occurs in women ranging in age from 17-83 years with a median age of 34.5 years [203,2867].

Clinical features

Most symptomatic women present with a pelvic mass or pain. About 28% of the 39 women in the 2 major series were pregnant at the time of presentation [203,2867].

Macroscopy

The macroscopic features are similar to those of SBT without microinvasion.

Tumour spread and staging

At presentation about 60% of the neoplasms are stage IA, 13% stage 1B, 5% stage IC, 8% stage IIC, 10% stage III (mostly IIIC) and 2.5% stage IV (liver metastases).

Histopathology

The hallmark of serous borderline tumours with microinvasion is the presence within the tumour stroma of single cells and cell clusters with generally abundant eosinophilic cytoplasm morphologically identical to those of the adjacent non-invasive tumour. The microinvasive foci form micropapillary, solid or rarely cribriform arrangements without or with only minimal stromal or cellular reaction. These cells are often

Table 2.01

Histological criteria for the diagnosis of serous borderline tumours.

- Epithelial hyperplasia in the form of stratification, tufting, cribriform and micropapillary arrangements
- Atypia (usually mild to moderate)
- Detached cell clusters
- Variable and usually minimal mitotic activity
- Absence of destructive stromal invasion

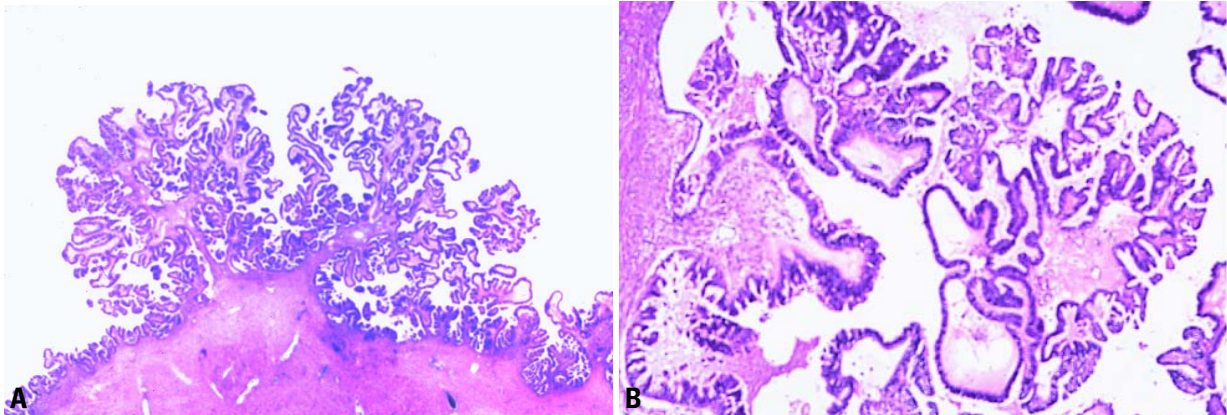


Fig. 2.06 Serous borderline tumour, typical pattern. **A** The epithelial papillae show hierarchical and complex branching without stromal invasion. **B** Higher magnification shows stratification and tufting of the epithelium with moderate atypia.

located within empty stromal spaces, but vascular space invasion occurs in 10% of cases. In 87% of the 39 reported cases the invasive cells were of the eosinophilic cell type [203,2867]. The lymph nodes were rarely assessed as part of staging for these tumours. Tumour cells, mainly of the eosinophilic cell type, were found in three nodes (obturator, external iliac, and para-aortic) from two women [203,2867].

Prognosis and predictive factors

The behaviour of SBTs with microinvasion is similar to that of SBTs without microinvasion. In one series long-term follow-up was available in 11 cases with a 5-year survival of 100% and a 10-year survival of 86% [2285]. Unilateral salpingo-oophorectomy is currently acceptable therapy for young women who wish to preserve fertility.

Serous borderline tumour

Definition

An ovarian tumour of low malignant potential exhibiting an atypical epithelial proliferation of serous type cells greater than that seen in their benign counterparts but without destructive stromal invasion.

Synonyms

Serous tumour of low malignant potential, serous tumour of borderline malignancy. The designation "atypical proliferative serous tumour" is not recommended because it discourages complete surgical staging [2285] and because long term follow up indicates that some patients with typical SBT do not follow a benign course [3946].

Epidemiology

Patients with SBT are approximately 10-15 years younger than those with serous carcinoma (i.e. 45 years vs. 60 years). About 30-50% of SBTs are bilateral.

Clinical features

Signs and symptoms

The tumour is often asymptomatic but may rarely present with abdominal enlargement or pain due to rupture of a cystic tumour or torsion. In younger women SBT has been associated with a high rate of infertility [2894a].

Macroscopy

The tumour may be cystic with a variable number of excrescences, form a solid purely surface papillary growth or have a combination of these appearances. In

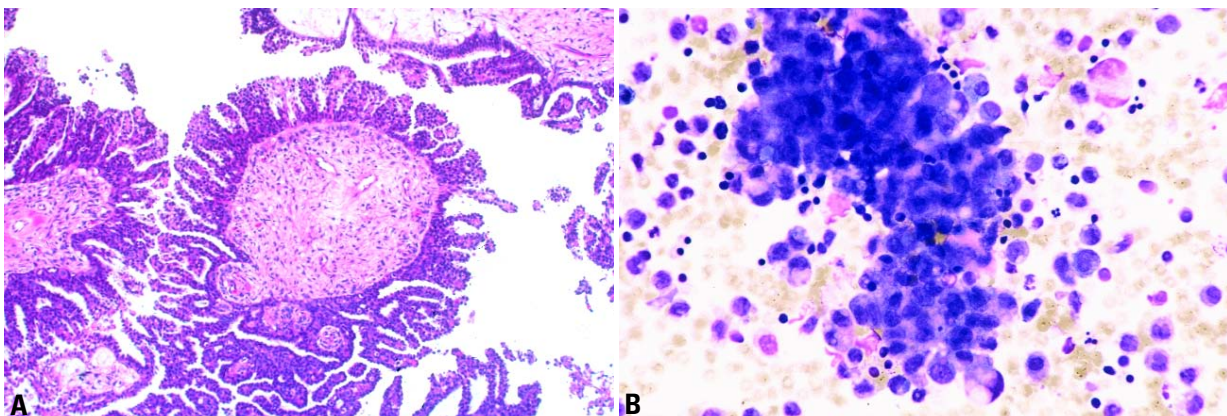


Fig. 2.07 Serous borderline tumour with micropapillary pattern. **A** Note the filigree papillae with non-hierarchical processes. **B** Peritoneal cytology shows a three-dimensional papillary-like tumour cell formation with low grade nuclear atypia mixed with mesothelial and inflammatory cells.

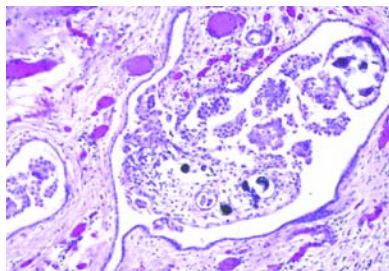


Fig. 2.08 Non-invasive peritoneal implant, epithelial type. The implant consists of hierarchical branching papillae within cystic spaces.

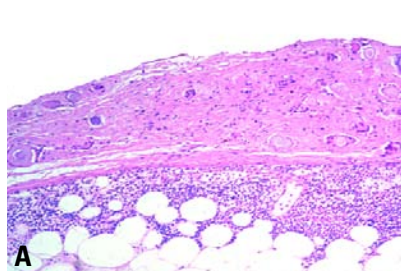


Fig. 2.09 Non-invasive peritoneal implant, desmoplastic type. **A** The implant is plastered on the peritoneal surface without destructive invasion of the underlying tissue. **B** The epithelial aggregates show moderate cellular atypia, and only a small portion of the implant is made up of epithelial cells.

contrast to carcinomas, SBTs generally lack areas of necrosis and haemorrhage. The cysts usually contain serous fluid, but occasionally it is mucinous.

Tumour spread and staging

Stage I SBTs are confined to the inner surface of the cyst with no spread beyond the ovary. The staging of SBT follows the TNM/FIGO system for carcinomas [51, 2976].

Histopathology

The hallmarks of SBT that distinguish it from a cystadenoma are the presence of epithelial hyperplasia forming papillae

(with fibroedematous stalks), micropapillae associated with "detached" or "floating" cell clusters and mild to moderate nuclear atypia. It is distinguished from serous carcinoma by the lack of destructive stromal invasion. The proliferating cells vary from uniform, small cells with hyperchromatic nuclei to larger cells displaying eosinophilic cytoplasm with variable and generally low mitotic activity. Psammoma bodies may be present but are less abundant than in serous carcinomas.

SBTs are divided into typical and micropapillary types. The typical type makes up the vast majority (90%) of SBTs and has a classic branching papillary

architecture and epithelial tufts overlying the papillae. The micropapillary type accounts for a small proportion (5-10%) of tumours. This type shows focal or diffuse proliferation of the tumour cells in elongated, thin micropapillae with little or no stromal support emerging directly from the lining of a cyst, from large papillae in a non-hierarchical pattern or from the surface of the ovary. The micropapillae are at least five times as long as they are wide, arising directly from papillae with a thick fibrous stalk (non-hierarchical branching creating a "Medusa head-like appearance"). Less common patterns are cribriform and almost solid proliferations of non-invasive cells overlying papillary stalks. A continuous 5-mm growth of any of these three patterns is required for the diagnosis of micropapillary SBT.

Up to 30% of SBTs are associated with tumour on the outer surface of the ovary, and about two-thirds are associated with peritoneal implants [376,2615].

Serous surface borderline tumour

In this variant, polypoid excrescences formed by fine papillae with features of SBT occupy the outer surface of the ovary.

Serous borderline adenofibroma and cystadenofibroma

In this variant, the epithelial lining of the glands and/or cysts of the adenofibroma or cystadenofibroma has the features of SBT instead of benign epithelium.

Peritoneal implants

Two prognostically different types of peritoneal implants have been identified, non-invasive and invasive. The former is further subdivided into desmoplastic and epithelial types. Whereas the non-invasive implants (regardless of their type) have almost no negative influence on the

Table 2.02

Serous borderline tumours. Histology of non-invasive vs. invasive peritoneal implants.

Non-invasive implants
Extension into interlobular fibrous septa of the omentum Lacks disorderly infiltration of underlying tissue
Desmoplastic type
Proliferation appears plastered on peritoneal surface Nests of cells, glands and or papillae proliferate in a prominent (>50%) background of dense fibroblastic or granulation tissue with well defined margins
Epithelial type
Fills submesothelial spaces Exophytic proliferations with hierarchical branching papillae Composed predominantly of epithelial cells No stromal reaction Frequent psammoma bodies
Invasive implants (Sampling of underlying tissues is crucial for assessment of invasion)
Haphazardly distributed glands invading normal tissues such as omentum Loose or dense fibrous reaction without significant inflammation Generally dominant epithelial proliferation Nuclear features resembling a low grade serous adenocarcinoma Irregular borders Aneuploidy

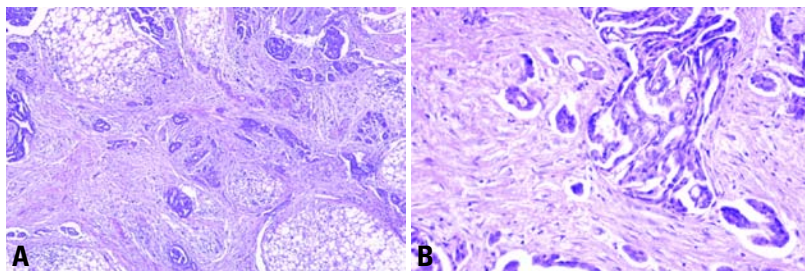


Fig. 2.10 Invasive peritoneal implant of the omentum. **A** Adipose tissue is invaded by haphazardly distributed glands and small cell clusters accompanied by a dense fibrous stromal reaction. **B** Haphazardly distributed glands and small cell clusters exhibit marked nuclear atypia and are accompanied by a dense fibrous stromal reaction.

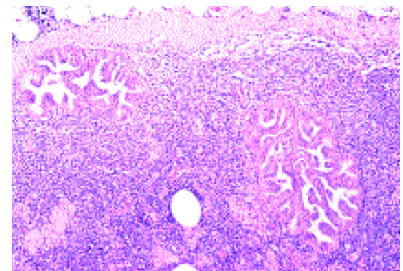


Fig. 2.11 Serous borderline tumour. A lymph node contains epithelial inclusions of serous borderline tumour showing the typical papillary growth pattern.

10 year survival rates, the invasive form is associated with a poor prognosis, i.e. more than 50% have recurrences, and the 10 year survival rate is only about 35%. Therefore, the morphology of the peritoneal implants is the main prognostic factor for patients with stage II-III SBT. When underlying tissue is absent in a biopsy specimen, the lesion is classified as non-invasive on the assumption that it has been stripped away with ease [2605]. It is important to note that implants are heterogeneous, and various types may coexist in different areas; therefore, sampling of as many implants as feasible is recommended. The omentum is the most likely site for invasive implants. Therefore, surgeons must take a sufficient amount of omental tissue to enable the pathologist to distinguish non-invasive from invasive implants. In turn, the pathologist must assess multiple samples of macroscopically "normal" appearing omentum to ascertain adequate sampling.

Invasive implants should be distinguished from benign epithelial inclusions and foci of endosalpingiosis. The latter are uncommon, occurring between a fifth and a tenth as often as implants [207]. Benign epithelial inclusions are characterized by small, generally round glands lined by a single layer of flat to low columnar cells without atypia or mitotic activity, often associated with a fibrous stroma. Small rounded glands also characterize endosalpingiosis, but the latter may be papillary and the lining cells show the typical appearance of tubal epithelium (ciliated, secretory and intercalated cells).

Lymph node involvement

Pelvic and para-aortic lymph nodes are involved by SBT in about 20% of cases;

this finding appears to be without clinical significance. These lesions may be true metastases in peripheral sinuses, mesothelial cells in sinuses misinterpreted as tumour cells or independent primary SBTs arising in müllerian inclusion glands that are present in 25-30% of pelvic and para-aortic lymph nodes.

Somatic genetics

The pattern of genetic alterations described in SBTs (for review see [1159]) differs from that of invasive carcinomas, e.g. *TP53* mutations are most often absent in typical [838,1408] and micropapillary SBTs [1408], but are present in up to 88% of cases of invasive serous carcinoma. Loss of heterozygosity on the long arm of the inactivated X chromosome [464] is characteristic for SBT and rare in carcinomas (for review see [838]). Chromosomal imbalances have been identified in 3 of 9 SBTs, 4 of 10 micropapillary SBTs and 9 of 11 serous carcinomas by comparative genomic hybridization; some changes in micropapillary SBT are shared with SBT and others with serous carcinomas only suggesting a relationship among them [2771]. The genetic profile indicates that SBTs are a separate category with little capacity to transform into a malignant phenotype. The situation concerning micropapillary SBTs has to be clarified.

Prognosis and predictive factors

Clinical criteria

Stage 1 SBTs do not progress and have an indolent clinical course with a 5-year survival rate of up to 99% [1542] and a 10-year survival which is not much worse. In stage III SBTs, i.e. distributed throughout the abdominal cavity with peritoneal implants (for details see below), the 5-year survival rate ranges between

55-75%, and the probability of a 10-year survival is not significantly worse.

Histopathological criteria

Compared to typical SBTs, it has been suggested that micropapillary SBTs have a higher frequency of bilaterality (59-71% vs. 25-30%) [754,2727], an increased risk of recurrence among higher stage lesions [2727], more frequent ovarian surface involvement (50-65% vs. 36%) and probably a higher frequency of advanced stage at presentation (48-66% vs. 32-35%) at least among referral cases [376,754]. Several reports based on large series of cases, however, have demonstrated no difference in survival among patients with typical SBT and those with a micropapillary pattern among specific stages [658,754,1000,1412,2285,2727], indicating a need for further investigation of the significance of the micropapillary pattern. In addition to its indolent course, micropapillary SBT differs from conventional serous carcinoma by its lack of responsiveness to platinum-based chemotherapy [210].

Cytophotometric predictive factors

The most reliable approach is the application of DNA-cytophotometry (preferably the static variant) according to the guidelines of the 1997 ESACP consensus report [1011,1141]. About 95% of SBTs display a diploid DNA-histogram with only a few cells in the 4c region indicating their low proliferative activity and only minor genetic alterations associated with an excellent clinical outcome [1380]. On the other hand, aneuploid SBTs characterized by a stemline deviation have a high recurrence rate, and the patients die frequently of their disease. For peritoneal implants DNA-cytophotometry is also of prognostic importance because aneuploid implants were found

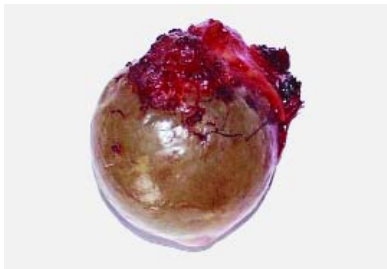


Fig. 2.12 Serosal surface papilloma. A portion of the external surface of the ovary is covered by papillary excrescences.

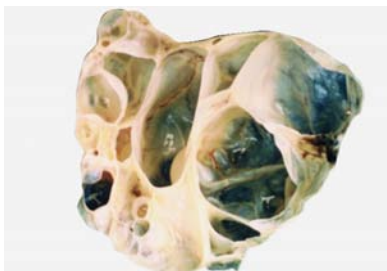


Fig. 2.13 Serosal cystadenoma. Sectioned surface shows a multiloculated cystic tumour with smooth cyst walls.

to be associated with a poor prognosis [652,2145]. Although rare, transformation of a SBT into a bona fide frankly invasive carcinoma may occur.

Benign serous tumours

Definition

Benign tumours composed of epithelium resembling that of the fallopian tube or in some cases the surface epithelium of the ovary.

Epidemiology

Benign serous tumours of the ovary account for approximately 16% of all ovarian epithelial neoplasms. The majority of benign serous tumours arise in adults in the fourth to sixth decades, although they may occur in patients younger than twenty or older than eighty years.

Localization

Benign serous tumours arise preferentially in the cortex of the ovary or on its surface (8%). They are usually bilateral, especially in older women. Often the tumours are metachronous with intervals that range from three to fourteen years.

Similar tumours in extraovarian sites occasionally accompany benign serous tumours.

Clinical features

Signs and symptoms

The most common symptoms are pain, vaginal bleeding and abdominal enlargement, but usually the tumour is asymptomatic and discovered incidentally during ultrasound investigation of another gynaecological disorder.

Macroscopy

Benign serous tumours are usually 1-10 cm in diameter but occasionally reach up to 30 cm or more. They are typically unilocular or multilocular cystic lesions, the external surface is smooth, and the inner surface may contain small papillary projections. The cyst contents are watery and very rarely opaque or bloody. Adenofibromas are solid and have a spongy sectioned surface with minute, colourless fluid-containing cysts. Cystadenofibromas contain both solid areas and cysts. Surface papillomas appear as warty excrescences of different sizes on the surface of the ovary.

Histopathology

Benign serous tumours typically are lined by an epithelium similar to that of the fallopian tube with ciliated and less frequently nonciliated secretory cells. Of special diagnostic interest are the cysts with flattened lining, some of which may represent benign serous neoplasms with a desquamated lining. The only effective method to establish their nature is the application of scanning electron microscopy, which easily detects the ciliated cells, allowing a definitive diagnosis to be made.

Histogenesis

Benign serous tumours result from the proliferation of the surface epithelium of the ovary, [272,1403,2605] producing surface papillary excrescences or invaginating into the cortex of the ovary, forming so called inclusion cysts. Some morphological data support the possibility that a number of benign serous tumours arise from remnants in the hilar region of the ovary, possibly from rete cysts [726,1403,1823].

Prognosis and predictive factors

Serosal cystadenomas are benign.

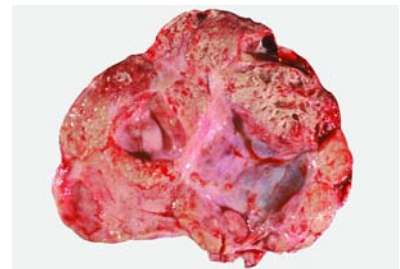


Fig. 2.14 Mucinous adenocarcinoma. The sectioned surface shows a multiloculated cystic tumour with more solid areas containing small cysts.

Mucinous tumours

Definition

Ovarian tumours some or all of whose epithelial cells contain intracytoplasmic mucin. They may resemble those of the endocervix, gastric pylorus or intestine. In some tumours only scattered goblet cells are present in an epithelium that is otherwise non-mucinous.

ICD-O codes

Mucinous adenocarcinoma	8480/3
Mucinous	
cystadenocarcinofibroma	9015/3
Mucinous borderline tumour	8472/1
Mucinous cystadenoma	8470/0
Mucinous adenofibroma	9015/0

Mucinous adenocarcinoma and related tumours

Definition

A malignant epithelial tumour of the ovary that in its better differentiated areas resembles intestinal or endocervical epithelium. Ovarian mucinous adenocarcinomas differ from borderline tumours by having evidence of ovarian stromal invasion.

Macroscopy

Mucinous carcinomas are usually large, unilateral, smooth surfaced, multilocular or unilocular cystic masses containing watery or viscous mucoid material. They are bilateral in approximately 5% of cases. Haemorrhagic, necrotic, solid or papillary areas are relatively frequent, and some tumours may be predominantly solid [1613,2605]. Because areas of malignancy may be limited, generous sampling of all mucinous cystic tumours to include up to one histological section per 1-2 cm of tumour diameter with sam-

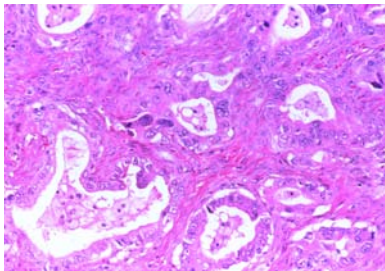


Fig. 2.15 Mucinous carcinoma with infiltrative invasive pattern. Irregular glands lined by cells with malignant features infiltrate the stroma.

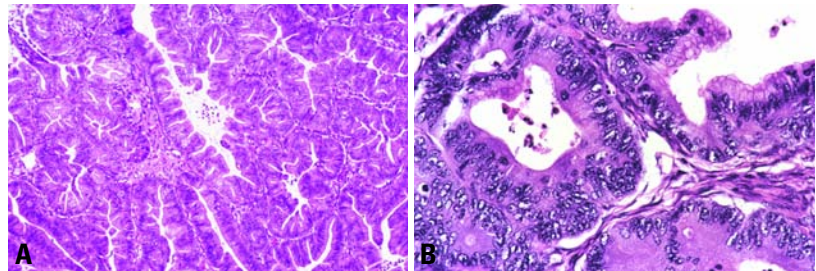


Fig. 2.16 Mucinous adenocarcinoma with expansile invasive pattern. **A** Note the complex glandular proliferation. **B** The glands are lined by cells that have highly atypical nuclei and some intracytoplasmic mucin.

pling of all macroscopically suspicious areas has been recommended.

Histopathology

In the absence of obvious infiltration of the stroma, invasion is assumed if there are complex papillary areas or back-to-back glands lined by malignant-appearing cells with little or no discernible intervening stroma. To qualify as frankly invasive, such areas should be at least 10 mm² and at least 3 mm in each of 2 linear dimensions [1613]. Alternatively, invasion may be in the form of infiltrative glands, tubules, cords or cell nests. The stroma may resemble ovarian stroma or be desmoplastic. In most cases there are also areas that are benign or borderline in appearance [1147,1150,1228,2047,2401]. Rarely, mucinous tumours contain areas of mucinous adenofibroma with malignant epithelial cells and foci of stromal invasion.

Differential diagnosis

The most important differential diagnosis of mucinous ovarian carcinoma is with metastatic mucinous carcinoma that may present clinically as a primary ovarian tumour. Most of these originate in the large intestine, appendix, pancreas, biliary tract, stomach or cervix [237,639,1587,1703,2377,2406,3200,3221]. Since this problem has been emphasized relatively recently, it is likely that early reports of the histological appearance and behaviour of ovarian mucinous carcinomas have been contaminated by metastatic carcinomas masquerading as primary ovarian neoplasms (see Table 2.03). Common features that favour a primary mucinous carcinoma are an expansile pattern of invasion and a complex papillary pattern [1614]. Common features favouring a metastatic mucinous carcinoma are bilaterality, a multinodular

growth pattern microscopically, histological surface involvement by epithelial cells (surface implants) and vascular space invasion [1614].

Somatic genetics

Tumour heterogeneity is common and probably is a reflection of the progression from benign to malignant neoplasia that occurs in the development of mucinous carcinomas. Recent studies strongly suggest that in the sequence of malignant transformation from benign and borderline mucinous tumours to infiltrative carcinoma intraepithelial (non-invasive) carcinomas and carcinomas with purely expansile (not obvious) invasion represent transitional stages of mucinous carcinogenesis [1613]. This hypothesis is also supported by recent molecular studies of genetic alterations in mucinous tumours [591,964,1755,1891]. An increasing frequency of codon 12/13 *KRAS* mutations in benign, borderline and carcinomatous mucinous ovarian tumours has been reported supporting the viewpoint that *KRAS* mutational activation is an early event in mucinous ovarian tumorigenesis. Mucinous borderline tumours have a higher frequency of *KRAS* mutations than that of mucinous cystadenomas but a lower rate than that of mucinous carcinomas [591,1755,1891]. Using microdissection, the same *KRAS* mutation has been detected in separate areas exhibiting different histological grades within the same neoplasm [591].

Prognosis and predictive factors

Clinical criteria

Stage I mucinous carcinomas have an excellent prognosis. However, the prognosis in cases with extraovarian spread is very poor [1076,1228,1458,1613,2377,2401,3069].

Histopathological criteria

With the exception of one recent series [3769], grading of mucinous carcinomas has not been shown to be predictive of behaviour or response to therapy independent of the surgical stage [1076,1228,1458,1613,2377,3069]. Infiltrative stromal invasion proved to be biologically more aggressive than expansile invasion. If individual invasive foci are all less than 10 mm², they have been termed "microinvasive," and cases with this finding have had a favourable outcome [1453,1613,1987,2047,2401,2713].

Mucinous borderline tumour, intestinal type

Definition

Ovarian tumours of low malignant potential exhibiting an epithelial proliferation of mucinous type cells greater than that seen in their benign counterparts but without evidence of stromal invasion. The epithelial component resembles intestinal epithelium, almost always contains goblet cells, usually contains neuroendocrine cells and rarely contains Paneth cells.

Synonyms

Mucinous tumour of low malignant potential, intestinal type; mucinous tumour of borderline malignancy, intestinal type.

Epidemiology

These account for 85-90% of mucinous borderline tumours.

Macroscopy

Mucinous borderline tumours of intestinal type are bilateral in approximately 5% of cases and usually are large, multilocular or unilocular cystic masses containing watery or viscous mucoid material.

Table 2.03
Primary vs. metastatic mucinous ovarian carcinomas.

Features favouring primary carcinoma
Unilaterality Large size, smooth surface Expansile pattern of growth
Features favouring metastatic carcinoma
Bilaterality Known primary mucinous carcinoma at another site Macroscopically friable and necrotic Variable or nodular pattern of growth Ovarian surface involvement Ovarian vascular invasion Cytokeratin 7-negative
Non-contributory
Benign or borderline-appearing areas Infiltrative pattern of growth Luminal necrotic debris Tumour grade

Velvety excrescences may line the cysts. Haemorrhagic, necrotic, solid or papillary areas are occasionally present [1613,2605].

Histopathology

Areas resembling mucinous cystadenoma are common. In the borderline areas the cells lining the cysts are stratified (usually to no more than 3 layers) and may form filiform intracystic papillae with at least minimal stromal support. Nuclei are slightly larger with more mitotic figures than in cystadenomas. Goblet cells and sometimes Paneth cells are present. The overall appearance resembles a hyperplastic or adenomatous colonic polyp [322,653,1076,1147,1150,1613,2377,2491,2605,2713]. Some or most of the epithelial cells lining the cysts of intestinal type borderline tumours may appear

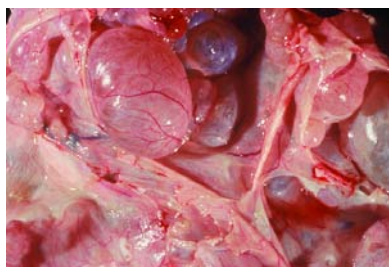


Fig. 2.17 Mucinous borderline tumour, intestinal type. The sectioned surface shows a multiloculated tumour with large cysts.

cytologically malignant and may be stratified to four or more layers in a solid, papillary or cribriform pattern. Whether tumours with such foci should be classified as non-invasive carcinomas or as borderline tumours has been a subject of controversy for many years. To provide for uniformity in reporting, it has been recommended that they be classified as borderline with intraepithelial carcinoma [2605].

Prognosis and predictive factors

When the tumour is confined to the ovaries at initial staging, the prognosis is excellent with only rarely reported recurrences [1150]. It is likely that most tumours diagnosed as intestinal-type mucinous borderline tumour that are associated with pseudomyxoma peritonei are actually metastatic from a similar-appearing tumour in the appendix (see section on pseudomyxoma peritonei). In the remaining cases with advanced disease, the metastases are usually in the form of invasive pelvic or abdominal implants rather than pseudomyxoma peritonei. In these cases the prognosis is similar to that of ovarian mucinous carcinomas with metastases, and it is likely that areas of invasion within the ovarian tumour were not sampled [1076,1147,1150,1613,2401]. Table 2.04 summarizes the differences in appearance and outcome among neoplasms having the appearance of mucinous borderline tumours.

Mucinous borderline tumour, endocervical-like

Definition

Ovarian tumours of low malignant potential exhibiting an epithelial proliferation of mucinous type cells greater than seen in their benign counterparts but without destructive stromal invasion. The mucinous epithelial cells resemble endocervical epithelium.

Synonyms

Mucinous tumour of low malignant potential, endocervical-like; mucinous tumour of borderline malignancy, endocervical-like; müllerian mucinous borderline tumour.

Epidemiology

These tumours make up 10-15% of mucinous borderline tumours [1613,2497,2713].

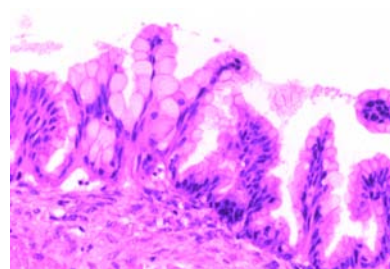


Fig. 2.18 Mucinous borderline tumour, intestinal type. Goblet cells and nuclear stratification are evident.

Macroscopy

Mucinous endocervical-like borderline tumours usually are multilocular or unilocular cystic masses containing watery or viscous mucoid material. Haemorrhagic, necrotic, solid or papillary areas may be present [1613,2605]. They are smaller than the intestinal type and have fewer cysts. They are bilateral in approximately 40% of cases and sometimes arise within an endometriotic cyst [2497].

Tumour spread and staging

Endocervical-like borderline tumours may be associated with abdominal or pelvic implants, some of which may appear invasive [2497,2713].

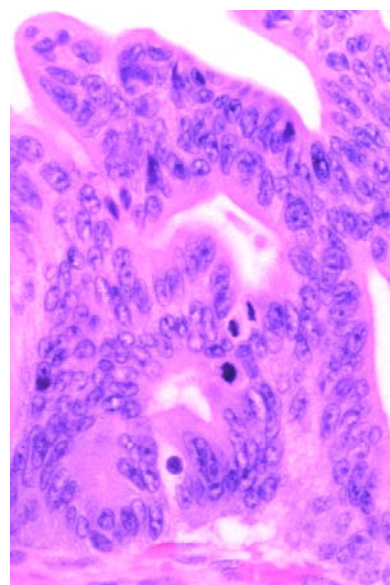


Fig. 2.19 Mucinous borderline tumour, intestinal type, with intraepithelial carcinoma. Malignant mucinous epithelium with a cribriform pattern and mitotic figures lines a cyst.

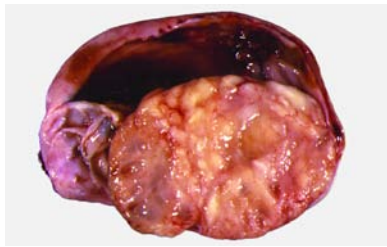

Fig. 2.20 Mucinous endocervical-like borderline tumour. The sectioned surface shows a solid and cystic mucin-containing tumour arising in an endometriotic cyst.

Histopathology

They differ from intestinal-type borderline tumours in that the intracystic growth is composed of broad bulbous papillae similar to those of serous borderline tumours. The epithelial cells lining the papillae are columnar mucinous cells and rounded cells with eosinophilic cytoplasm; the latter are often markedly stratified with detached cell clusters. The nuclei are only slightly atypical. Characteristically, there are many acute inflammatory cells within the papillae or free-floating in extracellular spaces.

Precursor lesions

Endocervical-like borderline tumours likely arise from endometriosis [2497]. At least in some cases the peritoneal implants may arise from independent foci of endometriosis with in situ transformation.

Prognosis and predictive features

Endocervical-like borderline tumours may be associated with abdominal or pelvic implants, some of which may appear invasive, but the clinical behaviour has been indolent in the relatively few cases that have been reported [2497,2713]. However, more cases in this category need to be studied.

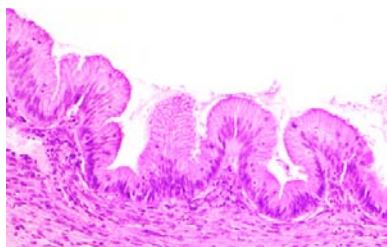


Fig. 2.22 Mucinous cystadenoma. The presence of pseudostratified epithelium with low cellular proliferation in the absence of nuclear atypia does not justify the borderline category.

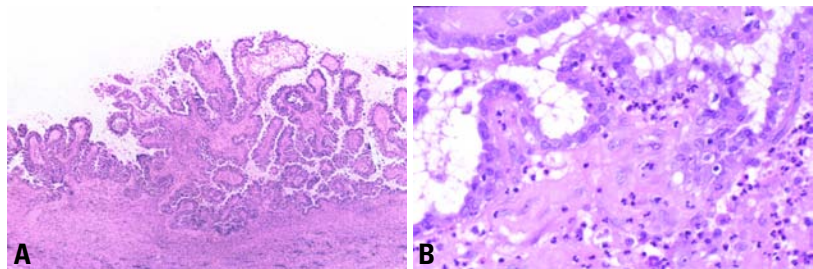


Fig. 2.21 Mucinous endocervical-like borderline tumour. **A** Note the papillae lined by atypical cells with stratification and budding. **B** Some cells contain intracytoplasmic mucin, and the stroma of the papillae is infiltrated by neutrophils.

Benign mucinous tumours

Definition

Benign mucinous tumours composed of epithelium resembling endocervical or gastrointestinal epithelium. The latter almost always contains goblet cells, usually contains neuroendocrine cells and rarely contains Paneth cells.

Macroscopy

Mucinous cystadenomas are usually large, unilateral, multilocular or unilocular cystic masses containing watery or viscous mucoid material. Cystadenofibromas and adenofibromas are partially to almost completely solid with only small cysts [200].

Histopathology

Benign mucinous tumours consist of cystadenomas, cystadenofibromas and adenofibromas. These contain glands and cysts lined by mucinous columnar epithelium [2605]. Cellular stratification is minimal, and nuclei are basally located with only slight, if any, atypia. Cystadenomas may have mucin extravasation with or without a stromal reaction. An ipsilateral dermoid cyst is present in 3–5% of cases. The uncommon mucinous adenofibroma is composed predominantly of fibromatous stroma [200].

Mucinous cystic tumours with mural nodules

Rare mucinous cystic tumours contain one or more solid mural nodules in which the histological features differ markedly from the background of either an intestinal-type borderline tumour or carcinoma [2007,2288,2290,2605]. The nodules are yellow, pink or red with areas of haemorrhage or necrosis and range up to 12 cm

in size. They may be malignant (anaplastic carcinoma, sarcoma or carcinosarcoma) or benign (sarcoma-like). Mucinous cystic tumours containing more than 1 type of mural nodule as well as mixed nodules have been described. Anaplastic carcinomatous nodules usually contain a predominant population of cytokeratin-positive, large, rounded or spindle-shaped cells with abundant eosinophilic cytoplasm and high grade malignant nuclei. The few sarcomas that have been reported have been fibrosarcomas or rhabdomyosarcomas or have not been otherwise classified. Sarcoma-like nodules are sharply circumscribed and without vascular invasion but otherwise may appear alarming, containing pleomorphic cells with bizarre nuclei and many mitotic figures, often accompanied by spindle-shaped cells, epulis-type giant cells, acute and chronic inflammatory cells and foci of haemorrhage and necrosis. The sarcoma-like cells may be weakly or focally cytokeratin-positive, but this finding, in itself, does not indicate a carcinomatous component [2605]. The distinction is important because patients with anaplastic carcinoma in a mural nodule may follow a malignant course [2290], whereas the outcome of

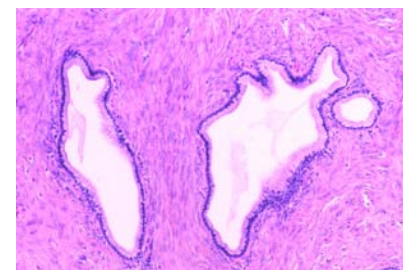


Fig. 2.23 Mucinous adenofibroma. Uniform mucinous glands are associated with a prominent fibrous stroma.

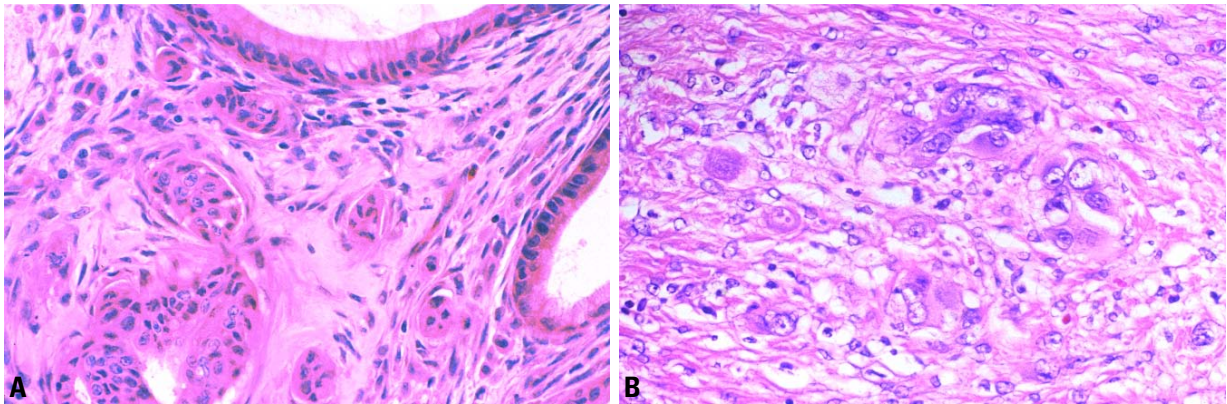


Fig. 2.24 Mucinous borderline tumour (MBT). **A** Note the microinvasive focus in a MBT. **B** Mural nodule from another MBT. The mural nodule is composed of epithelial cells with anaplastic nuclei, abundant cytoplasm and some intracytoplasmic mucin in a fibrous stroma.

those with only sarcoma-like nodules is the same as the corresponding category of mucinous tumour without the nodules {163}. Although the foci of anaplastic carcinoma are found more often in advanced stage tumours, it is now apparent that when they are confined to intact stage IA tumours, they are not necessarily associated with an adverse outcome {2401}.

Mucinous cystic tumours associated with pseudomyxoma peritonei

Since there is strong evidence that ovarian mucinous tumours associated with pseudomyxoma peritonei (PP) are almost all metastatic rather than primary, it is important that such tumours are not diagnosed as stage II or III mucinous borderline tumours or carcinomas without first excluding an appendiceal or other gastrointestinal primary. Present evidence suggests that almost all genuine ovarian mucinous borderline tumours are stage

1. The number of stage 2 and 3 tumours in this category has been greatly exaggerated by including cases in which PP is associated with an undetected primary tumour in the appendix. Also, there is probably an unwarranted apparent increase in the number of high stage ovarian mucinous carcinomas because of undetected primary intestinal mucinous carcinomas associated with the clinical syndrome of PP.

Pseudomyxoma peritonei is a clinical term used to describe the finding of abundant mucoid or gelatinous material in the pelvis and abdominal cavity surrounded by fibrous tissue. The mucus may be acellular or may contain mucinous epithelial cells. Mucinous ascites, the presence of free-floating mucinous fluid, in the peritoneal cavity, almost never leads to pseudomyxoma peritonei. Areas of pseudomyxoma peritonei should be thoroughly sampled and examined histologically. The degree of atypia (benign, borderline or malignant)

of any epithelial cells that are present should be reported, as well as whether the mucin dissects into tissues with a fibrous response or is merely on the surface. Pseudomyxoma peritonei with epithelial cells that are benign or borderline-appearing has been termed "disseminated peritoneal adenomucinosis" by some authors {2409}, and patients with this finding have had a benign or protracted clinical course. In cases where the epithelial cells of the pseudomyxoma peritonei appear malignant, termed "peritoneal mucinous carcinomatosis" {2409}, the source has usually been the appendix or colon, and the clinical course has usually been fatal. Pseudomyxoma peritonei may be present in women without a cystic ovarian tumour or in men. In such cases the source is almost always a gastrointestinal mucinous neoplasm, most commonly from the appendix {2409}. In cases where there is an appendiceal tumour and a mucinous cystic ovarian tumour,

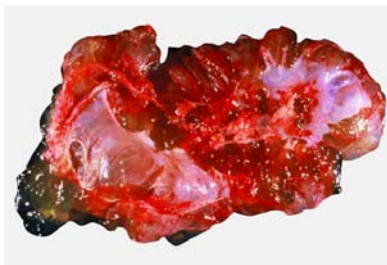

Fig. 2.25 Mucinous cystic tumour associated with pseudomyxoma peritonei. The sectioned surface shows a multiloculated cystic tumour associated with areas of haemorrhage.

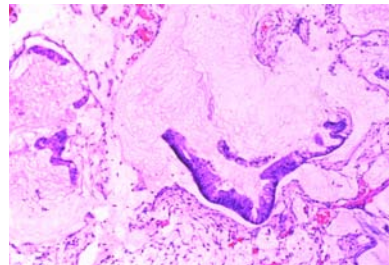


Fig. 2.26 Pseudomyxoma peritonei involving the omentum. Strips of low grade neoplastic mucinous epithelium are associated with abundant extracellular mucin.

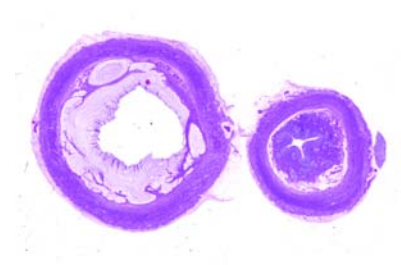


Fig. 2.27 Mucinous appendiceal tumour associated with pseudomyxoma peritonei. Note on the left, the dilatation of the wall and distention of the mucosa by mucin-producing tumour cells.

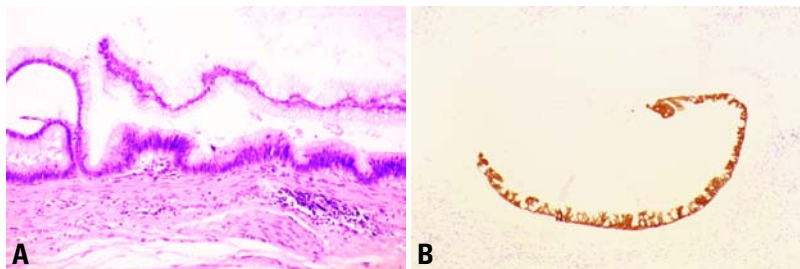


Fig. 2.28 Mucinous cystic tumour of the appendix associated with synchronous mucinous ovarian tumours. **A** The appendiceal lesion shows pseudostratified mucinous epithelium (colonic type) with mild nuclear atypia. **B** The mucinous epithelium of the ovarian lesion shows strong immunoreactivity for cytokeratin 20 and was negative for cytokeratin 7, strongly supporting the appendiceal origin of the tumour.

the origin of the pseudomyxoma peritonei has been disputed. A majority of investigators believe that the ovarian tumour(s) are secondary in almost all such cases [2294,2407,3199]. However, a synchronous origin in both organs has also been proposed [2623]. Clonality studies have demonstrated identical *KRAS* mutations or the lack of them in both the appendiceal and the simultaneous ovarian tumours [590, 2830]. LOH analysis has shown similar findings in three cases and divergent findings in three; this latter observation appears to indicate that some simultaneous tumours are independent primaries

[590], though genetic progression of the metastatic tumours could also account for the disparity of these results. The ovarian tumours are usually classified as either mucinous cystadenomas or intestinal-type borderline tumours. The epithelial cells within them are often found floating in mucin that dissects into the ovarian stroma (pseudomyxoma ovarii). They are well differentiated and often have a tall columnar appearance with abundant mucinous cytoplasm that is positive for cytokeratin 7 in approximately one-half of the cases [1075, 2408]. The latter finding differs from that of primary ovarian mucinous cystadenoma

or intestinal-type borderline tumours most of which are cytokeratin 7-positive. The appendiceal tumour may be quite small relative to the ovarian tumour(s) and may not be appreciated macroscopically. Thus, removal and thorough histological examination of the appendix is indicated in cases of pseudomyxoma peritonei with a mucinous cystic ovarian tumour. In cases where an appendiceal mucinous neoplasm is found, it should be considered as the primary site and the ovaries as secondary. If the appendix has not been examined histologically and the ovarian tumours are bilateral, or unilateral in the absence of an ipsilateral dermoid cyst, the appendix should also be considered primary. If an appendiceal mucinous neoplasm is not found after thorough histological examination, if the appendix had been removed previously in the absence of pseudomyxoma peritonei or if the ovarian tumour is accompanied by a dermoid cyst in the absence of either a macroscopic or histological appendiceal lesion, the ovarian tumour may be considered to be the source of the pseudomyxoma peritonei [1613]. In equivocal cases cytokeratin 7 negativity in the ovarian tumour strongly suggests that it is metastatic.

Table 2.04

Behaviour of problematic mucinous ovarian neoplasms with invasive implants or pseudomyxoma peritonei.

Tumour type	Macroscopy	Histopathology	Appearance of extraovarian disease	Usual behaviour in cases with extraovarian disease
Intestinal type MBT	Large, smooth surfaced multilocular cyst, bilateral in 5%	Cysts are lined with slightly stratified intestinal type cells with mild nuclear atypia and no detached cell clusters Usually CK7 positive	Invasive peritoneal implants without PP This is a rare finding	Prognosis is poor. Cases with invasive implants are likely due to unsampled invasive areas in the ovarian tumour.
Intestinal type MBT with intraepithelial carcinoma	Same	Same, with foci of malignant-appearing nuclei and often highly stratified, solid or cribriform areas	Invasive peritoneal implants without PP	Same as above
Endocervical-like MBT	Smaller with fewer cysts and may be associated with endometriosis, bilateral in 40%	Cysts composed of complex, bulbous papillae with highly stratified, benign-appearing mucinous and eosinophilic cells, detached cell clusters and numerous neutrophils	Invasive or noninvasive peritoneal implants	Benign
Mucinous ovarian tumours associated with PP	Bilateral in a high percentage of cases	Usually resembles intestinal type of MBT often with pseudomyxoma ovarii	PP Often primary appendiceal tumour	Variable, depending on the degree of atypia of the tumour cells in PP
PP = Pseudomyxoma peritonei; MBT = mucinous borderline tumour				

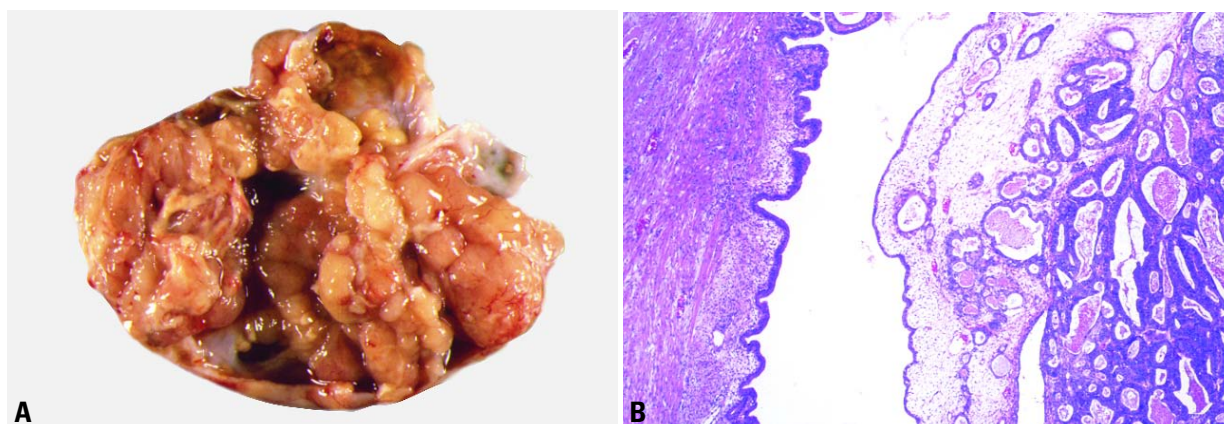


Fig. 2.29 Ovarian endometrioid adenocarcinoma arising from an endometriotic cyst. **A** This solid and cystic tumour forms polypoid structures. The patient had a synchronous endometrioid adenocarcinoma of the uterine corpus. **B** Well differentiated endometrioid adenocarcinoma is seen to the right and an endometriotic cyst on the left.

Endometrioid tumours

Definition

Tumours of the ovary, benign, low malignant potential or malignant, that closely resemble the various types of endometrioid tumours (epithelial and/or stromal) of the uterine corpus. Although an origin from endometriosis can be demonstrated in some cases, it is not required for the diagnosis.

ICD-O codes

Endometrioid adenocarcinoma, not otherwise specified	8380/3
Variant with squamous differentiation	8570/3
Ciliated variant	8383/3
Oxyphilic variant	8290/3
Secretory variant	8382/3
Adenocarcinofibroma	8381/3
Malignant müllerian mixed tumour	8950/3
Adenosarcoma	8933/3
Endometrioid stromal sarcoma	8930/3
Endometrioid borderline tumour	8380/1
Cystadenoma	8380/0
Adenofibroma; cystadenofibroma	8381/0

Endometrioid adenocarcinoma

Definition

A malignant epithelial tumour of the ovary that closely resembles the common variant of endometrioid carcinoma of the uterine corpus. Although an origin from endometriosis can be demonstrated in some cases, it is not required for the diagnosis.

Epidemiology

Endometrioid carcinomas account for 10-20% of ovarian carcinomas {1409, 2489} and occur most commonly in women in the fifth and sixth decades of life {2773}.

Aetiology

Up to 42% of the tumours are associated with endometriosis in the same ovary or elsewhere in the pelvis {676,932,1927, 2489,2287a} and 15-20% are associated with endometrial carcinoma {1477,1479, 1683,3239}. These associations suggest that some endometrioid ovarian carcinomas may have the same risk factors for their development as endometrial carcinomas {613}. Patients whose tumours occur in association with endometriosis are 5-10 years younger on average than patients without associated ovarian endometriosis {2600}.

Clinical features

Like most ovarian carcinomas, many endometrioid carcinomas are asymptomatic. Some present as a pelvic mass, with or without pain and may be associated with endocrine symptoms secondary to steroid hormone secretion by the specialized ovarian stroma {1790}. Serum CA125 is elevated in over 80% of the cases {946,1603}.

Macroscopy

The tumours, typically measuring 10-20 cm in diameter, are solid, soft, friable or cystic with a fungating mass protruding into the lumen. They are bilateral in 28% of the cases.

Tumour spread and staging

Stage I carcinomas are bilateral in 17% of the cases {2233}. The stage distribution of endometrioid carcinomas differs from that of serous carcinomas. According to the FIGO annual report, 31% of the tumours are stage I; 20%, stage II; 38%, stage III; and 11%, stage IV {2233}.

Histopathology

Ovarian endometrioid carcinomas closely resemble endometrioid carcinomas of the uterine corpus. The well differentiated form shows round, oval or tubular glands lined by stratified nonmucin-containing epithelium. Cribriform or villoglandular patterns may be present. Squamous differentiation occurs in 30-50% of the cases, often in the form of morules (cytologically benign-appearing squamous cells) {341,2605}. The designation "endometrioid carcinoma with squamous differentiation" (rather than adenoacanthoma and adenosquamous carcinoma) is favoured {2604,2605}. Aggregates of spindle-shaped epithelial cells are an occasional finding in endometrioid carcinoma {2942}. Occasionally, the spindle cell nests undergo a transition to clearly recognizable squamous cells suggesting that the former may represent abortive squamous differentiation {2605}.

Rare examples of mucin-rich, secretory, ciliated cell and oxyphilic types have been described {759,1187,2258}. In the mucin-rich variant glandular lumens and the apex of cells are occupied by mucin {2605}. The secretory type contains vacuolated cells resembling those of an

early secretory endometrium [2605]. The oxyphilic variant has a prominent component of large polygonal tumour cells with abundant eosinophilic cytoplasm and round central nuclei with prominent nucleoli [2258].

Occasional tumours contain solid areas punctuated by tubular or round glands or small rosette-like glands (microglandular pattern) simulating an adult granulosa cell tumour [3206]. In contrast to Call-Exner bodies, however, the microglands contain intraluminal mucin. The nuclei of endometrioid carcinomas are usually round and hyperchromatic, whereas those of granulosa cell tumours are round, oval, or angular, pale and grooved. Rare cases of endometrioid carcinomas of the ovary show focal to extensive areas resembling Sertoli and Sertoli-Leydig cell tumours [2111,2466,3206]. They contain small, well differentiated hollow tubules, solid tubules or, rarely, thin cords resembling sex cords. When the stroma is luteinized, this variant may be mistaken for a Sertoli-Leydig cell tumour, particularly in cases in which the patient is virilized. Nevertheless, typical glands of endometrioid carcinoma and squamous differentiation are each present in 75% of the tumours, facilitating their recognition as an endometrioid carcinoma [3206]. Furthermore, immunostains for alpha-inhibin are positive in Sertoli cells but negative in the cells of endometrioid carcinoma [1789].

Immunoprofile

Endometrioid carcinomas are vimentin, cytokeratin, epithelial membrane antigen, estrogen and progesterone recep-

tor and B72.3 positive but alpha-inhibin negative [1789].

Grading

Grading of endometrioid carcinoma uses the same criteria as endometrial adenocarcinoma [3238] (see chapter 4).

Histogenesis

Most endometrioid carcinomas are thought to arise from surface epithelial inclusions, and up to 42% are accompanied by ipsilateral ovarian or pelvic endometriosis [676,932,1927,2489] that may display the entire spectrum of endometrial hyperplasia (simple, complex, typical and atypical). Atypical ipsilateral endometriosis occurs in up to 23% of endometrioid carcinomas [932] and may have a role in the evolution of some endometrioid carcinomas [2618].

Somatic genetics

Somatic mutations of beta-catenin (*CTNNB1*) and *PTEN* are the most common genetic abnormalities identified in sporadic endometrioid carcinomas. The incidence of *CTNNB1* mutations ranges from 38-50% [1909,2153]. Mutations have been described in exon 3 (codons 32, 33, 37, and 41) and involve the phosphorylation sequence for glycogen synthase kinase 3. These mutations probably render a fraction of cellular beta-catenin insensitive to APC-mediated down-regulation and are responsible for its accumulation in the nuclei of the tumour cells. Beta-catenin is immunohistochemically detectable in carcinoma cells in more than 80% of the cases. Endometrioid carcinomas with beta-

catenin mutations are characteristically early stage tumours associated with a good prognosis [955].

PTEN is mutated in approximately 20% of endometrioid ovarian tumours and in 46% of those with 10q23 loss of heterozygosity (LOH) [2075]. *PTEN* mutations occur between exons 3 to 8. The majority of endometrioid carcinomas with *PTEN* mutations are well differentiated and stage I tumours, suggesting that in this subset of ovarian tumours *PTEN* inactivation is an early event [2075]. The finding of 10q23 LOH and *PTEN* mutations in endometriotic cysts that are adjacent to endometrioid carcinomas with similar genetic alterations provides additional evidence for the precursor role of endometriosis in ovarian carcinogenesis [2543].

Microsatellite instability (MI) also occurs in sporadic endometrioid carcinomas of the ovary although less frequently than in uterine endometrioid carcinomas. The reported frequency of MI in the former tumours ranges from 12.5-19% [1055, 1909]. Like endometrial carcinomas, many ovarian carcinomas with MI follow the same process of MLH1 promoter methylation and frameshift mutations at coding mononucleotide repeat microsatellites [1055].

Simultaneous endometrioid carcinomas of the ovary and endometrium

Endometrioid carcinoma of the ovary is associated in 15-20% of the cases with carcinoma of the endometrium [767,822, 1479,2651,3239]. The very good prognosis in those cases in which the tumour is

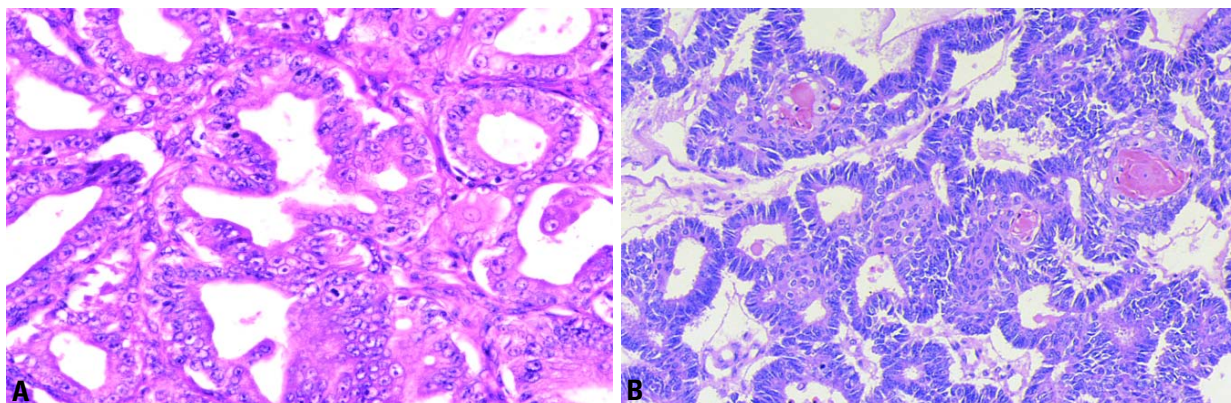


Fig. 2.30 Well differentiated endometrioid adenocarcinoma of the ovary. **A** Confluent growth of glands is evident with replacement of stroma. **B** Note the squamous differentiation in the form of squamous morules and keratin pearls.

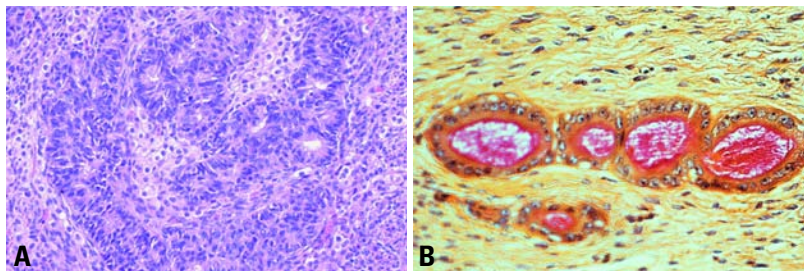


Fig. 2.31 Sertoliform endometroid carcinoma. **A** The tubular glands contain high grade nuclei. The luteinized ovarian stromal cells resemble Leydig cells. **B** Small endometroid glands contain luminal mucin. (Mucicarmine stain).

limited to both organs provides strong evidence that these neoplasms are mostly independent primaries arising as a result of a müllerian field effect [822]. Less frequently, one of the carcinomas represents a metastasis from the other tumour.

The criteria for distinguishing metastatic from independent primary carcinomas rely mainly upon conventional clinico-pathologic findings, namely stage, size, histological type and grade of the tumours, the presence and extent of blood vessel, tubal and myometrial invasion, bilaterality and pattern of ovarian involvement, coexistence with endometrial hyperplasia or ovarian endometriosis and, ultimately, patient follow-up [762, 2286, 2978]. By paying attention to these findings, the precise diagnosis can be established in most cases. Occasionally, however, the differential diagnosis may be difficult or impossible as the tumours may show overlapping features.

In difficult cases comparative analysis of the immunohistochemical and DNA flow cytometric features of the two neoplasms may be of some help [822, 2286]. The presence of identical aneuploid DNA indexes in two separate carcinomas suggests

that one of them is a metastasis from the other [2286]. In contrast, when the two neoplasm have different DNA indexes, the possibility of two independent primaries has to be considered [2286]. The latter results, however, do not completely exclude the metastatic nature of 1 of the tumours, since metastatic tumours or even different parts of the same tumour may occasionally have different DNA indexes reflecting tumour progression [2728].

Molecular pathology techniques can also be helpful [1788]. These include LOH, [783, 923, 1664, 2641], gene mutation [923, 1664, 1909] and clonal X-inactivation analyses [926]. Although LOH pattern concordance in two separate carcinomas is highly suggestive of a common clonal origin (i.e. one tumour is a metastasis from the other), the finding of different LOH patterns does not necessarily indicate that they represent independent tumours. Some studies have shown varying LOH patterns in different areas of the same tumour as a consequence of tumour heterogeneity [287]. Discordant *PTEN* mutations and different microsatellite instability (MI) patterns in the two neoplasms are suggestive of independent primary carcinomas; nevertheless,

metastatic carcinomas may also exhibit gene mutations that differ from those of their corresponding primary tumours as a result of tumour progression [923]. Alternatively, two independent primary carcinomas may present identical gene mutations reflecting induction of the same genetic abnormalities by a common carcinogenic agent acting in two separate sites of a single anatomic region [1786, 1788]. In other words, the genetic profile can be identical in independent tumours and different in metastatic carcinomas [1788]. Therefore, clonality analysis is useful in the distinction of independent primary carcinomas from metastatic carcinomas provided the diagnosis does not rely exclusively on a single molecular result and the molecular data are interpreted in the light of appropriate clinical and pathologic findings [1786, 1788, 2283].

According to FIGO when the site of origin remains in doubt after pathological examination, the primary site of the tumour should be determined by its initial clinical manifestations.

Genetic susceptibility

Most endometrioid carcinomas occur sporadically, but occasional cases develop in families with germline mutations in DNA mismatch repair genes, mainly *MSH2* and *MLH1* (Muir-Torres syndrome) [535]. This syndrome, thought to be a variant of the hereditary nonpolyposis colon cancer syndrome, is characterized by an inherited autosomal dominant susceptibility to develop cutaneous and visceral neoplasms [796].

Prognosis and predictive factors

The 5-year survival rate (FIGO) of patients with stage I carcinoma is 78%; stage II, 63%; stage III, 24%; and stage

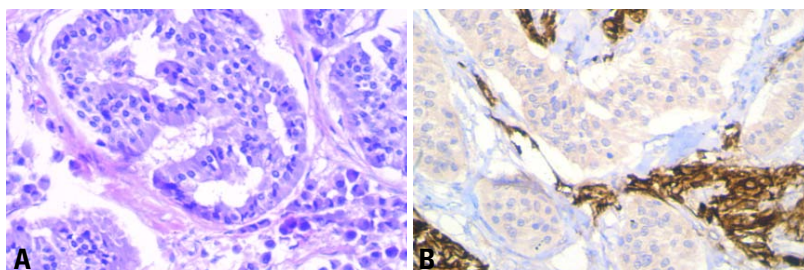


Fig. 2.32 Endometrioid adenocarcinoma resembling a granulosa cell tumour. **A** Note the microglandular pattern. **B** Immunostains for alpha-inhibin are positive in the luteinized stromal cells and negative in the epithelial cells.

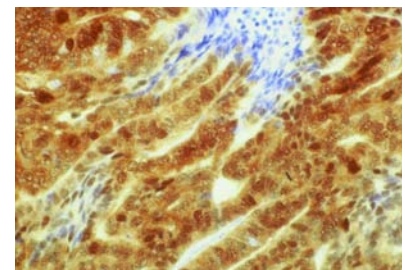


Fig. 2.33 Ovarian endometrioid carcinoma. Immunostain for beta-catenin shows intense and diffuse positivity.

IV, 6% {2233}. Patients with grade 1 and 2 tumours have a higher survival rate than those with grade 3 tumours {1479}. Peritoneal foreign body granulomas to keratin found in cases of endometrioid carcinoma with squamous differentiation do not seem to affect the prognosis adversely in the absence of viable-appearing tumour cells on the basis of a small series of cases {1459}. Endometrioid carcinomas with a mixed clear cell, serous or undifferentiated carcinoma component are reported to have a worse prognosis {2941}.

Malignant müllerian mixed tumour

Definition

A highly aggressive neoplasm containing malignant epithelial and mesenchymal elements.

Synonyms

Carcinosarcoma, malignant mesodermal mixed tumour, metaplastic carcinoma.

Epidemiology

Malignant müllerian mixed tumours (MMMTs) are rare, representing less than 1% of ovarian malignancies. They occur most commonly in postmenopausal women of low parity, the median age being around 60.

Clinical features

The clinical presentation is similar to that of carcinoma of the ovary.

Aetiology

An increased incidence has been reported in women who have had pelvic irradiation {3080}.

Macroscopy

The neoplasms form large (10-20 cm diameter), partly solid and partly cystic, or, less commonly, solid, grey-brown, unilateral or bilateral, bosselated masses with foci of haemorrhage and necrosis {479}. The sectioned surface is fleshy and friable, and cartilage and bone may be apparent. The tumours are bilateral in 90% of cases.

Tumour spread and staging

There is extraovarian spread to the pelvic peritoneum, omentum, pelvic organs and regional lymph nodes in more than 75% of cases at the time of diagnosis.

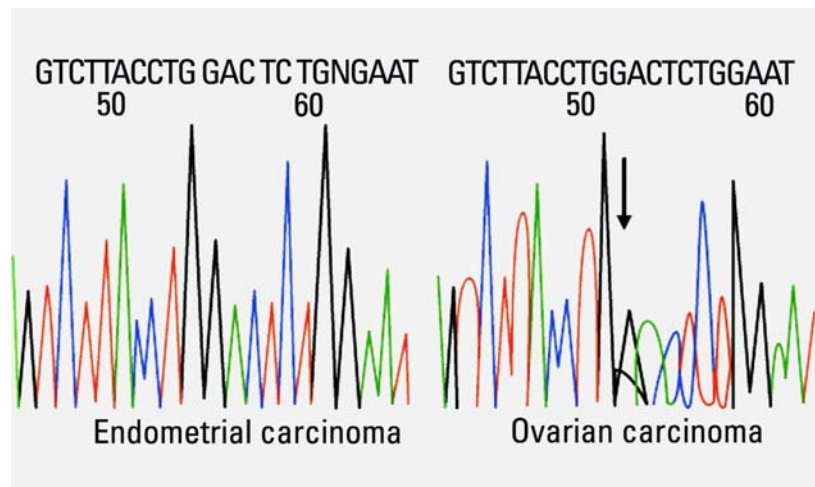


Fig. 2.34 Genetic differences in concurrent endometrial and ovarian adenocarcinoma. DNA sequencing of exon 3 of the beta-catenin (*CTNNB1*) gene showing a GGA to GCA change at codon 32 (Asp>His) in the ovarian endometrioid adenocarcinoma (right, arrow). The mutation was not identified in the uterine endometrioid carcinoma (left).

Histopathology

The histological and immunoprofile are similar to those of its uterine counterpart and those occurring elsewhere in the female genital system (see chapter 4).

Histogenesis

MMMT is believed to develop from the ovarian surface epithelium or from foci of endometriosis and, therefore, may be regarded as a high grade carcinoma with metaplastic sarcomatous elements. The positive tumour response to chemotherapy directed at ovarian carcinoma also supports this viewpoint.

Somatic genetics

There is evidence that MMMTs are monoclonal {26,2748} as the phenotypically different elements share similar allelic losses and retentions {925} and a cell line developed from an MMMT expresses both mesenchymal and epithelial antigens {195}. Furthermore, a heterogeneous pattern of allelic loss at a limited number of chromosomal loci in either the carcinomatous or sarcomatous component of the neoplasm is consistent with either genetic progression or genetic diversion occurring during the clonal evolution of the tumour.

Genetic susceptibility

There is anecdotal evidence of *BRCA2* mutation {2748}.

Prognosis and predictive factors

Improved cytoreductive surgery and platinum based chemotherapy has resulted in a median survival of 19 months {2715} and an overall 5-year survival of 18-27% {120,1182}. The survivors almost invariably have early stage disease at the time of diagnosis, and low stage is a statistically significant indicator of outcome {120,436,1182,2749}. No other histopathological factors are significant indicators of outcome.

Adenosarcoma

Definition

A biphasic tumour characterized by a proliferation of müllerian-type epithelium with a benign or occasionally markedly atypical appearance embedded in or

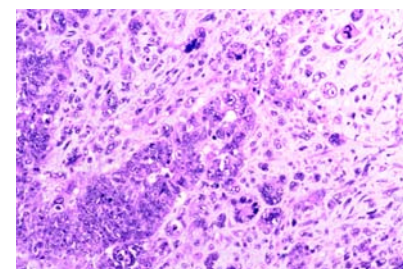


Fig. 2.35 Malignant müllerian mixed tumour. Poorly differentiated glands are surrounded by spindle-shaped, rounded and multinucleated cells.

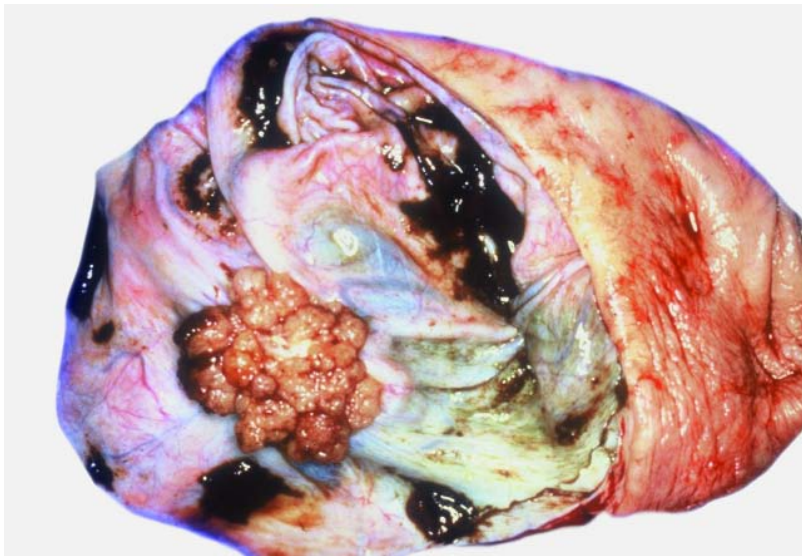


Fig. 2.36 Endometrioid borderline tumour. Whereas most endometrioid borderline tumours have an adenofibromatous appearance, the adenofibromatous lesion is rarely evident within a large cystic mass.

overlying a dominant sarcomatous mesenchyme.

Clinical features

Most of the tumours reported so far have been unilateral, occurring in the 4th and 5th decades. Abdominal discomfort and distension are the usual complaints.

Macroscopy and histopathology

The tumour is frequently adherent to the surrounding tissue [512,604,929]. The macroscopic and histological features are described in detail in the uterine counterpart (see chapter 4).

Prognosis and predictive factors

Occasional reports have linked the spread of adenosarcomas into the abdominal cavity with a poor clinical outcome [510]. The stroma is often predominantly fibrotic, oedematous or hyalized with characteristic foci of perivascular cuffing seen only focally (sometimes, the foci are very small) and still the tumours recur and kill the patient [760]. Unfortunately, there exist no established morphological criteria to predict such biological behaviour. However, if during the course of the disease sarcomatous overgrowth develops, signifying invasive potential, the patient requires careful monitoring. In a series of 40 cases, the 5-year survival was

64%, the 10-year survival 46% and the 15-year survival 30% [760]. Age greater than 53 years, tumour rupture, high grade and the presence of high grade sarcomatous overgrowth appear to be associated with recurrence or extraovarian spread. Ovarian adenosarcoma has a worse prognosis than its uterine counterpart, presumably because of the greater ease of peritoneal spread [760]. Therapeutically, an aggressive surgical approach with wide excision is most often recommended [510]. Chemotherapy and radiation may be applied in individual cases; however, no established protocols exist.

Endometrioid stromal and undifferentiated ovarian sarcoma

Definition

Endometrioid stromal sarcoma (ESS) is a monophasic sarcomatous tumour characterized by a diffuse proliferation of neoplastic cells similar to stromal cells of proliferative endometrium. At its periphery the tumour exhibits a typical infiltrative growth pattern. Those neoplasms that have moderate to marked pleomorphism, significant nuclear anaplasia and more cytoplasm than is found in endometrial stromal cells should be classified as undifferentiated ovarian sarcoma.

Clinical features

More than 70% of the tumours are unilateral. The age range is 11-76 years with the majority of tumours occurring around the 5th and 6th decade. The clinical symptoms do not differ from those recognized for other ovarian tumours.

Macroscopy

Most tumours are solid and firm, but some may show variably sized cysts, sometimes filled with mucoid or haemorrhagic fluid or debris. The sectioned surface appears yellow-white or tan, sometimes interspersed with grey fibrous bundles or septa.

Histopathology

Roughly half of the cases of ESS are associated with either endometriosis or a similar sarcomatous lesion of the endometrial stroma or both [2605]. The dominant cell type of ESS consists of small, round to oval, or occasionally spindle shaped cells with round nuclei and scanty, sometimes barely visible pale cytoplasm. The cells may be arranged haphazardly in a diffuse pattern or may form parallel cell sheets mimicking fibroma. Hypocellular areas with a distinct oedematous appearance can be present. Lipid droplets may be present within tumour cells, which are often associated with foam cells. A hallmark of ESS is the presence of abundant small thick-walled vessels resembling spiral arteries of the late secretory endometrium. The vessels often are surrounded by whorls of neoplastic cells. Reticulin stain discloses delicate fibrils characteristically enveloping individual tumour cells. The cellularity can vary markedly within the same specimen. The tumour can be partly intersected by fibrous bands forming more or less distinct nodules. Sometimes, hyaline plaques are present. Rarely, cord-like or plexiform arrangements of tumour cells similar to the growth patterns seen in ovarian sex cord tumours such as granulosa cell tumours or thecomas are observed. In these areas reticulin fibrils are more or less absent. Rarely, glandular elements are interspersed, but they never represent a dominant feature. At its periphery the tumour exhibits a typical infiltrative growth pattern. In cases where the tumour has spread into extraovarian sites, a tongue-like pattern of invasion

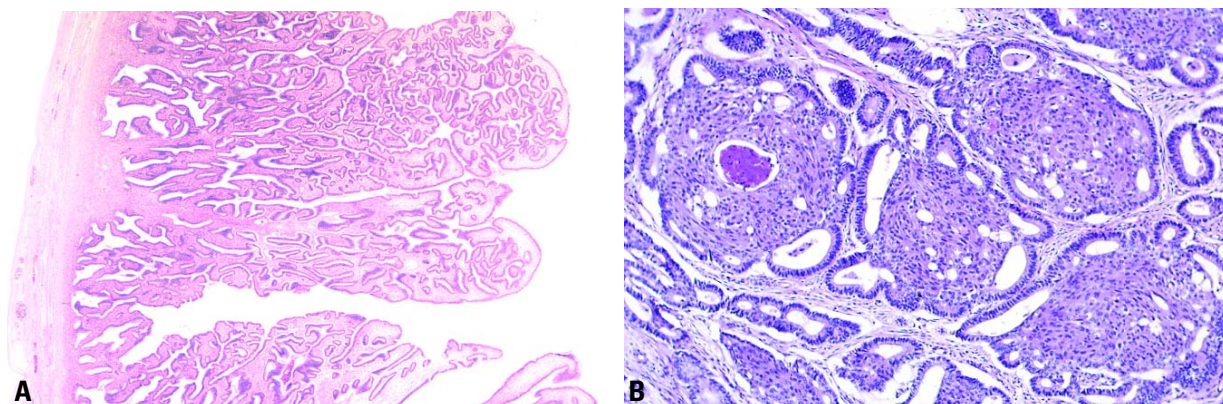


Fig. 2.37 **A** This polypoid intracystic tumour consists of complex villoglandular structures with abundant stroma. Neither confluence of glands nor destructive infiltrative growth is present. **B** Endometrioid borderline tumour of the ovary. Squamous morules appear to form bridges within dilated endometrial glands.

into the adjacent tissue and intravascular growth appears.

Most neoplasms are low grade, whereas approximately 10% of cases are high grade and are classified as undifferentiated ovarian sarcoma. In the past, tumours with less than 10 mitoses per 10 high power fields were classified as low grade ESS, whereas tumours with more than 10 mitoses per 10 high power fields were traditionally designated high grade [3208]. However, there is no evidence that mitotic rate alone alters the outcome, and all tumours with an appearance resembling that of endometrial stroma should be designated endometrioid stromal sarcoma [438], whereas those that lack endometrial stromal differentiation should be diagnosed as undifferentiated ovarian sarcoma. The latter is a high grade neoplasm that is composed of pleomorphic mesenchymal cells with distinct variability in size and shape. The nuclei are highly atypical with prominent nucleoli and occasionally resemble rhabdomyosarcoma or fibrosarcoma.

Immunoprofile

Immunostaining demonstrates the expression of vimentin and CD10 in ESS. Muscle-associated proteins are only focally expressed. Alpha-inhibin was negative in all cases examined [1681].

Differential diagnosis

ESS must be differentiated from other ovarian lesions, including some small cell tumours. The major problem is to distinguish ESS from adult granulosa cell-tumour, foci of stromal hyperplasia, ovarian fibroma or ovarian thecoma.

On morphological grounds alone, it is not always possible to decide whether the ovarian lesion is a primary ESS of the ovary or a metastatic lesion from a uterine ESS. Thus, an ovarian ESS should never be diagnosed unless the uterus is carefully examined to exclude a uterine primary. Should ESS be found in both organs, it is more or less impossible to decide which tumour is the primary and which is metastatic. One criterion that establishes a primary site in the ovary is its continuity with endometriotic foci in the ovary.

Somatic genetics

Mutation of the *TP53* tumour suppressor gene associated with overexpression of TP53 protein has been frequently observed in ovarian sarcomas. These mutations may occur on the basis of an impaired DNA repair system in these tumours [1681].

Prognosis and predictive factors

Since over one-half of the ESSs have already spread to pelvic or upper abdominal sites at the time of diagnosis, the tumour stage remains the major prognostic criterion [438]. Whether the neoplasm is an ESS or undifferentiated ovarian sarcoma also influences the clinical course [3208]. ESS often has a favourable outcome with survival in excess of 5 years even in the context of extraovarian spread. After 10 years, however, the tumour-related mortality increases, particularly if extraovarian manifestations were noted at the time of diagnosis. Tumour relapse represents an ominous prognostic sign. Undifferentiated ovarian sarcomas have a rapid course and a

poor prognosis [3208].

Radical panhysterectomy is the recommended therapy. Successful treatment with progesterone, non-hormonal cytostatic drugs or radiation has been reported occasionally in ESS.

Endometrioid borderline tumour

Definition

An ovarian tumour of low malignant potential composed of atypical or histologically malignant endometrioid type glands or cysts often set in a dense fibrous stroma with an absence of stromal invasion.

Synonyms

Endometrioid tumour of low malignant potential, endometrioid tumour of borderline malignancy.

Epidemiology

Endometrioid tumours with atypical epithelial proliferations and lacking stromal invasion are rare. Their precise prevalence is not known because of variation in diagnostic criteria, but reportedly they account for 3-18% of malignant ovarian neoplasms [137,2490,2528].

Aetiology

These tumours appear to be predominantly derived from the surface epithelium of the ovary or endometriosis.

Clinical features

Patients range in age from 22-77 years [201,2737]. A pelvic mass is palpable in a majority of patients, and others present with uterine bleeding. The tumours are

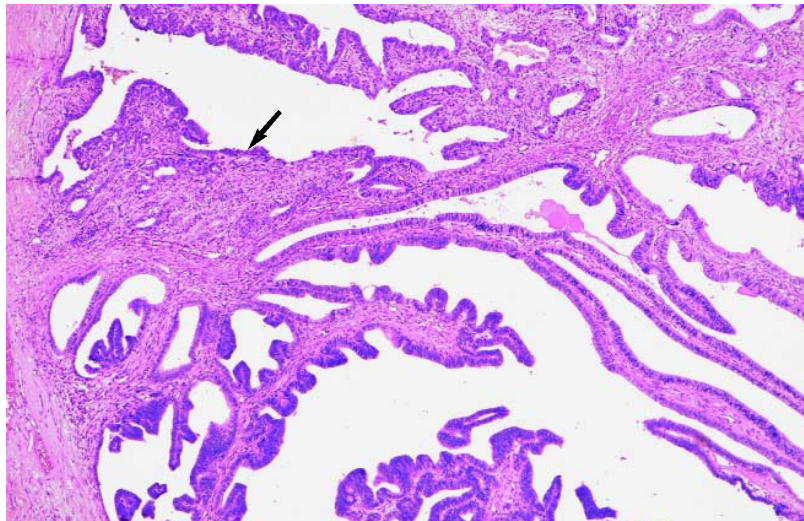


Fig. 2.38 Endometrioid borderline tumour of the ovary with microinvasion. Cystic tumour contains complex papillae. A small area has densely packed glands indicative of microinvasion (arrow) .

predominantly unilateral, but rare bilateral lesions occur.

Macroscopy

Tumours range in size from 2-40 cm, have a tan to grey-white sectioned surface that varies from solid to predominantly solid with cysts ranging from a few mm to 8 cm in diameter [201,2737]. Haemorrhage and necrosis are present mainly in larger tumours.

Histopathology

Three patterns have been described [201,2737]. The most common is adenofibromatous. Islands of crowded endometrioid glands or cysts lined by cells displaying grade 1 to, rarely, grade 3 cytological atypia proliferate in an adenofibromatous stroma. Stromal invasion is absent. Mitotic activity is usually low.

Squamous metaplasia is common, and necrosis may develop in the metaplastic epithelium. The second pattern is villoglandular or papillary with an atypical cell lining similar to atypical hyperplasia of the endometrium again in a fibromatous background. The third form shows a combination of villoglandular and adenofibromatous patterns. Anywhere from 15% to over half of the patients have endometriosis in the same ovary as well as at extraovarian sites [201,2737].

Prognosis and predictive factors

The prognosis is excellent. Recurrences and metastases are rare. Even in the rare case of an extraovarian tumour nodule involving the colonic serosa [2737], no subsequent problems developed 9 years after surgery, radiation and chemotherapy. Since a few patients treated by unilat-

eral salpingo-oophorectomy developed endometrioid carcinoma in the contralateral ovary, and 1 died from it, bilateral salpingo-oophorectomy would be prudent when retention of fertility is no longer an issue. Unilateral salpingo-oophorectomy along with follow-up for early detection of any subsequent ovarian or endometrial adenocarcinoma is acceptable for women of childbearing age.

Benign endometrioid tumours

Definition

Ovarian tumours with histological features of benign glands or cysts lined by well differentiated cells of endometrial type.

Epidemiology

Because of the rarity of these neoplasms no convincing epidemiological data can be quoted. The reported patients are mainly of the reproductive age.

Localization

Benign endometrioid tumours are usually unilateral, though in rare cases involvement of both ovaries is encountered.

Clinical features

Signs and symptoms

There are no specific clinical symptoms of benign endometrioid tumours. Small neoplasms are incidental findings, sometimes in the wall of an ovarian endometriotic cyst. Large tumours are manifested by pain and abdominal swelling.

Imaging

Imaging techniques, including US, CT and MRI, cannot effectively establish the specific nosological character of the process. They can visualize endometriotic foci and thus indirectly indicate the presumptive endometrioid nature of the neoplasm; otherwise the results of imaging technique show the formal characteristics, i.e. cystic or cystic-fibrous architecture of the lesion [234].

Histopathology

The histological diagnosis of endometrioid adenomas and cystadenomas is based on the presence of well differentiated, benign appearing glands or cysts lined by endometrial type cells with or without squamous differentiation. In the adenofibromatous variant fibrous stroma predominates. Though adenofibromas

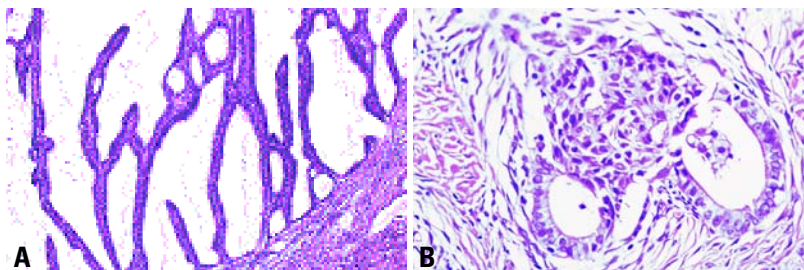


Fig. 2.39 **A** Endometrioid cystadenoma. The cystic neoplasm forms villiform structures lined by well differentiated endometrioid type epithelium. **B** Endometrioid adenofibroma. A squamous morule bridges two endometrioid type glands lined by uniform cells set in a fibrous stroma.

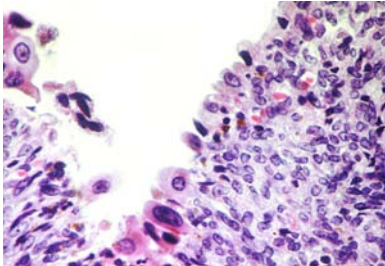


Fig. 2.40 Endometrioid cyst with atypia. The cyst wall is lined by markedly atypical cells surrounded by endometrial stroma.

can have minimal periglandular endometrial stroma, cases in which endometrial stroma is present throughout the lesion are classified as endometriosis. The latter can have all forms of endometrial hyperplasia including those with atypia.

Clear cell tumours

Definition

Ovarian tumours, benign, borderline or malignant, with an epithelial component consisting most commonly of clear and hobnail cells, but often containing other cell types, which rarely predominate.

Histopathology

Clear cell tumours may be predominantly epithelial or may also contain a prominent fibromatous component. The epithelium may consist of one or more cell types. The most common cells are clear cells and hobnail cells. Other cells that

may be present include cuboidal, flat, oxyphilic and rarely, signet-ring cells. Most clear cell tumours are carcinomas, and many have an adenofibromatous background. Benign and borderline clear cell tumours are rare and almost always adenofibromatous.

ICD-O codes

Clear cell adenocarcinoma	8310/3
Clear cell adenocarcinofibroma	8313/3
Clear cell tumour of borderline malignancy	8310/1
Clear cell adenofibroma of borderline malignancy	8313/1
Clear cell cystadenoma	8310/0
Clear cell cystadenofibroma	8313/0

Clear cell adenocarcinoma

Definition

A malignant ovarian tumour composed of glycogen-containing clear cells and hobnail cells and occasionally other cell types.

Epidemiology

The mean age of patients is 57 years.

Aetiology

Tumours may arise directly from the ovarian surface epithelium, from inclusion cysts or from an endometriotic cyst.

Clinical features

Clear cell tumours among all surface epithelial cancers have the highest association of ovarian and pelvic endometriosis

and paraendocrine hypercalcaemia [3204].

Macroscopy

The mean diameter of clear cell adenocarcinomas is 15 cm. The tumours may be solid, but more commonly the sectioned surface reveals a thick-walled unilocular cyst with multiple yellow fleshy nodules protruding into the lumen or multiloculated cysts containing watery or mucinous fluid. Tumours associated with endometriosis typically contain chocolate-brown fluid.

Tumour spread and staging

Patients with clear cell adenocarcinomas present as stage I disease in 33% of cases, as stage II in 19%, as stage III in 29% and as stage IV in 9% [2233].

Histopathology

Clear cell adenocarcinomas display tubulocystic, papillary and solid patterns that may be pure or mixed. The most common patterns are papillary and tubulocystic. Rarely, the tumour has a reticular pattern similar to that of a yolk sac tumour. Sheets of polyhedral cells with abundant clear cytoplasm separated by a delicate fibrovascular or hyalinized stroma are characteristic of the solid pattern. The tubulocystic pattern is characterized by varying-sized tubules and cysts lined by cuboidal to flattened epithelium and occasionally hobnail cells. The papillary pattern is characterized by thick or thin papillae containing

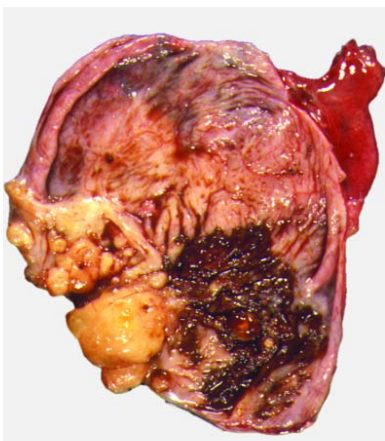


Fig. 2.41 Clear cell adenocarcinoma arising within an endometriotic cyst. The sectioned surface shows a solid tumour within a chocolate cyst.

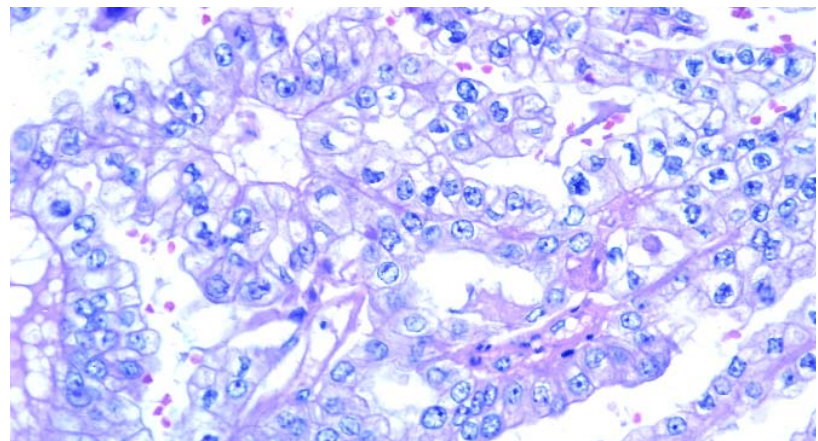


Fig. 2.42 Clear cell adenocarcinoma. The neoplasm has a solid and tubular pattern and is composed of polygonal cells with abundant cytoplasm. Most cells have clear cytoplasm, but some are eosinophilic. Nuclei are round but exhibit irregular nuclear membranes, nucleoli and abnormal chromatin patterns.

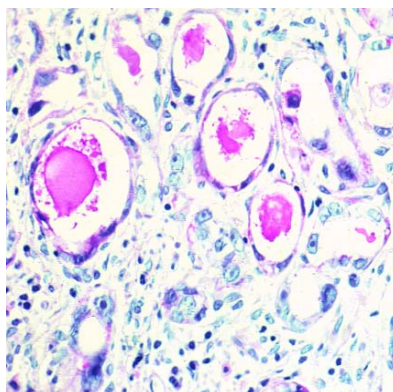


Fig. 2.43 Clear cell adenocarcinoma. Round tubules lined by flattened to highly atypical hobnail cells are present in a fibroedematous stroma (PAS-hematoxylin stain).

fibrous tissue or abundant hyaline material. The most common cell types are the clear and hobnail cells. Clear cells tend to be arranged in solid nests or masses or lining cysts, tubules and papillae, whereas hobnail cells line tubules and cysts and cover papillary structures. The clear cells tend to be rounded or polygonal with eccentric nuclei, often containing prominent nucleoli. The hobnail cells have scant cytoplasm and contain bulbous hyperchromatic nuclei that protrude into the lumens of the tubules. Flattened or cuboidal cells are also encountered. Occasionally, oxyphilic cells with abundant eosinophilic cytoplasm, which in a few instances make up the majority of the neoplasm, are observed. Signet-ring cells often contain inspissated mucinous material in the

centre of a vacuole, creating what has been referred to as a "targetoid" cell. The clear cells contain abundant glycogen and may also contain some lipid. Mucin may be found, typically located in the lumens of tubules and cysts and is abundant within the cytoplasm of the signet-ring cells.

Immunoprofile

Clear cell adenocarcinomas stain strongly and diffusely for keratins, epithelial membrane antigen, Leu M1 and B72.3. Stains for carcinoembryonic antigen are positive in 38% of cases and for CA125 (OC-125) in 50%. There have been a few reports of clear cell adenocarcinomas containing AFP. In a patient with clear cell adenocarcinoma who developed hypercalcaemia when the tumour recurred, immunostains for parathyroid hormone-related protein were strongly positive in the recurrent carcinoma but negative in the primary carcinoma [3209].

Differential diagnosis

The differential diagnosis includes germ cell tumours, particularly yolk sac tumour, dysgerminoma and, rarely, struma ovarii, endometrioid carcinoma with secretory change and steroid cell tumours that contain prominent areas of cells with clear cytoplasm. Metastatic clear cell neoplasms from outside the female genital system are very rare. Clinical information can be particularly helpful in the differential diagnosis as germ cell tumours occur in young women, and elevated serum alpha-feto-

protein (AFP) levels are always found in patients with yolk sac tumours. Histologically, the papillary structures of clear cell carcinoma are more complex than those of yolk sac tumours and contain hyalinized cores. In contrast, yolk sac tumours display a variety of distinctive features including a prominent reticular pattern and Schiller-Duval bodies. Negative immunostains for AFP are useful in excluding yolk sac tumours, although rare examples of AFP-containing clear cell carcinomas have been reported. Positive staining for EMA and diffuse strong positivity for cytokeratins exclude dysgerminoma. Immunostains for thyroglobulin are very useful in ruling out struma ovarii.

Endometrioid carcinomas with secretory change typically are composed of cells that are columnar with subnuclear and supranuclear vacuolization resembling early secretory endometrium. In contrast, the clear cell changes in clear cell carcinoma are more diffuse, the cells are polygonal, and they typically display the other characteristic patterns of clear cell carcinoma. A metaplastic squamous component may be seen in endometrioid carcinoma and is not observed in clear cell carcinoma. In contrast to clear cell carcinomas, steroid cell tumours of the ovary that contain prominent clear cytoplasm are smaller, well circumscribed, have low grade nuclear features and stain strongly for alpha-inhibin.

Grading

Nuclei in clear cell carcinomas range from grade 1 to grade 3, but pure grade

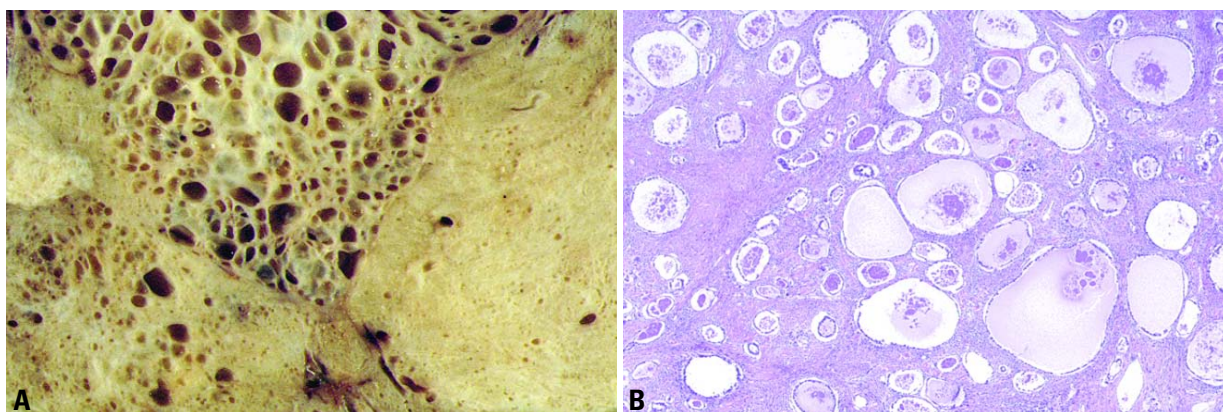


Fig. 2.44 Borderline clear cell adenofibromatous tumour. **A** Though predominantly solid on the right, the tumour is composed of numerous small cysts on the left. **B** Histologically, round glands, many of which are dilated and contain secretions, proliferate in a fibrous stroma.

1 tumours are extremely rare. Almost invariably high grade (grade 3) nuclei are identified. In view of this finding as well as the mixture of different architectural patterns, clear cell adenocarcinoma is not graded.

Prognosis and predictive factors

When controlled for stage, survival of women with clear cell adenocarcinoma may be slightly lower than that of patients with serous carcinoma. The five year survival is 69% for patients with stage I tumours, 55% for stage II, 14% for stage III and 4% for stage IV. There is no consensus in the literature about the value of pattern, cell type, mitotic index or grade as a prognostic indicator [395].

Borderline clear cell adenofibromatous tumour

Definition

An ovarian tumour of low malignant potential composed of atypical or histologically malignant glands or cysts lined by clear or hobnail cells set in a dense fibrous stroma with an absence of stromal invasion.

Synonyms

Clear cell adenofibromatous tumour of low malignant potential, clear cell adenofibromatous tumour of borderline malignancy.

Epidemiology

Of approximately 30 cases of neoplasms classified as borderline clear cell adenofibromatous tumour, the mean age of patients was 65 years.

Macroscopy

Adenofibromas with increasing atypia including intraepithelial carcinoma have a similar appearance to adenofibromas but in addition have areas that are softer and fleshier.

Histopathology

Borderline clear cell adenofibromatous tumours include those in which the epithelium is atypical or carcinomatous without invasion. Adenofibromatous tumours in which the glands are lined by malignant epithelium are best designated as "borderline clear cell adenofibromas with intraepithelial carcinoma". They are similar to borderline adenofibromas; however, nuclear atypia is more

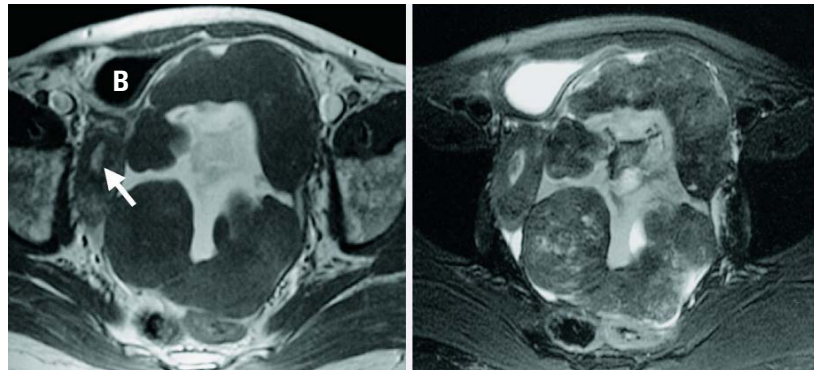


Fig. 2.45 MRI: T1-weighted image (left) and T2-weighted (right) of a borderline clear cell cystadenofibroma of the left ovary. The huge multicystic tumour fills the pelvis almost completely. The uterus with endometrial hyperplasia (arrow) is pushed to the right iliac bone, and the urinary bladder (B) is compressed.

marked with coarse chromatin clumping, prominent nucleoli and increased mitotic activity. Occasionally, minute foci of invasion can be identified, and these tumours are designated "microinvasive". The epithelium often displays stratification and budding, although true papillary structures are uncommon. Small solid masses of clear cells in the stroma raise the question of invasion.

Prognosis and predictive factors

With the exception of one case [202], borderline clear cell adenofibromatous tumours including those with intraepithelial carcinoma and microinvasion have a benign course following removal of the ovary [583,1285,1435,1897,2052].

Clear cell adenofibroma

Definition

An ovarian tumour composed of histologically benign glands or cysts lined by

clear or hobnail cells set in a dense fibrous stroma.

Epidemiology

Among approximately twelve reported cases of benign clear cell adenofibroma, the mean age of patients was 45.

Macroscopy

Adenofibromas have a median diameter of 12 cm and display a smooth lobulated external surface. The sectioned surface has a fine honeycomb appearance with minute cysts embedded in a rubbery stroma.

Histopathology

Clear cell adenofibromas are characterized by tubular glands lined by one or two layers of epithelium that contains polygonal, hobnail or flattened cells. The cytoplasm may be clear, slightly granular or eosinophilic. Nuclear atypia and mitotic activity are minimal. The stroma is densely fibrous.

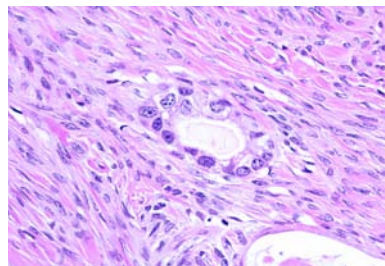


Fig. 2.46 Borderline clear cell adenofibromatous tumour. High power magnification shows simple glands with nuclear enlargement, irregular nuclear membranes and distinct nucleoli.

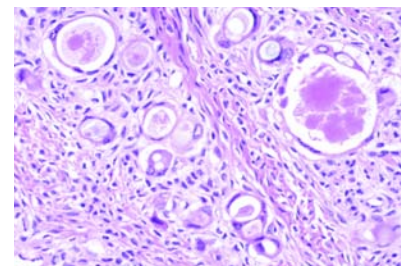


Fig. 2.47 Borderline clear cell tumour with microinvasion. Clear cell adenofibromatous tumour is seen on the right with the area of microinvasion on the left.

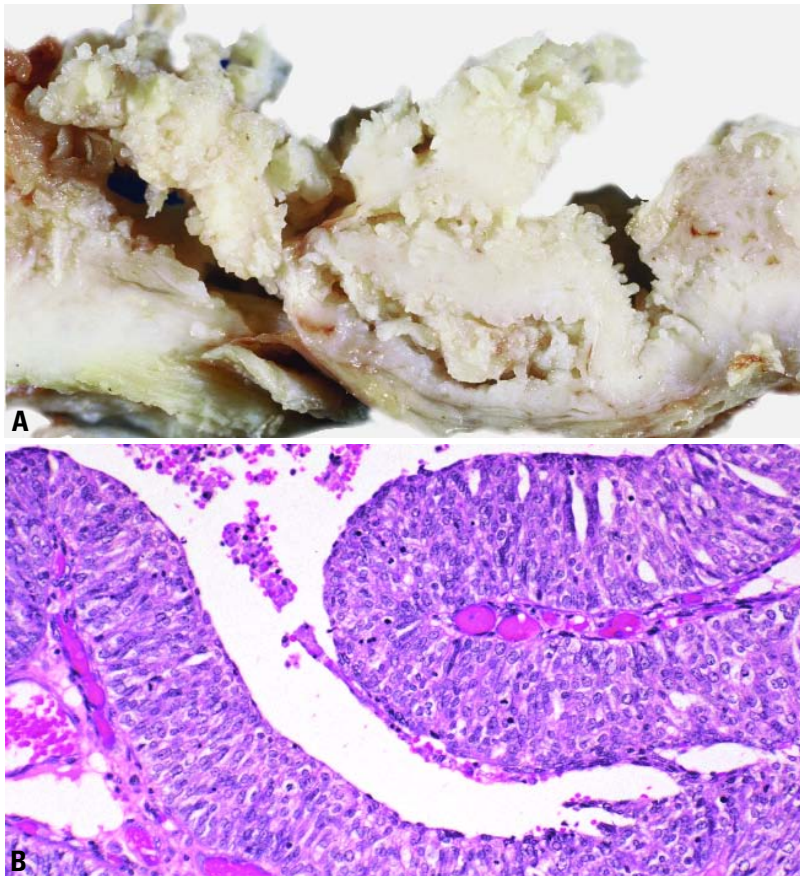


Fig. 2.48 **A** Transitional cell carcinoma. This tumour is primarily cystic with prominent intracystic papillary projections. **B** Papillary growth of malignant transitional epithelium with a smooth luminal border predominates.

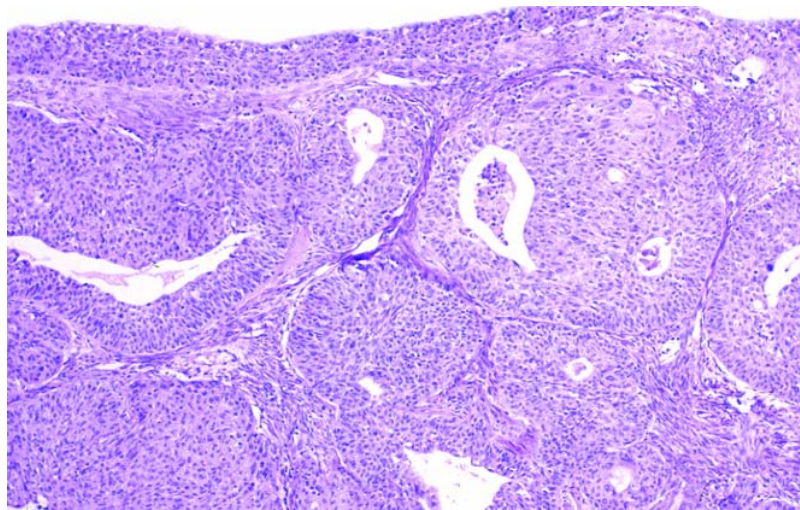


Fig. 2.49 Malignant Brenner tumour. The malignant component consists of large, closely-packed, irregular aggregates of transitional epithelial cells infiltrating the stroma. There was also an area of benign Brenner tumour (not shown).

Transitional cell tumours

Definition

Ovarian tumours composed of epithelial elements histologically resembling urothelium and its neoplasms.

Histopathology

This group of tumours includes the following:

- (1) Benign Brenner tumours, distinguished by a prominent stromal component accompanying transitional cell nests.
- (2) Borderline and malignant Brenner tumours in which a benign Brenner tumour component is associated with exuberantly proliferative, variably atypical but non-invasive transitional epithelium in the former and unequivocal stromal invasion in the latter.
- (3) Transitional cell carcinoma in which a malignant transitional cell tumour is not associated with a benign or borderline Brenner component.

ICD-O codes

Transitional cell carcinoma (non-Brenner)	8120/3
Malignant Brenner tumour	9000/3
Borderline Brenner tumour	9000/1
Brenner tumour	9000/0

Epidemiology

Transitional cell tumours account for 1-2% of all ovarian tumours.

Transitional cell carcinoma

Definition

An ovarian tumour that is composed of epithelial elements histologically resembling malignant urothelial neoplasms and does not have a component of benign or borderline Brenner tumour.

Epidemiology

Transitional cell carcinoma is the pure or predominant element in 6% of ovarian carcinomas {2676}. The great majority of transitional cell carcinomas occur in women 50-70 years old {1110}.

Clinical features

The presentation of women with transitional cell carcinoma is the same as with other malignant ovarian tumours, abdominal pain, swelling, weight loss, and bladder or bowel symptoms {139,2676}.

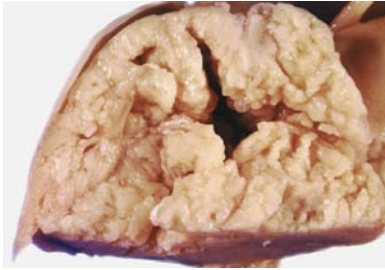

Fig. 2.50 Borderline Brenner tumour. A large, papillary, polypoid component protrudes into a cystic space.

Macroscopy

Transitional cell carcinomas are bilateral in approximately 15% of cases [139] and are macroscopically indistinguishable from other surface epithelial-stromal tumours [139,2676].

Tumour spread and staging

At the time of diagnosis transitional cell carcinomas have spread beyond the ovary in over two-thirds of cases [2676].

Histopathology

Transitional cell carcinomas resemble those occurring in the urinary tract and lack a benign or borderline Brenner tumour component [139,2676]. Typically, they are papillary with multilayered transitional epithelium and a smooth luminal border ("papillary type"). A nested pattern characterized by malignant transitional cell nests irregularly distributed in fibrotic stroma ("malignant Brenner-like type") has been described [2464,2465]. As in urothelial carcinoma, foci of glandular and/or squamous differentiation may occur. Very commonly, transitional cell carcinoma is admixed with other epithelial cell types, primarily serous adenocarcinoma. Transitional cell carcinomas lack the prominent stromal calcification characteristic of some benign and malignant Brenner tumours.

Immunoprofile

Ovarian transitional cell carcinomas have an immunoprofile that differs from transitional cell carcinomas of the urinary tract and closely resembles that of ovarian surface epithelial-stromal tumours. Ovarian transitional cell carcinomas are consistently uroplakin, thrombomodulin and cyokeratin 13 and 20 negative and CA125 and cytokeratin 7 positive [2115, 2371].

Grading

Transitional cell carcinomas should be graded utilizing criteria for transitional cell carcinoma of the urinary tract.

Histogenesis

The term transitional cell carcinoma is not uniformly accepted, and overlapping features with other epithelial-stromal tumours, particularly serous carcinoma, are present. It is important that strict histological criteria be applied to establish the diagnosis [2465]. Not only an architectural but also a histological resemblance to transitional epithelium is required. The frequent association with epithelial-stromal tumours of other types strongly suggests a surface epithelial ori-

gin [2465]. In addition, several immunohistochemical studies have demonstrated that the tumour lacks a urothelial phenotype [2115,2371]. Thus, the ovarian neoplasm shows histological but not immunohistochemical similarities to transitional cell carcinoma of the urinary bladder.

Prognosis and predictive factors

The overall 5-year survival rate for transitional cell carcinoma is 35%. Some, but not all, investigators have reported greater chemosensitivity and higher 5-year survival in patients whose metastases are composed purely or predominantly of transitional cell carcinoma [564, 1232,2676].

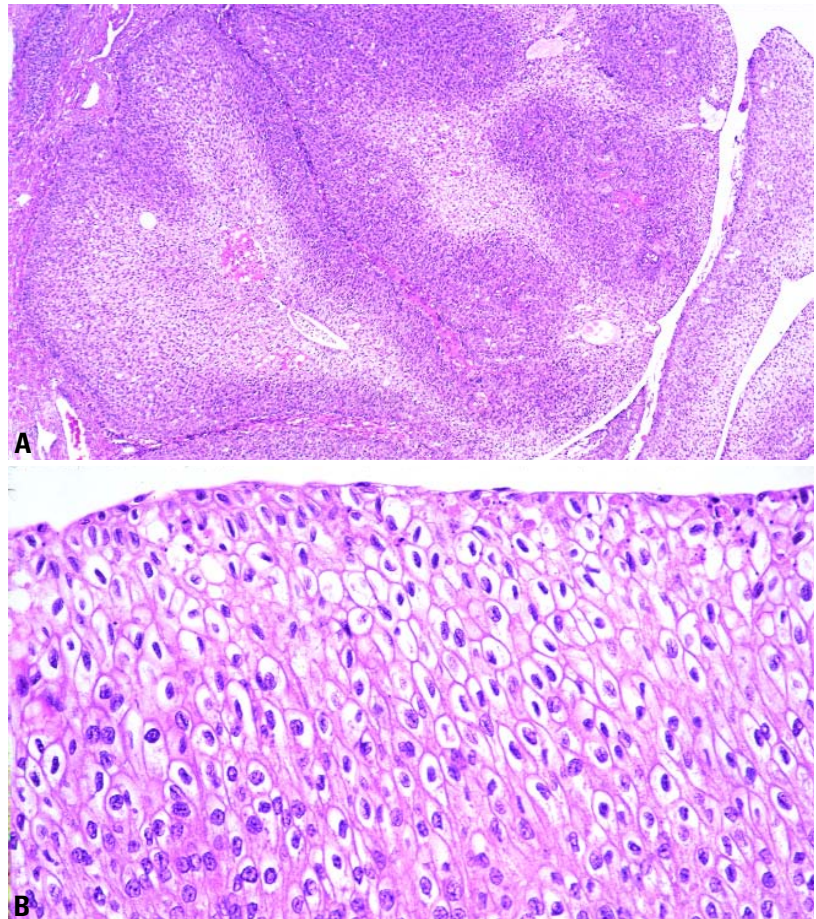


Fig. 2.51 Borderline Brenner tumour (proliferating Brenner tumour). **A** Complex undulating and papillary transitional cell epithelium protrudes into a cystic space. **B** The transitional epithelium is thick with low grade cytological features.

Malignant Brenner tumour

Definition

An ovarian tumour containing invasive transitional cell aggregates as well as benign nests of transitional epithelium set in a fibromatous stroma.

Epidemiology

The great majority of malignant Brenner tumours occur in women 50-70 years old {1110,1868,2676}. Only 5% of Brenner tumours are malignant {1110,1868}.

Clinical features

Most patients seek medical attention because of an abdominal mass or pain {139,2460,2461}. A few patients present with abnormal vaginal bleeding.

Macroscopy

Malignant Brenner tumours are typically large with a median diameter of 16-20 cm and typically have a solid component resembling benign Brenner tumour as well as cysts containing papillary or polypoid masses {2461}.

Tumour spread and staging

Malignant Brenner tumours are bilateral in 12% of cases {139,452}. About 80% of malignant Brenner tumours are stage 1 at the time of diagnosis.

Histopathology

In malignant Brenner tumours there is stromal invasion associated with a benign or borderline Brenner tumour component {139}. The invasive element is usually high grade transitional cell carcinoma or squamous cell carcinoma, although occasional tumours are composed of crowded, irregular islands of malignant transitional cells with low grade features {2460}. Glandular elements may be admixed, but pure mucinous or serous carcinomas associated with a benign Brenner tumour component should not be diagnosed as a malignant Brenner tumour. Foci of calcification are occasionally prominent.

Immunoprofile

The very small number of malignant Brenner tumours studied have exhibited a benign Brenner tumour immunoprofile in that component with a variable pattern of antigen expression in the invasive component; uroplakin immunopositivity has occurred in some {2371}.

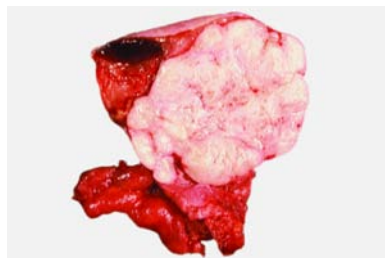


Fig. 2.52 Benign Brenner tumour. Sectioned surface is firm, lobulated and fibroma-like with a small cystic component.

Prognosis and predictive factors

When confined to the ovary, malignant Brenner tumours have an excellent prognosis. Patients with stage IA tumours have an 88% 5-year survival, and those with high stage malignant Brenner tumours have a better prognosis than stage matched transitional cell carcinomas {139}.

Borderline Brenner tumour

Synonyms

Brenner tumour of low malignant potential, proliferating Brenner tumour (for cases with low grade features).

Definition

An ovarian transitional cell tumour of low malignant potential with atypical or malignant features of the epithelium but lacking obvious stromal invasion.

Epidemiology

Only 3-5% of Brenner tumours are borderline {1110,1868}.

Tumour spread and staging

Borderline Brenner tumours are confined to the ovary and, with rare exceptions, have been unilateral {1110,1868,2461,3144}.

Clinical features

Most patients seek medical attention because of an abdominal mass or pain {139,2460,2461}. A few patients present with abnormal vaginal bleeding.

Macroscopy

Borderline Brenner tumours are typically large with a median diameter of 16-20 cm. They usually have a solid component resembling benign Brenner tumour as well as a cystic component containing a papillary or polypoid mass {2461}.

Histopathology

Borderline Brenner tumours show a greater degree of architectural complexity than benign Brenner tumours typified by branching fibrovascular papillae surfaced by transitional epithelium often protruding into cystic spaces. The transitional epithelium manifests the same spectrum of architectural and cytological features encountered in urothelial lesions of the urinary tract. By definition, there is no stromal invasion. A benign Brenner tumour component is typically present but may be small and easily overlooked. The mitotic rate is highly variable but may be brisk, and focal necrosis is common. Mucinous metaplasia may be a prominent feature. The diagnostic criteria and terminology applied to the intermediate group of transitional cell tumours is somewhat controversial {2461,2605}. Some have advocated categorizing tumours with low grade features as "proliferating" rather than borderline {2461}, and others designate those resembling grade 2 or 3 transitional cell carcinoma of the urinary tract as "borderline with intraepithelial carcinoma" {2605}.

Prognosis and predictive factors

No Brenner tumour in the intermediate category without stromal invasion has metastasized or caused the death of a patient {1110,2461}.

Benign Brenner tumour

Definition

An ovarian transitional cell tumour composed of mature urothelial-like cells arranged in solid or cystic circumscribed aggregates within a predominantly fibromatous stroma.

Epidemiology

Benign Brenner tumours account for 4-5% of benign ovarian epithelial tumours {1409,1502,1970,2865}. Most benign Brenner tumours (95%) are diagnosed in women 30-60 years old {753,905,1868,2460,2461,2676,2685,3073,3186}.

Clinical features

The majority of patients with benign Brenner tumours are asymptomatic; over 50% of tumours are less than 2 cm and are typically discovered incidentally in ovaries removed for some other reason {753,905,2685,3073}. In only 10% of cases is the tumour larger than 10 cm;

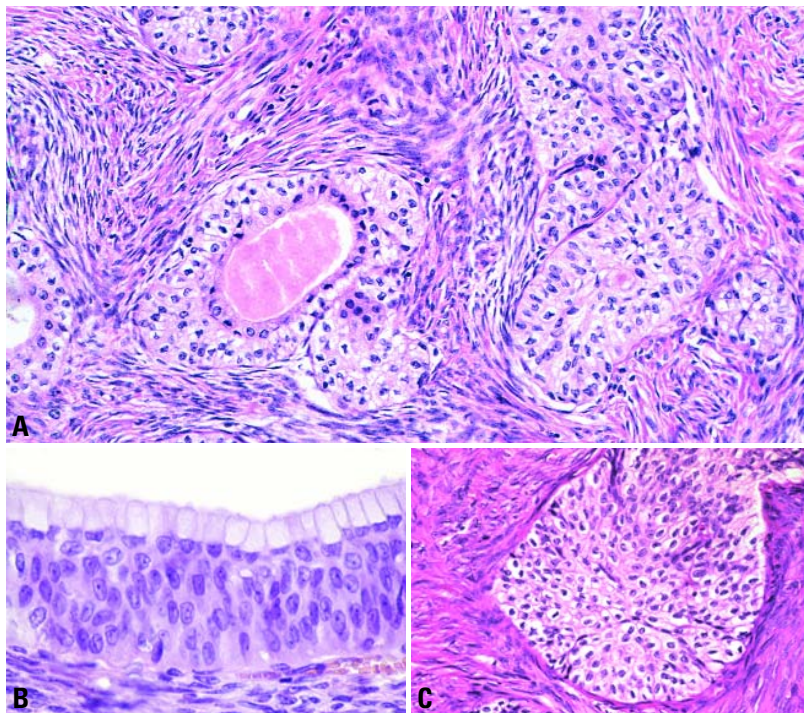


Fig. 2.53 Benign Brenner tumour. **A** One of the transitional cell nests is cystic and contains eosinophilic secretions. **B** One of the transitional cell nests contains a central lumen lined by mucinous columnar epithelium. **C** This transitional cell nest shows scattered grooved, coffee bean shaped nuclei.

such patients may present with non-specific signs and symptoms referable to a pelvic mass. Occasionally, Brenner tumours are associated with manifestations related to the elaboration of estrogens or androgens by the stromal component of the tumour.

Macroscopy

The typical benign Brenner tumour is small, often less than 2 cm, but, regardless of size, is well circumscribed with a firm, white, sometimes gritty sectioned surface due to focal or extensive calcification. Small cysts are common, and a rare tumour is predominately cystic. Brenner tumours are associated with another tumour type, usually mucinous cystadenoma, in 25% of cases

Tumour spread and staging

Only 7-8% of benign Brenner tumours are bilateral [753]

Histopathology

Benign Brenner tumours are characterized by nests and islands of transitional type epithelial cells with centrally

grooved, "coffee bean" nuclei, abundant amphophilic to clear cytoplasm and distinct cell membranes growing in a dominant fibromatous stroma. The nests may be solid or exhibit central lumina containing densely eosinophilic, mucin-positive material. The lumina may be lined by transitional type cells or mucinous, ciliated or nondescript columnar cells. Variably sized cysts lined by mucinous epithelium, either pure or overlying transitional epithelium are common in benign Brenner tumours. Benign Brenner tumours with crowded transitional nests and cysts with a prominent mucinous component, sometimes with complex gland formations, are termed "metaplastic Brenner tumour" by some and not mixed epithelial tumours [2461] since the epithelial components are admixed rather than separate. Their recognition avoids confusion with borderline or malignant Brenner tumours.

Immunoprofile

Benign Brenner tumours show some urothelial differentiation evidenced by uroplakin expression, but they do not

express thrombomodulin and have been immunonegative for cytokeratin 20 in most, but not all, studies [2085,2115,2116,2371,2758].

Benign Brenner tumours have an endocrine cell component demonstrable with immunostains for chromogranin A, serotonin and neuron specific enolase [45,2530].

Somatic genetics

There is one report of a 12q14-21 amplification in a benign Brenner tumour [2207].

Squamous cell lesions

Squamous cell carcinoma

Definition

Malignant ovarian tumour composed of squamous epithelial cells that is not of germ cell origin.

ICD-O code 8070/3

Epidemiology

The age of women with squamous cell carcinoma, pure or associated with endometriosis, has ranged from 23-90 years.

Macroscopy

Most squamous cell carcinomas are solid, although in some instances cystic components predominate.

Histopathology

Histologically, squamous cell carcinomas are usually high grade and show a variety of patterns including papillary or polypoid, cystic, insular, diffusely infiltrative, verruciform or sarcomatoid. They must be distinguished from endometrioid adenocarcinomas with extensive squamous differentiation and from metastatic squamous cell carcinoma from the cervix and other sites [3198].

Histogenesis

Most squamous cell carcinomas arise from dermoid cysts and are classified in the germ cell tumour category. Less commonly, they occur in association with endometriosis [1624,1828,1973,2255,2902], as a component of malignant Brenner tumour [2460] or in pure form [2255] and are considered to be surface epithelial-stromal tumours. Some pure

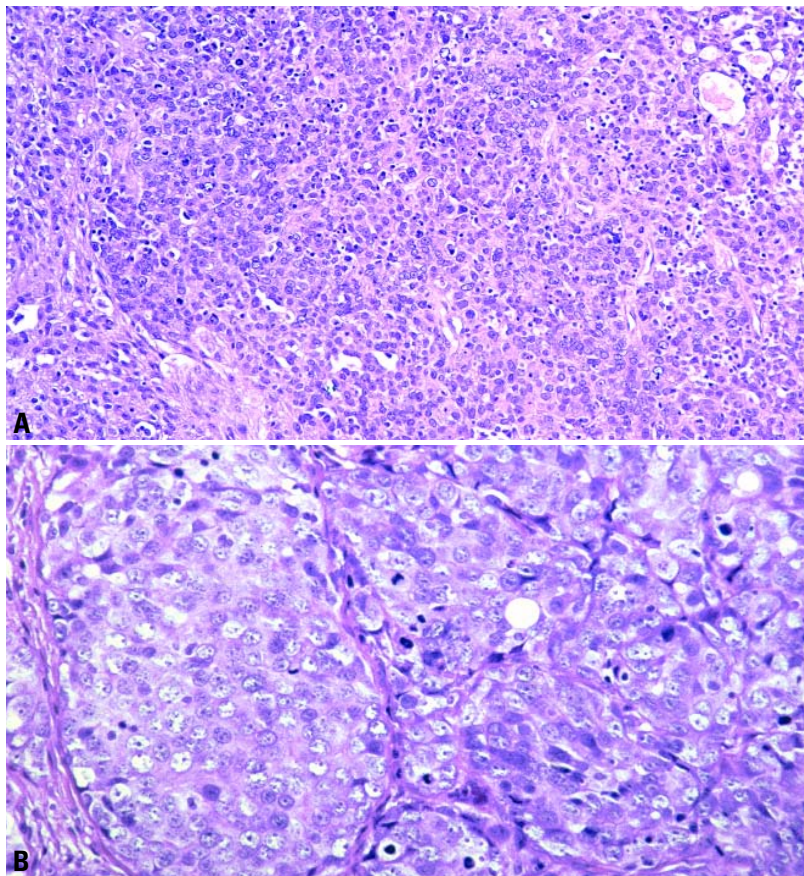


Fig. 2.54 Undifferentiated carcinoma of the ovary. **A** Sheets of tumour cells with small cystic spaces are separated by irregular fibrous septa. **B** Aggregates of undifferentiated tumour cells with pleomorphic nuclei and frequent mitotic figures are separated by thin bands of fibrous stroma.

squamous cell carcinomas have occurred in women with cervical squamous cell carcinoma in situ {1738}.

Prognosis and predictive factors

Most tumours have spread beyond the ovary at the time of presentation, and the prognosis in the small number of reported cases is poor.

Epidermoid cyst

Definition

Benign ovarian cysts lined by squamous epithelial cells that are not clearly of germ cell origin.

Histopathology

Epidermoid cysts lined by benign keratinized squamous epithelium devoid of skin appendages and unaccompanied by teratomatous elements are rare in the

ovary {823,3205}. All are small (2-46 mm) and unilateral.

Histogenesis

The presence of small epithelial cell nests resembling Walthard cell nests in the walls of epidermoid cysts suggests an epithelial rather than a teratomatous origin {3205}.

Mixed epithelial tumours

Definition

An ovarian epithelial tumour composed of an admixture of two or more of the five major cell types: serous, mucinous, endometrioid, clear cell and Brenner/transitional. The second or second and third cell types must comprise alone or together at least 10% of the tumour epithelium, or, in the case of a

mixed Brenner-mucinous cystic tumour, both components should be macroscopically visible. A mixed epithelial tumour (MET) may be benign, borderline or malignant. Endometrioid tumours with squamous differentiation and neuroendocrine tumours associated with a surface epithelial-stromal tumour are not included in this definition.

ICD-O codes

Malignant mixed epithelial tumour 8323/3
Borderline mixed epithelial tumour 8323/1
Benign mixed epithelial tumour 8323/0

Epidemiology

The reported incidence of MET varies from 0.5-4% of surface epithelial-stromal tumours. This variability is due in part to problems in developing a standardized classification.

Tumour spread and staging

Mixed epithelial borderline tumours (MEBTs) are stage I in 93% of cases and show bilateral ovarian involvement in 22% {2496}.

Histopathology

In cystadenomas the most frequent mixture is serous (ciliated) and mucinous epithelium. The mucinous epithelium should contain abundant intracytoplasmic mucin, not just apical or luminal mucin. MEBTs show papillae with detached cell clusters reminiscent of serous borderline tumours, but they generally contain a mixture of endocervical-like mucinous cells, endometrioid epithelium with focal squamous differentiation and indifferent eosinophilic epithelium. An acute inflammatory infiltrate is frequently seen. Microinvasion may be seen rarely. Mixed Brenner-mucinous tumours are usually composed of a benign, and, occasionally, a borderline Brenner component; the mucinous component may be benign, borderline or malignant. A few mucinous glands within Brenner nests or histological areas of mucinous differentiation represent mucinous metaplasia in Brenner tumours, a common finding, and are not a MET. Rarely, the tumour macroscopically contains a myriad of small cysts lined by an admixture of mucinous and transitional epithelium and the term metaplastic Brenner tumour is applied {2461}. For cystadenocarcinomas frequent combinations are serous and endometrioid,

serous and transitional cell carcinoma and endometrioid and clear cell.

Grading

The least differentiated component determines the tumour grade.

Histogenesis

Endometriosis, occasionally with atypia, is found in association with 53% of MEBT [2496] and up to 50% of mixed clear cell-endometrioid tumours [2511]. Some cases show a transition from endometriosis to neoplastic epithelium.

Somatic genetics

It is impossible to make broad statements, as studies are limited to a few cases. LOH on chromosome 17, common in serous tumours, has been found in two of five mixed endometrioid-serous tumours [959]. *PTEN* mutation, which has been associated with the endometrioid type, has also been noted in a mixed mucinous-endometrioid tumour [2075]. *KRAS* mutations, an early event in mucinous tumours, have been noted in three mixed Brenner-mucinous tumours [589]. The mucinous cystadenocarcinoma and Brenner tumour components shared amplification of 12q 14-21 in one MET, suggesting clonal relatedness [2207].

Prognosis and predictive factors

The behaviour of MEBT is similar to that of endocervical-like mucinous borderline tumours. The dominant cell type generally dictates behaviour. An exception is mixed endometrioid and serous carcinoma, which, even when the serous component is minor, behaves more aggressively than pure endometrioid carcinoma and similarly to their serous counterpart. Mixed endometrioid and serous carcinoma may recur as serous carcinoma [2907]. This finding stresses the importance of careful sampling of an endometrioid cystadenocarcinoma to rule out a mixed serous component.

Undifferentiated carcinoma

Definition

A primary ovarian carcinoma with no differentiation or only small foci of differentiation.

ICD-O code 8020/3

Epidemiology

When applying the WHO criteria, approximately 4-5% of ovarian cancers are undifferentiated carcinoma. The frequency of undifferentiated carcinoma was 4.1% when defined as carcinomas with solid areas as the predominant component representing over 50% of the tumour [2677].

Clinical features

In the only large series the age of the patients ranged from 39-72 (mean, 54 years) [2677].

Macroscopy

Macroscopically, undifferentiated carcinoma does not have specific features. The tumours are predominantly solid, usually with extensive areas of necrosis.

Tumour spread and staging

According to FIGO, 6% of the patients are discovered in stage I, 3% are in stage II, 74% in stage III and 17% in stage IV; thus 91% of the tumours are discovered in stages III and IV [2677].

Histopathology

Histologically, undifferentiated carcinoma consists of solid groups of tumour cells with numerous mitotic figures and significant cytological atypia. Areas with a spindle cell component, microcystic pattern and focal vascular invasion can be seen. It is unusual to see an undifferentiated carcinoma without any other component of müllerian carcinoma. Usually, areas of high grade serous carcinoma are present. Foci of transitional cell carcinoma can also be seen. Undifferentiated carcinoma of the ovary does not have a specific immunophenotype.

Differential diagnosis

The main differential diagnoses are granulosa cell tumour of the adult type, transitional cell carcinoma, poorly differentiated squamous cell carcinoma, small cell carcinoma and metastatic undifferentiated carcinoma.

Granulosa cell tumours may have a diffuse pattern; however, it is unusual not to have also areas with a trabecular pattern, Call-Exner bodies or areas showing sex cords. In addition, undifferentiated carcinoma

is a more anaplastic tumour with a larger number of mitotic figures.

Transitional cell carcinomas might have areas of undifferentiated tumour; however, either a trabecular pattern or large papillae are always identified in the former.

Small cell carcinoma of the hypercalcaemic type typically occurs in young women and often contains follicle-like structures. The cells of small cell carcinoma of the pulmonary type show nuclear molding and have high nuclear to cytoplasmic ratios.

Finally, metastatic undifferentiated carcinomas are uniform tumours without papillary areas.

All these differential diagnoses can usually be resolved when the tumour is well sampled, and areas with a different macroscopic appearance are submitted. Sampling will identify the different components of the tumour that are characteristic of primary ovarian lesions.

Prognosis and predictive factors

The five-year survival of patients with undifferentiated carcinoma is worse than that of ovarian serous or transitional cell carcinoma. Only 6% of these patients survive for 5 years.

Unclassified adenocarcinoma

Definition

A primary ovarian adenocarcinoma that cannot be classified as one of the specific types of müllerian adenocarcinoma because it has overlapping features or is not sufficiently differentiated. These tumours are uncommon.

ICD-O code 8140/3

Histopathology

Tumours in this category would include well or moderately differentiated tumours with overlapping features such as a mucinous tumour with cilia, or it might include a less differentiated tumour without distinctive features of one of the müllerian types of adenocarcinoma.

Prognosis and predictive factors

Since this group of tumours has not yet been specifically studied, the prognosis is not known.

Sex cord-stromal tumours

F.A. Tavassoli
E. Mooney
D.J. Gersell
W.G. McCluggage
I. Konishi

S. Fujii
T. Kiyokawa
P. Schwartz
R.A. Kubik-Huch
L.M. Roth

Definition

Ovarian tumours composed of granulosa cells, theca cells, Sertoli cells, Leydig cells and fibroblasts of stromal origin, singly or in various combinations. Overall, sex cord-stromal tumours account for about 8% of ovarian neoplasms.

Granulosa-stromal cell tumours

Definition

Tumours containing granulosa cells, theca cells or stromal cells resembling fibroblasts or any combination of such cells.

Granulosa cell tumour group

Definition

A neoplasm composed of a pure or at the least a 10% population of granulosa cells often in a fibrothecomatous background. Two major subtypes are recognized, an adult and a juvenile type.

ICD-O codes

Granulosa cell tumour group
Adult granulosa cell tumour 8620/1
Juvenile granulosa cell tumour 8622/1

Epidemiology

Granulosa cell tumours account for approximately 1.5% (range, 0.6-3%) of all ovarian tumours. The neoplasm occurs in

a wide age range including newborn infants and postmenopausal women. About 5% occur prior to puberty, whereas almost 60% occur after menopause [284,2588].

Aetiology

The aetiology of these tumours is unknown. Several studies suggest that infertile women and those exposed to ovulation induction agents have an increased risk for granulosa cell tumours [2458, 2982,3125].

Clinical features

Signs and symptoms

Granulosa cell tumours may present as an abdominal mass, with symptoms suggestive of a functioning ovarian tumour or both. About 5-15% present with symptoms suggestive of haemoperitoneum secondary to rupture of a cystic lesion [3195]. Ascites develops in about 10% of the cases. The tumour is clinically occult in 10% of the patients [829]. Granulosa cell tumours produce or store a variety of steroid hormones. When functional, most are estrogenic, but rarely androgenic activity may occur. The symptoms and clinical presentation vary depending on the patient's age and reproductive status. In prepubertal girls, granulosa cell tumours frequently induce isosexual pseudoprecocious puberty. In women of reproductive age, the tumour may be associated with a variety of menstrual disorders related to hyperoestrinism. In postmenopausal women, irregular uterine bleeding

due to various types of endometrial hyperplasia or, rarely, well differentiated adenocarcinoma is the most common manifestation of hyperoestrinism. A rare unilocular thin-walled cystic variant is often androgenic when functional [1971,2059].

Imaging

Cross sectional imaging, i.e. computed tomography and magnetic resonance imaging is of value in the surgical planning and preoperative determination of resectability of patients with granulosa cell tumours [859,1480,1728,1915,2131]. In contradistinction to epithelial ovarian tumours, granulosa cell tumours have been described as predominantly solid adnexal lesions; variable amounts of cystic components may, however, be present. Enlargement of the uterus and endometrial thickening might be seen as a result of the hormone production of the tumour [859,1480,1728,1915,2131].

Adult granulosa cell tumour

Epidemiology

More than 95% of granulosa cell tumours are of the adult type, which occurs in middle aged to postmenopausal women.

Macroscopy

Adult granulosa cell tumours (AGCTs) are typically unilateral (95%) with an average size of 12.5 cm and are commonly encapsulated with a smooth or lobulated surface. The sectioned surface of the tumour

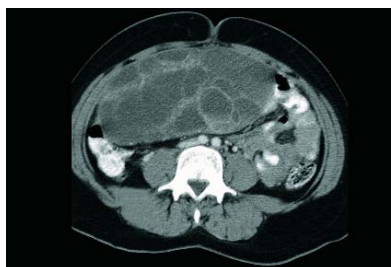

Fig. 2.55 Granulosa cell tumour. Axial contrast-enhanced computed tomography image of the pelvis shows a large, well defined, multicystic mass.

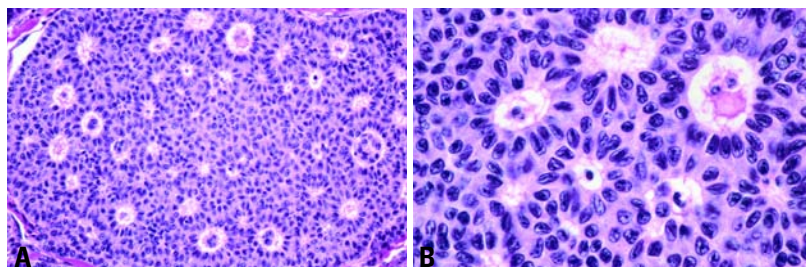


Fig. 2.56 Adult granulosa cell tumour, microfollicular pattern. **A** An aggregate of neoplastic granulosa cells contains numerous Call-Exner bodies. **B** The Call-Exner bodies contain fluid and/or pyknotic nuclei; the tumour cells have scant cytoplasm and longitudinal nuclear grooves.

is yellow to tan with a variable admixture of cystic and solid areas [906,2058]. Haemorrhage is seen in larger tumours; necrosis is focal and uncommon. A small percentage is totally cystic, either uniloculated or multiloculated [2058,2716]. A solid or cystic tumour with a combination of yellow tissue and haemorrhage is highly suggestive of a granulosa cell tumour.

Histopathology

Histologically, there is a proliferation of granulosa cells often with a stromal component of fibroblasts, theca or luteinized cells. The granulosa cells have scant cytoplasm and a round to ovoid nucleus with a longitudinal groove. The mitotic activity rarely exceeds 1-2 per 10 high power fields. When luteinized, the cells develop abundant eosinophilic or vacuolated cytoplasm, and the nuclei become round and lose their characteristic groove. The rare presence of bizarre nuclei does not have an adverse effect on the prognosis [2890,3210]. The tumour cells grow in a variety of patterns. The best known of these is the microfollicular pattern characterized by the presence of Call-Exner bodies. Others include the macrofollicular, characterized by large spaces lined by layers of granulosa cells, insular, trabecular, diffuse (sarcomatoid) and the moiré silk (watered silk) patterns. A fibrothecomatous stroma often surrounds the granulosa cells.

Immunoprofile

Granulosa cell tumours are immunoreactive for CD99, alpha-inhibin, vimentin, cytokeratin (punctate), calretinin, S-100 protein and smooth muscle actin. The tumour cells are negative for cytokeratin 7 and epithelial membrane antigen [482, 563,889,1815,2124,2379].

Differential diagnosis

Although endometrioid carcinomas may display an abundant rosette-like arrangement of nuclei mimicking Call-Exner bodies, they often show squamous metaplasia and lack nuclear grooves. Undifferentiated carcinomas and poorly differentiated adenocarcinomas may resemble the diffuse (sarcomatoid) pattern of granulosa cell tumours. These carcinomas have abundant mitotic figures and frequently have already extended beyond the ovary at presentation.

The insular and trabecular patterns of granulosa cell tumour may be mistaken for a

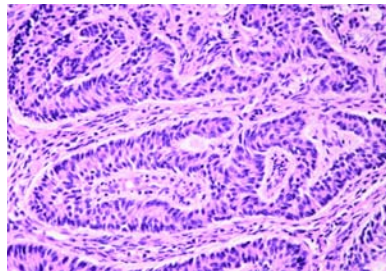


Fig. 2.57 Adult granulosa cell tumour, trabecular pattern. The granulosa cells form cords and trabeculae in a background of cellular fibrous stroma.

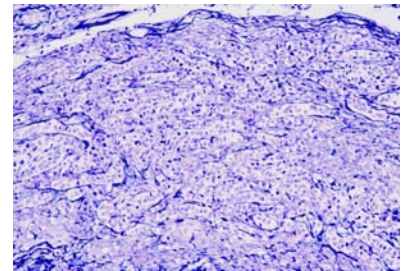


Fig. 2.58 Adult granulosa cell tumour. Reticulin surrounds the cords rather than investing individual cells (reticulin stain).

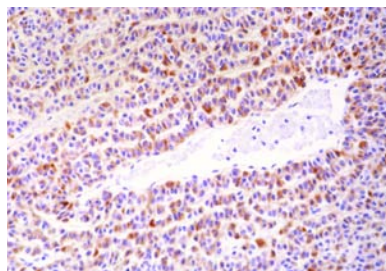


Fig. 2.59 Adult granulosa cell tumour, gyriform pattern. Immunostain for alpha-inhibin is moderately positive. The cords have a zigzag arrangement.

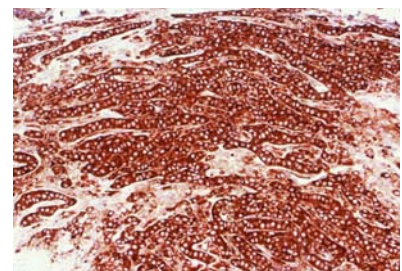


Fig. 2.60 Adult granulosa cell tumour. Immunostain for alpha-inhibin shows a diffuse, intensely positive reaction.

carcinoid and vice versa. Carcinoids have uniform round nuclei with coarse chromatin, lack nuclear grooves and show chromogranin positivity. Furthermore, primary carcinoids of the ovary are usually associated with other teratomatous elements, whereas the metastatic ones are generally multi-nodular and bilateral.

The diffuse pattern of granulosa cell tumours may be confused with a benign thecoma, particularly when there is luteinization. A reticulin stain is helpful since granulosa cells typically grow in sheets or aggregates bound by reticulin fibres, whereas thecomas contain an abundance of intercellular fibrils surrounding individual cells. The distinction

is important since granulosa cell tumours have an aggressive potential, whereas thecomas are with rare exceptions benign. Similarly, the presence of nuclear grooves and the absence of the characteristic vascular pattern of endometrioid stromal sarcoma distinguish AGCT from the former.

Somatic genetics

In contrast to older studies [1635,2862], recent karyotypic and fluorescence in situ hybridization analyses have shown that trisomy and tetrasomy 12 are rarely present in granulosa cell tumours [1635, 1653,2221,2635,2862]. The few available studies have shown trisomy 14 [1043]

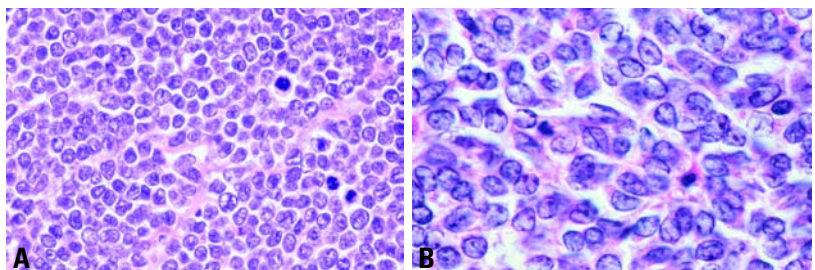


Fig. 2.61 Adult granulosa cell tumour, diffuse pattern. **A** Mitotic figures are more readily identifiable in the diffuse variant. **B** Note the presence of several nuclear grooves.

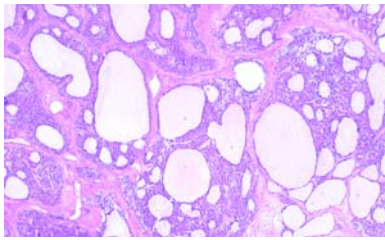


Fig. 2.62 Juvenile granulosa cell tumour. Neoplastic cell aggregates form multiple round to oval follicles containing basophilic fluid.

and structural changes in chromosome 6 with loss of 6q material [3021].

Prognosis and predictive factors

All granulosa cell tumours have a potential for aggressive behaviour. From 10–50% of patients develop recurrences. Some recurrences of AGCT develop as late as 20–30 years following the initial diagnosis [906,2058,2786], and long term follow-up is required.

The most important prognostic factor is the stage of the tumour [1815]. Nearly 90% of patients with granulosa cell tumour have stage I disease, however, and the prediction of tumour behaviour is most difficult in this group. Factors related to a relatively poor prognosis include age over 40 years at the time of diagnosis, large tumour size (>5cm), bilaterality, mitotic activity and atypia [906,1871,2786]. There is, however, disagreement on the precise significance of some of these factors. Among adults, survival is adversely affected by tumour rupture.

Juvenile granulosa cell tumour

Epidemiology

Accounting for nearly 5% of all granulosa cell tumours, juvenile granulosa cell tumour (JGCT) is encountered predominantly during the first 3 decades of life [3195].

Clinical features

In prepubertal girls, approximately 80% are associated with isosexual precocity [277,3195,3242].

Macroscopy

The macroscopic appearance of JGCT is not distinctive and is similar in its spectrum of appearances to the adult variant.

Tumour spread and staging

JGCT presents almost always as stage I disease; less than 5% of tumours are

bilateral, and only 2% have extraovarian spread.

Histopathology

JGCT is characterized by a nodular or diffuse cellular growth punctuated by macrofollicles of varying sizes and shapes. Their lumens contain eosinophilic or basophilic fluid. A fibrothecomatous stroma with variable luteinization and/or oedema is often evident. The typically rounded neoplastic granulosa cells have abundant eosinophilic and/or vacuolated cytoplasm; and almost all nuclei lack grooves. Mitotic figures are abundant. Cytomegaly with macronuclei, multinucleation and bizarre multilobulated nuclei is occasionally observed [2890,3210].

Differential diagnosis

Only the entity of small cell carcinoma associated with hypercalcaemia, which

also occurs in children and young women, poses a significant diagnostic problem. The clinical presentation of JGCT with estrogenic manifestations and that of small cell carcinoma with hypercalcaemia are important clues to the precise diagnosis.

Dissemination beyond the ovary is evident in 20% of these small cell carcinomas at presentation, a feature that is most unusual for a JGCT. The presence of necrosis and more eccentric nuclei in the carcinomas are additional features that can help. The presence of mucinous epithelium in 10% of cases and clusters of larger cells in most small cell carcinomas provide further support. Finally, immunostains for alpha-inhibin are positive in granulosa cell tumours but completely negative in the carcinomas. Both tumours may be negative with a variety of epithelial markers.

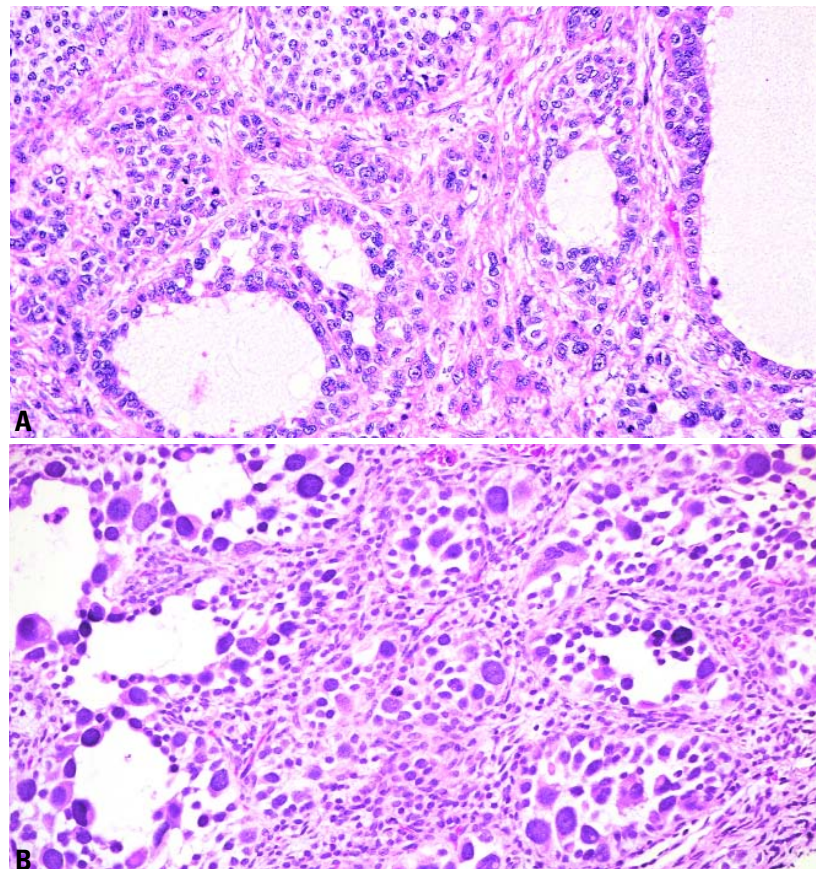


Fig. 2.63 Juvenile granulosa cell tumour. **A** Solid nests of primitive granulosa cells alternate with macrofollicles lined by the same cell population. **B** Moderate to severe atypia is sometimes evident in both the solid and the cystic areas.

Genetic susceptibility

JGCTs may present as a component of a variety of non-hereditary congenital syndromes including Ollier disease (enchondromatosis) {2857,3015} and Maffucci syndrome (enchondromatosis and haemangiomas) {1102,2859}. Bilateral JGCT may develop in infants with features suggestive of Goldenhar (craniofacial and skeletal abnormalities) {2306} or Potter syndrome {2468}.

Prognosis and predictive factors

Despite their more primitive histological appearance, only about 5% of JGCTs behave aggressively, and these usually do so within 3 years of presentation. The overall prognosis for JGCT is good with a 1.5% mortality associated with stage IA tumours; but it is poor in stage II or higher tumours {3195}.

Thecoma-fibroma group

Definition

Tumours forming a continuous spectrum from those composed entirely of fibroblasts and producing collagen to those containing a predominance of theca cells.

Thecoma	8600/0
Luteinized thecoma	8601/0
Fibroma, NOS	8810/0
Cellular fibroma	8810/1
Fibrosarcoma	8810/3
Stromal tumour with minor sex cord elements	8593/1
Sclerosing stromal tumour	8602/0

Thecoma

Definition

Thecomas are stromal tumours composed of lipid-containing cells resembling theca interna cells with a variable component of fibroblasts. Luteinized thecomas contain lutein cells in a background of thecoma or fibroma.

Epidemiology

Typical thecomas are about one-third as common as granulosa cell tumours. The great majority (84%) occur in postmenopausal women (mean age 59 years). Thecomas are rare before puberty, and only about 10% occur in women younger than 30 years {283}. The rare variant of luteinized thecoma associated

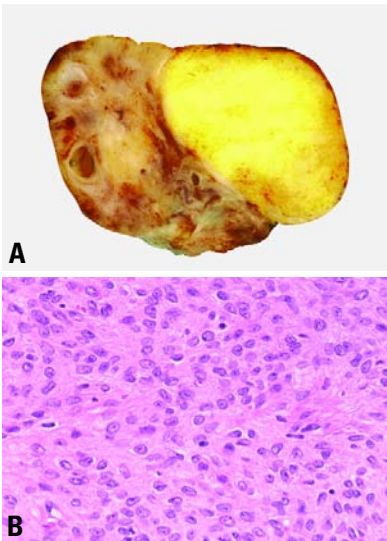


Fig. 2.64 Thecoma. **A** Sectioned surface shows a circumscribed bright yellow tumour compressing the adjacent ovary. **B** The tumour cells have abundant pale, poorly delimited cytoplasm.

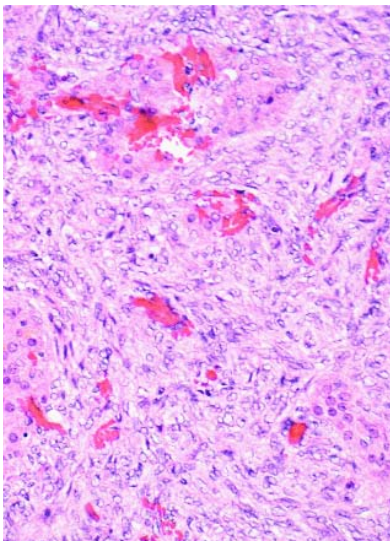


Fig. 2.65 Luteinized thecoma. Nests of luteinized tumour cells with eosinophilic cytoplasm and round nucleoli occur in a background of neoplastic spindle-shaped cells.

with sclerosing peritonitis typically occurs in young women less than 30 years, only rarely occurring in older women {520}.

Clinical features

Typical thecomas may be discovered incidentally or produce non-specific signs and symptoms of a pelvic mass. Symptoms related to estrogen produc-

tion including abnormal uterine bleeding occur in about 60% of patients, and about 20% of postmenopausal women with thecoma have endometrial adenocarcinoma or rarely a malignant müllerian mixed tumour or endometrial stromal sarcoma {2300}. Luteinized thecomas have a lower frequency of estrogenic manifestations than typical thecomas, and about 10% are associated with

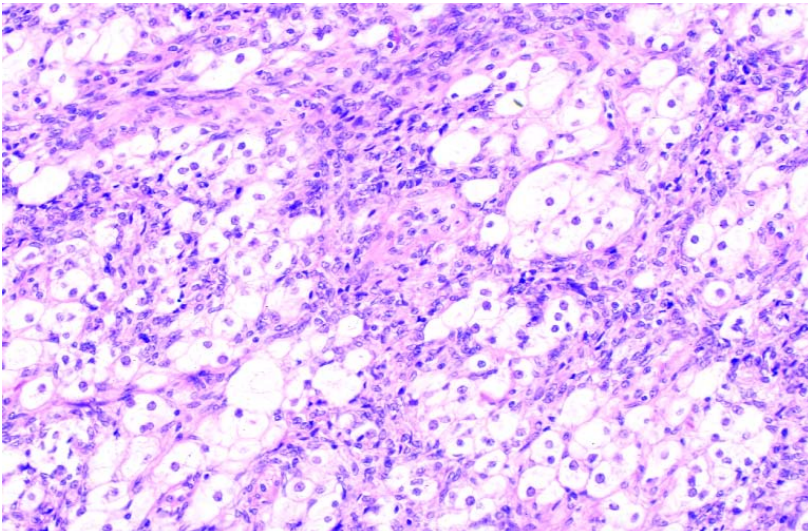


Fig. 2.66 Luteinized thecoma. There are clusters of luteinized cells with vacuolated cytoplasm dispersed among the spindle-shaped cells

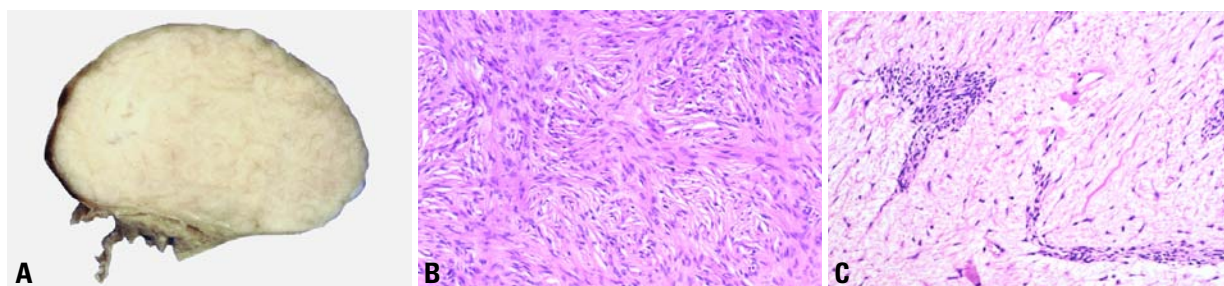


Fig. 2.67 Fibroma. **A** The sectioned surface shows a white fibrous tumour. **B** The neoplasm is composed of spindle-shaped cells with abundant collagen. **C** Oedema is striking in this fibroma associated with Meigs syndrome.

androgenic manifestations [3252]. Patients with the rare variant of luteinized thecoma associated with sclerosing peritonitis present with abdominal swelling, ascites and symptoms of bowel obstruction [520].

Macroscopy

Thecomas may be small and non-palpable, but they usually measure 5–10 cm. The sectioned surface is typically solid and yellow, occasionally with cysts, haemorrhage or necrosis. Typical thecomas are almost invariably unilateral; only 3% are bilateral. Luteinized thecomas associated with sclerosing peritonitis are usually bilateral.

Histopathology

Typical thecomas are characterized by cells with uniform, bland, oval to spindle

shaped nuclei with abundant, pale, vacuolated, lipid-rich cytoplasm. Individual cells are invested by reticulin. Mitoses are absent or rare. Rarely, the nuclei may be large or bizarre [3210]. The fibromatous component commonly contains hyaline plaques and may be calcified. Extensively calcified thecomas tend to occur in young women [3194]. Rarely, thecomas include a minor component of sex cord elements [3211]. Luteinized thecomas contain lutein cells, individually or in nests, in a background often more fibromatous than thecomatous. Oedema and microcyst formation may be striking.

Immunoprofile

Thecomas are immunoreactive for vimentin and alpha-inhibin [482,562,1499,1816,2181,2211].

Somatic genetics

Trisomy and tetrasomy 12 have been demonstrated in tumours in the thecoma-fibroma group by karyotypic analysis and fluorescence in situ hybridization [1635,1653,2221,2635,2862]. This chromosomal abnormality is not, however, specific to tumours in this group since it has also been found in some benign and borderline epithelial tumours, as well as in occasional granulosa cell tumours [2209,2221].

Prognosis and predictive factors

Rarely, a typical or luteinized thecoma with nuclear atypia and mitotic activity may metastasize [1819,3074,3252], although most cases reported as "malignant thecomas" are probably fibrosarcomas or diffuse granulosa cell tumours. Patients with luteinized thecomas associated with sclerosing peritonitis may experience small bowel obstruction, and several have died of complications related to peritoneal lesions, but there has been no recurrence or metastasis of the ovarian lesion [520].

Fibroma and cellular fibroma

Definition

Fibromas are stromal tumours composed of spindle, oval or round cells producing collagen. In cellular fibromas the cells are closely packed, collagen is scanty, and the mitotic rate is increased.

Epidemiology

Fibromas account for 4% of all ovarian tumours. They are most common in middle age (mean 48 years) [709]; less than 10% occur before age 30, and they occur only occasionally in children [328].

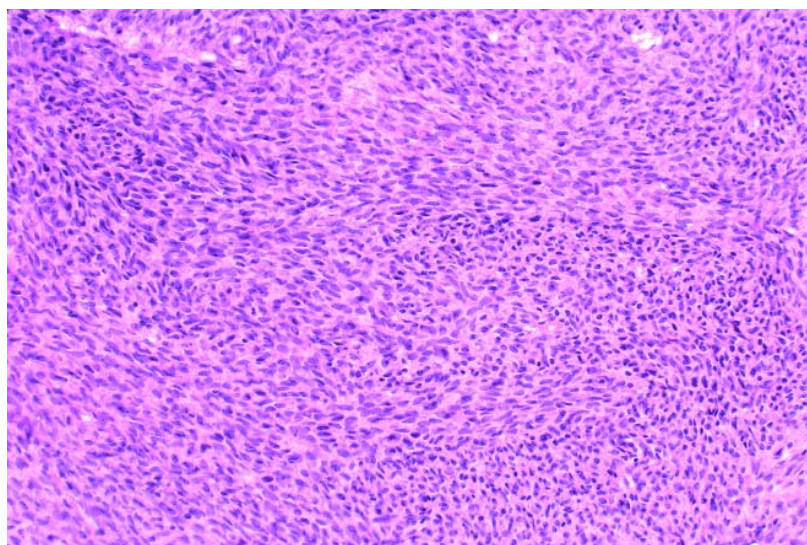


Fig. 2.68 Cellular fibroma. The tumour is cellular but shows no cytological atypia and has a low mitotic rate.

Clinical features

Fibromas may be found incidentally, but when large, patients may present with non-specific signs and symptoms of a pelvic mass. Between 10-15% of fibromas over 10 cm are associated with ascites [2519], and Meigs syndrome (ascites and pleural effusion with resolution after fibroma removal) occurs in about 1% of cases [1839].

Macroscopy

Fibromas are hard white tumours averaging 6 cm in diameter. Oedematous tumours may be soft, and cyst formation is common. Haemorrhage and necrosis are rare outside the setting of torsion. The majority of tumours are unilateral. Only 8% are bilateral, and less than 10% show focal or diffuse calcification.

Histopathology

Fibromas are composed of spindle-shaped cells with uniform, bland nuclei and scant cytoplasm that may contain small amounts of lipid or occasionally eosinophilic droplets. The cells are arranged in fascicles or in a storiform pattern. Mitoses are absent or rare. Fibromas are generally sparsely to moderately cellular with abundant intercellular collagen, hyalinized plaques and variable degrees of oedema. The cellularity may vary from area to area. About 10% of tumours are uniformly and densely cellular (attaining the cellularity of a diffuse granulosa cell tumour) and are referred to as cellular fibromas [2289]. Cellular fibromas exhibit no more than mild cytological atypia and an average of three or less mitoses per 10 high power fields. Fibromas express vimentin and may be immunoreactive for alpha-inhibin [1816, 2211].

Genetic susceptibility

Ovarian fibromas are common in females with the nevoid basal cell carcinoma syndrome, occurring in about 75% of patients having the syndrome referred to gynaecologists. Syndrome-related tumours are usually bilateral (75%), frequently multinodular, almost always calcified, sometimes massively, and tend to occur at a younger age, usually in children, adolescents, or young adults [1042,1354,2603]. Additional tumours may arise after local excision. The nevoid basal cell carcinoma syndrome has been reported in four

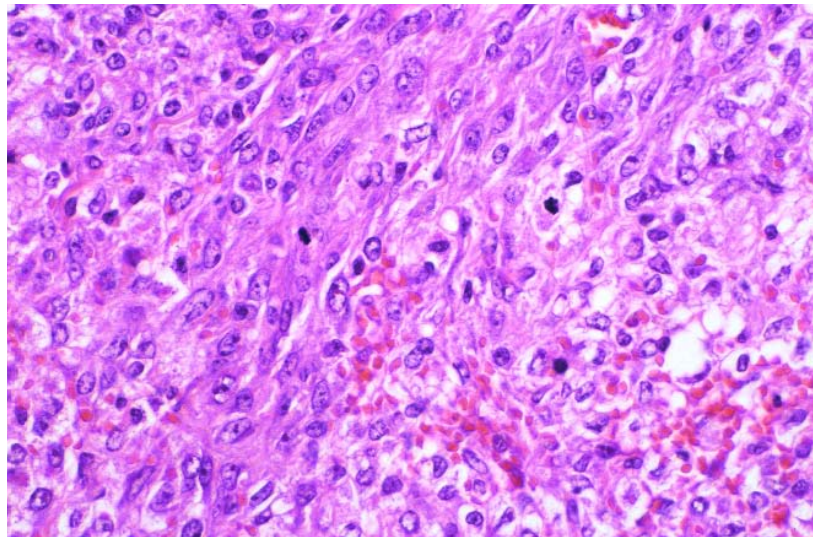


Fig. 2.69 Fibrosarcoma. Moderate to severe cytological atypia accompanied by numerous mitotic figures characterize this fibrosarcoma.

generations of a kindred lacking other stigmata of the syndrome [728,1635, 2221,2635].

Prognosis and predictive features

Rarely, cellular fibromas recur in the pelvis or upper abdomen, often after a long interval, particularly if they were adherent or ruptured at the time of diagnosis [2289]. Very rarely, fibromatous tumours with no atypical features may spread beyond the ovary [1722].

Fibrosarcoma

Definition

A rare fibroblastic tumour of the ovary that typically has 4 or more mitotic figures per 10 high power fields as well as significant nuclear atypia.

Epidemiology

Fibrosarcomas are the most common ovarian sarcoma, occurring at any age but most often in older women.

Macroscopy

Fibrosarcomas are large, solid tumours, commonly haemorrhagic and necrotic, and are usually unilateral.

Histopathology

Fibrosarcomas are densely cellular, spindle cell neoplasms with moderate to severe cytological atypia, a high mitotic rate (an average of 4 or more mitoses

per 10 high power fields) with atypical division figures, haemorrhage and necrosis [90,145,2289].

Somatic genetics

Trisomy 12 as well as trisomy 8 have been reported in an ovarian fibrosarcoma [2963].

Genetic susceptibility

Ovarian fibrosarcomas are rarely associated with Maffucci syndrome [484] and the nevoid basal cell carcinoma syndrome [1517].

Prognosis and predictive factors

The majority of ovarian fibrosarcomas have had a malignant course.

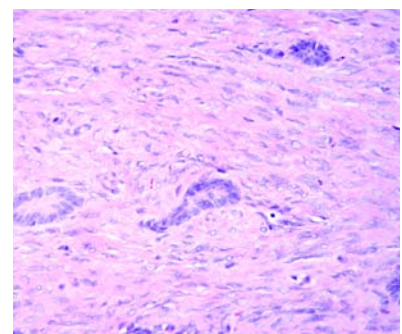


Fig. 2.70 Stromal tumour with minor sex cord elements. Rarely, fibrothecomas contain a few tubules lined by cells resembling Sertoli cells.

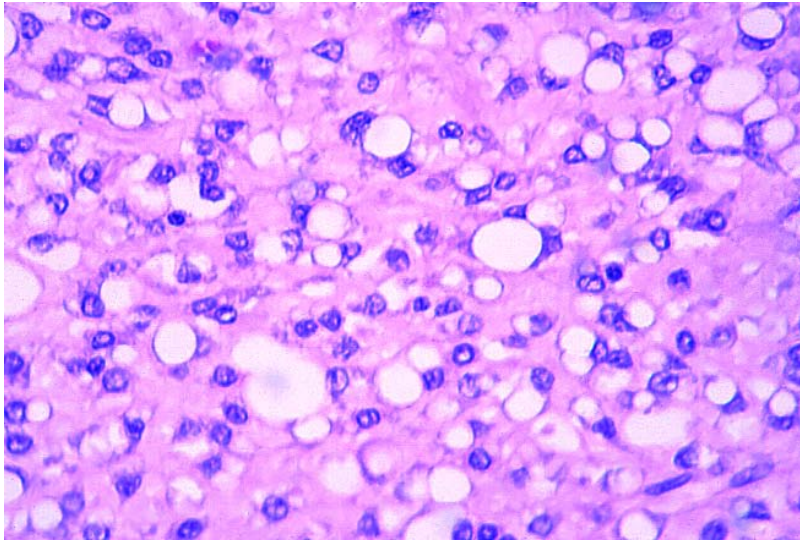


Fig. 2.71 Signet-ring stromal tumour. There is a diffuse proliferation of round cells with eccentric nuclei and a single large cytoplasmic vacuole resembling signet-ring cells.

Stromal tumour with minor sex cord elements

Definition

Stromal tumour with minor sex cord elements is a rare, fibrothecomatous tumour containing scattered sex cord elements [2605,3211]. By definition, the sex cord element must account for <10% of the composition of the tumour [2605].

Clinical features

This tumour may occur in women of any age. It is usually hormonally inactive, but there have been several cases associated with endometrial hyperplasia or adenocarcinoma.

Macroscopy

Macroscopically, the tumour is solid, not distinguishable from thecoma or fibroma, and ranges from 1-10 cm in diameter.

Histopathology

Histological examination demonstrates the typical features of thecoma or fibroma in which sex cord structures are intermingled with the fibrothecomatous cells. Sex cord components vary in appearance between fully differentiated granulosa cells and indifferent tubular structures resembling immature Sertoli cells.

Prognosis and predictive factors

All of the reported cases are benign.

Sclerosing stromal tumour

Definition

A distinctive type of benign stromal tumour characterized by cellular pseudolobules that are composed of

fibroblasts and round cells and separated by hypocellular, oedematous or collagenous tissue.

Epidemiology

This tumour accounts for 2-6% of ovarian stromal tumours, and more than 80% occur in young women in the second and third decades [433].

Clinical features

Presenting symptoms include menstrual abnormalities or abdominal discomfort [433,1280a,1409a,1695a]. Hormonal manifestations are rare [433], although a few tumours have been shown to produce estrogens or androgens [614,1222,1778,2315,2964]. Virilization may occur in pregnant women [419,738,1308].

Macroscopy

The tumour is typically unilateral and sharply demarcated, measuring 3-17 cm in diameter. The sectioned surface is solid, grey-white with occasional yellow foci and usually contains oedematous or cystic areas.

Histopathology

Histological examination shows a characteristic pattern with pseudolobulation of the cellular areas separated by hypocellular areas of densely collagen-

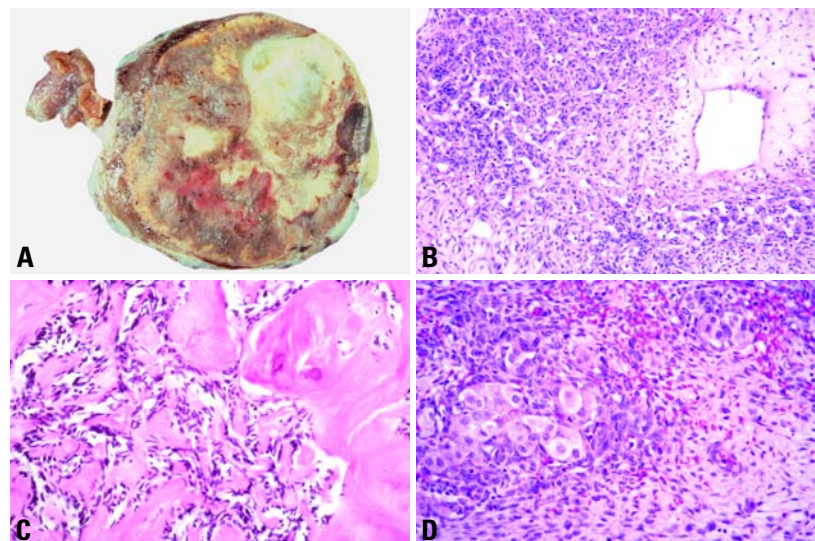


Fig. 2.72 Sclerosing stromal tumour. **A** Macroscopically, the variegated sectioned surface with alternating areas of oedema, haemorrhage and luteinization is typical. Histologically, cellular, often haemangiopericytoma-like, areas (**B**) alternate with sclerotic regions (**C**), and luteinized cell clusters (**D**).

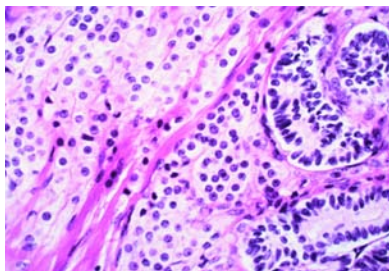


Fig. 2.73 Well differentiated Sertoli-Leydig cell tumour. The tumour shows well developed tubules lined by Sertoli cells and aggregates of Leydig cells.

nous or oedematous tissue. The cellular areas contain prominent thin-walled vessels with varying degrees of sclerosis admixed with both spindle and round cells, the latter may resemble luteinized theca cells or show perinuclear vacuolization. Histochemical studies show the activity of steroidogenesis-related enzymes {1575,2537} and immunoreactivity for desmin and smooth muscle actin, as well as vimentin {419,1419,2512,2637}.

Prognosis and predictive factors

The tumour is benign, and there have been no recurrent cases.

Signet-ring stromal tumour

Definition

A rare stromal tumour composed of signet-ring cells that do not contain mucin, glycogen or lipid {697,2332,2605,2811}.

Clinical findings

This tumour occurs in adults and is hormonally inactive.

Macroscopy

Macroscopically the tumours, may be both solid and cystic or uniformly solid.

Histopathology

Histological examination shows a diffuse proliferation of spindle and round cells; the latter show eccentric nuclei with a single large cytoplasmic vacuole and resemble signet-ring cells. The tumour may be composed entirely of signet-ring cells or may occur as a component of an otherwise typical fibroma. With the exception of one case {697}, nuclear atypia and mitotic figures are not present. Negative staining for mucin

distinguishes this tumour from the Krukenberg tumour. All of the reported cases are benign.

Sertoli-stromal cell tumours

Definition

Tumours containing in pure form or in various combinations Sertoli cells, cells resembling rete epithelial cells, cells resembling fibroblasts and Leydig cells in variable degrees of differentiation.

ICD-O codes

Sertoli-Leydig cell tumour group	
Well differentiated	8631/0
Of intermediate differentiation	8631/1
With heterologous elements	8634/1
Poorly differentiated	8631/3
With heterologous elements	8634/3
Retiform	8633/1
With heterologous elements	8634/1
Sertoli cell tumour, NOS	8640/1

Sertoli-Leydig cell tumour group

Definition

Tumours composed of variable proportions of Sertoli cells, Leydig cells, and in

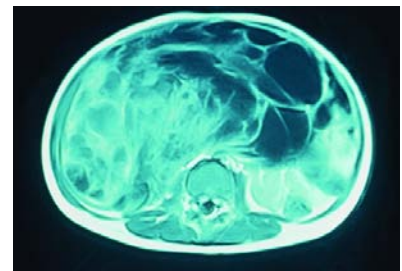


Fig. 2.74 T1 weighted MR image of a Sertoli-Leydig cell tumour that fills the abdomen.

the case of intermediate and poorly differentiated neoplasms, primitive gonadal stroma and sometimes heterologous elements.

Synonym

Androblastoma.

Epidemiology

Sertoli-Leydig cell tumours (SLCTs) are rare, accounting for <0.5% of ovarian neoplasms; intermediate and poorly differentiated forms are most common. SLCTs have been reported in females from 2-75 years of age with a mean age of 23-25 years in different studies {2459,3217,3243}.

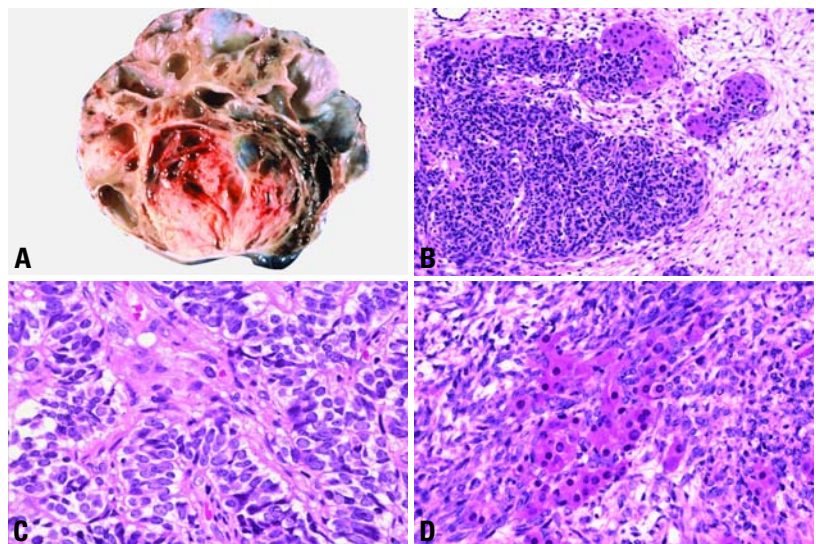


Fig. 2.75 Sertoli-Leydig cell tumour of intermediate differentiation. **A** The sectioned surface of the tumour shows solid, cystic and partly haemorrhagic areas. **B** Nests of Leydig cells are at the edge of an aggregate of Sertoli cells adjacent to an oedematous area. **C** Solid cords of Sertoli cells surround a cluster of Leydig cells in the centre of the field. **D** Leydig cells are admixed with gonadal stroma and sex cord elements.

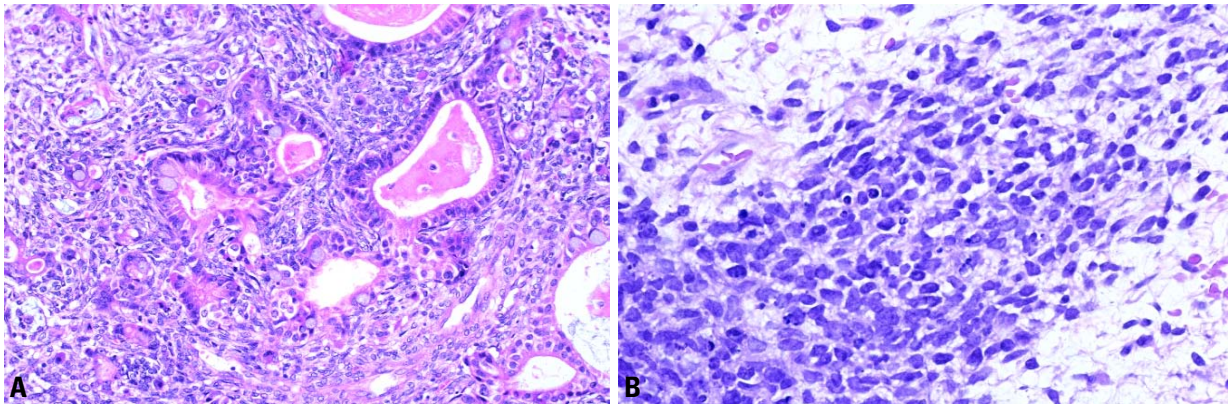


Fig. 2.76 Poorly differentiated Sertoli-Leydig cell tumour. **A** Heterologous elements consisting of mucinous glands are intimately associated with primitive gonadal stroma. **B** A nodule of primitive gonadal stroma is composed of poorly differentiated spindle-shaped cells with apoptotic bodies.

Clinical features

Signs and symptoms

One-third of patients are virilized, and others may have estrogenic manifestations. Androgenic manifestations include amenorrhea, hirsutism, breast atrophy, clitoral hypertrophy and hoarseness, whereas estrogenic effects include isosexual pseudoprecocity and menometrorrhagia. One-half of the patients have no endocrine manifestations, and the symptoms are non-specific. Patients with poorly differentiated neoplasms are slightly more likely to present with androgenic manifestations. About 10% of cases have tumour rupture or ovarian surface involvement, and 4% have ascites [3217].

Imaging

A solid, cystic or solid and cystic mass may be identified on ultrasound, computed tomography or magnetic resonance imaging.

Macroscopy

Over 97% of SLCTs are unilateral. They may be solid, solid and cystic or, rarely, cystic. The size ranges from not detectable to 35 cm (mean 12-14 cm). Poorly differentiated tumours are larger. Solid areas are fleshy and pale yellow, pink or grey. Areas of haemorrhage and necrosis are frequent, and torsion and infarction may be seen.

Tumour spread and staging

About 2-3% of tumours have spread beyond the ovary at presentation [3217].

Histopathology

In well differentiated SLCTs, Sertoli cells are present in open or closed tubules and lack significant nuclear atypia or mitotic activity [3216]. There is a delicate fibrous stroma in which Leydig cells may be found in small clusters.

In tumours of intermediate differentiation, cellular lobules composed of hyperchromatic spindle-shaped gonadal stromal cells with poorly defined cytoplasm are separated by oedematous stroma. These merge with cords and poorly developed tubules of Sertoli cells, some with atypia. With better differentiation of Sertoli cell elements, the distinction between the stromal and Sertoli cell components is more easily made. Leydig cells are found in clusters at the periphery of the cellular lobules or admixed with other elements. They may be vacuolated, contain lipofuscin or rarely have Reinke crystals. Mitotic figures average 5 per 10 high power fields. Mitotic figures are rare among the Leydig cells, which also lack cytological atypia.

In poorly differentiated tumours, a sarcomatoid stroma resembling primitive gonadal stroma is a dominant feature, and the lobulated arrangement of SLCT of intermediate differentiation is absent. Occasional tumours contain bizarre nuclei. The mitotic activity in the Sertoli and stromal elements is variable with a mean of over 20 per 10 high power fields.

Immunoprofile

Positivity is seen for vimentin, keratin and alpha-inhibin with differing intensity

of expression between sex cord and stromal areas. Rarely, positivity for epithelial membrane antigen may be seen. Positivity for estrogen and progesterone receptors may also be seen in a minority of cases.

Grading

SLCTs are subdivided into well differentiated, intermediate and poorly differentiated forms based on the degree of tubular differentiation of the Sertoli cell component (decreasing with increasing grade) and the quantity of the primitive gonadal stroma (increasing with increasing grade). Leydig cells also decrease with increasing grade. Heterologous elements and/or a retiform pattern may be seen in all but the well differentiated variant.

Somatic genetics

Analysis of six SLCTs has shown limited, if any, loss of heterozygosity with 10 polymorphic DNA markers that have shown high rates of loss of heterozygosity in a variety of tumours. Three of these were assessed for clonality by examining the DNA methylation pattern at a polymorphic site to the androgen receptor gene. The Leydig cells in these three cases were all polyclonal in contrast to the cells from a pure Leydig cell tumour that were monoclonal. These findings suggest that the Leydig cells in SLCTs are reactive cells of ovarian stromal origin and not a neoplastic component of the tumour [1902]. Trisomy 8 was reported as the sole karyotypic abnormality in a SLCT that metastasized [1756].

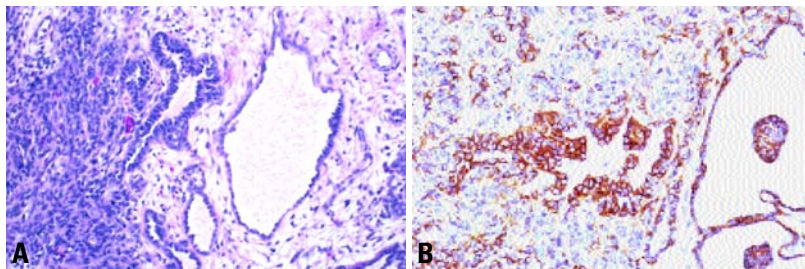


Fig. 2.77 **A** Retiform Sertoli-Leydig cell tumour. Note the retiform spaces surrounded by oedematous stroma at the periphery of a cellular nodule. **B** Keratin stains the retiform areas and shows limited staining of adjacent sex cord areas and stroma.

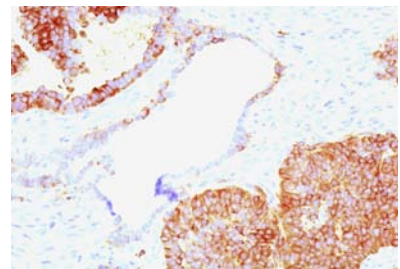


Fig. 2.78 Sertoli-Leydig cell tumour with retiform elements. The sex cord areas stain strongly for inhibin with weaker staining in retiform areas.

Genetic susceptibility

A familial occurrence of SLCTs in association with thyroid disease has been reported [1344] with occasional reports of other families since then. The thyroid abnormalities are usually adenomas or nodular goitres. Autosomal dominant inheritance with variable penetrance has been suggested as the method of genetic transmission. SLCT has been reported in association with cervical sarcoma botryoides in three cases [1026].

Prognosis and predictive factors

The mortality from SLCTs as a group is low and is confined to those of intermediate and poor differentiation. Poor differentiation, tumour rupture and heterologous mesenchymal elements were identified as features correlating with the development of metastases [302, 2459]. In one large series none of the well differentiated tumours, 11% of those of intermediate differentiation and 59% of those that were poorly differenti-

ated behaved in a clinically malignant fashion [3217]. Presentation with stage II or higher disease is also associated with a poor outcome. However, tumours without any apparent poor prognostic factors may behave in an aggressive fashion [1903].

Sertoli-Leydig tumour with heterologous elements

Definition

A SLCT that contains either macroscopic or histological quantities of a tissue not regarded as intrinsic to the sex cord-stromal category. Such elements include epithelial (mostly mucinous) and/or mesenchymal tissues (most commonly chondroid and rhabdomyoblastic) and tumours arising from these elements.

Clinical features

The presence of heterologous elements does not alter the presentation, but 20%

of patients have a slightly raised serum alpha-fetoprotein (AFP) due in some cases to hepatocytes as a heterologous element.

Macroscopy

Part or the entire cystic component of a SLCT may be mucinous in type; however, heterologous elements are only occasionally diagnosed macroscopically.

Histopathology

Heterologous elements are seen in approximately 20% of SLCTs. They occur only in those of intermediate or poor differentiation or in retiform tumours but are not identified in well-differentiated tumours. Heterologous mesenchymal elements occur in 5% of SLCTs and usually consist of cartilage, skeletal muscle or rhabdomyosarcoma. They may be admixed with the sex cord areas of the tumour or present as discrete areas. Both cartilage and skeletal

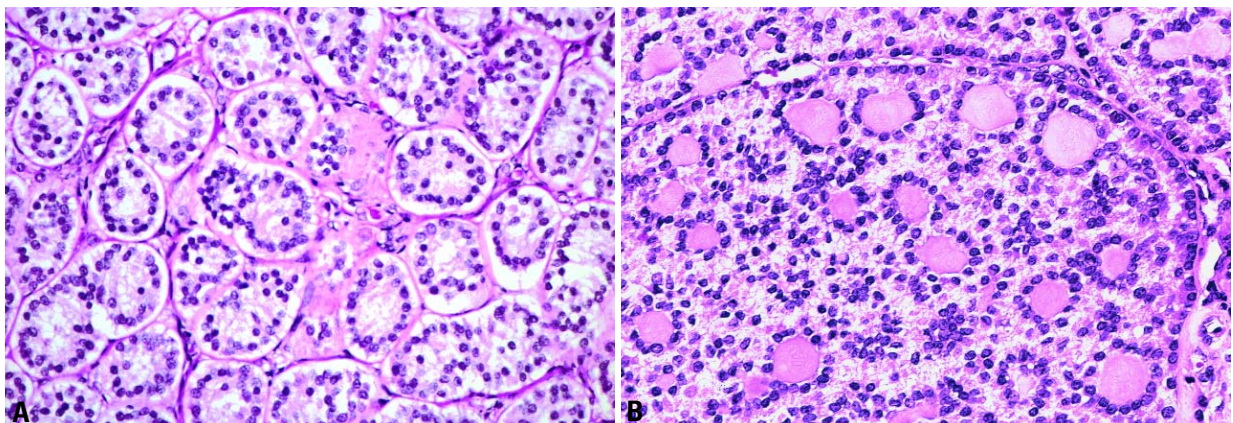


Fig. 2.79 **A** Sertoli cell tumour, simple tubular pattern. Note the hollow and obliterated tubules in cross section. **B** Sertoli cell tumour, complex tubular pattern. Islands of Sertoli cells are arranged around multiple round hyaline bodies.

muscle may appear cellular and of fetal type.

The mucinous epithelium is usually bland intestinal or gastric-type epithelium, but sometimes shows borderline or malignant change. Argentaffin cells, goblet cells and carcinoid may be seen. The gonadal stroma may condense around areas of mucinous epithelium, a useful clue to the diagnosis of a SLCT in a tumour that appears to be a mucinous cystadenoma. Hepatocytic differentiation may be recognized by the presence of bile plugs or an acinar arrangement of hepatocytes, but immunohistochemistry is usually necessary to distinguish hepatocytes from Leydig cells [1904].

Immunoprofile

Variable positivity is seen in the sex cord elements for vimentin, keratin and alpha-inhibin.

The immunoprofile of the heterologous elements is what would be expected from their constituent tissues. The mucinous elements show more extensive staining for cytokeratin 7 than for cytokeratin 20. They are positive for epithelial membrane antigen and may be focally positive for chromogranin. Leydig cells are negative for pan-keratin, CAM 5.2 and AFP but show intense positivity for vimentin and alpha-inhibin. These findings distinguish them from hepatocytes. AFP may be identified in

endodermal-like structures in some cases.

Prognosis and predictive factors

The small number of cases of this tumour reported make it difficult to determine the significance of individual elements. Heterologous mesenchymal elements (skeletal muscle or cartilage) or neuro-blastoma imply a poor outcome with 8 of 10 patients dead of disease [2291]. In contrast, gastrointestinal epithelium or carcinoid as the heterologous element does not have prognostic significance [3207].

Retiform Sertoli-Leydig cell tumour and variant with retiform elements

Definition

Retiform SLCT is composed of anastomosing slit-like spaces that resemble the rete testis and comprise 90% or more of the tumour. Tumours with at least 10% but less than 90% retiform elements are classified as being of intermediate or poor differentiation and qualified "with retiform elements".

Epidemiology

Retiform tumours tend to occur in younger patients but may occur at any age [3209]. Virilization is less common in tumours with a retiform pattern.

Macroscopy

Retiform tumours may contain papillae or polypoid structures.

Histopathology

Like heterologous elements, retiform areas occur only in SLCTS of intermediate and poor differentiation [2471,3209]. They vary from slit-like spaces to areas comprising a complex microcystic pattern. Dilated spaces may be continuous with sex cord areas of the tumour. The lining cells may be flattened and non-specific or cuboidal and sertoliform. The lumens frequently contain variably inspissated eosinophilic material resembling colloid. Within the SLCT category, retiform tumours shows the highest incidence of heterologous elements [3209].

Immunoprofile

Retiform areas stain with keratin and show moderate staining for alpha-inhibin, with a reversed pattern seen in sex cord and stromal areas of the tumour. Vimentin may show subnuclear localization in the retiform areas.

Differential diagnosis

Serous tumours, yolk sac tumours and malignant müllerian mixed tumours may resemble a retiform SLCT [3209]. The presence of primitive gonadal stroma, heterologous elements, Leydig cells and/or alpha-inhibin positivity assists in making the diagnosis.

Prognosis and predictive factors

Approximately 25% of patients with SLCTs that contain retiform elements will have an aggressive course [3209]. Many have stage II or higher disease, poor differentiation and/or heterologous elements.

Sertoli cell tumour

Definition

A neoplasm composed of Sertoli cells arranged in hollow or solid tubular formations with rare, if any, Leydig cells. Simple or complex annular tubules are dominant in those lesions that occur in association with the Peutz-Jeghers syndrome.

Epidemiology

Sertoli cell tumours are rare [2882]. Patients range in age from 2-79 years.

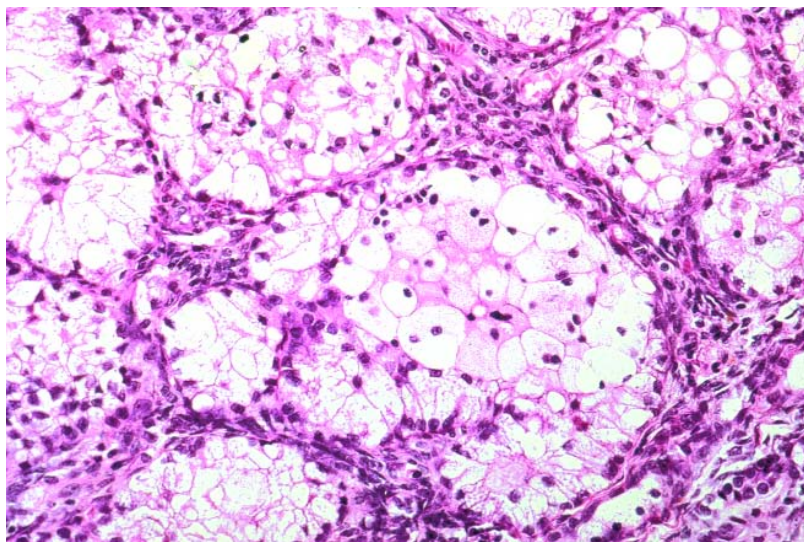


Fig. 2.80 Sertoli cell tumour, lipid-rich variant (folliculome lipidique). The Sertoli cells have abundant vacuolated cytoplasm filled with lipid.

Mean ages of 21 and 38 years and median ages of 33 and 50 years have been reported in the two largest series [2882,3215].

Clinical features

The tumours are functional in 40-60% of cases, most often estrogenic, but occasionally androgenic or rarely both. Rarely, the tumour produces progestins. Clinical manifestations include isosexual pseudoprecocity, menometrorrhagia, amenorrhea, hirsutism, breast atrophy, clitoral hypertrophy and hoarseness. Cases with menstrual disturbances or postmenopausal bleeding may show hyperplasia or adenocarcinoma of the endometrium. A peritoneal decidual reaction may be seen. Patients with Sertoli cell tumour may have elevated levels of serum estrogen, progesterone and luteinizing hormone. Rarely, the tumour may cause hypertension due to renin production.

Macroscopy

These are unilateral neoplasms, and the ovaries are involved with equal frequency. They range in size from 1-28 cm with an average of 7-9 cm. They are well circumscribed, solid neoplasms with a smooth or lobulated external surface, a fleshy consistency and a yellow-tan sectioned surface. Areas of haemorrhage and/or cystic degeneration may be seen in larger tumours. Rare examples are totally cystic or are solid with fibrosis and ossification.

Histopathology

A variety of tubular arrangements characterize Sertoli cell tumours. The tubular pattern is either open or closed (with paired cell arrangements) and simple or complex. Simple tubules are surrounded by a basement membrane and may contain a central hyaline body. Complex tubules form multiple lumens often filled with hyaline bodies and surrounded by a thick basement membrane that may coalesce to form hyalinized areas. Diffuse and pseudopapillary patterns may be seen. In some tumours, cells distended by intracytoplasmic lipid are dominant in a pattern known as "folliculome lipidique". The Sertoli cell tumours that occur in women with the Peutz-Jeghers syndrome may have abundant eosinophilic cytoplasm, termed the oxyphilic variant [852]. The nucleus is

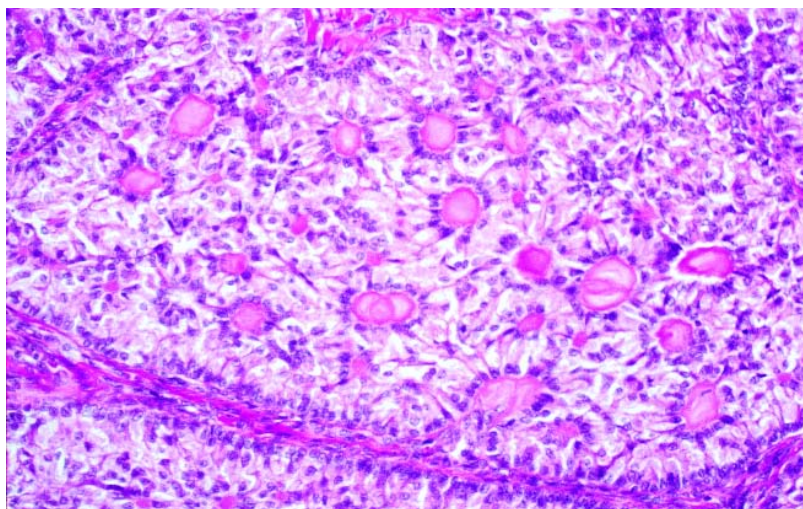


Fig. 2.81 Sex cord tumour with annular tubules in a case not associated with the Peutz-Jeghers syndrome. A complex annular tubular pattern consists of pale cells arranged around multiple hyaline bodies.

typically oval or spherical with a small nucleolus. The cytoplasm is clear or lightly vacuolated, stains for lipid are positive, and glycogen may be demonstrated. Mitotic figures are usually scanty (<1 per 10 high power fields), but >9 mitotic figures per 10 high power fields may be seen in tumours from younger women. The neoplasm may contain rare Leydig cells, but lacks the primitive gonadal stroma characteristic of Sertoli-Leydig cell tumours.

Immunoprofile

Sertoli cell tumours are variably positive for keratins, vimentin and alpha-inhibin. CD99 and calretinin are positive in about 50% of cases. The tumours are negative for epithelial membrane antigen.

Electron microscopy

A diagnostic feature of Sertoli cell tumour is the presence of Charcot-Böttcher (CB) filaments and Spangaro bodies. These bodies represent aggregates of intracytoplasmic microfilaments of varying size and are not present in every cell or every tumour. CB filaments have been found most frequently in the complex tubular variant, the so-called sex cord tumour with annular tubules (SCTAT).

Differential diagnosis

Sertoli cell tumours must be distinguished from struma ovarii, carcinoid

and endometrioid carcinoma (see section on endometrioid carcinoma). Phenotypic females with the androgen insensitivity syndrome (AIS) may be incorrectly diagnosed as having a Sertoli cell tumour of the ovary if the syndrome has not been diagnosed preoperatively [2498]. On the other hand, Sertoli cell tumours can occur in the testes of patients with AIS. While most are benign, rare malignant Sertoli cell tumours have been reported in this setting [3165].

Somatic genetics

There is little information on chromosomal abnormalities in these tumours. An extra isochromosome 1q was seen in one tumour [2208].

Genetic susceptibility

A variety of Sertoli cell phenotypes including SCTAT [2599], oxyphilic [852] and lipid rich (folliculome lipidique) variants have been described in patients with the Peutz-Jeghers syndrome (PJS), an autosomal dominant disease with a propensity for breast, intestinal and gynaecological neoplasia.

Prognosis and predictive factors

These tumours are typically benign. In the rare forms that behave clinically in an aggressive fashion, infiltration of the ovarian stroma, extension beyond the ovary and intravascular extension may be seen. Cytological atypia and a high

mitotic rate may be present in these tumours.

Stromal-Leydig cell tumour

Definition

An ovarian stromal tumour composed of fibromatous stroma and clusters of Leydig cells containing crystals of Reinke.

Clinical features

This tumour is virilizing in approximately one-half of the cases.

Macroscopy

These extremely rare neoplasms are usually well circumscribed {302,2165,2842}. The sectioned surface has been described as lobulated with a yellow-white appearance. They may be bilateral.

Histopathology

Stromal-Leydig cell tumours have two components. Spindle-shaped or ovoid stromal cells identical to those of a fibroma or thecoma are present together with Leydig cells containing Reinke crystals {2789,3252}. Typically, in these neoplasms the fibrothecomatous element predominates with the Leydig cell component comprising small nodular aggregates.

Definitive diagnosis requires the presence of Reinke crystals, otherwise the neoplasm would be categorized as luteinized thecoma. Since Reinke crystals may be difficult to identify and since sampling errors may occur, it has been suggested that stromal-Leydig cell tumours are more common than the literature would suggest.

Prognosis and predictive factors

The clinical behaviour of stromal-Leydig cell tumours is benign, and neither clinical recurrence nor metastasis has been documented.

Sex cord-stromal tumours of mixed or unclassified cell types

Definition

Sex cord-stromal tumours that do not fall in the granulosa-stromal, Sertoli-stromal or steroid cell categories.

ICD-O codes

Sex cord tumour with annular tubules	8623/1
Variant associated with Peutz-Jeghers syndrome	8623/0
Gynandroblastoma	8632/1
Sex cord-stromal tumour, NOS	8590/1

Sex cord tumour with annular tubules

Definition

A tumour composed of sex cord (Sertoli) cells arranged in simple and complex annular tubules {2599}.

Synonym

Sertoli cell tumour, annular tubular variant.

Epidemiology

Patients with this tumour most commonly present in the third or fourth decades, but the age ranges from 4-76 years. About one-third of cases occur in women with Peutz-Jeghers syndrome (PJS). The average age of patients with PJS is in the mid-twenties and of those unassociated with PJS in the mid-thirties.

Clinical features

Nearly all women without PJS present with a palpable mass. Isosexual pseudoprecocity or other features of aberrant estrogen occurs in about 40% of cases, and, occasionally, there are progesterone effects. Those tumours that are associated with PJS are found either incidentally at autopsy or in ovaries removed as part of treatment for other gynaecological disease.

Macroscopy

These are unilateral neoplasms except for those occurring in the PJS, which are usually bilateral. PJS-associated lesions are usually macroscopically undetectable; when visible, the tumourlets are multiple and <3 cm in diameter. Bilateral lesions are present in two-thirds of women. Non-PJS cases may be up to 33 cm in diameter. The sectioned surface of the tumours is solid and yellow. Calcification or cystic degeneration may be apparent.

Histopathology

Regardless of the clinical setting, the annular tubules show Sertoli cells with pale cytoplasm and nuclei arranged antipodally around a single hyaline body (simple annular tubules) or multiple hyaline bodies (complex annular tubules). Classic tubular Sertoli cell arrangements may be admixed. In PJS lesions the annular tubules are typically widely scattered in the ovarian stroma without forming a distinct mass.

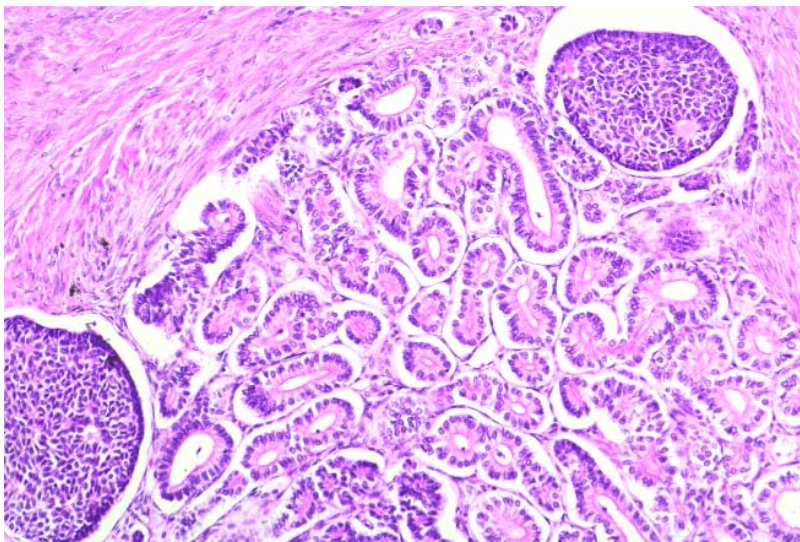


Fig. 2.82 Gynandroblastoma. Two islands of granulosa cells with Call-Exner bodies are located on either side of an aggregate of hollow tubules lined by Sertoli cells.

Tumours unassociated with PJS form masses of simple and complex tubules separated by sparse fibrous stroma. Extensive hyalinization may develop. The neoplastic cells may spill over beyond the confines of the tubules and infiltrate the surrounding stroma. Mitotic figures occasionally exceed 4 per 10 high power fields and rarely exceed 10 per 10 high power fields. Areas of well differentiated Sertoli cell tumour characterized by elongated solid tubules and/or microfollicular granulosa cell tumour are often present. Calcification of the hyaline bodies is typically found in over half of the tumours associated with PJS.

Electron microscopy

Ultrastructural assessment has shown Charcot-Böttcher filaments in several cases [2882]. While not required for diagnosis, their presence confirms the identification of the sex cord component as Sertoli cells.

Histogenesis

Although there is ultrastructural evidence supporting differentiation towards Sertoli cells in SCTAT, the histological and clinical features are sufficiently distinctive to merit its classification as a specific form of sex cord-stromal tumour.

Prognosis and predictive factors

All PJS-associated tumourlets have been benign. Up to 25% of SCTATs that occur in the absence of the PJS have been clinically malignant. Tumours with an infiltrative growth pattern and mitotic figures beyond the usual 3-4 per 10 high power fields are more likely to recur or otherwise behave aggressively. It is difficult, however, to predict the behaviour of individual cases. Some tumours produce müllerian inhibiting substance and/or alpha-inhibin, and these tumour markers may be useful in monitoring the course of disease in those cases [1091,2304]. Recurrences are often late and may be multiple. Spread through lymphatics may result in regional and distant lymph node involvement.

Somatic genetics

Germline mutations in a gene encoding serine-threonine kinase have been identified in a SCTAT associated with PJS but not in sporadic cases [548].

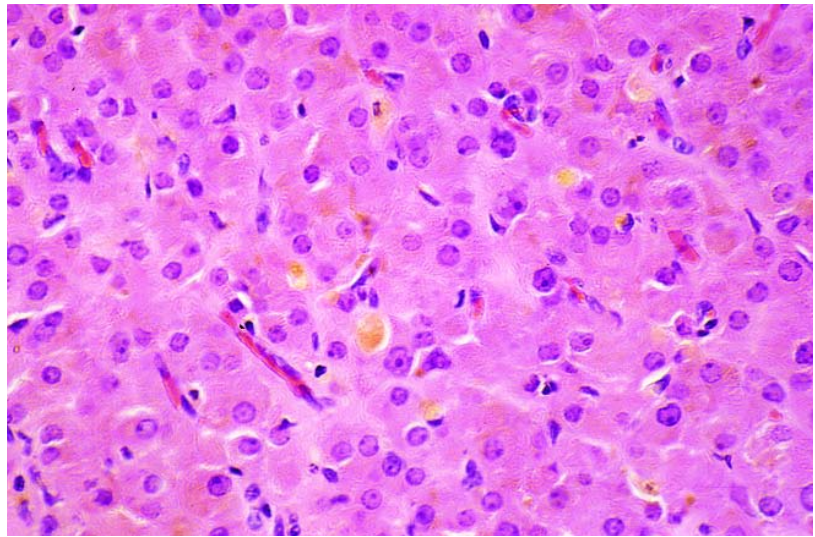


Fig. 2.83 Steroid cell tumour. The tumour is composed of large polygonal cells with eosinophilic cytoplasm containing lipofuscin pigment.

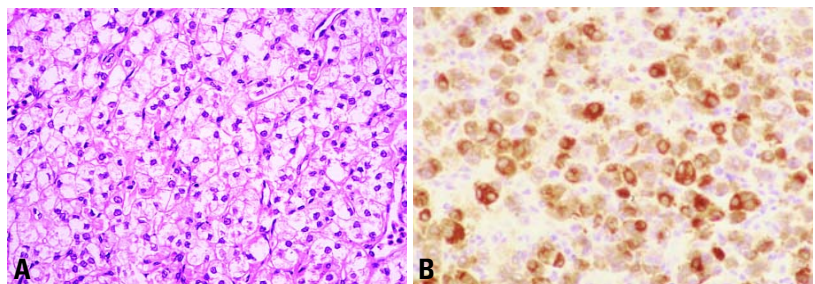


Fig. 2.84 **A** Steroid cell tumour composed of large polygonal cells with vacuolated cytoplasm. **B** Tumour cells show intense cytoplasmic immunoreactivity for alpha-inhibin.

Gynandroblastoma

Definition

A tumour composed of an admixture of well differentiated Sertoli cell and granulosa cell components with the second cell population comprising at least 10% of the lesion.

Clinical features

An extremely rare tumour, gynandroblastoma generally occurs in young adults, though it may be encountered in a wide age range [96,432,1820,1996]. Nearly all tumours present in stage I and may have either estrogenic or androgenic manifestations. Variable in size, they may be massive (up to 28 cm) with a predominantly solid sectioned surface showing a few cysts.

Histopathology

Well formed hollow tubules lined by Sertoli cells are generally admixed with rounded islands of granulosa cells growing in a microfollicular pattern. Variation from this typical histology with a juvenile granulosa cell pattern or an intermediate or poorly differentiated Sertoli-Leydig cell tumour with or without heterologous elements has been reported [1820]. The tumours are alpha-inhibin positive.

Prognosis and predictive factors

Almost all tumours are stage I at initial presentation and clinically benign. It is important to mention the components of the tumour in the diagnosis, in particular whether the granulosa cell component is of adult or juvenile type and also the subtype of Sertoli-Leydig cell tumour.

Unclassified sex cord-stromal tumour

Definition

Sex cord-stromal tumours in which there is no clearly predominant pattern of testicular or ovarian differentiation [2605].

Epidemiology

They account for 5-10% of tumours in the sex cord-stromal category.

Clinical features

The tumour may be estrogenic, androgenic or non-functional [2619,2701, 3196].

Histopathology

Histologically, the tumour cells show patterns and cell types that are intermediate between or common to granulosa-stromal cell tumours and Sertoli-stromal cell tumours.

Prognosis and predictive factors

The prognosis is similar to that of granulosa cell tumours and SLCTs of similar degrees of differentiation [2619].

Steroid cell tumours

Definition

Tumours that are composed entirely or predominantly (greater than 90%) of cells that resemble steroid hormone-secreting cells. This category includes the stromal luteoma, steroid cell tumour, not further classified and the Leydig cell tumours that do not have another component.

ICD-O codes

Steroid cell tumour, NOS	8670/0
Well differentiated	8670/0
Malignant	8670/3
Stromal luteoma	8610/0
Leydig cell tumour	8650/0

Synonym and historical annotation

The designation "lipid cell tumour" is no longer recommended because it is inaccurate as well as nonspecific, since up to 25% of tumours in this category contain little or no lipid [2605]. The term "steroid cell tumour" has been accepted by the World Health Organization (WHO) because it reflects both the morphological features of the neoplastic cells and their propensity to secrete steroid hormones.

Steroid cell tumour, not otherwise specified

Definition

These are steroid cell tumours that cannot be classified into one of the aforementioned groups. It is probable that some of these cases represent Leydig cell tumours in which Reinke crystals cannot be identified. Some may also represent large stromal luteomas where a parenchymal location can no longer be established.

Clinical features

They are usually associated with androgenic manifestations and occasionally with estrogenic effects [1163]. Rare neoplasms have also been associated with progestogenic effects, Cushing syndrome or other paraneoplastic syndromes due to hormone secretion [3218].

Macroscopy

These neoplasms are often large and are usually well circumscribed, often having a lobulated appearance. Occasional neoplasms are bilateral. The sectioned surface ranges from yellow to brown or black. Especially in large tumours, areas of haemorrhage and necrosis may be seen.

Histopathology

These neoplasms are usually composed of solid aggregates of cells with occasional nests or trabeculae. Tumour cells are polygonal with cytoplasm that is usually granular and eosinophilic but which may be vacuolated. Sometimes both cell types may be present. Cytoplasmic lipofuscin pigment may be identified. Nuclei may be bland, but in some cases there is considerable nuclear atypia and significant numbers of mitotic figures may be found. Areas of haemorrhage and necrosis can be present. Intracytoplasmic lipid can usually be identified with special stains and rarely may be so abundant as to result in a signet-ring appearance. Occasional tumours contain a considerable amount of fibrous stroma.

Immunoprofile

These neoplasms are usually immunoreactive to alpha-inhibin and variably with anti-cytokeratin antibodies and vimentin.

Differential diagnosis

Luteoma of pregnancy may mimic a lipid-poor or lipid-free steroid cell tumour. The former is usually discovered

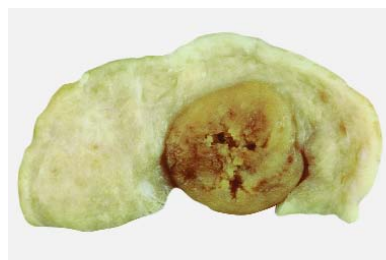


Fig. 2.85 Hilus cell tumour. Note the typical tan tumour in the hilus, well demarcated from the adjacent ovary.

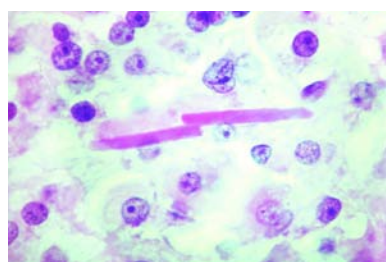


Fig. 2.86 Leydig cell tumour, non-hilus cell type. The cells are large and polygonal. Note the two large, rod-shaped crystals of Reinke.

in patients at caesarean section with a term pregnancy and typically occurs in multiparous Black patients in their third or fourth decade. Also in the differential diagnosis are oxyphilic variants of a number of other ovarian tumours, e.g. struma ovarii, clear cell carcinoma, primary or secondary malignant melanoma and carcinoid.

Prognosis and predictive factors

Approximately one-third of these neoplasms are clinically malignant, and they sometimes have extensive intra-abdominal spread at presentation. Malignant tumours are more likely to be greater than 7 cm diameter, contain areas of haemorrhage and necrosis, exhibit moderate to marked nuclear atypia and have a mitotic count of two or more per 10 high power fields. Occasionally, however, as with other endocrine neoplasms, the behaviour may be unpredictable, and tumours lacking these histological features may behave in a malignant fashion.

Stromal luteoma

Definition

Stromal luteomas are clinically benign steroid cell neoplasms of ovarian stro-

mal origin without crystals of Reinke {1164}.

Clinical features

Most occur in postmenopausal women and are associated with estrogenic effects, but occasional patients have androgenic manifestations {477}.

Macroscopy

These are usually unilateral tumours and are generally small. They are typically well circumscribed and on sectioning are usually grey-white or yellow.

Histopathology

These neoplasms are well circumscribed, are located in the ovarian stroma and are composed of a nodule of luteinized stromal cells that may be arranged diffusely or, less commonly, in nests and cords. The cytoplasm is pale or eosinophilic, the nuclei are bland, and mitoses are rare. Most cases are associated with stromal hyperthecosis in the same and/or contralateral ovary. In such cases it is arbitrary when a nodule of luteinized cells in stromal hyperthecosis is regarded as a stromal luteoma, but generally a cut-off of 1.0 cm in diameter is used. Degenerative changes may occur in stromal luteomas resulting in the formation of spaces that can simulate vessels or glandular formation. Reinke crystals are not present. Stromal luteomas usually exhibit positive immunohistochemical staining for alpha-inhibin.

Prognosis and predictive factors

All of the reported cases have behaved in a benign fashion.

Leydig cell tumours

Definition

Rare ovarian steroid cell neoplasms composed entirely or predominantly of Leydig cells that contain crystals of Reinke. In the case of larger tumours it may not be possible to determine whether the tumour arose in the ovarian parenchyma or in the hilus, and these are referred to as Leydig cell tumours not otherwise specified. Other tumours in this group include hilar cell tumours and Leydig cell tumour of non-hilar type.

Clinical features

These neoplasms typically occur in postmenopausal women {2171,2472} (average age 58 years) but may occur in young women, pregnant women {2165} or children. They are usually associated with androgenic manifestations, but occasionally produce estrogenic effects and are associated with endometrial carcinoma {1278,2455}. In single reports ovarian Leydig cell tumours have been associated with multiple endocrine neoplasia syndrome {2630} and congenital adrenal hyperplasia {1718}.

Immunoprofile

Leydig cell tumours of all types are intensely positive for alpha-inhibin and vimentin. There may be focal reactivity for keratins (CAM 5.2, AE1/AE3) with positivity for actin, CD68, desmin, epithelial membrane antigen and S-100 protein reported {2620}.

Prognosis and predictive factors

The clinical behaviour of all neoplasms in the pure Leydig cell category is benign, and neither clinical recurrence nor metastasis has been documented.

Hilus cell tumour

Definition

A Leydig cell tumour arising in the ovarian hilus separated from the medullary stroma.

Macroscopy

Hilus cell tumours are usually small, well circumscribed lesions located at the ovarian hilus and typically have a red brown to yellow appearance on sectioning. Rarely, they are bilateral {739,1718}. When they are larger, the hilar location may no longer be apparent.

Histopathology

On histological examination the lesion is well circumscribed and comprised of cells with abundant cytoplasm that usually is eosinophilic but which may be clear with abundant intracytoplasmic lipid. Lipofuscin pigment is often seen, and characteristic Reinke crystals were present in 57% of cases in the largest series {2171}. These are eosinophilic, rod-shaped inclusions. Occasionally, they are numerous, but they are often identified only after extensive searching.

PTAH histological staining or electron microscopy may facilitate their identification. Often the nuclei in Leydig cell tumours cluster with nuclear-rich areas separated by nuclear-free zones. The nuclear features are usually bland, but occasionally focal nuclear atypia may be found, an observation of no clinical significance. Mitotic figures are rare. Often, there is a background of hyperplasia of the adjacent non-neoplastic hilar cells in association with non-myelinated nerve fibres.

Although the definitive diagnosis of a hilar cell tumour requires the identification of Reinke crystals, a presumptive diagnosis can be made without crystals if the typical histological features are present in a neoplasm with a hilar location, especially if it is associated with hilus cell hyperplasia or nerve fibres {2171}.

Leydig cell tumour, non-hilar type

Definition

A Leydig cell tumour that originates from the ovarian stroma and containing crystals of Reinke.

Epidemiology

Leydig cell tumours of non-hilar type have been reported much less often than hilus cell tumours, but their true relative frequency is unknown.

Macroscopy

These tumours are macroscopically well circumscribed and centered in the medullary region {2472}.

Histopathology

They are histologically composed of steroid cells without discernible lipid and surrounded by ovarian stroma that often shows stromal hyperthecosis. Leydig cells containing demonstrable crystals of Reinke must be identified histologically in order to make the diagnosis, and lipofuscin pigment is often present.

Histogenesis

These tumours originate from the ovarian stroma, an origin supported by the rare non-neoplastic transformation of ovarian stromal cells to Leydig cells {2789}.

Germ cell tumours

F. Nogales
A. Talerman
R.A. Kubik-Huch
F.A. Tavassoli
M. Devouassoux-Shisheboran

Definition

A heterogeneous group of tumours reflecting the capacity for multiple lines of differentiation of the main stem cell system. The great majority of these neoplasms originate at different stages of development from germ cells that colonize the ovary.

Epidemiology

Germ cell tumours account for approximately 30% of primary ovarian tumours, 95% of which are mature cystic teratomas [1409,1502]. The remaining germ cell tumours are malignant and represent approximately 3% of all ovarian cancers in Western countries but have been reported to represent up to 20% of ovarian tumours in Japanese women [1970]. The median age at presentation is 18 years [883].

Malignant germ cell tumours are the most common ovarian cancer among children and adolescent females. Approximately 60% of ovarian tumours occurring in women under the age of 21 are of germ cell type, and up to one-third of them may be malignant [1555].

Aetiology

The aetiology of ovarian germ cell malignancies is unknown.

Clinical features

Signs and symptoms

Pain and a mass are the common pre-

sentations in young women [2586, 2587,2903]. Teenagers who present with abdominal masses and who have never menstruated should be evaluated for the possibility of a gonadoblastoma that has undergone malignant progression. Preoperative karyotyping of such individuals can be helpful to identify underlying chromosomal abnormalities in cases of gonadoblastoma.

Imaging

The ultrasonographic appearance of dermoid cyst ranges from a predominantly solid-appearing mass due to the echogenic aspect of sebaceous material intermixed with hair to a predominantly cystic mass [2132]. Computed tomography can accurately diagnose a teratoma because of fat attenuation within the cyst, and its complex appearance with dividing septa, hypodensity, calcified structures, and the identification of the Rokitansky protuberance [1080,2132]. Radiographic studies of fetiform teratoma demonstrate portions of skull, vertebra and limb bones within the tumour [19]. There are no diagnostic findings for other germ tumours; they often have solid and cystic components.

Histopathology

Morphologically, the different tumour types present in this group replicate in a distorted, grotesque form various stages of embryonal development from early,

transient structures to mature adult tissues that in their turn may also be capable of undergoing malignant change [2248].

Histogenesis

As for histogenesis, they are believed to be from the primordial germ cells that migrate into the gonadal ridge at 6 weeks of embryonic life [2848]. A small proportion may also arise from non-germ stem cells present in the adult female genital tract [2039].

Primitive germ cell tumours

Definition

Tumours that contain malignant germ cell elements other than teratoma.

ICD-O codes

Dysgerminoma	9060/3
Yolk sac tumour	9071/3
Embryonal carcinoma	9070/3
Polyembryoma	9072/3
Non-gestational choriocarcinoma	9100/3
Mixed germ cell tumour	9085/3

Dysgerminoma

Definition

A tumour composed of a monotonous proliferation of primitive germ cells associated with connective tissue septa containing varying amount of lymphocytes and macrophages. Occasionally, syncytiotrophoblastic differentiation or somatic cysts occur. This tumour is identical to testicular seminoma.

Macroscopy

The usually well encapsulated tumour masses are apparently unilateral in 90% of cases. Macroscopic involvement of the contralateral ovary is apparent in 10% of cases, and in another 10% occult foci of dysgerminoma can be detected by biopsy [1929]. Tumours average 15 cm in maximal dimension and on section are solid, uniform or lobular and creamy white or light tan. Irregular areas of coag-

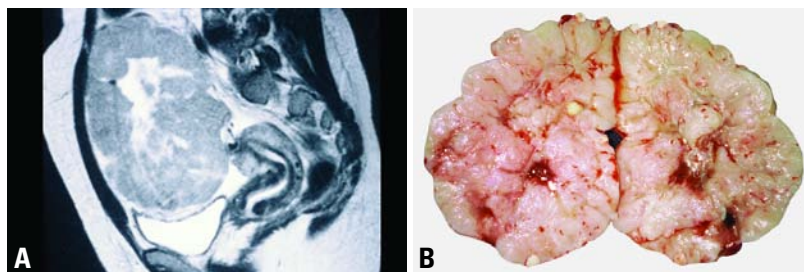


Fig. 2.87 Dysgerminoma in a 28 year old nulligravida woman. **A** Magnetic resonance image sagittal view shows a 10 x 15 cm predominantly solid tumour with some central cystic changes. **B** Sectioned surface of the tumour shows a predominantly solid, multilobulated appearance with some cystic degeneration and foci of necrosis.

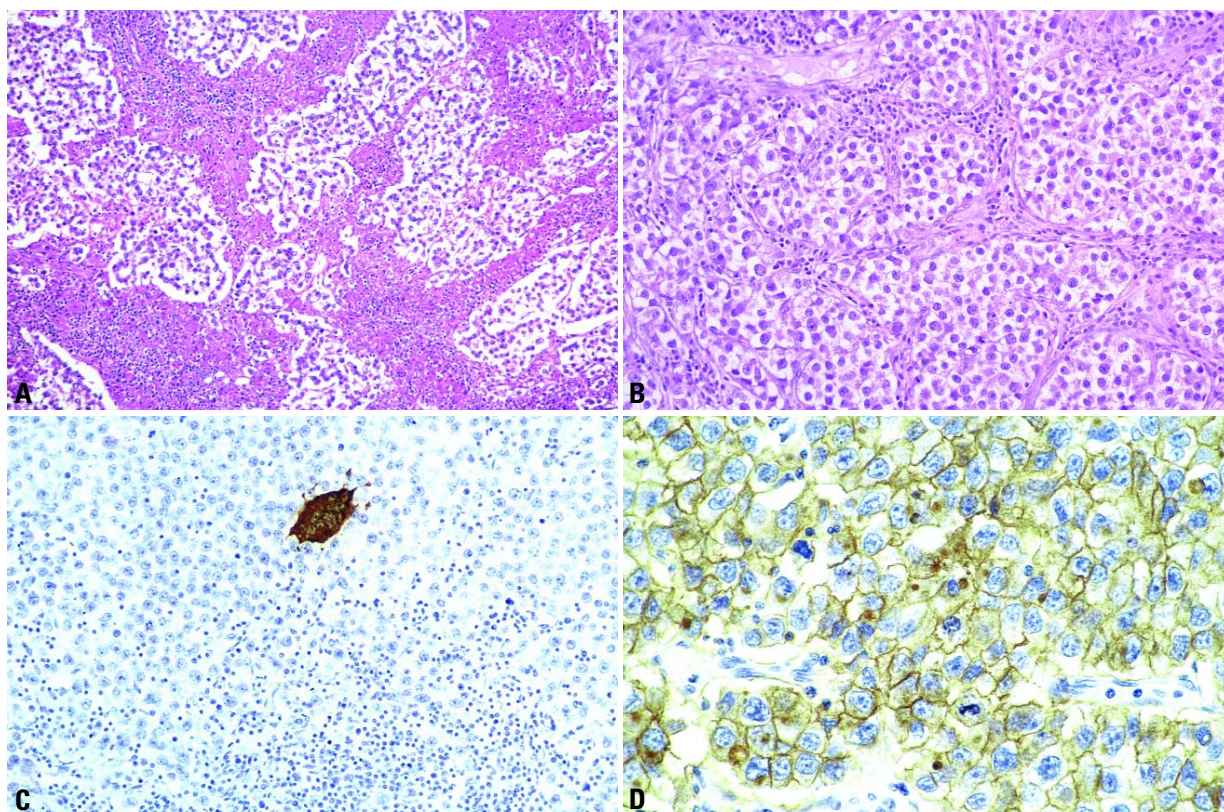


Fig. 2.88 Dysgerminoma. **A** This tumour has thick septa with an extensive chronic inflammatory reaction of granulomatous type. **B** Aggregates of tumour cells are separated by fibrous tissue septa infiltrated by lymphocytes. **C** Occasional beta-human chorionic gonadotropin-positive syncytiotrophoblasts occur. **D** The tumour cells show membranous staining for placental-like alkaline phosphatase.

ulative necrosis may be present and may be associated with cystic change or macroscopic calcification. However, the presence of minute, sandy calcifications should point towards the presence of a concomitant gonadoblastoma. Focal haemorrhagic areas may be indicative of the presence of other germ cell components, possibly containing trophoblastic tissue.

Histopathology

The proliferating germ cells have a monotonous appearance with a polygonal shape, abundant pale cytoplasm and fairly uniform nuclei. They aggregate in cords and clumps, although sometimes the lack of cohesion between cells may lead to the formation of pseudoglandular spaces. Although the stroma is usually reduced to thin perivascular sheaths, occasionally it can be abundant. It always contains variable amounts of chronic inflammatory infiltrate, mainly

composed of T lymphocytes [700] and macrophages. In fact, epithelioid granulomas are a prominent feature in a quarter of cases. Inflammation can also be present in the metastases. The mitotic rate is variable, and some tumours show anisokaryosis. Differentiation in the form of syncytiotrophoblastic cells is found in 5% of cases [3246]. In these cases, beta-human chorionic gonadotropin (β -hCG)-secreting syncytiotrophoblast originates directly from dysgerminoma cells without intervening cytotrophoblast.

Immunoprofile

Most dysgerminomas show positivity for vimentin and placental-like alkaline phosphatase (PLAP) [1660,2011], the latter is usually found in a membranous location. An inconstant and heterogeneous cytoplasmic positivity can be found to cytoskeletal proteins such as cytokeratins (rarely), desmin, glial fibrillary acidic protein, as well as to S-100

protein and carcinoembryonic antigen (CEA). C-kit gene product (CD117) is present in dysgerminoma as it is in seminoma [2965], further supporting the similarity to its testicular counterpart.

Precursor lesions

There is no known precursor lesion for the vast majority of dysgerminomas, except for those arising from gonadoblastoma.

Histogenesis

Some dysgerminomas may subsequently be the precursors of other primitive germ cells neoplasms such as yolk sac tumour [2185].

Prognosis and predictive factors

Dysgerminomas respond to chemotherapy or radiotherapy. The clinical stage of the tumour is probably the only significant prognostic factor [2605]. The presence of a high mitotic index and, in some

cases, anisokaryosis has no prognostic implication. The behaviour of dysgerminoma with trophoblastic differentiation is identical to the usual type, but with the advantage of having β -hCG as a serum marker.

Yolk sac tumour

Definition

Yolk sac tumours are morphologically heterogeneous, primitive teratoid neoplasms differentiating into multiple endodermal structures, ranging from the primitive gut to its derivatives of extraembryonal (secondary yolk sac vesicle) and embryonal somatic type, e.g. intestine, liver [2035]. These neoplasms have many epithelial patterns and are typically immunoreactive for alpha-fetoprotein.

Synonym and historical annotation

Since the secondary yolk sac component represents only one of its many lines of differentiation, the current nomenclature is clearly restrictive. Perhaps the term "endodermal primitive tumours" would be more accurate in defining all the possible lines of differentiation, both epithelial and mesenchymal, that occur in these neoplasms.

The term "endodermal sinus tumour", although still in use, is misleading, since the endodermal sinus is neither a structure present in human embryogenesis [1463] nor is it a constant feature of these neoplasms, as it only occurs in a minority of cases [1537].

Macroscopy

These tumours are usually well encapsulated with an average diameter of 15 cm [1537]. The sectioned tumour surface is soft and grey-yellow with frequent areas

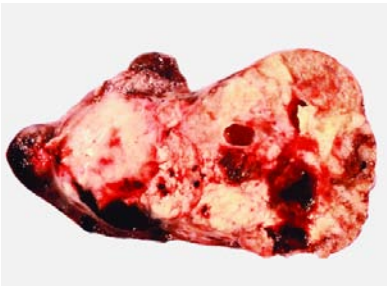

Fig. 2.89 Yolk sac tumour. Sectioned surface is predominantly solid and fleshy with areas of haemorrhage, necrosis and cyst formation.

Table 2.05
Morphological patterns of yolk sac tumours with their equivalent types of tissue differentiation.

Site differentiated	Tissue differentiated	Histological pattern
Extraembryonal endoderm	Primitive endoderm and secondary yolk sac	Reticular Solid Endodermal sinus
	Allantois	Polyvesicular
	Murine-type (?) parietal yolk sac	Parietal
Somatic endoderm	Primitive intestine and lung (?)	Glandular
	Early liver	Hepatic

of necrosis, haemorrhage and liquefaction. Cysts can be found in the periphery forming a honeycomb appearance [2043]; rarely, they can be unicystic [522]. A relatively frequent finding is the presence of a benign cystic teratoma in the contralateral ovary [3033].

Histopathology

Although a marked histological heterogeneity due to numerous patterns of differentiation coexisting in the same neoplasm may occur, almost invariably characteristic areas are present that allow for the correct diagnosis.

The characteristic reticular pattern formed by a loose, basophilic, myxoid stroma harbouring a meshwork of microcystic, labyrinthine spaces lined by clear or flattened epithelial cells with various degrees of atypia and cytoplasmic PAS-positive, diastase-resistant hyaline globules permits tumour identification. Irregular but constant amounts of hyaline, amorphous basement membrane material are found in relation to the epithelial cells. Both hyaline globules and the coarse aggregates of basement membrane material [2032,2979] are good histological indicators for tumour identity. Less frequently, in 13-20% of cases, papillary fibrovascular projections lined by epithelium (Schiller-Duval bodies) are found that bear a resemblance to the structures of the choriovitelline placenta of the rat, a fact that permitted the establishment of the teratoid, endodermal identity of these tumours [2896].

Histological variants

Less common histological variants include the polyvesicular vitelline tumour, solid yolk sac tumour, parietal yolk sac

tumour, glandular types of yolk sac tumour and hepatoid yolk sac tumour.

In the polyvesicular vitelline tumour cystic, organoid change of the epithelial spaces occurs that consists of multiple dilatations lined by mesothelial-like cells that coexist with a columnar, PAS-positive epithelium [2043].

The solid yolk sac tumour shows areas of solid epithelial sheets of cells with a characteristic abundant clear cytoplasm and numerous hyaline globules. These areas may resemble anaplastic changes of dysgerminoma or even clear cell tumours [1537] but have the distinctive immunophenotype of a yolk sac tumour.

Although exceptionally rare, parietal-type yolk sac tumours that are AFP-negative have been described [598,620]. They are analogous to the experimental murine tumour of the same name and can be identified by the massive deposition of amorphous extracellular basement membrane, a material similar to the Reichert membrane of the murine parietal yolk sac.

Differentiation into organized somatic endodermal derivatives such as endodermal type gland-like structures resembling early lung and intestine as well as liver tissue can occur in a focal fashion in as many as a third of tumours [1968, 2515,2979]. In rare instances these differentiated tissues may become the predominant elements in the tumour. Extensive differentiation of endodermal type glands characterizes the glandular variants of yolk sac tumours, which may adopt different morphological subtypes. From an embryological viewpoint the more immature type is represented by numerous dilated angular glands or papillae lined by an eosinophilic columnar

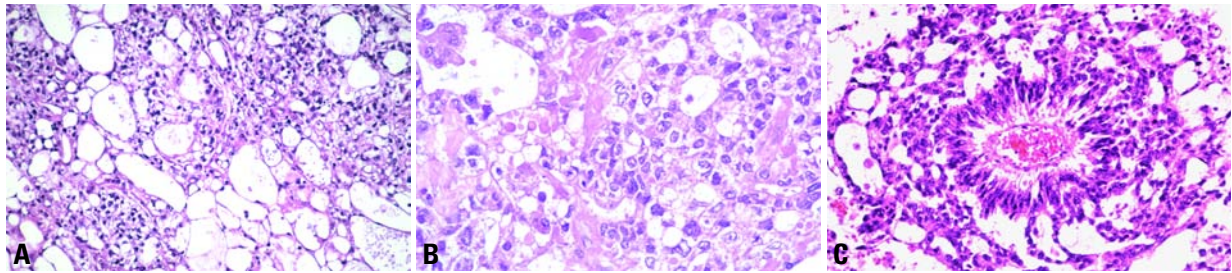


Fig. 2.90 Yolk sac tumour. **A** The reticular pattern is characterized by a loose meshwork of communicating spaces. **B** Hyaline globules and amorphous basement membrane material are present. **C** An endodermal or Schiller-Duval sinus is characteristic.

nar epithelium and surrounded by an oedematous, mesoblastic-type stroma that exhibits the characteristic appearance of early endoderm in both early differentiated intestine and the pseudoglandular phase of the embryonal lung [2038]. Indeed, similar tumours are reported in the lung itself [1968]. This gland-like aspect coupled with the presence of subnuclear vacuolization in the columnar lining mimics early secretory endometrium and endometrioid carcinoma of the ovary and, thus, was named the "endometrioid" variant [522]. Some endometrioid yolk sac tumours are highly differentiated and difficult to distinguish from grade 1 endometrioid carcinoma. Another type of glandular yolk sac tumour is composed of typical small crib-

riform glands resembling early intestinal differentiation. This type has been termed the intestinal-type of yolk sac tumour [533]. Extensive differentiation into hepatic tissue is another form of somatic differentiation [2515]. In some yolk sac tumours extensive solid nodular areas of liver tissue can be found [2284] and can be so well formed that they reproduce their laminar structure complete with sinusoids and even haematopoiesis. Finally, since any immature teratoid tissue is considered to be capable of undergoing fully accomplished differentiation, it is possible that pure endodermal immature teratoma composed solely of AFP-secreting endodermal glands and mesenchyme may be closely related to yolk

sac tumours [2042]. Predominance of mesenchymal, rather than epithelial, elements with differentiation into other components such as cartilage, bone or muscle may occur as a postchemotherapeutic conversion and be responsible for the occurrence of associated sarcomas in some cases [1854]. The haematopoietic capacity of the normal secondary yolk sac may have its neoplastic counterpart in yolk sac tumours, where isolated cases of haematological disorders have been reported associated with ovarian yolk sac tumours [1782] in a similar way to those occurring in extragonadal germ cell tumours.

Immunoprofile

AFP is the characteristic marker of the epithelial component of yolk sac tumours, although it is not exclusive to them, as it can also be found in some ovarian tumours that are not of germ cell type. AFP is found as a dense granular cytoplasmic deposit and is absent in hyaline globules, which are rarely immunoreactive. A host of other substances can be found in yolk sac tumours recapitulating the complex functions of early endoderm, including those involved in haematopoiesis [1158,2011]. The usual positivity for cytokeratins may differentiate solid yolk sac tumour from dysgerminoma. CD30 is usually positive in embryonal carcinoma [736] but is only focally positive in yolk sac tumour. Leu M1, which is positive in clear cell carcinoma, is negative in yolk sac tumour. The absence of estrogen and progesterone receptors in yolk sac tumour differentiates areas of yolk sac epithelium from associated areas of true endometrioid tumour [533].

Prognosis and predictive factors

Because numerous patterns of differenti-

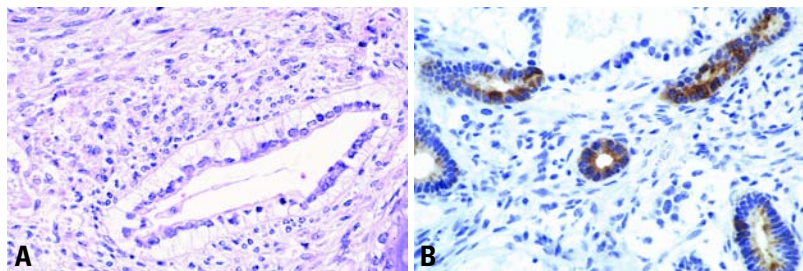


Fig. 2.91 Yolk sac tumour, glandular pattern. **A** Its glands show subnuclear vacuolization characteristic of early differentiated endoderm. **B** Marked cytoplasmic positivity for alpha-fetoprotein is seen in glandular areas.

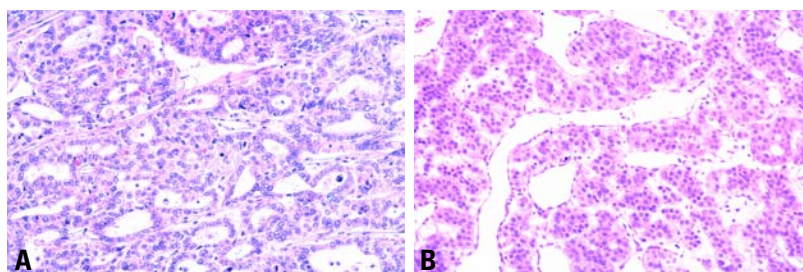


Fig. 2.92 **A** Yolk sac tumour, intestinal type. Note the cribriform pattern. **B** Yolk sac tumour with hepatic differentiation. The tumour is characterized by liver cell trabeculae and sinusoids.

ation may coexist in the same neoplasm, their behaviour, with some exceptions {1500}, is not conditioned by specific tumour morphology but shows a generally favourable response to chemotherapy. Although the histological appearance bears little prognostic implications, mature or well differentiated glandular forms may have an indolent course even when treated by surgery alone {1500, 2284}.

Embryonal carcinoma and polyembryoma

Definition

Embryonal carcinoma is a tumour composed of epithelial cells resembling those of the embryonic disc and growing in one or more of several patterns, glandular, tubular, papillary and solid. Polyembryoma is a rare tumour composed predominantly of embryoid bodies resembling early embryos.

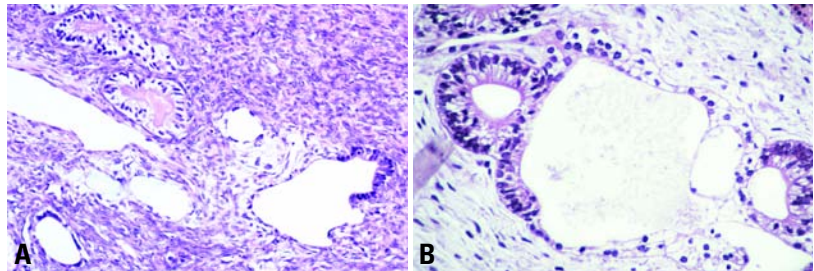


Fig. 2.93 **A** Yolk sac tumour. Note the polyvesicular vitelline area with biphasic lining. **B** Allantoic remnants from an aborted embryo. The allantoic remnants from an aborted embryo are identical to the polyvesicular vitelline structure shown in A.

Epidemiology

These rare tumours are the ovarian counterparts of their more frequent testicular homologues. Many are reported as a component of mixed germ cell tumours that originate from gonadoblastoma (see section on mixed germ cell-sex cord stromal tumours), arising in Y-chromosome containing dysgenetic gonads (and thus are technically "testicular"

tumours) or even in 46 XX gonads {3253}. They are multipotent stem cell tumours reproducing the primitive stages of embryonal differentiation.

Clinical features

Clinically, -hCG stimulation may determine various hormonal manifestations such as precocious pseudopuberty in premenarchal girls and vaginal bleeding in adult women {1536}.

Histopathology

Histologically, embryonal carcinoma reveals disorganized sheets of large primitive AFP and CD30-positive cells {736,1536}, forming papillae or crevices which coexist with -hCG positive syncytiotrophoblasts as well as early teratoid differentiation such as squamous, columnar, mucinous or ciliated epithelia. Its even more infrequent organoid variant is called polyembryoma due to a structural organization into blastocyst-like formations that resemble early presomatic embryos. These so-called embryoid bodies show embryonic disks with corresponding amniotic or primary yolk sac cavities and are surrounded by a mesoblast-like loose connective tissue. The surrounding tissues can differentiate into endodermal structures such as intestine or liver {2287} and trophoblast. However close the resemblance to normal early structures, the sequences of early embryonal development are not reproduced {1969}.

Non-gestational choriocarcinoma

Definition

A rare germ cell tumour composed of cytotrophoblast, syncytiotrophoblast and extravillous trophoblast.

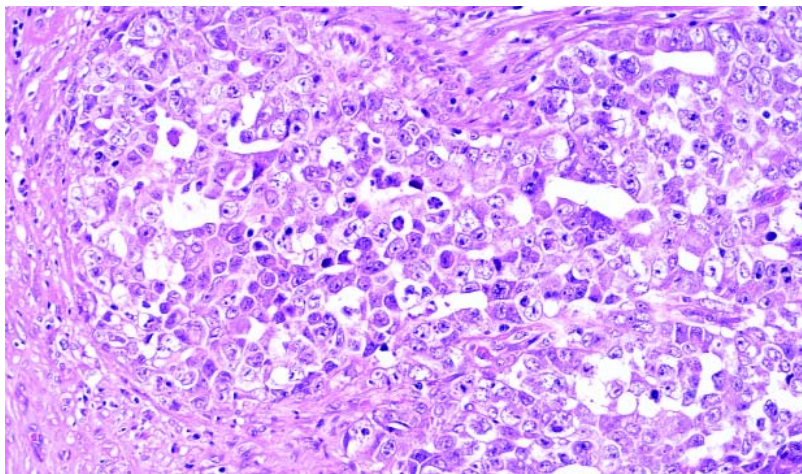


Fig. 2.94 Embryonal carcinoma. Cells with primitive-appearing nuclei form solid aggregates and line irregular gland-like spaces.

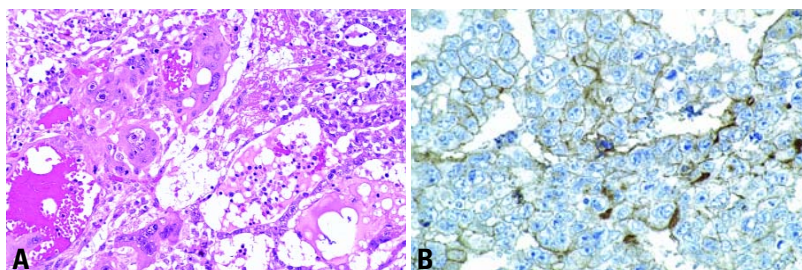


Fig. 2.95 Embryonal carcinoma. **A** Numerous syncytiotrophoblastic giant cells are typical. **B** The tumour cells show membranous staining for placental-like alkaline phosphatase.

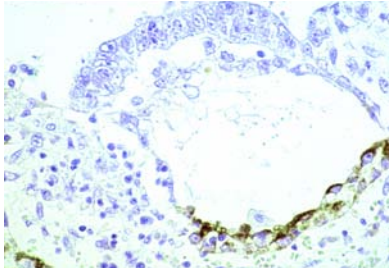


Fig. 2.96 Embryoid body in polyembryoma. Note the blastocyst-like formation consisting of an embryonic disc that is continuous with a primitive yolk sac cavity exhibiting alpha-fetoprotein secretion in its distal portion.

Clinical features

Clinically, hormonal manifestations such as precocious pseudopuberty and vaginal bleeding are present in children and young adults.

Macroscopy

Macroscopically, tumours are large and haemorrhagic, and large luteinized nodules or cysts due to β -hCG stimulation may appear in the uninvolved ovarian tissue.

Histopathology

Morphologically identical to gestational choriocarcinoma, primary non-gestational choriocarcinoma is rare in pure form, differentiates as an admixture of cytotrophoblast, syncytiotrophoblast and extravillous trophoblast and is usually found associated with other germ cell components [2704]. Histologically, there are fenestrated or plexiform sheets or

pseudopapillae of cytotrophoblast and extravillous trophoblast admixed with numerous syncytiotrophoblasts. Tumour can be found in blood-filled spaces and sinusoids. Vascular invasion is frequent. The immunophenotype is characteristic for each type of proliferating trophoblastic cell [1759] and includes cytokeratins, human placental lactogen and, above all, β -hCG.

Differential diagnosis

When found in a pure form in childbearing age, gestational choriocarcinoma, either primary in the ovary [3024] or metastatic [718] must be excluded. This may be accomplished by identifying paternal sequences by DNA analysis [1698,2655].

Prognosis and predictive factors

The distinction from gestational choriocarcinoma is important since non-gestational choriocarcinoma has a less favourable prognosis and requires more aggressive chemotherapeutic treatment regimens.

Mixed germ cell tumours

Definition

Mixed germ cell tumours are composed of at least two different germ cell elements of which at least one is primitive.

Clinical features

The value of tumour markers such as β -hCG and AFP in the diagnosis and follow-up of patients with mixed germ cell tumours containing elements of chorio-

carcinoma or yolk sac tumour has been proven over the years [2850]. Elevated serum levels of these markers should prompt a search for different components with extensive sampling of the tumour.

Histopathology

Histologically, the most common combination of neoplastic germ cell elements found in ovarian mixed germ cell tumours is dysgerminoma and yolk sac tumour [2850]. Additional neoplastic germ cell elements, including immature or mature teratoma, embryonal carcinoma, polyembryoma and/or choriocarcinoma, may also be present. All components of a mixed germ cell tumour and their approximate proportions should be mentioned in the diagnosis.

Most ovarian embryonal carcinomas are really malignant mixed germ cell tumours, usually admixed with yolk sac tumour and showing a large or predominant component of embryonal carcinoma [2850]. Although polyembryoma may have been the predominant malignant germ cell element within the tumour, a careful review of all the published cases of ovarian polyembryoma shows that other germ cell elements were also present [2850]. Also, ovarian choriocarcinoma of germ cell origin is in the majority of cases combined with other neoplastic germ cell elements. Immunohistochemical demonstration of β -hCG and AFP is a useful diagnostic modality in this group of tumours, as is the demonstration of PLAP in a component of dysgerminoma

Prognosis and predictive factors

All elements in a malignant mixed germ cell tumour are capable of widespread metastatic dissemination. The metastases may be composed of a single neoplastic germ cell element or of various elements.

Although these tumours are highly responsive to platinum-based chemotherapy, the therapeutic regimens should be based primarily on the most malignant elements of the tumour [2850].

Biphasic or triphasic teratomas

Definition

Tumours composed of derivatives of two or three primary germ layers (ectoderm, mesoderm, endoderm).

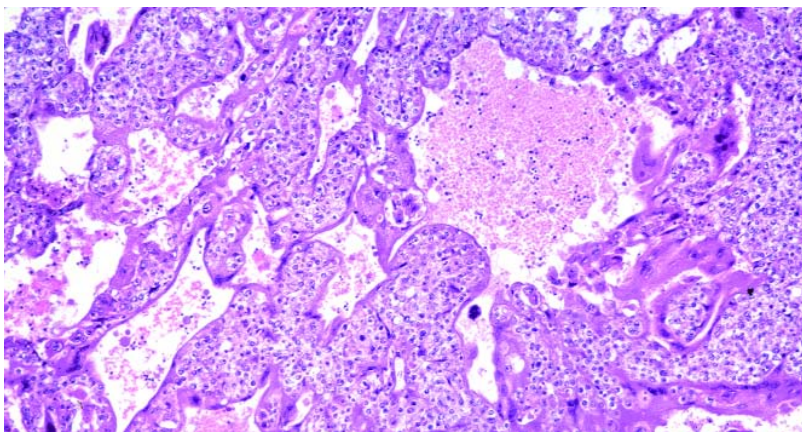


Fig. 2.97 Ovarian choriocarcinoma. A plexiform pattern is present with syncytiotrophoblasts covering clusters of smaller cytotrophoblasts.

Table 2.06
Grading of ovarian immature teratomas.

Three-tiered grading system {2060}
Grade 1 Tumours with rare foci of immature neuroepithelial tissue that occupy less than one low power field (40x) in any slide.
Grade 2 Tumours with similar elements, occupying 1 to 3 low power fields (40x) in any slide.
Grade 3 Tumours with large amount of immature neuroepithelial tissue occupying more than 3 low power fields (40x) in any slide.

Table 2.07
Management of immature teratomas according to grade of primary tumours and/or implants.

Three-tiered grading {2060}	Two-tiered grading {2072}	Stage	Combination chemotherapy
Grade 1 ovarian tumour	Low grade	Ia	Not required
Grade 2 or 3 ovarian tumour	High grade	Ia	Required
Grade 2 or 3 implants	High grade	II	Required
Grade 0 implants* regardless of ovarian tumour grade		II	Not required
* Those extraovarian implants that are composed of mature tissue, essentially glia.			

ICD-O codes	
Immature teratoma	9080/3
Mature teratoma	9080/0
Cystic teratoma	9080/0
Dermoid cyst	9084/0

Immature teratoma

Definition
A teratoma containing a variable amount of immature, embryonal-type (generally immature neuroectodermal) tissue.

Epidemiology
Immature teratoma represents 3% of teratomas, 1% of all ovarian cancers and 20% of malignant ovarian germ cell tumours and is found either in pure form or as a component of a mixed germ cell tumour [989]. It occurs essentially during the two first decade of life (from 1-46 years; average 18) [989,1174,2060].

Macroscopy
Immature teratoma is typically unilateral, large, variegated (6-35 cm; average, 18.5), predominantly solid, fleshy, and grey-tan and may be cystic with haemorrhage and necrosis [989,2060].

Histopathology
Immature teratoma is composed of variable amounts of immature embryonal-type tissues, mostly in the form of neuroectodermal rosettes and tubules, admixed with mature tissue. Neuroepithelial rosettes are lined by crowded basophilic cells with numerous mitoses [2060] and may be pigmented. Immature mesenchyme in the form of loose, myxoid stroma with focal differentiation into immature cartilage, fat, osteoid and rhabdomyoblasts is often present as well [2060]. Immature endodermal structures including hepatic tissue, intestinal-type epithelium with basal

vacuolization and embryonic renal tissue resembling Wilms tumour are encountered less frequently. Immature vascular structures may occur and are sometimes prominent.

Grading
Based on the quantity of the immature neuroepithelial component, primary and metastatic ovarian immature teratomas (including peritoneal implants and lymph nodes metastases) are separately graded from 1 to 3 [2060]. More recently the possibility of using a two-tiered (low grade and high grade) grading system was suggested [2072]. Adequate sampling of the primary tumour (one block per 1 or 2 cm of tumour) and of all resected implants is crucial, as the tumour grade may vary in different implants.

Somatic genetics
Immature teratomas grades 1-2 are

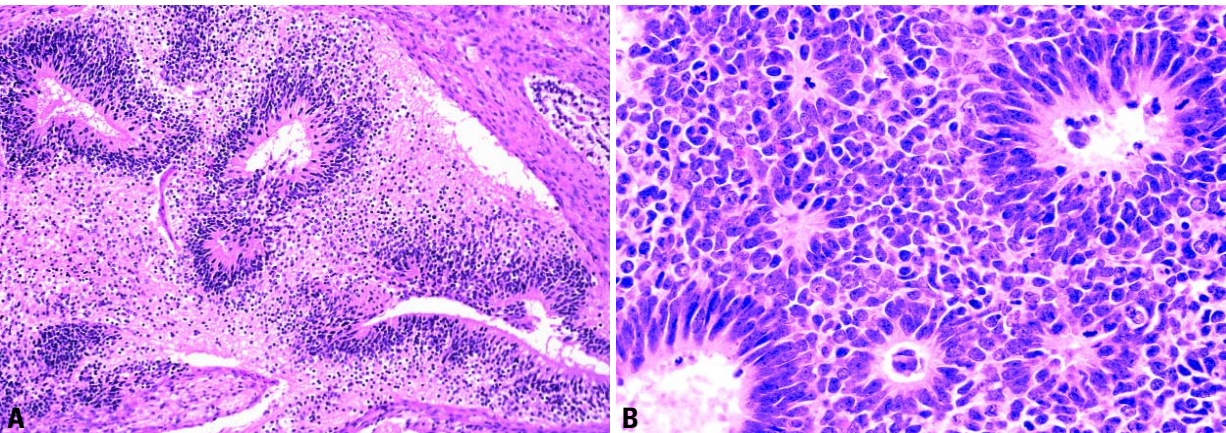


Fig. 2.98 A Immature teratoma, high grade. Neuroectodermal rosettes lie in a background of glial tissue. **B** Mitotic figures are evident within the immature neuroectodermal tissue.

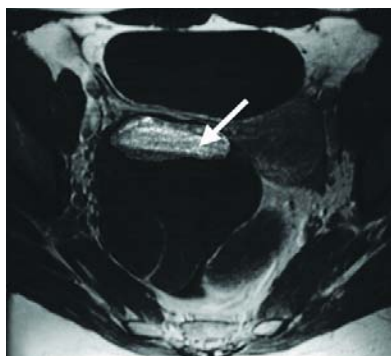


Fig. 2.99 Mature cystic teratoma. T1-weighted pre-contrast magnetic resonance image. A fat-fluid level is seen (arrow).

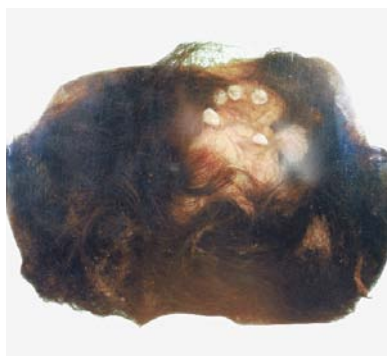


Fig. 2.100 Mature cystic teratoma with dark hair. The Rokitsansky protuberance is composed of fatty tissue, bone, and teeth protruding into the lumen.

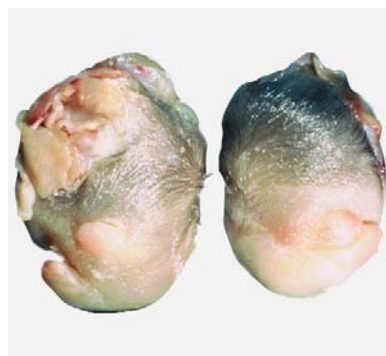


Fig. 2.101 Fetiform teratoma (homunculus). Limb buds are apparent, and there is abundant hair over the cephalic portion.

diploid in 90% of cases, whereas most (66%) of grade 3 tumours are aneuploid [165,2684]. Similarly, karyotypic abnormalities are most often seen in grade 3 tumours [165]. Immature teratomas show fewer DNA copy number changes detected by comparative genomic hybridization than other ovarian germ cell tumours and do not usually exhibit a gain of 12p or i(12p) [1518,2378].

Prognosis and predictive factors

The stage and grade of the primary tumour and the grade of its metastases are important predictive factors. Prior to the chemotherapy era, the overall survival rate of patients with grade 1, 2 and 3 neoplasms was 82%, 63% and 30%, respectively [2060].

The use of cisplatin-based combination chemotherapy has dramatically improved the survival rate of patients; 90-100% of those receiving this regimen remain disease-free [989].

The tumour grade is a crucial feature that determines behaviour and type of therapy. Patients with grade 1 tumours that are stage IA and those with mature (grade 0) implants do not require adjuvant chemotherapy. Those with grade 2 or 3 tumours, including stage IA, as well as those with immature implants require combination chemotherapy. The management of patients with grade 1 implants/metastases is not well established.

A recent report from the Pediatric Oncology Group concludes that surgery alone is curative in children and adolescents with immature teratoma of any grade, reserving chemotherapy for

cases with relapse [600]. Also, in immature teratomas occurring in childhood, the presence of histological foci of yolk sac tumour rather than the grade of the immature component, per se, is the only predictor of recurrence [1174].

Mature teratoma

Definition

A cystic or, more rarely, a solid tumour composed exclusively of mature, adult-type tissues. A cyst lined by mature tissue resembling the epidermis with its appendages is clinically designated as "dermoid cyst". Homunculus or fetiform teratoma is a rare type of mature, solid teratoma containing highly organized structures resembling a malformed fetus ("homunculus" = little man).

Epidemiology

Age

Although most mature cystic teratomas occur during the reproductive years, they have a wide age distribution, from 2-80 years (mean, 32), and 5% occur in post-menopausal women [564]. Mature solid teratoma occurs mainly in the first two decades of life [199,2922].

Incidence

Mature cystic teratoma accounts for 27-44% of all ovarian tumours and up to 58% of the benign tumours [1502]. In addition to their pure form, dermoid cysts are found macroscopically within 25% of immature teratomas and in the ovary contralateral to a malignant primitive germ cell tumour in 10-15% of the cases.

Clinical features

Signs and symptoms

Most mature cystic teratomas present with a mass, but at least 25% (up to 60% in some series) are discovered incidentally [546]. Symptoms such as a pelvic mass or pain are more common when the mature teratoma is solid [199,2922].

The following complications have been described:

(1) Torsion of the pedicle occurs in 10-16% of the cases, is responsible for acute abdominal pain and may be complicated by infarction, perforation or intra-abdominal haemorrhage.

(2) Tumour rupture occurs in 1% of cases and can be spontaneous or traumatic. The spillage of the cyst contents into the peritoneum produces chemical peritonitis with granulomatous nodules mimicking tuberculosis or carcinomatosis. Rupture of mature teratoma containing neuroglial elements is thought to be responsible for gliomatosis peritonei characterized by peritoneal "implants" composed of mature glial tissue and does not affect the prognosis [2389]. However, a recent molecular study has demonstrated that these glial implants were heterozygous, whereas the associated mature ovarian teratomas were homozygous at the same microsatellite loci. This finding suggests that glial implants may arise from metaplasia of pluripotent müllerian stem cells rather than from implantation of the associated ovarian teratomas [845]. Similarly, peritoneal melanosis characterized by pigmentation of the peritoneum has been reported in cases of dermoid cysts.

(3) Infection of the tumour occurs in 1% of cases.

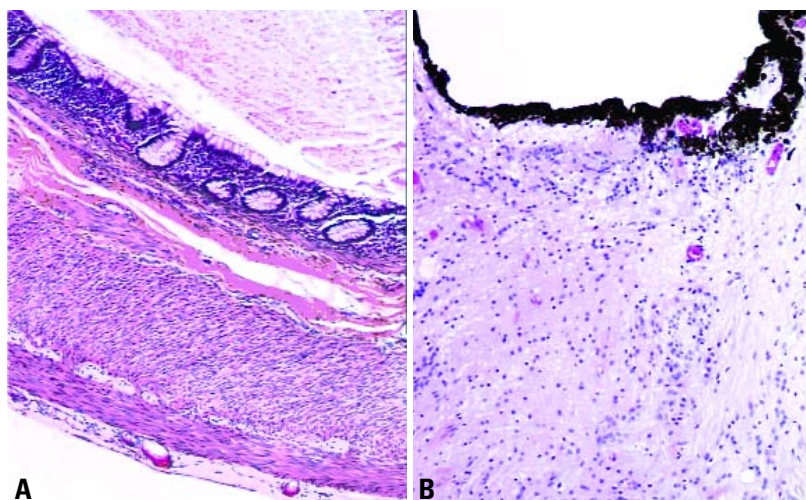


Fig. 2.102 **A** Mature cystic teratoma. Adult-type tissues such as intestine tend to have an organoid arrangement with two layers of smooth muscle beneath glandular mucosa. **B** Note the pigmented retinal epithelium and associated mature glial tissue.

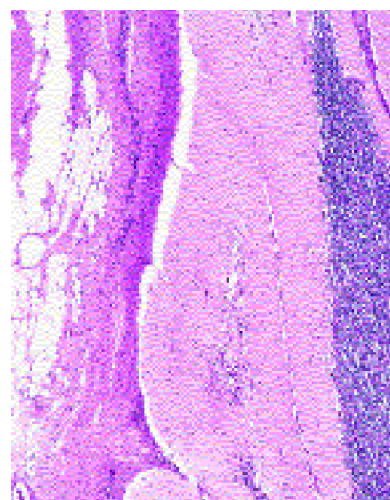


Fig. 2.103 Mature teratoma. Note the cerebellar structures adjacent to adipose and fibrous connective tissue.

(4) Haemolytic anaemia has been reported in rare cases [1020].

Macroscopy

Dermoid cyst is an ovoid, occasionally bilateral (8-15% of cases), cystic mass of 0.5-40 cm (average 15 cm) with a smooth external surface and is filled with sebaceous material and hair. A nodule composed of fat tissue with teeth or bone protrudes into the cyst and is termed a Rokitansky protuberance.

Mature solid teratoma is a large, solid mass with multiple cysts of varying size, a soft, cerebroid appearance and small foci of haemorrhage.

Histopathology

Mature teratomas are composed of adult-type tissue derived from two or three embryonic layers. Benign tumours such as struma ovarii, carcinoid, corticotroph cell adenoma, prolactinoma, naevus and glomus tumour may arise within a typical dermoid cyst [143, 1389,2162,2682].

Histogenesis

The presence of Barr bodies (nuclear sex chromatin) and a 46 XX karyotype is consistent with origin through parthenogenetic development. Selective tissue microdissection and genetic analysis of mature ovarian teratomas demonstrated a genotypic difference between homozygous teratomatous tissues and heterozy-

gous host tissue in support of their origin from a post-meiotic germ cell [1667, 3032]. Lymphoid aggregates associated with squamous or glandular epithelium within teratomas are heterozygous and derived from host tissue, whereas well differentiated thymic tissue is homozygous, suggesting capability for lymphoid differentiation [3032].

Although multiple teratomas in the same ovary originate independently from different progenitor germ cells, they may appear histologically similar indicating the role of possible local and environmental factors in phenotypic differentiation of ovarian germ cell tumours [683].

Prognosis and predictive factors

Dermoid cysts with histological foci (up to 21 mm²) of immature neuroepithelial tissue have an excellent prognosis [3174]. Recurrence in the form of a dermoid cyst (3% of cases) or immature teratoma (2-2.6% of cases) in the residual ipsilateral ovary is most frequent when the initial cysts are bilateral or multiple and have ruptured [104,3174].

Monodermal teratomas and somatic-type tumours associated with dermoid cysts

Definition

Teratomas composed exclusively or predominantly of a single type of tissue

derived from one embryonic layer (ectoderm or endoderm) and adult-type tumours derived from a dermoid cyst.

ICD-O codes

Struma ovarii	9090/0
Carcinoid	8240/3
Mucinous carcinoid	8243/3
Strumal carcinoid	9091/1
Ependymoma	9391/3
Primitive neuroectodermal tumour	9473/3
Glioblastoma multiforme	9440/3
Teratoma with malignant transformation	9084/3
Malignant melanoma	8720/3
Melanocytic naevus	8720/0
Sebaceous adenoma	8410/0
Sebaceous carcinoma	8410/3
Retinal anlage tumour	9363/0

Struma ovarii

Definition

A mature teratoma composed either exclusively or predominantly of thyroid tissue. Struma ovarii may harbour changes histologically identical to thyroid adenoma, carcinoma (malignant struma ovarii) or both. Those admixed with a carcinoid (strumal carcinoid) are classified separately.

Epidemiology

Struma ovarii, the most common type of monodermal teratoma, accounts for 2.7% of all ovarian teratomas [3146] with

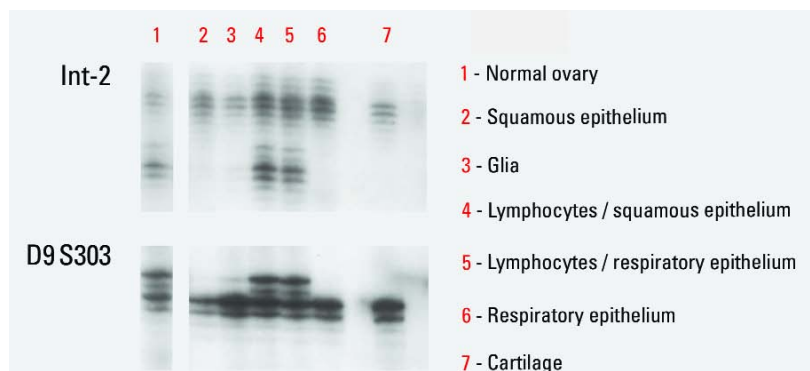


Fig. 2.104 Genetic analysis of various histological components selectively microdissected from a mature ovarian teratoma using microsatellite markers INT-2 (11q13) and D9S303 (9p). Teratomatous components are homozygous showing one allelic band, whereas lymphocytes associated with squamous and respiratory epithelium are heterozygous with both allelic bands, similar to host tissue (normal ovarian stroma).

malignant struma ovarii representing 0.01% of all ovarian tumours and 5-10% of all struma ovarii. Most patients are in their fifth decade [3146].

Clinical features

Signs and symptoms

Patients present with a palpable abdominal mass or unusual symptoms including Meigs syndrome [983], cervical thyroid hypertrophy and thyrotoxicosis (5% of cases) with high pelvic iodine uptake [2697]. An elevated serum level of thyroglobulin occurs in malignant struma ovarii [2412].

Macroscopy

The tumour is unilateral and varies from 0.5-10 cm in diameter. It has a brown solid and gelatinous sectioned surface and sometimes appears as a nodule within a dermoid cyst. Entirely cystic strumas containing green gelatinous material also occur [2831].

Histopathology

Struma ovarii is composed of normal or hyperplastic thyroid-type tissue with patterns seen in thyroid adenoma such as microfollicular, macrofollicular, trabecular and solid. Oxyphil or clear cells may be found [2832]. Cystic struma is composed of thin fibrous septa lined by flat, cuboidal cells with sparse typical thyroid follicles in the cyst wall [2831]. Immunoreactivity for thyroglobulin may be helpful in problematic cases such as cystic struma, oxyphilic or clear cell variants and a trabecular architecture that

might be indistinguishable from Sertoli-Leydig cell tumours. Criteria used for malignant changes within struma ovarii are the same as those used for a diagnosis of malignancy in the thyroid gland [677,2387]. Papillary carcinomas (85% of cases) display the characteristic ground glass nuclei. However, follicular

carcinomas are difficult to diagnose since struma ovarii generally lacks a capsule and has irregular margins. The thyroid tissue of struma may be uniformly malignant in some cases, undoubtedly arising in such cases from histological foci of normal-appearing thyroid tissue, which are not extensive enough in itself to qualify for the diagnosis of struma ovarii.

Prognosis and predictive factors

Tumours with the morphology of papillary or follicular thyroid cancer and extra-ovarian spread at presentation are probably the only lesions that deserve a designation of malignant struma, whilst the so-called "benign strumatosus", peritoneal implants composed of benign thyroid-type tissue, does not alter the prognosis. Factors increasing the likelihood of recurrences include the size, the presence of ascites or adhesions and solid architecture, whereas the mitotic rate and vascular invasion (identified in 15% of malignant strumas) are not prognostically helpful features [2387].

Carcinoids

Definition

These tumours contain extensive components of well differentiated neuroendocrine cells and most subtypes resemble carcinoids of the gastrointestinal tract. They may occur in pure form or within a dermoid cyst, a mucinous cystic tumour or a Brenner tumour. It should be distinguished from isolated neuroendocrine cells found within some mucinous and Sertoli-Leydig cell tumours.

Epidemiology

Ovarian carcinoids account for 0.5-1.7% of all carcinoids [2743], and the age range is 14-79 years (mean 53) [166, 2388,2390,2392].

Clinical features

Signs and symptoms

Carcinoid syndrome is a clinical sign of insular carcinoids in 30% of patients and is rare in trabecular (13%) and strumal (3.2%) carcinoids [631,2743]. Peptide YY production by the tumour cells causes severe constipation and pain with defecation in 25% of trabecular carcinoids [2656]. Strumal carcinoids may cause symptoms of functioning thyroid tissue in 8% of cases [2390].

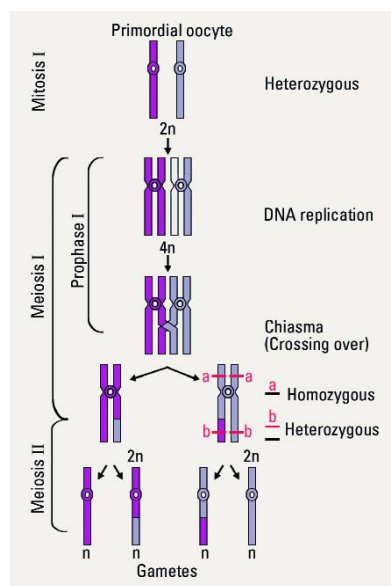


Fig. 2.105 Meiotic division. Primordial germ cells are heterozygous with all informative microsatellite markers. After the first meiotic division and crossing over between homologous chromatids, a homozygous genotype is demonstrated with microsatellite marker "a" while a heterozygous genotype is seen with microsatellite marker "b".

Diagnostic procedures

Elevated urine 5-hydroxyindoleacetic acid (5-HIAA) and serum serotonin levels are found in patients with carcinoid syndrome [631,2388].

Macroscopy

Primary ovarian carcinoids are unilateral and present as a firm tan nodule (less than 5 cm) protruding into a typical dermoid cyst (32-60% of tumours) or are predominantly solid with small cysts. The sectioned surface is firm, homogeneous and tan to yellow.

Histopathology

Insular carcinoid accounts for 26-53% of cases [631,2743] and resembles midgut derivative carcinoids. It is composed of nests of round cells with uniform nuclei and abundant eosinophilic cytoplasm enclosing small red argentaffin granules at the periphery of the nests. Acinus formation and a cribriform pattern with luminal eosinophilic secretion are present [2388].

Trabecular carcinoid accounts for 23-29% of cases [631,2743] and resembles hindgut or foregut derivative carcinoids. It exhibits wavy and anastomosing ribbons composed of columnar cells with the long axes of the cells parallel to one another and oblong nuclei with prominent nucleoli. The abundant cytoplasm is finely granular with red-orange argyrophilic granules at both poles of the nucleus [2392].

Mucinous carcinoid accounts for only 1.5% of cases [2743] and resembles goblet cell carcinoids arising in the appendix. The well differentiated mucinous carcinoid is composed of numerous small glands lined by columnar or cuboidal cells, some of which contain intracytoplasmic mucin or have a goblet cell appearance, whilst others disclose

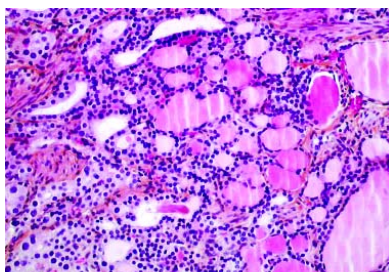


Fig. 2.106 Struma ovarii. The struma resembles a thyroid microfollicular adenoma with dystrophic nuclei.

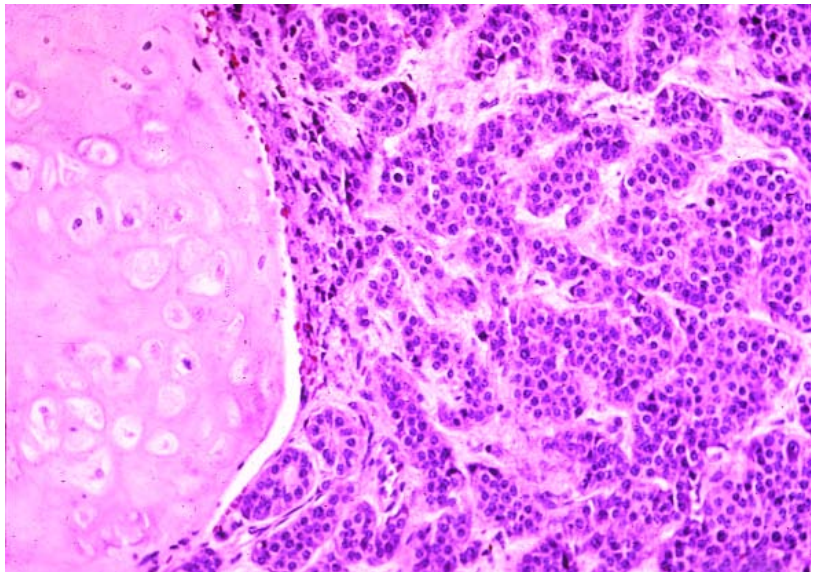


Fig. 2.107 Carcinoid arising in a teratoma. Nests and cords of carcinoid cells proliferate next to a choroid nodule.

orange-red neuroendocrine granules. Individual tumour cells may contain both mucin and neuroendocrine granules. Glands may be floating within pools of mucin that also dissect the surrounding fibrous stroma with isolated signet-ring cells infiltrating the stroma. Atypical mucinous carcinoid demonstrates crowded glands or a cribriform pattern. Carcinoma arising in mucinous carcinoid exhibits large islands of tumour cells or closely packed glands with high grade nuclei, numerous mitoses and necrosis [166].

Strumal carcinoid accounts for 26-44% of cases [631,2743] and is composed of a variable proportion of thyroid tissue and carcinoid, the latter mostly having a trabecular architecture. The neuroendocrine cells invade progressively the strumal component, replacing the follicular lining cells. Glands or cysts lined by columnar epithelium with goblet cells may be found [2390].

Carcinoids with mixed patterns (essentially insular and trabecular), are classified according to the pattern that predominates [2388].

Immunoprofile

Carcinoids are immunoreactive to at least one of the neuroendocrine markers (chromogranin, synaptophysin, Leu-7) and various peptide hormones such as pan-

creatic polypeptide, gastrin, vasoactive intestinal peptides and glucagon [166].

Differential diagnosis

Metastatic gastrointestinal carcinoid to the ovary should be ruled out specifically when extraovarian disease is detected. Bilateral and multinodular ovarian involvement, the absence of other teratomatous components and the persistence of the carcinoid syndrome after oophorectomy favour the diagnosis of metastasis [166,2391].

Prognosis and predictive features

Almost all primary trabecular and strumal carcinoids occur in women with stage I disease and have an excellent outcome. The overall survival of patients with insular carcinoid is 95% at 5 years and 88% at 10 years [2388].

Primary ovarian mucinous carcinoid, like those in the appendix, has a more aggressive behaviour with extraovarian spread and lymph node metastases. The presence of frank carcinoma within the tumour is an important prognostic factor [166].

Neuroectodermal tumours

Definition

Tumours composed almost exclusively of neuroectodermal tissue, closely resem-

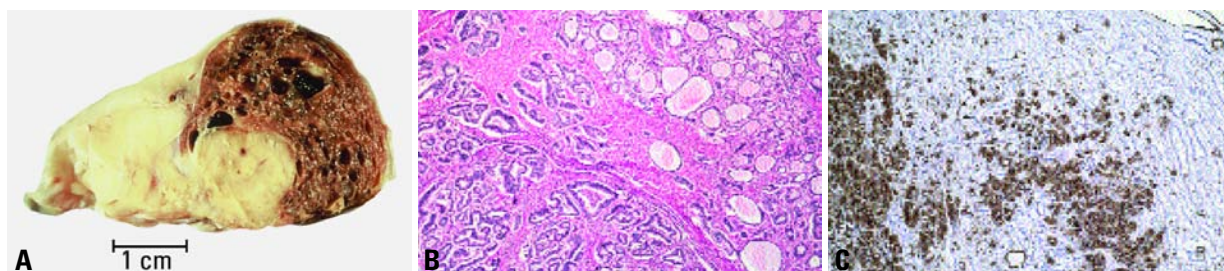


Fig. 2.108 Strumal carcinoid. **A** Sectioned surface of the ovarian tumour shows a spongy brown area reflecting the strumal component and a solid yellow region reflecting the carcinoid component. **B** The strumal and carcinoid tumour patterns are located side by side, with the struma on the right. **C** Immunoreactivity for cytokeratin 7 is present in the strumal elements but not in the carcinoid trabeculae.

bling neoplasms of the nervous system with a similar spectrum of differentiation.

Epidemiology

Less than 40 cases are reported in patients 6-69 years old (average 28), {1077,1418,1476}.

Clinical features

The tumours usually present as a pelvic mass.

Macroscopy

Tumours are unilateral and 4-20 cm in diameter, averaging 14 cm {1476}. The sectioned surface varies from solid with friable, gray-pink tissue to cystic with papillary excrescences in their inner or outer surface {1077}.

Tumour spread and staging

The majority of patients have stage II or III disease at laparotomy usually in the form of peritoneal implants {1476}.

Histopathology

These tumours are morphologically identical to their nervous system counterparts. They may be divided into three categories as follows:

- (1) Well differentiated forms such as ependymoma.
- (2) Poorly differentiated tumours such as primitive neuroectodermal tumour (PNET), and medulloepithelioma.
- (3) Anaplastic forms such as glioblastoma multiforme.

Whilst ependymomas are not found in association with teratoma, other neuroectodermal tumours in the ovary may be associated with elements of mature or immature teratoma {2605}. Cases previously reported as neuroblastoma or medulloblastoma would now most likely be classified as PNETs since the mor-

phology of all three tumours is similar with the term medulloblastoma being reserved for cerebellar and neuroblastoma for adrenal neoplasms {1474}. Medulloepithelioma, on the other hand, has a distinctive appearance characterized by papillary, tubular or trabecular arrangements of neoplastic neuroepithelium mimicking the embryonic neural tube {1474}.

Ependymomas and anaplastic tumours are immunoreactive for glial fibrillary acidic protein. The characteristic immunoprofile of PNETs, vimentin and MIC2 protein (CD99) positive and GFAP, cytokeratin, desmin, chromogranin, and inhibin negative, help to distinguish these tumours from small cell carcinoma and juvenile granulosa cell tumour.

Somatic genetics

Reverse transcription-polymerase chain reaction in a case of ovarian PNET led to the detection of *EWS/FLI1* chimeric transcript, originating from the characteristic t(11;22)(q24;q12) translocation of the PNET/Ewing tumour family {1418}.

Prognosis and predictive factors

Most patients with ovarian ependymomas survive despite multiple recurrences, whereas patients with PNET and anaplastic tumours have a poor outcome {1476}.

Carcinomas

Definition

A dermoid cyst in which a secondary carcinoma develops.

Epidemiology

Malignancy arising within a mature cystic teratoma is a rare complication (1-2% of cases), mostly reported in post-

menopausal women (mean 51-62 years) {1214,1429,2164}.

Clinical features

The tumour may present as a dermoid cyst or as an advanced ovarian cancer depending on tumour stage {2605}. The tumour may show adherence to surrounding pelvic structures {1214,1429,2164}.

Macroscopy

On macroscopic examination cauliflower exophytic growth, infiltrative grey-white plaques or thickenings of the cyst wall with necrosis and haemorrhage may be seen {1214,1429,2164}.

Histopathology

The malignancy may be detectable only after histological examination, thus dermoid cysts in postmenopausal women must be adequately sampled. Any component of a mature teratoma may undergo malignant transformation. Carcinomas are the most common malignancy, with squamous cell carcinomas accounting for 80% of cases and 51% of all primary ovarian squamous cell carcinomas {1214,2255}. Adenocarcinoma is the second most common malignancy arising in dermoid cysts {1456}. Adenocarcinoma of intestinal type {2970}, Paget disease, adenosquamous carcinoma, transitional cell carcinoma {1456}, undifferentiated carcinoma, small cell carcinoma, basal cell carcinoma and carcinosarcoma {123} have been described {2605}. The malignant component invades other parts of the dermoid cyst and its wall.

Somatic genetics

Selective tissue microdissection and genetic analyses of malignant tumours

associated with mature teratomas showed an identical homozygous genotype for the malignant component and the mature teratomatous tissues, thus demonstrating a direct pathogenetic relationship [683].

Prognosis and predictive features

The prognosis of squamous cell carcinoma is poor with a 15-52% overall 5-year survival and disease related death usually within 9 months. Vascular invasion is associated with a high mortality rate [1214]. Although relatively few cases have been reported, the prognosis of adenocarcinoma appears to be similar to that of squamous cell carcinoma [2970].

Sarcomas

Sarcomas account for 8% of cases of malignancies in dermoid cysts and are more often seen in younger patients than those with squamous cell carcinoma. Cases of leiomyosarcoma, angiosarcoma [2021], osteosarcoma [2006], chondrosarcoma, fibrosarcoma, rhabdomyosarcoma and malignant fibrous histiocytoma have been reported [2605].

Melanocytic tumours

Melanomas are rare, occurring much less commonly than metastatic melanoma [630]. Overall, one-half of the patients with stage I dermoid-associated melanoma are alive at 2 years [404]. Melanocytic naevi of various types may arise within a typical dermoid cyst [1544].

Sebaceous tumours

Sebaceous tumours are specialized neoplasms arising within an ovarian dermoid cyst that resemble various forms of cutaneous sebaceous gland tumours (sebaceous adenoma, basal cell carcinoma with sebaceous differentiation, sebaceous carcinoma). The hallmark of these lesions is the presence of large numbers of mature, foamy or bubbly sebaceous cells that stain positively with oil red O in a tumour arising within a dermoid cyst [491].

Pituitary-type tumours

Corticotroph cell adenoma and prolactinoma, respectively responsible for

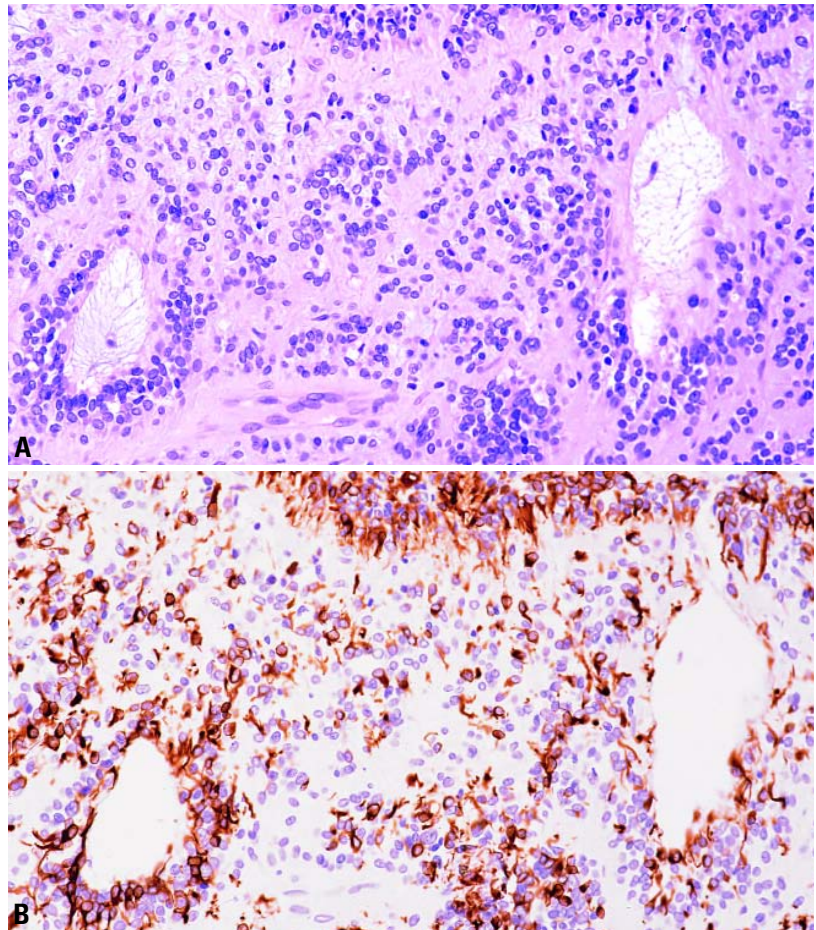


Fig. 2.109 Ependymoma of the ovary. **A** The tumour cells have uniform nuclei and form two rosettes. **B** Many tumour cells are strongly positive for glial fibrillary acidic protein with accentuated staining around the rosettes.

Cushing syndrome and hyperprolactinemia with amenorrhea, may arise within a typical dermoid cyst and have a benign clinical course [143,1389,2162].

Retinal anlage tumours

Pigmented progonoma and malignant tumours derived from retinal anlage within ovarian teratomas have macroscopically pigmented areas that correspond to solid nests, tubules and papillae composed of atypical cells with melanin-containing cytoplasm [1112,1466,2712].

Other monodermal teratomas and related tumours

Neural cyst of the ovary lined by a single layer of ependymal cells with white mat-

ter, astrocytes and reactive glia in the underlying wall corresponds to a monodermal teratoma with unidirectional neurogenic differentiation [894]. Similarly, endodermal variants of mature teratoma lined exclusively by respiratory epithelium [508] and ovarian epidermoid cysts [823] may fall into the category of monodermal teratoma.

Mucinous cystadenomas arising within mature teratomas have a homozygous teratomatous genotype, supporting their germ cell origin [1731]. Mesodermal derived tumours such as lipoma composed of mature adipocytes with scattered benign sweat glands may occur [961]. Glomus tumour may rarely arise within a typical dermoid cyst [2682].

Mixed germ cell-sex cord-stromal tumours

A. Talerman
P. Schwartz

This group of neoplasms is composed of a mixture of germ cell and sex cord-stromal elements. They have mainly benign clinical behaviour except in cases with a malignant germ cell component.

Gonadoblastoma

Definition

A neoplasm composed of tumour cells closely resembling dysgerminoma or seminoma, intimately admixed with sex cord derivatives resembling immature Sertoli or granulosa cells and in some cases containing stromal derivatives mimicking luteinized stromal or Leydig cells devoid of Reinke crystals.

ICD-O code

Gonadoblastoma 9073/1

Epidemiology

Gonadoblastomas typically are identified in children or young adults with one-third of the tumours being detected before the age of 15 [2598].

Aetiology

Gonadoblastomas are frequently associated with abnormalities in the secondary sex organs [2598,2847]. In over 90% of the cases of gonadoblastoma a Y chromosome was detected [2598,2605,2849,2850].

Localization

Gonadoblastoma is found more often in the right gonad than in the left and is bilateral in 38% of cases [2598]. Recent reports suggest an even higher frequency of bilateral involvement [2850].

Clinical features

Signs and symptoms

The usual patient with a gonadoblastoma is a phenotypic female who is frequently virilized [2605]. A minority may present as phenotypic males with varying degrees of feminization.

The clinical presentation of a patient with a gonadoblastoma can vary considerably depending upon whether or not a tumour mass is present, on the nature of

the underlying abnormal gonads, on the development of secondary sex organs and the occasional secretion of steroid hormones [2598]. A patient with pure gonadal dysgenesis may present with a failure to develop secondary sex organs and characteristics at puberty but has a normal height, and other congenital anomalies are absent. Those with Turner syndrome have sexual immaturity, a height of less than 150 cm and one or more congenital anomalies including neonatal lymphedema, web neck, prognathism, shield-shaped chest, widely spaced nipples, cubitus valgus, congenital nevi, coarctation of the aorta, renal anomalies, short fifth metacarpal bones and others [2598]. If a germ cell malignancy develops in the dysgenetic gonad, the patient may present with lower abdominal or pelvic pain.

Macroscopy

Pure gonadoblastoma varies from a histological lesion to 8 cm, and most tumours are small, measuring only a few cm [2598,2849,2850]. When a gonadoblastoma is overgrown by dysgerminoma or other neoplastic germ cell elements, much larger tumours are encountered. The macroscopic appearance of gonadoblastoma varies depending on the presence of hyalinization and calcification and on the overgrowth by other malignant germ cell elements.

Histopathology

Histologically, gonadoblastoma is a tumour composed of two main cell types, germ cells which are similar to those present in dysgerminoma or seminoma and sex cord derivatives resembling immature Sertoli or granulosa cells. The stroma in addition may contain collections of luteinized or Leydig-like cells devoid of Reinke crystals. The tumour is arranged in collections of cellular nests surrounded by connective tissue stroma. The nests are solid, usually small, oval or round, but occasionally may be larger or elongated. The cellular nests are composed of germ cells and sex cord deriv-

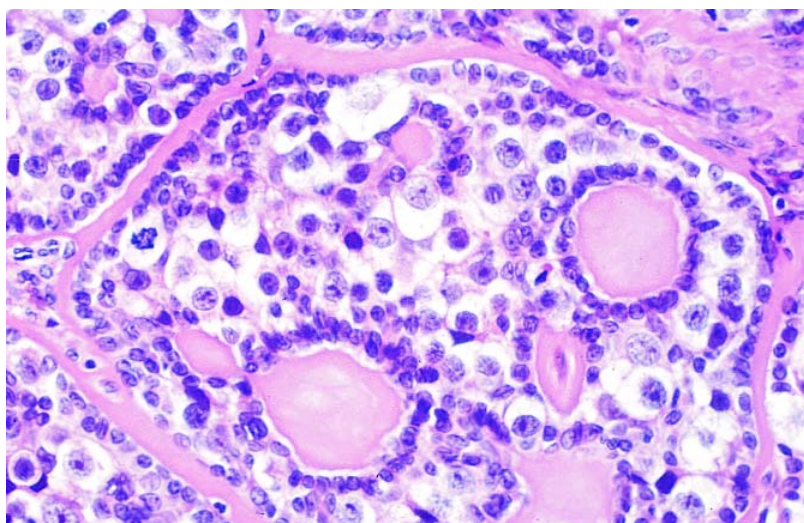


Fig. 2.110 Gonadoblastoma. The tumour consists of cellular nests(germ cells and sex cord derivatives) surrounded by connective tissue stroma. The sex cord derivatives form a coronal pattern along the periphery of the nests and also surround small round spaces containing hyaline material. A mixture of cells is present in the centre of the nests.

atives intimately admixed. The germ cells are large and round with clear or slightly granular cytoplasm and large, round, vesicular nuclei, often with prominent nucleoli, and show mitotic activity, which may be brisk. Their histological and ultrastructural appearance and histochemical reactions are similar to the germ cells of dysgerminoma or seminoma. The immature Sertoli or granulosa cells are smaller and epithelial-like. These cells are round or oval and contain dark, oval or slightly elongated carrot-shaped nuclei. They do not show mitotic activity [2598,2849,2850]. The sex cord derivatives are arranged within the cell nests in three typical patterns as follows:

- (1) Forming a coronal pattern along the periphery of the nests.
- (2) Surrounding individual or collections of germ cells.
- (3) Surrounding small round spaces containing amorphous, hyaline, eosinophilic, PAS-positive material resembling Call-Exner bodies.

The connective tissue stroma surrounding the cellular nests may be scant or abundant and cellular, resembling ovarian stroma, or dense and hyalinized. It may contain luteinized or Leydig-like cells devoid of Reinke crystals [2598,2849,2850].

Three processes, hyalinization, calcification and overgrowth by a malignant germ cell element, usually dysgerminoma, may alter the basic histological appearance of gonadoblastoma. The hyalinization occurs by coalescence of the hyaline bodies and bands of hyaline material around the nests with replacement of the cellular contents. Calcification originates in the hyaline Call-Exner-like bodies and is seen histologically in more than 80% of cases [2598]. It tends to replace the hyalinized nests forming rounded, calcified concretions. Coalescence of such concretions may lead to the calcification of the whole lesion, and the presence of smooth, rounded, calcified bodies may be the only evidence that gonadoblastoma has been present. The term "burned-out gonadoblastoma" has been applied to such lesions [2598,2849,2850]. Gonadoblastoma is overgrown by dysgerminoma in approximately 50% of cases, and in an additional 10% another malignant germ cell element is present [2598,2846,2849,2850]. Gonadoblastoma has never been observed in metastatic lesions or

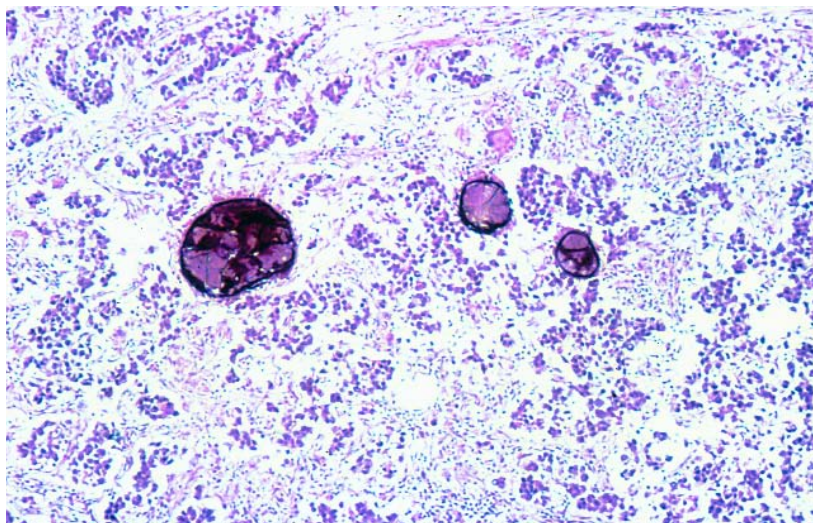


Fig. 2.111 Dysgerminoma with "burnt out" gonadoblastoma. The typical pattern of a dysgerminoma consists of aggregates of primitive germ cells separated by fibrous septa infiltrated by lymphocytes. The presence of "burnt out" gonadoblastoma is indicated by smooth, rounded, calcified bodies.

outside the gonads [2598,2849,2850].

In most cases the gonad of origin is indeterminate because it is overgrown by the tumour. When the nature of the gonad can be identified, it is usually a streak or a testis. The contralateral gonad, when identifiable, may be either a streak or a testis, and the latter is more likely to harbour a gonadoblastoma [2598,2849,2850]. Occasionally, gonadoblastoma may be found in otherwise normal ovaries [2077,2598,2849,2850].

Tumour spread and staging

At the time of operation gonadoblastomas typically are bilateral, although at times they may be not macroscopically detectable in the gonad. Those that are overgrown by dysgerminoma or other malignant germ cell tumour may be much larger. If a malignant germ cell tumour develops, the potential for metastatic disease exists. Dysgerminomas typically spread by the lymphatic route, less frequently by peritoneal dissemination. Therefore, it is extremely important not only to remove both gonads but to perform surgical staging if at the time of operative consultation a malignant germ cell tumour is identified. The typical staging for a dysgerminoma or other malignant germ cell tumour includes pelvic and para-aortic lymph node sampling as well as peritoneal washings if no ascites is present [2586].

The operation should include omentectomy, and multiple peritoneal samplings are required. For patients with spread of a malignant germ cell tumour other than dysgerminoma, aggressive cytoreduction surgery is appropriate [2586].

Precursor lesions

Gonadoblastoma is almost invariably associated with an underlying gonadal disorder. When the disorder is identifiable, it is usually pure or mixed gonadal dysgenesis with a Y chromosome being detected in over 90% of the cases [2598,2605].

Prognosis and predictive factors

Clinical criteria

Patients having gonadoblastoma without dysgerminoma or other germ cell tumour are treated by surgical excision of the gonads without additional therapy. However, if dysgerminoma and/or another malignant germ cell element is present, surgical staging and postoperative combination chemotherapy, the most popular current regimen being bleomycin, etoposide and cisplatin (BEP), are required. Other regimens include etoposide and carboplatin [2586]. Dysgerminoma is exquisitely sensitive to chemotherapy, as it was previously shown to be exquisitely responsive to radiation therapy.

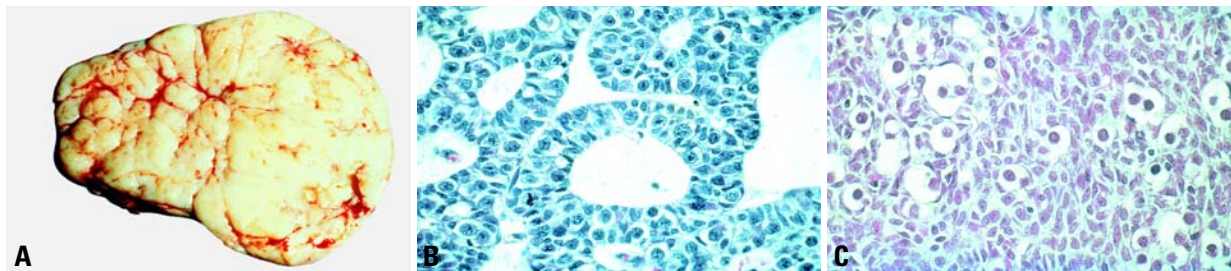


Fig. 2.112 Mixed germ cell-sex cord-stromal tumour. **A** The sectioned surface shows a lobulated, pale yellow tumour. **B** The tumour is composed of an admixture of smaller sex cord cells and larger germ cells with clear cytoplasm forming cords and trabeculae surrounded by loose oedematous connective tissue. **C** Small carrot-shaped sex cord cells are admixed with large pale germ cells in a haphazard fashion. .

Histopathological criteria

Pure gonadoblastoma may show extensive involvement of the gonad but does not behave as a malignant lesion [2598, 2849,2850]. More frequently, its germ cell component gives rise to a malignant germ cell neoplasm capable of invasion and metastases. Gonadoblastoma may sometimes undergo ablation by a process of marked hyalinization and calcification. In such cases the lesion becomes innocuous, but great care must be taken to exclude the presence of viable elements, especially of germ cell lineage.

Dysgerminoma arising within gonadoblastoma tends to metastasize less frequently and at a later stage than dysgerminoma arising de novo [2598, 2849,2850]. There is no satisfactory explanation for this phenomenon. The patients can be treated similarly to patients with pure dysgerminoma with a very high likelihood of complete cure.

Mixed germ cell-sex cord-stromal tumour

Definition

A neoplasm composed of intimately admixed germ cells and sex cord derivatives that has a different histological appearance from gonadoblastoma. Mixed germ cell-sex cord-stromal tumour also differs from gonadoblastoma by its occurrence in anatomically, phenotypically and genetically normal females [2844,2845,2847].

Epidemiology

Mixed germ cell-sex cord-stromal tumours usually occur in infants or children under the age of 10, but have been occasionally reported in postmenarchal women [1556,2844,2852].

Aetiology

Patients with mixed germ cell-sex cord-stromal tumour have normal gonadal development and a normal XX karyotype. The tumour is not associated with gonadal dysgenesis, and its aetiology is unknown [1556,2844,2852,3270].

Clinical features

Patients with a mixed germ cell-sex cord-stromal tumour generally present with lower abdominal pain. In almost a fourth of the cases patients have isosexual pseudoprecocity and may have vaginal bleeding and bilateral breast development [1556,2852,3270]. Physical examination routinely reveals a large mass in the adnexal area or in the lower abdomen.

Macroscopy

This tumour, unlike gonadoblastoma, tends to be relatively large, measuring 7.5-18 cm and weighing 100-1,050 grams. Except for two reported cases, mixed germ cell-sex cord-stromal tumour is unilateral [1321,2849,2850]. The tumour is usually round or oval and is surrounded by a smooth, grey or grey-yellow capsule. In most cases it is solid, but in some cases it may be partly cystic. The sectioned surface is grey-pink or yellow to pale brown. There is no evidence of calcification. In all cases the fallopian tube, the uterus and the external genitalia are normal.

Tumour spread and staging

Since mixed germ cell-sex cord-stromal tumours are less aggressive than gonadoblastoma and uncommonly bilateral, the routine evaluation of patients with a mixed germ cell-sex cord-stromal tumour can be less extensive. Although the tumours are often of considerable

size, metastases have occurred in only two cases [124,1556]. If intraoperative consultation is inconclusive, it is appropriate to limit the operation to removal of the involved gonad and to await the final pathology results before performing any definitive surgery that might impair future fertility.

Histopathology

Mixed germ cell-sex cord-stromal tumour is composed of germ cells and sex cord derivatives resembling immature Sertoli or granulosa cells intimately admixed with each other. The tumour cells form four distinctive histological patterns as follows:

- (1). A cord-like or trabecular pattern composed of long, narrow, ramifying cords or trabeculae that in places expand to form wider columns and larger round cellular aggregates surrounded by connective tissue stroma that varies from dense and hyalinized to loose and oedematous.
- (2). A tubular pattern composed of solid tubules surrounded by fine connective tissue septa and containing peripherally located smaller epithelial-like sex cord derivatives surrounding large, round germ cells with clear or slightly granular cytoplasm and large vesicular nuclei containing prominent nucleoli.
- (3). A haphazard pattern consisting of scattered collections of germ cells surrounded by sex cord derivatives, which may be very abundant.
- (4). A mixed pattern showing an admixture of the three above mentioned patterns without any predominance.

The germ cells show mitotic activity and a close similarity to those of dysgerminoma, but in some cases they are better differentiated showing smaller nuclei and less marked mitotic activity. Unlike the

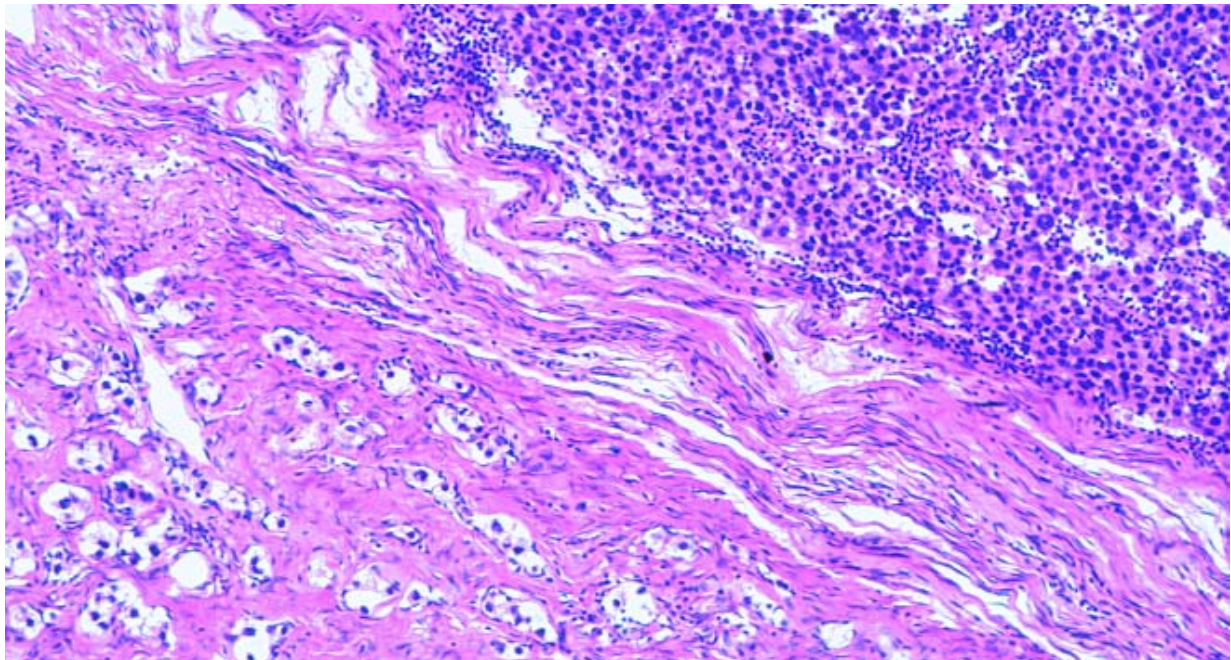


Fig. 2.113 Mixed germ cell-sex cord-stromal tumour associated with dysgerminoma. The former is composed of clusters of germ cells and small sex-cord type cells in a dense fibrous stroma. Note the dysgerminoma in the right upper portion of the field.

finding in gonadoblastoma, the sex cord derivatives also show mitotic activity [2847,2849,2850].

The composition of a mixed germ cell-sex cord-stromal tumour varies, and in some areas the sex cord elements may predominate, whereas in others there is a predominance of germ cells. The cystic spaces seen in some tumours resemble the cystic spaces seen in cystic and retiform Sertoli cell tumours and should not be confused with cysts and papillae seen in ovarian serous tumours, which they may resemble superficially [2849, 2850].

Although originally mixed germ cell-sex cord-stromal tumours were found to occur in pure form, it was later noted that approximately 10% of cases are associated with dysgerminoma or other malignant germ cell elements. This finding is by far less common than in gonadoblastoma.

The tumour is always found in normal ovaries, and whenever the unaffected contralateral gonad is examined, it is a normal ovary.

Genetic susceptibility

Familial clustering of these rare tumours has not been reported.

Prognosis and predictive factors

In the majority of cases the mixed germ cell-sex cord-stromal tumour occurs in pure form. Mixed germ cell-sex cord-stromal tumours are generally benign and are treated by unilateral oophorectomy. Preservation of fertility should be a priority in those patients that appear to have a unilateral mixed germ cell-sex cord-stromal tumour.

The association with other neoplastic germ cell elements is more common in postmenarchal subjects, but it may be seen in children in the first decade

[2849,2850]. One case of mixed germ cell-sex cord-stromal tumour was associated with para-aortic lymph node and abdominal metastases [1556]. Another patient developed intra-abdominal metastatic disease two years following the excision of a large ovarian tumour [124]. Both patients are well and disease free following surgery and chemotherapy. It is of interest that the tumour associated with the intra-abdominal recurrence showed an unusual histological pattern of sex cord tumour with annular tubules, but differed from the latter by the presence of numerous germ cells [124].

In those cases with metastatic disease, aggressive surgical cytoreduction is performed, and the BEP regimen is routinely used postoperatively.

Tumours and related lesions of the rete ovarii

F. Nogales

Definition

A varied group of benign and malignant tumours and related lesions that originate from the rete ovarii, a vestigial structure present in the ovarian hilus and histologically identical to its testicular homologue.

ICD-O codes

Rete ovarii adenocarcinoma	9110/3
Rete ovarii adenoma	9110/0

Clinical features

Most lesions are incidental findings in postmenopausal patients. Sizeable cysts and tumours manifest as pelvic masses. Some cases may present with hormonal symptoms due to concomitant hilus cell hyperplasia or stromal luteinization in adenomas.

Histopathology

The rete is an unusual site for any type of pathology. In order to diagnose a lesion as originating in the rete, it must be located in the ovarian hilus and be composed of cuboidal or columnar non-ciliated cells arranged in retiform spaces. Areas of normal rete and hilus cells should be found in the vicinity of the tumour or show a transition [2495]. Dilated areas and cysts are the most frequent histological finding, but a few solid proliferative lesions have been reported.

The rete ovarii appears to be functionally related to folliculogenesis [385]. Although its embryology is not fully understood, it is likely to be mesonephric in origin. Recently, attention has been focused on its morphology and immunophenotype in order to find histogenetic relationships with neoplasms of uncertain origin such as tumours of probable wolffian origin [682] and retiform Sertoli-Leydig cell tumours [1904], as well as to differentiate it from endometriosis [2494] and to identify new mesonephric identity markers [2110]. These studies show constant coexpression of vimentin and cytokeratin and positivity for CD10 [2110], frequent positivity for calretinin, inhibin and CA125 and iso-

lated positivity to A103 (melan-A) and epithelial membrane antigen [605,1450,2495,2792].

Immunoprofile

Immunohistochemically, adenomas and adenocarcinomas are positive for CAM

5.2, cytokeratin 19, CA125, CD10 and occasionally for epithelial membrane antigen and estrogen and progesterone receptors.

Adenocarcinoma

Adenocarcinoma of the rete ovarii is

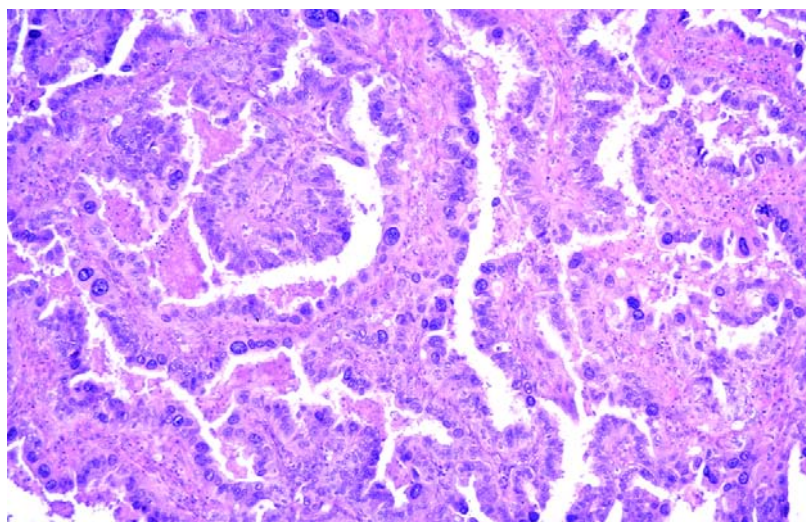


Fig. 2.114 Carcinoma of the rete ovarii. The epithelial cells lining the papillae show marked atypia.

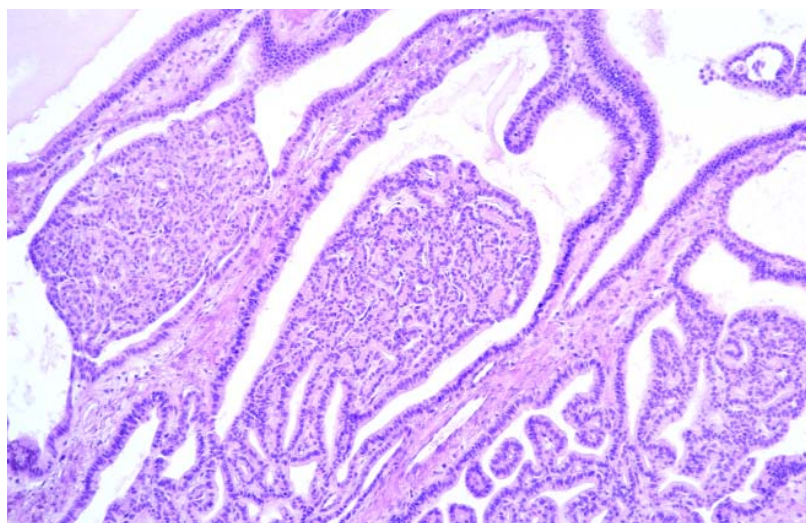


Fig. 2.115 Adenoma of the rete ovarii. Note the tubulopapillary architecture.

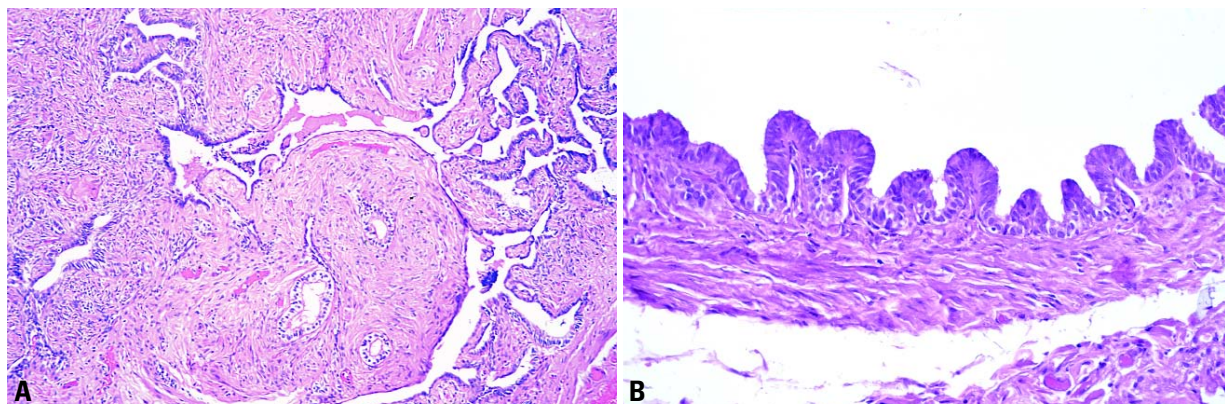


Fig. 2.116 **A** Adenomatous hyperplasia of the rete ovarii. Note the branching network of spaces. **B** Cyst of rete ovarii. The cyst lining has shallow infoldings.

exceptional. A bilateral tumour with a retiform tubulopapillary histology admixed with transitional-like areas has been reported [2495]. The patient initially had stage II disease, and the tumour recurred with elevated serum levels of CA125.

Adenoma

Adenoma of the rete ovarii typically occurs as an incidental finding in middle-aged or elderly women, is located in the hilus and is well circumscribed [2495]. It is composed of closely packed elongated tubules, some of which are dilated and contain simple papillae, and may show stromal luteinization or concomitant hilus cell hyperplasia. All reported adenomas have behaved in a benign fashion.

Cystadenoma and cystadenofibroma

One cystadenofibroma and two cystadenomas of the rete ovarii, one of which was bilateral, have been reported [2040]. In both instances they originated from the rete, involved only the ovarian medulla and were tubulopapillary cystic proliferations of clear columnar cells. The stroma was densely populated by luteinized cells, which caused irregular bleeding in both postmenopausal patients. The bilateral case had on one side a non-invasive adenoma but with marked cellular atypia and pleomorphism.

Adenomatous hyperplasia

Among the proliferative lesions, adenomatous hyperplasia of the rete ovarii is similar to the same lesion in the testis

[1169]. It is differentiated from adenoma only by its poorly defined margins.

Cysts

Most cysts are unilocular with an average diameter of 8.7cm [2495] and a smooth inner surface. Histologically, they show serrated contours with crevice formation. Their lining consists of a single layer of cuboidal to columnar non-ciliated cells. Their walls contain tracts of smooth muscle and foci of hilus cells, which are sometimes hyperplastic and may be responsible for some hormonal manifestations [2495].

Miscellaneous tumours and tumour-like conditions of the ovary

L.M. Roth
A. Tsubura
M. Dietel
H. Senzaki

Definition

A group of benign and malignant ovarian tumours of diverse or uncertain origin.

ICD-O codes

Small cell carcinoma, hypercalcaemic type	8041/3
Small cell carcinoma, pulmonary type	8041/3
Large cell neuroendocrine carcinoma	8013/3
Adenoid cystic carcinoma	8200/3
Basal cell tumour	8090/1
Hepatoid carcinoma	8576/3
Malignant mesothelioma	9050/3
Gestational choriocarcinoma	9100/3
Hydatidiform mole	9100/0
Ovarian wolffian tumour	9110/1
Wilms tumour	8960/3
Paraganglioma	8693/1
Myxoma	8840/0

Small cell carcinoma, hypercalcaemic type

Definition

An undifferentiated carcinoma that is usually associated with paraendocrine hypercalcaemia and is composed primarily of small cells.

Clinical features

This neoplasm typically occurs in young women and is associated with paraendocrine hypercalcaemia in approximately two-thirds of patients {3204}. Most of the patients presented with abdominal swelling or pain related to their tumour; however, one patient had a neck exploration for presumed parathyroid disease with negative results before the ovarian tumour was discovered {3204}.

Macroscopy

The tumours are usually large and predominantly solid, pale white to gray masses. Necrosis, haemorrhage and cystic degeneration are common.

Tumour spread and staging

In approximately 50% of the patients the

tumour has spread beyond the ovary at the time of initial laparotomy.

Histopathology

On histological examination the tumours typically grow diffusely, but they may form small islands, trabeculae or cords. They frequently form follicle-like spaces that almost always contain eosinophilic fluid, and nuclei show easily discernible nucleoli. Foci of either benign or malignant mucinous epithelium are present in 10–15% of the cases. Typically, the cells of the tumour contain scant cytoplasm, but in approximately one-half of cases a component of large cells with abundant eosinophilic cytoplasm and nuclei containing prominent nucleoli is present.

Immunoprofile

Small cell carcinomas generally stain for epithelial membrane antigen but not for inhibin {2376}. Variable staining of the neoplastic cells for vimentin, cytokeratin

and epithelial membrane antigen is observed {46}.

Cytometric studies

Flow cytometric studies of paraffin-embedded tissue has demonstrated that the neoplastic cells are diploid {755}.

Electron microscopy

Electron microscopic examination has shown an epithelial appearance to the neoplasm consisting of small desmosomes and, in some cases, tight junctions {695}. Dilated granular endoplasmic reticulum containing amorphous material is characteristically present within the cytoplasm {695,696}. Few or no neurosecretory granules have been identified.

Differential diagnosis

Because of the young age of the patients and the presence of follicle-like spaces in the neoplasm, the differential diagnosis includes juvenile granulosa cell tumour.

Table 2.08

Comparison of small cell carcinoma of the hypercalcaemic type with juvenile granulosa cell tumour.

Small cell carcinoma, hypercalcaemic type	Juvenile granulosa cell tumour
Stage I in 50% of cases	Stage I in greater than 97% of cases
Highly malignant	Usually non-aggressive
Hypercalcaemia in two-thirds of cases	Hypercalcaemia absent
Never estrogenic	Usually estrogenic
Scant or non-specific stroma	Fibrothecomatous stroma common
Follicles often contain mucicarminophilic basophilic secretion	Follicles rarely contain mucicarminophilic basophilic secretion
Nuclei hyperchromatic	Rounded euchromatic nuclei,
Prominent nucleoli	Indistinct nucleoli
Mitoses frequent	Mitoses variable
Usually epithelial membrane antigen positive	Epithelial membrane antigen negative
Alpha-inhibin negative	Alpha-inhibin positive

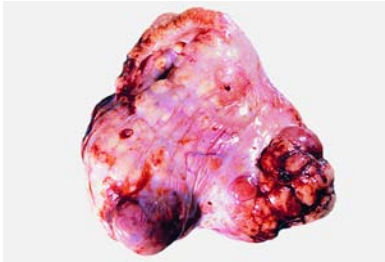

Fig. 2.117 Small cell carcinoma, hypercalcaemic type. The ovary is involved by a solid, knobby tumour that has extended through the capsule to the right.

This tumour may also be confused with adult type granulosa cell tumours, malignant lymphoma and other small cell malignant neoplasms that involve the ovary [695]. The absence of membrane immunoreactivity for MIC2 protein (CD99) serves to distinguish small cell carcinoma from primitive neuroectodermal tumour (see section on germ cell tumours).

Histogenesis

The histogenesis of small cell carcinoma has not been definitively established [755]. It has been proposed that this tumour may be a variant of a surface epithelial-stromal tumour [2376]. A study utilized a mouse xenograft model in which tumour fragments of small cell carcinoma were cultured in six subsequent generations of nude mice. The transplanted tumour morphology remained the same as that of primary tumour from the patient, and serum calcium levels were significantly higher in tumour-bearing mice compared to controls. By comparative genomic hybridization and electron microscopy the tumour appeared to be a distinct tumour entity, not related to either a germ cell tumour or epithelial ovarian cancer [3050].

Genetic susceptibility

The neoplasm has been familial in several instances. The tumour has occurred in three sisters, in two cousins and in a mother and daughter [3204]. The familial tumours were all bilateral in contrast to the rarity of bilateral tumours in general.

Prognosis and predictive factors

In the largest series of patients approximately one-third of patients with stage IA disease were alive and free of tumour at last follow up [3204]. Almost all the patients with a stage higher than IA died of disease.

Small cell carcinoma, pulmonary type

Definition

A small cell carcinoma resembling pulmonary small cell carcinomas of neuroendocrine type.

Synonym

Small cell carcinoma of neuroendocrine type.

Clinical features

Patients typically are postmenopausal and present with pelvic or abdominal masses.

Macroscopy

The tumours are typically large and solid with a cystic component.

Histopathology

The pulmonary type resembles small cell carcinoma of the lung and is associated with a surface epithelial-stromal tumour, most often endometrioid carcinoma [761]. The neoplastic cells have nuclei with finely stippled chromatin, lack nucleoli and show molding. The cytoplasm is scant. Mitoses are numerous. The appearance varies somewhat depending on cellular preservation.

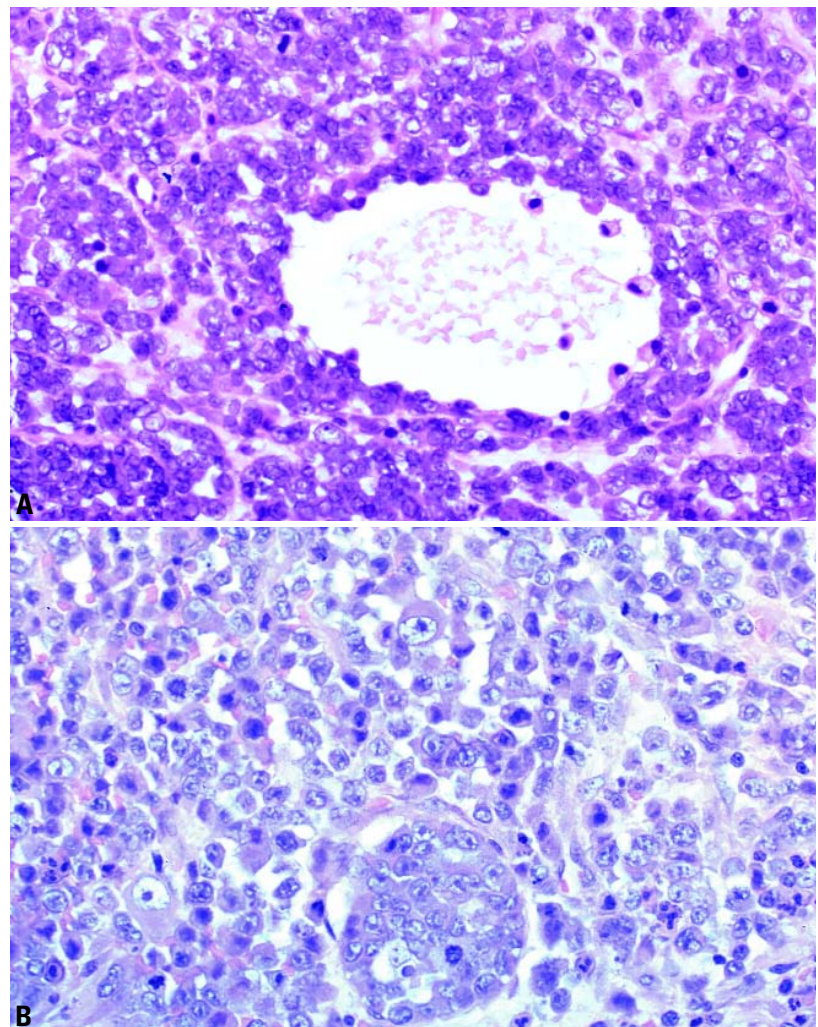


Fig. 2.118 Small cell carcinoma, hypercalcaemic type. **A** Note the follicle-like space. **B** There is a diffuse proliferation of mitotically active small cells with enlarged nuclei that contain small nucleoli.

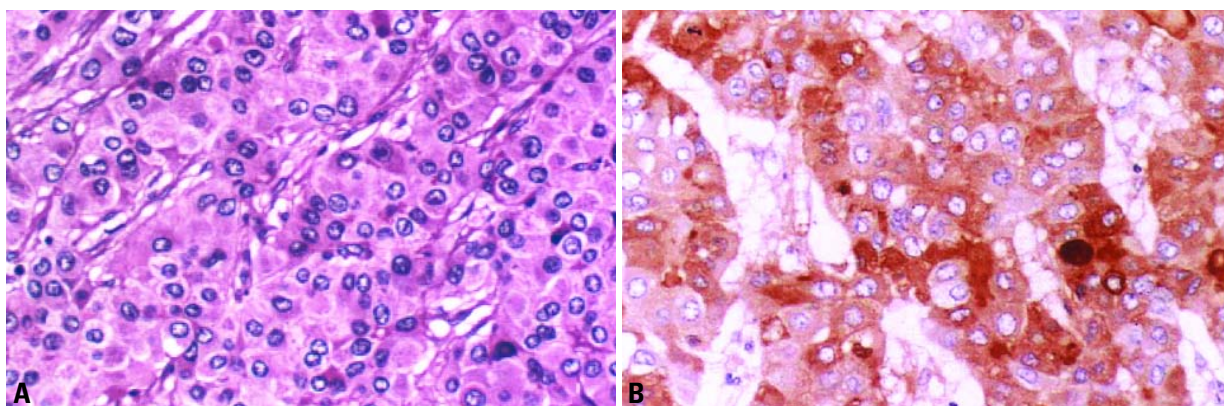


Fig. 2.119 Hepatoid carcinoma. **A** Note the trabecular pattern with thick cords of hepatoid cells. **B** Positive staining for alpha-fetoprotein is observed.

Immunoprofile

Immunohistochemical markers for neuron specific enolase are typically positive, and a minority of cases were positive for chromogranin [761].

Cytometric studies

The majority of neoplasms are aneuploid by flow cytometry [761].

Prognosis and predictive factors

The neoplasm is highly malignant, and the behaviour has been aggressive regardless of stage [761].

Large cell neuroendocrine carcinoma

Definition

A malignant tumour composed of large cells that show neuroendocrine differentiation.

Synonym

Undifferentiated carcinoma of non-small cell neuroendocrine type.

Clinical features

Two series of ovarian neuroendocrine carcinomas of non-small cell type have been reported [455,756]. The patients were in the reproductive age group or beyond (mean 56 years) and presented with symptoms related to a pelvic mass in the majority of cases [756].

Histopathology

These tumours have in all the reported cases been associated with a tumour of surface epithelial-stromal type, either benign or malignant [455,542,756]. The neuroendocrine component consisted

of medium to large cells. Nuclei contained prominent nucleoli, and mitoses were frequent. The solid component stained for chromogranin, and neuropeptides were demonstrated in some cases.

Prognosis and predictive factors

This type of tumour appears to be highly aggressive; only the neuroendocrine carcinoma component was present in the metastatic sites [455].

Hepatoid carcinoma

Definition

A primary ovarian neoplasm that histologically resembles hepatocellular carcinoma and is positive for alpha-fetoprotein.

Epidemiology

Hepatoid carcinoma of the ovary is a rare tumour; only 12 cases have been reported [1798,2629,2951]. It mainly occurs in postmenopausal women with a mean age of 59.6 years (range, 35-78 years).

Clinical features

The symptoms are not specific and are related to an ovarian mass [2629]. Elevation of serum alpha-fetoprotein (AFP) is characteristic, and CA125 is elevated in most cases.

Macroscopy

Tumours vary from 4-20 cm in maximum dimension with no distinctive macroscopic features [1798,2629,2951]. In some cases, formalin fixation reveals green-coloured areas suggestive of bile production [2629].

Histopathology

The tumour cells are arranged in sheets, cords and trabeculae with moderate to abundant amounts of eosinophilic cytoplasm and distinctive cell borders resembling hepatocellular carcinoma. Mitoses are generally conspicuous. PAS-positive, diastase-resistant hyaline globules and Hall stain-positive bile pigment can be seen. The presence of immunoreactive AFP and protein induced by vitamin K absence or antagonist II (PIVKA-II) shows functional differentiation toward hepatocytes [1307,2629]. CA125 is positive in one-half of the tumours [2629].

Differential diagnosis

Metastatic hepatocellular carcinoma and hepatoid yolk sac tumour must be ruled out [3197].

Histogenesis

Tumours admixed with serous carcinoma and tumour cells positive for CA125 suggest an ovarian surface epithelial origin [1307,2610,2629].

Prognosis and predictive factors

Clinical outcome is poor. Seven out of 12 patients died between 4 months and 5 years (mean, 19 months) after initial diagnosis, and 2 patients had a tumour recurrence after 6-7 months [1798,2629,2951].

Tumours resembling adenoid cystic carcinoma and basal cell tumour

Definition

A group of primary ovarian tumours that histologically resemble certain tumours of the salivary glands or cutaneous basal cell carcinoma.

Clinical features

Adenoid cystic-like carcinoma presents typically as a pelvic mass or abdominal distension in postmenopausal women [758]. On the other hand, the two cases of adenoid cystic carcinoma occurred in the reproductive age group [837,3248]. Cases of basal cell carcinoma of the ovary also typically present as a pelvic mass but occur over a wide age range [758].

Histopathology

These neoplasms histologically resemble adenoid cystic carcinoma, basal cell tumours of salivary gland or cutaneous basal cell carcinoma and occur in several forms. The adenoid cystic-like carcinomas resemble adenoid cystic carcinoma of salivary gland but lack a myoepithelial component [758]. On the other hand a myoepithelial component has been demonstrated in the cases of adenoid cystic carcinoma [837,3248]. Cribriform patterns composed of uniform small cells surrounding round lumens and cysts were typical, and luminal mucin and hyaline cylinders were common to both forms. A surface epithelial-stromal component was present in the great majority of cases of adenoid cystic-like carcinoma [758] but was absent in the cases of adenoid cystic carcinoma [837,3248]. The cases of basal cell tumour consisted of aggregates of basaloid cells with peripheral palisading [758]. Several tumours of this type had foci of squamous differentiation or gland formation, and some showed an ameloblastoma-like pattern. A case of a monomorphic adenoma of salivary gland type described as a cribriform variant of basal cell adenoma has been reported [2492]. In none of the reported cases in this group was there evidence of a teratoma or other germ cell tumour.

Immunoprofile

Actin and S-100 protein stains were both positive in the two cases of adenoid cystic carcinoma [837,3248]; however, these stains were negative in the cases of adenoid cystic-like carcinoma [758].

Prognosis and predictive factors

The prognosis of adenoid cystic-like carcinoma is generally unfavourable and appears to depend on the degree of malignancy of the surface epithelial-stromal component. On the other hand, cases of basal cell tumour and adenoid

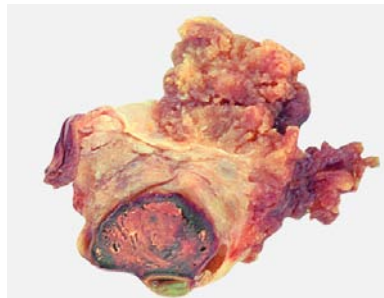


Fig. 2.120 Ovarian papillary mesothelioma. Note the papillary tumour growth on the surface and a haemorrhagic corpus luteum within the ovary.

cystic carcinoma have an excellent prognosis with relatively limited follow up.

Ovarian malignant mesothelioma

Definition

Ovarian malignant mesotheliomas (OMMs) are mesothelial tumours confined mostly or entirely to the ovarian surface and/or the ovarian hilus.

Aetiology

In the largest series there was no history of asbestos exposure [526].

Clinical features

The clinical presentation was usually abdominal or pelvic pain or abdominal swelling and an adnexal mass on pelvic examination [526].

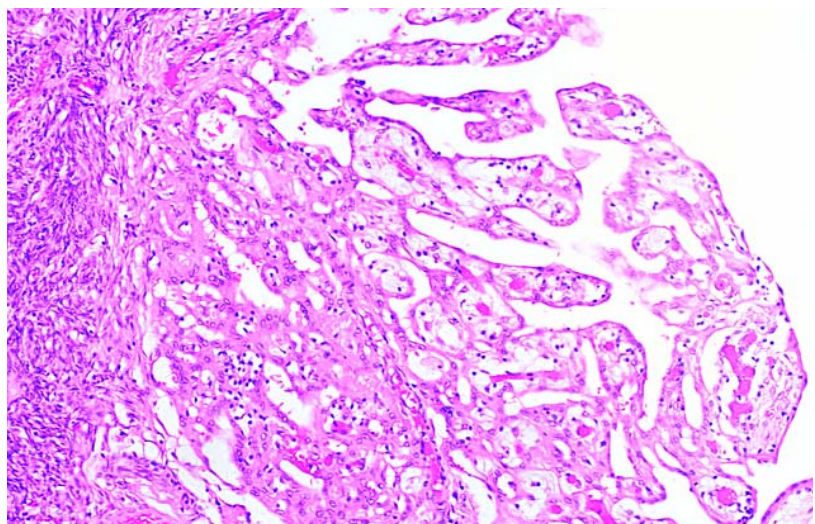


Fig. 2.121 Papillary mesothelioma of the ovary. Well differentiated papillary fronds of tumour grow from the surface of the ovary.

Macroscopy

The tumours were typically solid and varied from 3-15 cm in maximum dimension. Most were bilateral.

Histopathology

The tumours usually involved both the serosa and the parenchyma of the ovary. The histological and immunohistochemical characteristics of the OMM are analogous to those observed in peritoneal mesotheliomas. The proliferating mesothelial tumour cells may invade and partly replace ovarian tissue and/or the hilar soft tissue.

Differential diagnosis

Just like diffuse peritoneal malignant mesotheliomas, OMMs can extensively involve one or both ovaries in a macroscopically and histologically carcinomatous growth pattern and may thus be confused with ovarian epithelial neoplasms. In this context immunohistochemical detection of thrombomodulin, calretinin, Ber-EP4 and cytokeratin 5/6 provide the most useful markers [2113].

Prognosis and predictive factors

In the absence of sufficient follow-up data for this rare neoplasm, OMM can be assumed to have a prognosis similar to its disseminated peritoneal analogue.

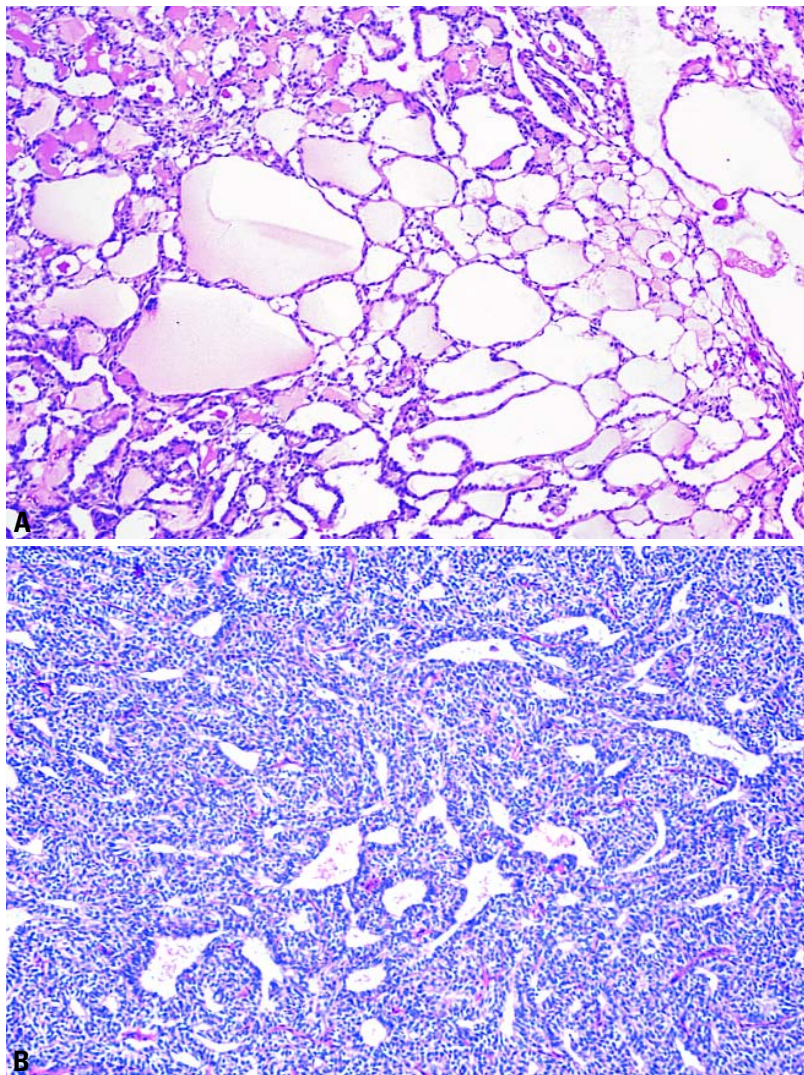


Fig. 2.122 Wolffian tumour. **A** The microcysts containing an eosinophilic material result in a sieve-like appearance. **B** The tumour cells may be spindle-shaped and form irregularly-shaped tubules simulating a retiform pattern.

Gestational choriocarcinoma

Definition

A rare tumour composed of both cytotrophoblast and syncytiotrophoblast that arises as a result of an ectopic ovarian pregnancy. No germ cell or common epithelial component is present.

Clinical features

Patients with choriocarcinoma have symptoms related to a large haemorrhagic mass that may rupture causing haematoperitoneum.

Macrosopy

Choriocarcinoma consists typically of a haemorrhagic mass.

Histopathology

The typical appearance is an admixture of syncytiotrophoblast and cytotrophoblast often arranged in a plexiform pattern [142,1317]. The specimens must be sampled extensively to rule out a germ cell, or in the older age group, a surface epithelial component. They must be distinguished from rarely reported ovarian hydatidiform moles, which have

hydropic chorionic villi with cistern formation and trophoblastic proliferation.

Prognosis and predictive factors

The prognosis of gestational choriocarcinoma is more favourable than that of the nongestational type. Single agent chemotherapy with methotrexate or actinomycin D is highly effective.

Hydatidiform mole

Definition

Hydatidiform mole is an ectopic ovarian molar pregnancy. Ovarian hydatidiform moles have hydropic chorionic villi with cistern formation and trophoblastic proliferation.

Clinical features

Patients with hydatidiform mole have symptoms related to large haemorrhagic masses that may rupture causing haematoperitoneum.

Macrosopy

Hydatiform mole typically consists of a haemorrhagic mass; chorionic vesicles may be identified.

Histopathology

Hydatidiform moles show characteristic hydropic chorionic villi with cistern formation and trophoblastic proliferation [2821,3212].

Ovarian wolffian tumour

Definition

A tumour of presumptive wolffian origin characterized by a variety of epithelial patterns.

Synonyms

Ovarian tumour of probable wolffian origin, retiform wolffian tumour.

Localization

Although more common in the broad ligament, this tumour also occurs in the ovary [1262,3212].

Clinical features

Patients are in the reproductive age group or beyond and present with abdominal swelling or a mass [3212]. Preoperative serum oestradiol levels may be elevated and return to normal postmenopausal levels after operation [1289].

Histopathology

This epithelial tumour may show diffuse, solid tubular, hollow tubular and sieve-like patterns, and combinations of the various patterns may occur. Cases have been reported associated with endometrial hyperplasia {1262,1289}.

Immunoprofile

The neoplasms are positive for CAM5.2, cytokeratins 7 and 19 and vimentin but are negative for cytokeratin 20, 34betaE12, B72.3, carcinoembryonic antigen, and epithelial membrane antigen {2321,2878,2926}. The neoplastic cells often express CD10 {2110} and often are weakly positive for alpha-inhibin {1499}.

Histogenesis

Cases have been reported arising within the rete ovarii {662,2878}. An immunohistochemical study based on a comparison with mesonephric remnants and paramesonephric structures supported but did not prove a mesonephric origin of these neoplasms {2926}.

Prognosis and predictive factors

These tumours typically are not aggressive; however, a significant minority of patients have had an aggressive course {3212}. The malignant cases sometimes, but not always, show nuclear atypia and increased mitotic activity.

Wilms tumour

Definition

A primary ovarian neoplasm that has the typical features of a Wilms tumour of the kidney.

Epidemiology

Several cases of pure Wilms tumour of the ovary have been reported {1303,2506}.

Clinical features

The tumour occurs in patients in the reproductive age group and beyond and presents as a rapidly growing adnexal mass.

Histopathology

They have the typical appearance of a Wilms tumour including small tubules, glomeruloid structures and blastema. No teratomatous elements were identified.

Prognosis and predictive factors

Two of the patients were living and well 10 months and 7 years postoperatively.

Paraganglioma

Definition

A unique neuroendocrine neoplasm, usually encapsulated and benign, arising in specialized neural crest cells associated with autonomic ganglia (paraganglia).

Synonym

Phaeochromocytoma.

Clinical features

A single case of a paraganglioma of the ovary in a fifteen year old girl with hypertension has been reported {832}. In addition two unpublished cases have been described {2605}.

Histopathology

The tumours consist of polygonal epithelioid cells arranged in nests separated by a fibrovascular stroma.

Immunoprofile

The tumour is positive for chromogranin. In addition, stains for S-100 protein can identify sustentacular cells {2605}.

Biochemistry

Epinephrine and norepinephrine were extracted from the tumour {832}.

Myxoma

Definition

A benign mesenchymal tumour composed of cells with bland nuclear features producing abundant basophilic intercellular ground substance.

Clinical features

Patients with ovarian myxomas present in the reproductive age group typically with an asymptomatic unilateral adnexal mass {757}.

Macrosocopy

The tumours are large, averaging 11 cm in diameter. The sectioned surface is soft, often with cystic degeneration.

Histopathology

Myxoma is a sharply demarcated tumour composed of spindle and stellate-shaped cells within an abundant, well vascularized myxoid background. Small foci of non-myxoid fibrous tissue or smooth muscle may be present. Lipoblasts are not identified. Mitoses are rare. The intercellular material stains with alcian blue and

colloidal iron. Staining is prevented by pretreatment with hyaluronidase indicating that the material is hyaluronic acid.

Immunoprofile

Immunohistochemical stains show that the tumours are positive for vimentin and smooth muscle actin but negative for most other common immunohistochemical markers {567}.

Electron microscopy

Ultrastructural features of thin filaments condensed into dense bodies also support the presence of myofibroblasts {567}.

Histogenesis

Based on an immunohistochemical comparison with myxoid areas of ovarian stromal tumours, myxomas were considered to be a variant of the thecoma-fibroma group {3254}.

Prognosis and predictive factors

The tumour is practically always benign although one case diagnosed originally as myxoma had a late recurrence after 19 years {2901}. In that case the original tumour showed occasional mitotic figures (less than 1 per ten high power fields), slight atypia and occasional vacuolated cells. The recurrent neoplasm, but not the original, was aneuploid by DNA-flow cytometry {2901}.

Malignant soft tissue tumours not specific to the ovary

Pure soft tissue sarcomas of somatic type rarely occur as primary tumours of the ovary. They typically present as a rapidly enlarging adnexal mass. Their histological appearance is similar to soft tissue tumours in other locations. Among the reported cases of pure sarcomas are

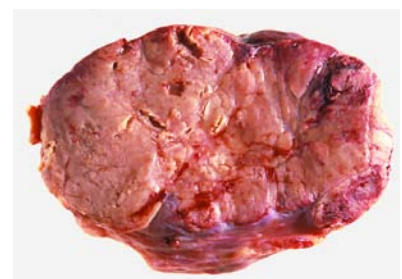


Fig. 2.123 Luteoma of pregnancy. The sectioned surface shows a nodular brown tumour.

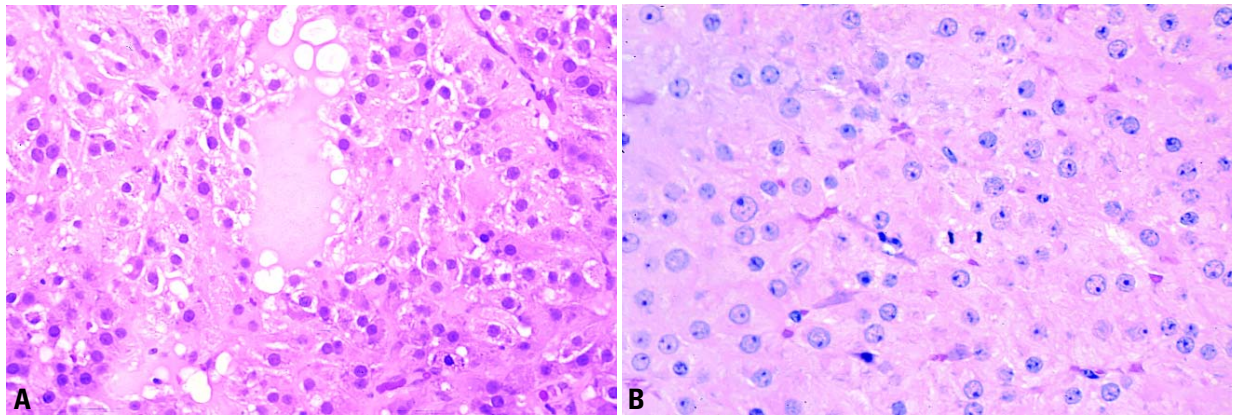


Fig. 2.124 Luteoma of pregnancy. **A** The tumour is composed of polygonal eosinophilic cells that form follicle-like spaces filled with pale fluid. **B** The tumour is composed of large polygonal eosinophilic cells that are mitotically active.

fibrosarcoma [1517,1867], leiomyosarcoma [917,1416,1895,1983,2037], malignant peripheral nerve sheath tumour [2797], lymphangiosarcoma, angiosarcoma [2021,2064], rhabdomyosarcoma [2018], osteosarcoma [1215] and chondrosarcoma [2851]. These tumours should be classified according to the WHO Histological Typing of Soft Tissue Tumours [3086]. Similarly, tumours may also arise as a component of a complex ovarian tumour such as malignant müllerian mixed tumour, adenosarcoma, immature teratoma or dermoid cyst or from heterologous elements in a Sertoli-Leydig cell tumour. Rare sarcomas of various types may be associated with surface epithelial stromal tumours, particularly serous, mucinous and clear cell adenocarcinoma. These tumours must be distinguished from metastatic sarcoma to the ovary [3222].

Benign soft tissue tumours not specific to the ovary

Of the remaining soft tissue tumours, leiomyomas and haemangiomas are most common. Occasional benign neural tumours, lipomas, lymphangiomas, chondromas, osteomas and ganglioneuromas have been reported. Their appearance is similar to soft tissue tumours in other locations. These tumours should be classified according to the World Health Organization Histological Typing of Soft Tissue Tumours [3086].

Tumour-like conditions

Definition

Non-neoplastic conditions that can mimic an ovarian neoplasm clinically, macroscopically and/or histologically.

Luteoma of pregnancy

Definition

Single or multiple nodules composed of lutein cells with abundant eosinophilic cytoplasm that are detected at the end of a term pregnancy.

Synonym

Nodular theca-lutein hyperplasia of pregnancy.

Epidemiology

Patients with luteoma of pregnancy are typically in their third or fourth decade and multiparous, and 80% are Black [2056,2364,2788].

Clinical features

Most patients are asymptomatic, and the tumour is usually found incidentally at term during caesarean section or postpartum tubal ligation [2788]. Exceptionally, a pelvic mass is palpable or obstructs the birth canal. Approximately 25% of patients are hirsute or show signs of virilization. Elevated levels of plasma testosterone and other androgens may be observed.

Macroscopy

The tumours vary from not being macroscopically detectable to over 20 cm. In

one series the medium diameter of the tumour was between 6-7 cm [2056]. The sectioned surface is circumscribed, solid, fleshy and red to brown. In approximately one-half of cases the lesions are multiple and at least one-third are bilateral.

Histopathology

There is a diffuse proliferation of polygonal, eosinophilic cells that contain little or no lipid [2364]. The nuclei are round and contain prominent nucleoli. Follicle-like spaces may be present. Mitotic figures may be frequent. The tumour cells were found to be positive for alpha-inhibin, CD99, cytokeratin and vimentin [2242].

Differential diagnosis

The differential diagnosis includes lipid-poor steroid cell tumours, metastatic melanoma and corpus luteum of pregnancy. Steroid cell tumours occurring during pregnancy may present a difficult differential diagnosis; however, the typical clinical setting of luteoma of pregnancy would be an unusual presentation for a steroid cell tumour. The presence of follicle-like spaces or multiple nodules favours the diagnosis of luteoma of pregnancy. In contrast to luteoma of pregnancy, steroid cell tumours that have a high mitotic rate are likely to exhibit significant nuclear atypia. Metastatic melanoma may be multinodular and contain follicle-like spaces; however, the presence of melanin pigment in some cases and positive stains for S-100 protein and often HMB-45 and Melan A and negative stains for alpha-inhibin would confirm the diagnosis.

sis. Corpus luteum of pregnancy has a central cavity and a convoluted border. It is composed of granulosa-lutein and theca-lutein layers and contains hyaline or calcified bodies. Multinodularity of the tumour or bilaterality favour luteoma of pregnancy.

Histogenesis

Luteoma of pregnancy appears dependent on beta-human chorionic gonadotropin for its growth based on its clinical presentation at term and regression following the conclusion of the pregnancy.

Prognosis and predictive factors

The tumours regress after the conclusion of the pregnancy.

Uncommon tumour-like conditions associated with pregnancy

Many tumour-like conditions occur during or subsequent to a pregnancy including ovarian pregnancy, hyperreactio luteinalis, large solitary luteinized follicle cyst of pregnancy and puerperium [513], granulosa cell proliferations of pregnancy [524], hilus cell proliferation of pregnancy and ectopic decidua [505].

Stromal hyperthecosis

Definition

Stromal hyperthecosis consists of hyperplastic ovarian stroma containing clusters of luteinized stromal cells.

Epidemiology

The lesion typically occurs in women in the late reproductive years and beyond.

Clinical features

The patients may present with endocrine manifestations including virilization, obesity, hypertension and decreased glucose tolerance and may have elevated levels of plasma testosterone. Bilateral ovarian enlargement is typically encountered at laparotomy.

Macroscopy

The ovaries are typically enlarged and may measure up to 7 cm in greatest dimension [2605]. With rare exceptions, the lesion is bilateral. The sectioned surface is predominately solid and white to yellow. Multiple superficial cysts may be present in premenopausal women.

Histopathology

On histological examination hyperplastic stroma is present containing clusters of luteinized stromal cells. In premenopausal women the outer cortex may be thickened and fibrotic with luteinized follicle cysts as is observed in the polycystic ovary syndrome.

Differential diagnosis

The lesion is distinguished from the closely related condition of stromal hyperplasia by the absence of luteinized stromal cells in the latter. Polycystic ovarian disease typically occurs in younger women and is less distinctly virilizing. The ovaries are more cystic than is typically seen in stromal hyperthecosis.

Somatic genetics

Patients with acanthosis nigricans and masculinization (HAIR-AN syndrome) all had the histologic findings of pre-

menopausal hyperthecosis in their ovaries [729].

Prognosis and predictive factors

The lesion is usually treated by oophorectomy, and the postoperative course is uneventful.

Stromal hyperplasia

Definition

A tumour-like proliferation of ovarian stromal cells without the presence of luteinized stromal cells.

Clinical features

Patients are typically menopausal or early postmenopausal. It is much less frequently estrogenic or androgenic than stromal hyperthecosis, and patients may occasionally have obesity, hypertension or abnormal glucose metabolism [2605].

Macroscopy

Ill defined white or pale yellow nodules that sometimes coalesce are present in the cortical or medullary regions of the ovary or both. In extensive cases the ovaries may be enlarged, and the architecture replaced.

Histopathology

The medullary and to a lesser extent the cortical regions are replaced by a nodular or diffuse densely cellular proliferation of small stromal cells with scanty amounts of collagen. In advanced cases the ovarian architecture is completely replaced and follicle derivatives are not observed.

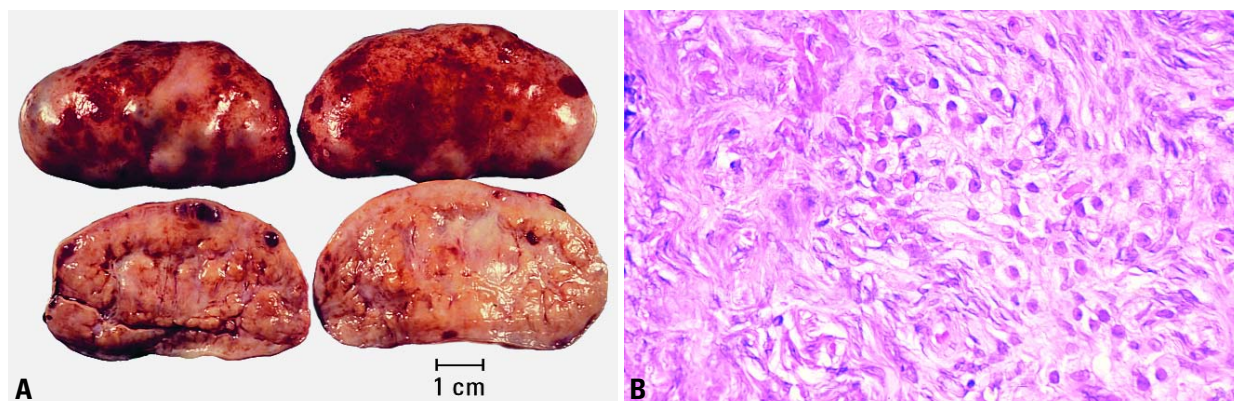


Fig. 2.125 Stromal hyperthecosis. **A** The ovaries are enlarged and solid with a smooth external surface and have a multilobulated sectioned surface with a few follicle cysts. **B** Note the clusters of luteinized stromal cells within hyperplastic ovarian stroma.

Differential diagnosis

Stromal hyperplasia is distinguished from stromal hyperthecosis by the absence of luteinized stromal cells. It is distinguished from low grade endometrial stromal sarcoma by the presence of spindle shaped rather than round or oval stromal cells and the absence of mitotic figures or spiral arterioles.

Fibromatosis

Definition

Fibromatosis is a tumour-like enlargement of one or both ovaries due to a non-neoplastic proliferation of collagen-producing ovarian stroma.

Clinical features

The patients range from 13-39 years with an average of 25. The typical presentation is menstrual irregularities, amenorrhea or, rarely, virilization [3214].

Macroscopy

The ovaries range from 8-14 cm and have smooth or lobulated external surfaces. The sectioned surface is typically firm and grey or white, and small cysts may be apparent. About 80% of cases are bilateral.

Histopathology

There is a proliferation of spindle-shaped fibroblasts with a variable but usually large amount of collagen. Foci of luteinized stromal cells as well as oedema may be present. Ovarian architecture is maintained, and the fibrous proliferation surrounds follicle derivatives. Nests of sex cord type cells are present in some cases [384]. Most cases show diffuse involvement of the ovaries, but occasional cases are localized.

Differential diagnosis

The lesion is distinguished from fibroma in that the latter is usually unilateral and does not incorporate follicular derivatives. However, it differs from ovarian oedema in that oedema in the latter is massive and fibrous proliferation is not observed. It differs from stromal hyperplasia in that the latter does not produce abundant collagen and is usually unilateral. The sex cord type nests may superficially resemble a Brenner tumour, but the latter shows transitional cell features and replaces the ovarian architecture.

Prognosis and predictive factors

The lesion does not spread beyond the ovaries.

Massive ovarian oedema

Definition

Formation of a tumour-like enlargement of one or both ovaries by oedema fluid.

Epidemiology

The age range is 6-33 with an average of 21 years [3214].

Clinical features

Most patients present with abdominal pain, which may be acute, and a pelvic mass. [3214]. Others may present with abnormal uterine bleeding, hirsutism or virilization. Elevated levels of plasma testosterone and other androgens may be observed. At laparotomy ovarian enlargement, which is usually unilateral, is encountered, and torsion is observed in approximately one-half of the patients.

Macroscopy

The external surface is usually white and opaque. The ovaries range from 5-35 cm in size with an average diameter of 11 cm [3214]. The sectioned surface typically exudes watery fluid.

Histopathology

On histological examination oedematous, hypocellular ovarian stroma is present, and the ovarian architecture is preserved. The outer cortex is thickened and fibrotic. Clusters of luteinized stromal cells are present in the oedematous stroma in a minority of cases, especially those that have endocrine symptoms.

Differential diagnosis

The differential diagnosis includes an oedematous fibroma and Krukenberg

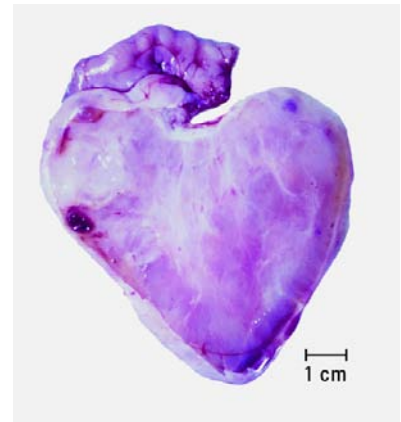

Fig. 2.126 Massive ovarian oedema. The sectioned surface of the ovary was moist and exuded watery fluid.

tumour. The diffuse nature of the process and the preservation of ovarian architecture are unlike an oedematous fibroma, which is likely to be a circumscribed mass. The distinction from Krukenberg tumour is based on the absence of signet-ring cells and the typically unilateral mass, whereas Krukenberg tumours are bilateral in the vast majority of cases. It is important for the pathologist to recognize this lesion at the time of intraoperative consultation so that fertility may be maintained in these young patients.

Histogenesis

In many cases the oedema is due to partial torsion of the ovary insufficient to cause necrosis [1390,2463].

Prognosis and predictive factors

The lesion is usually treated by oophorectomy, and the postoperative course is uneventful.

Other tumour-like conditions

A wide variety of other conditions can, on occasion, mimic an ovarian neoplasm. Those not associated with pregnancy include follicle cyst, corpus luteum cyst, ovarian remnant syndrome, polycystic ovarian disease, hilus cell hyperplasia, simple cyst, idiopathic calcification, uterus-like adnexal mass [48], spenicogonadal fusion, endometriosis and a variety of infections.

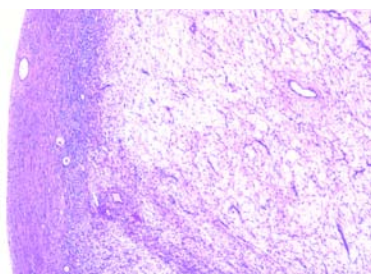


Fig. 2.127 Massive ovarian oedema. A portion of the ovarian cortex remains around an oedematous ovary.

Lymphomas and leukaemias

L.M. Roth
R. Vang

Malignant lymphoma

Definition

A malignant lymphoproliferative neoplasm that may be primary or secondary.

Epidemiology

Although unusual, ovarian involvement is more frequent than that of other sites in the female genital tract {1588}. The peak incidence of ovarian involvement by lymphoma is in the fourth and fifth decades, although it may occur at any age. Ovarian involvement by lymphoma may either be primary or secondary; however, the latter is much more common.

Clinical features

Lymphoma rarely presents clinically as an ovarian mass, and in most cases it is only one component of an intra-abdominal or generalized lymphoma {483}. An exception is Burkitt lymphoma, which may account for about one-half of the cases of malignant ovarian neoplasms in childhood in endemic areas {2605}. In such cases involvement of one or both ovaries is second in frequency only to jaw involvement.

Macroscopy

Lymphoma is bilateral in approximately one-half of the cases. The tumours are

large and typically have an intact capsule. The sectioned surfaces are typically white, tan or grey-pink and occasionally contain foci of haemorrhage or necrosis.

Tumour spread and staging

Ovarian involvement by lymphoma is rare and is associated with simultaneous involvement of the ipsilateral tube in 25% of the cases {2119}.

Histopathology

The histological appearance of ovarian lymphomas is similar to that observed at other sites; however, the neoplastic cells tend to proliferate in cords, islands and trabeculae with occasional follicle-like spaces or alveoli and often have a sclerotic stroma {2605}. In some cases ovarian follicular structures may be spared, but in others the entire ovarian architecture is obliterated.

Almost any type of lymphoma may occur in the ovary; however, the most common are diffuse large B-cell, Burkitt and follicular lymphomas {1900,2119}.

Differential diagnosis

Dysgerminoma is the most important and perhaps the most difficult differential diagnosis of ovarian lymphoma, particularly of the large B-cell type, which it may

mimic both macroscopically and histologically {2605,3226}. Careful attention to the appearance of the cell nuclei and immunohistochemical stains for lymphoid markers and placental-like alkaline phosphatase are important in reaching the correct diagnosis. Other tumours that may be confused with lymphoma include granulocytic sarcoma, undifferentiated carcinoma, small carcinoma of the hypercalcaemic type and metastatic breast carcinoma {2605,3226}.

Prognosis and predictive factors

Almost one-half (47%) of the patients with lymphoma who presented with ovarian involvement were alive at their last follow up with a median survival of 5 years {1900}.

Leukaemia

Definition

A malignant haematopoietic neoplasm that may be primary or secondary.

Epidemiology

Ovarian involvement by leukaemia may either be primary or secondary; however, the latter is much more common {428}. A series of primary granulocytic sarcomas of the female genital tract including 7 cases of the ovary was reported {2099}.

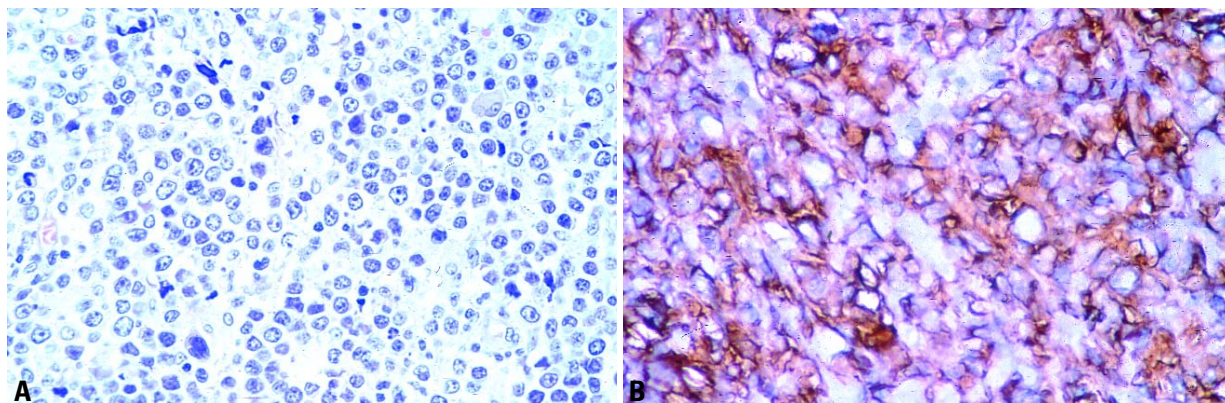


Fig. 2.128 Diffuse large B-cell lymphoma of ovary. **A** Intermediate-power magnification shows a diffuse growth pattern. Nuclei are medium-sized to large and polymorphic. **B** Immunohistochemical stain is positive for CD20.

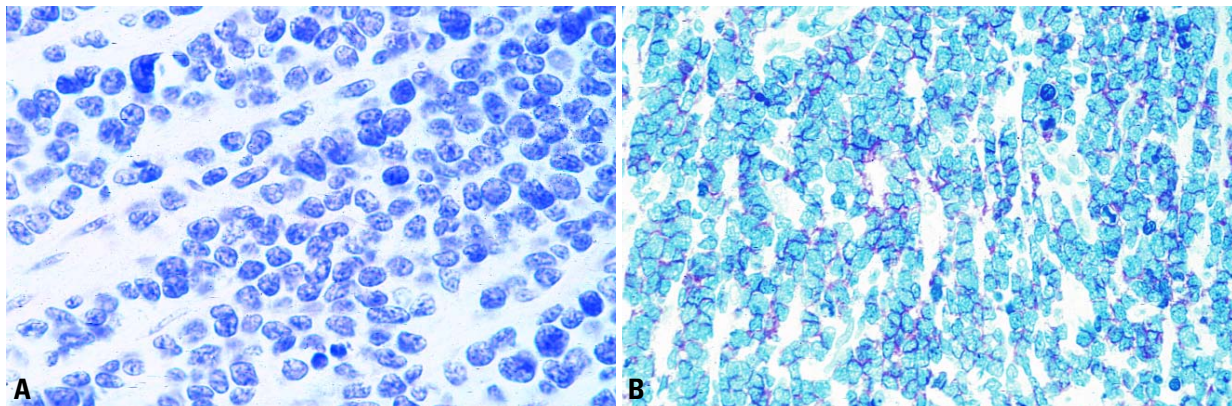


Fig. 2.129 Precursor T-cell lymphoblastic lymphoma of ovary. **A** High power magnification shows small to medium-sized cells with scant cytoplasm, round nuclei and fine chromatin. **B** Immunohistochemical stain is positive for CD99.

Clinical features

Rarely, a patient presents with an ovarian granulocytic sarcoma with or without haematological evidence of acute myeloid leukaemia [2099]. Cases of acute lymphoblastic leukaemia, mostly in children and teenagers, are known to recur in the ovaries during haematological remission.

Macroscopy

The ovarian tumours are usually large and may be either unilateral or bilateral. They are typically solid, soft, and white, yellow or red-brown; occasionally, they may be green, and such tumours have been designated as a "chloroma" [2605].

Histopathology

Granulocytic sarcomas have a predominantly diffuse growth pattern, but sometimes a cord-like or pseudoacinar arrangement of the tumour cells is present focally [2099]. They are usually composed of cells with finely dispersed nuclear chromatin and abundant cyto-

plasm that may be deeply eosinophilic. The identification of eosinophilic myelocytes is helpful in establishing the diagnosis; however, they are not always present.

Differential diagnosis

The most important differential diagnosis is malignant lymphoma. Histochemical stains for chloracetate esterase or immunohistochemical stains for myeloperoxidase, CD68 and CD43 will establish the diagnosis in almost all cases [2099].

Plasmacytoma

Definition

A clonal proliferation of plasma cells that is cytologically and immunophenotypically identical to plasma cell myeloma but manifests a localized growth pattern.

Histopathology

The tumour cells may be mature or immature. The mature type has eccentric nuclei with clumped chromatin, low

nuclear to cytoplasmic ratios, abundant cytoplasm and a prominent perinuclear hof. The immature form is pleomorphic with frequent multinucleated cells.

Clinical findings

Ovarian plasmacytoma is a rare tumour that may present clinically with a unilateral adnexal mass. The 7 reported patients were 12-63 years old [782].

Macroscopy

The tumours were large, and the sectioned surface was white, pale yellow or grey.

Prognosis and predictive factors

One patient developed multiple myeloma 2 years after removal of the tumour.

Secondary tumours of the ovary

J. Prat
P. Morice

Definition

Malignant tumours that metastasize to the ovary from extraovarian primary neoplasms. Tumours that extend to the ovary directly from adjacent organs or tissues are also included in this category. However, most ovarian carcinomas associated with uterine cancers of similar histological type are independent primary neoplasms. General features of ovarian metastasis include: bilaterality, small multinodular surface tumours, extensive extraovarian spread, unusual patterns of dissemination, unusual histological features, blood vessel and lymphatic invasion and a desmoplastic reaction.

Synonym

Metastatic tumours.
The term Krukenberg tumour refers to a metastatic mucinous/signet-ring cell adenocarcinoma of the ovaries which typically originates from primary tumours of the G.I. tract, most often colon and stomach.

Epidemiology

Metastatic tumours to the ovary are common and occur in approximately 30% of women dying of cancer. Approximately 6-7% of all adnexal masses found during physical examination are actually metastatic ovarian tumours, frequently unsuspected by gynaecologists [1587,2605,2980]. The metastasis often masquerades as a primary ovarian tumour

and may even be the initial manifestation of the patient's cancer. Pathologists also tend to mistake metastatic tumours for primary ovarian neoplasms even after histological examination. Carcinomas of the colon, stomach, breast and endometrium as well as lymphomas and leukaemias account for the vast majority of cases [3226]. Ovarian metastases are associated with breast cancer in 32-38% of cases, with colorectal cancer in 28-35% of cases and with tumours of the genital tract (endometrium, uterine cervix, vagina, vulva) in 16% of cases. In recent years attention has been drawn to mucinous tumours of the appendix, pancreas and biliary tract that often spread to the ovary and closely simulate ovarian mucinous borderline tumours or carcinomas [590,1848,2406,3199,3200].

Aetiology

The routes of tumour spread to the ovary are variable. Lymphatic and haematogenous metastasis to the ovaries is the most common form of dissemination [1587,2605,2980]. Direct extension is also a common manner of spread from adjacent tumours of the fallopian tube, uterus and colorectum [3226]. Transtubal spread provides an explanation for some surface ovarian implants from uterine cancers. Neoplasms may also reach the ovary by the transperitoneal route from abdominal organs, such as the appendix [3199]. Embolic spread often produces

Table 2.09
Metastatic tumours to the ovary.

Clues to the diagnosis
1 - Bilaterality (mucinous and endometrioid-like)
2 - Small, superficial, multinodular tumours
3 - Vascular invasion
4 - Desmoplastic reaction
5 - Extensive, unusual extraovarian spread
6 - Unusual clinical history

multiple nodules within the substance of the ovary and commonly is accompanied by prominent intravascular nests of tumour in the ovarian hilum, mesovarium and mesosalpinx.

Clinical features

Signs and symptoms
Ovarian metastases can be discovered in patients during follow-up after treatment of a primary tumour, serendipitously diagnosed during a surgical procedure for treatment of an abdominal tumour or fortuitously found at autopsy. The circumstances leading to the discovery of these metastatic lesions depends on the site of the primary tumour [951,1802]. Ovarian metastasis was detected before the breast cancer in only 1.5% of cases

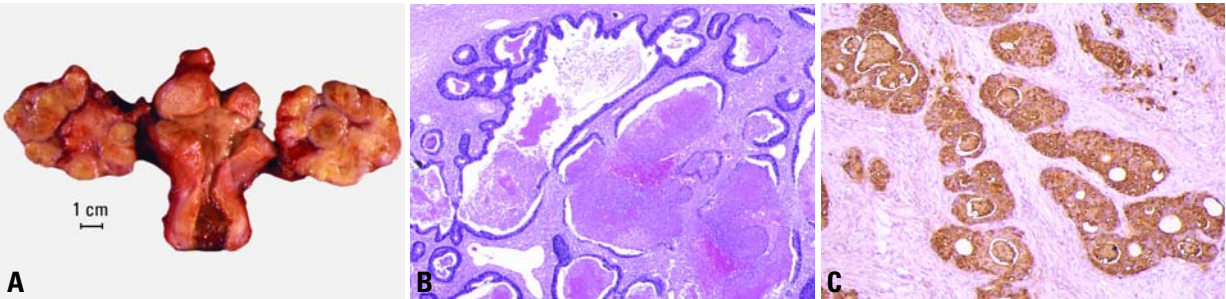


Fig. 2.130 Metastatic colonic adenocarcinoma of the ovaries. **A** The ovaries are replaced by bilateral, multinodular metastases. Note the additional leiomyomas of the corpus uteri (centre). **B** This tumour shows a garland-like glandular pattern with focal segmental necrosis of glands and luminal necrotic debris. **C** Immunohistochemical stain for carcinoembryonic antigen is strongly positive.

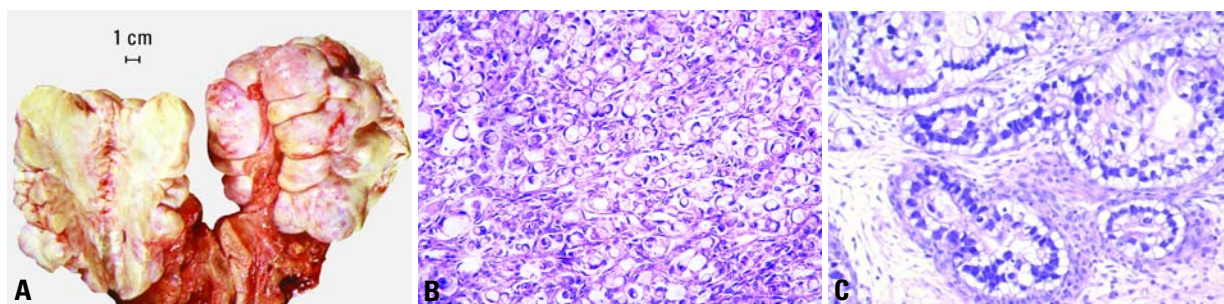


Fig. 2.131 Krukenberg tumour. **A** Note the bilateral nodular ovarian masses of solid yellow-white tissue. **B** Histology shows the typical features of metastatic gastric carcinoma consisting of signet-ring cells within a fibrous stroma. **C** Tubular variant. This mucin-secreting adenocarcinoma resembles a primary ovarian clear cell adenocarcinoma.

[951]. In patients with a gastrointestinal cancer, the ovarian malignant growth was discovered before, or more frequently, at the same time as the gastrointestinal primary [2232]. In 35% of patients with a Krukenberg tumour, the diagnosis of the digestive primary preceded the diagnosis of the ovarian metastasis [1933,2545]. When a patient presents with abdominopelvic symptoms leading to suspicion of an ovarian tumour, the symptoms are non-specific and similar to those of ovarian cancer, i.e. pelvic masses, ascites or bleeding [1598,2545]. Eighty percent of patients with a Krukenberg tumour had bilateral ovarian metastases, and 73% of patients with ovarian metastases from breast carcinoma had extraovarian metastases [951,2545].

Imaging

Several studies have evaluated radiological findings in patients with a Krukenberg tumour [1094,1460]. When imaging features were compared, patients with a Krukenberg tumour more frequently had a solid mass with an intratumour cyst, whereas primary ovarian growths were predominantly cystic [1460]. Magnetic resonance (MR) imaging seems to be more specific than computed tomography scan. Identification of hypointense solid components in an ovarian mass on T2-weighted MR images seems to be characteristic of a Krukenberg lesion, but this aspect is not specific [1094].

Macroscopy

Ovarian metastases are bilateral tumours in approximately 70% of cases [2605].

They grow as superficial or parenchymatous solid nodules or, not uncommonly, as cysts. The size of ovarian metastases is variable even from one side to the other. The ovaries may be only slightly enlarged or measure 10 cm or more.

Site of origin

The frequencies of various sites of origin of secondary ovarian tumours differ among different countries according to the incidence of various cancers therein. Colonic adenocarcinoma probably accounts for most metastatic ovarian tumours that cause errors in diagnosis [1587,2605,3226]. Frequently, the ovarian metastases and the primary tumour are discovered synchronously, or the intestinal tumour has been resected months or years previously.

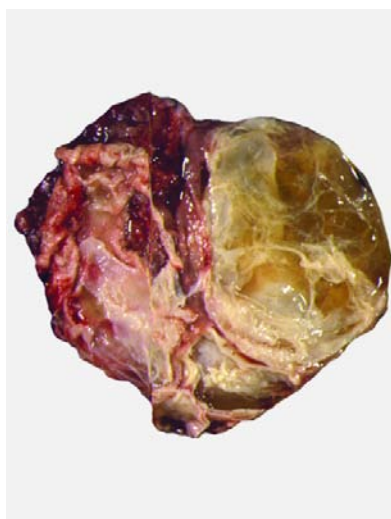


Fig. 2.132 Metastatic adenocarcinoma of colon. Note the solid and cystic mucinous appearance.

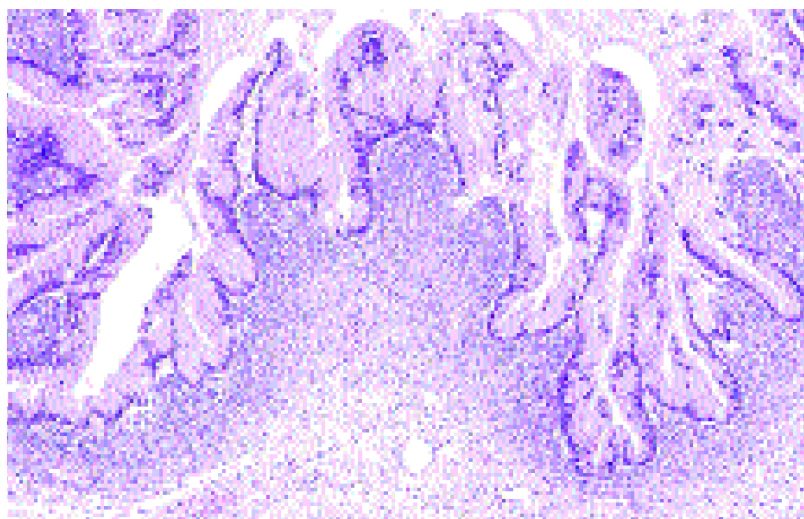


Fig. 2.133 Metastatic adenocarcinoma of pancreas. Note the resemblance to a mucinous borderline tumour.

Occasionally, the colonic adenocarcinoma is found several months to years after resection of the ovarian metastases. Rectal or sigmoid colon cancer accounts for 75% of the metastatic colon tumours to the ovary [1587,2605,3226]. The primary tumour can also be located in the pancreas, biliary tract or the appendix [590,1848,2406,3199,3200].

The Krukenberg tumour is almost always secondary to a gastric carcinoma but may occasionally originate in the intestine, appendix, breast or other sites [367,2605,3226]. Rarely, breast cancer metastatic to the ovary presents clinically as an ovarian mass. A much higher percentage of cases of lobular carcinoma of the breast, including those of signet-ring cell type, metastasizes to the ovary than does ductal carcinoma [1142]. A wide variety of other tumours may metastasize to the ovary.

Histopathology

The identification of surface implants, multinodularity and intravascular tumour emboli are extremely helpful histological clues in the recognition of secondary ovarian tumours that spread through the abdominal cavity and tubal lumen. The histological appearance of the metastases is variable, depending on the nature of the primary tumour.

Differential diagnosis

Sometimes, metastases resemble primary ovarian tumours [2605,2980,3226]. Metastatic colonic adenocarcinoma to the ovary may be confused with primary endometrioid or mucinous carcinoma depending on whether the colonic carcinoma is predominantly mucinous or non-mucinous. Features that help to distinguish colon cancer from endometrioid carcinoma include luminal necrotic debris, focal segmental necrosis of the glands, occasional presence of goblet cells and the absence of müllerian features (squamous differentiation, an adenofibromatous component or association with endometriosis). Also the nuclei lining the glands of metastatic colon carcinoma exhibit a higher degree of atypia than those of endometrioid carcinoma.

Metastatic tumours may also closely resemble primary mucinous ovarian tumours. The former may be moderately differentiated or so well differentiated that they can be mistaken for mucinous borderline or less often benign ovarian

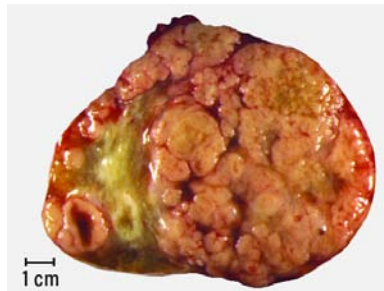

Fig. 2.134 Metastatic lobular carcinoma of the breast. Sectioned surface shows a solid, multinodular tumour.

tumours. Metastatic mucinous tumours to the ovary can originate in the large intestine, pancreas, biliary tract or the appendix. Features supportive of the diagnosis of a metastasis include bilaterality, histological surface involvement by epithelial cells (surface implants), irregular infiltrative growth with desmoplasia, single cell invasion, signet-ring cells, vascular invasion, coexistence of benign-appearing mucinous areas with foci showing a high mitotic rate and nuclear hyperchromasia and histological surface mucin [1614]. Immunostains for cytokeratin 7 and 20 should be used with caution and along with thorough consideration of all clinical information keeping in mind that no tumour shows absolute consistency in its staining with these markers [2183].

Krukenberg tumours must be distin-

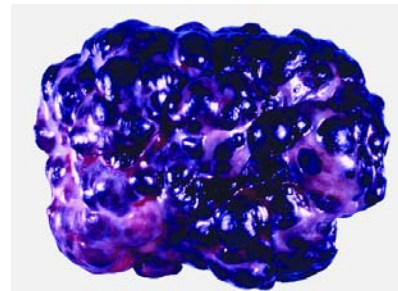


Fig. 2.135 Metastatic malignant melanoma. The ovary is replaced by a multinodular nodular black tumour.

guished from primary and other metastatic ovarian tumours including clear cell adenocarcinoma, mucinous (goblet cell) carcinoid and a variety of ovarian tumours that contain signet-ring-like cells filled with non-mucinous material. Ovarian clear cell adenocarcinoma may have a signet-ring cell component that simulates a Krukenberg tumour; however, the identification of a characteristic tubulocystic pattern, hobnail cells, stromal hyalinization and eosinophilic secretion are helpful in establishing the diagnosis. Mucinous carcinoid, either primary or metastatic, may contain large areas of signet-ring cells; however, teratomatous elements other than carcinoid are usually present in the former.

The tubular variant of Krukenberg tumour, sometimes associated with stro-

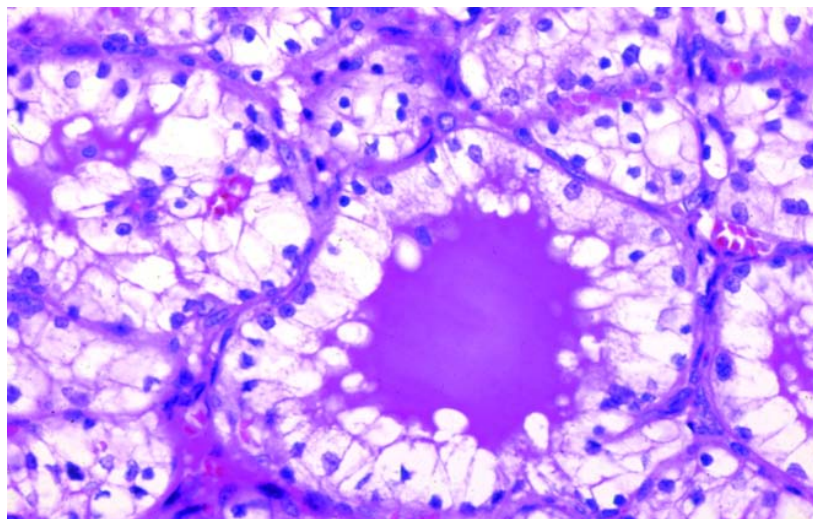


Fig. 2.136 Metastatic renal cell carcinoma to the ovary. Note the tubules lined by cells with abundant clear cytoplasm.

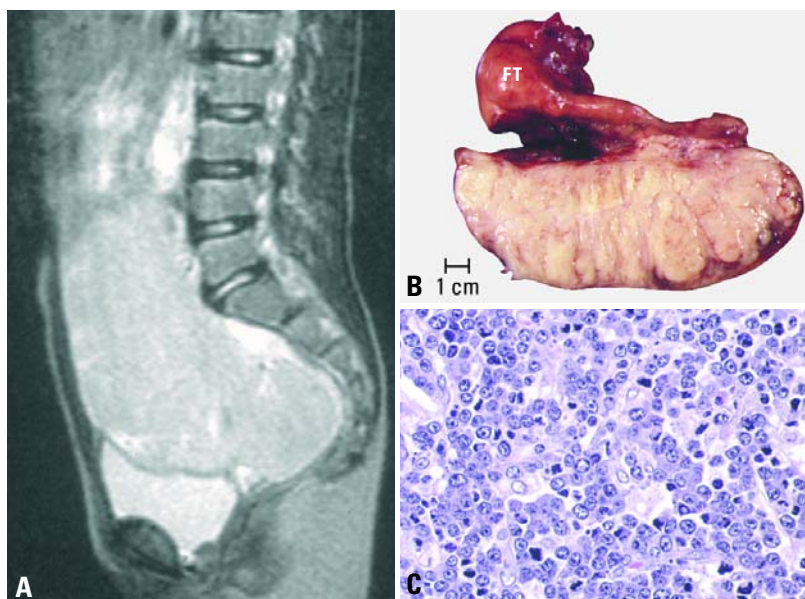


Fig. 2.137 Burkitt-like lymphoma. **A** T2 weighted sagittal computed tomography scan from an 8-year old girl shows a large pelvic mass. **B** Sagittal section of the ovarian tumour shows a homogeneous, pale surface. Notice the enlargement of the fallopian tube (FT). **C** A starry-sky pattern is apparent (B5 fixation).

mal luteinization, can be confused with a Sertoli-Leydig cell tumour. Positive mucicarmine and PAS-stains with diastase digestion are of great value in establishing the diagnosis of a Krukenberg tumour. Occasional Krukenberg tumours may closely resemble fibromas on macroscopic examination and may contain relatively few signet-ring cells. Bilaterality and positive mucin stains facilitate the differential diagnosis.

Distinction between a transitional cell carcinoma of the urinary tract metastatic to the ovary and a primary transitional cell carcinoma may be difficult [2100,3220]. Clinical information may be necessary to resolve the issue.

Renal cell carcinoma rarely metastasizes to the ovaries; however, when it does, it must be distinguished from a primary clear cell carcinoma. The metastatic tumour usually shows a sinusoidal vascular pattern, a homogenous clear cell pattern without hobnail cells, the absence of hyalinized papillae and the absence of mucin [3226].

A *metastatic carcinoid* can be confused

with a primary carcinoid, granulosa cell tumour, Sertoli-Leydig cell tumour, Brenner tumour, adenofibroma or endometrioid carcinoma [2605,3226]. Bilaterality and extraovarian extension are important features of metastatic carcinoid.

In the ovary, *metastatic malignant melanoma* may be confused with primary malignant melanoma; the latter is unilateral and usually associated with a dermoid cyst. When a melanoma is composed predominantly of large cells, it may resemble steroid cell lesions such as steroid cell tumour or luteoma of pregnancy; when it is composed predominantly of small cells it may be confused with a variety of other tumours characterized by small cells [3223]. Positive stains for melanin, S-100 protein, melan A, and/or HMB-45 should establish the diagnosis of melanoma.

Sarcomas may metastasize to the ovary from the uterus or extragenital sites and may occasionally be discovered before the primary tumour [3222]. Metastatic low grade endometrial stromal sarcoma

(ESS) may simulate a primary ovarian sex cord-stromal tumour. Features helpful in their distinction include the presence of extraovarian disease, bilaterality and the characteristic content of spiral arterioles in metastatic low grade ESS. Metastatic epithelioid leiomyosarcoma may have an appearance that simulates the solid tubular pattern of a Sertoli cell tumour.

Although *lymphoma* and *leukaemia* can involve the ovaries simulating various primary tumours, they rarely present clinically as an ovarian mass. In countries where Burkitt lymphoma is endemic, however, it accounts for approximately half the cases of malignant ovarian tumours in childhood. Dysgerminoma is one of the most common and difficult differential diagnoses. The appearance of the cell nuclei is very important. Immunohistochemistry for lymphoid markers and placental alkaline phosphatase are helpful. Carcinoid, granulosa cell tumour or small cell carcinoma can also resemble lymphoma. In patients with acute myeloid leukaemia, ovarian involvement in the form of granulocytic sarcoma ("chloroma") may rarely constitute the initial clinical presentation of the disease. Histological examination reveals a diffuse growth pattern with a prominent "single file" arrangement of the tumour cells. Myeloid differentiation can be demonstrated by the chloroacetate esterase stain. Immunoperoxidase stains for lysozyme, CD68, and LCA are also helpful.

Recognition of the secondary nature of an ovarian tumour depends on a complete clinical history, a careful operative search for a primary extraovarian tumour, and accurate evaluation of the macroscopic and histological features of the ovarian tumour. In rare cases the primary tumour is not found until several years after resection of the ovarian metastases [2605,3226].

Prognosis and predictive factors

Ovarian metastases often represent a late disseminated stage of the disease in which other haematogenous metastases are also found. The prognosis is, therefore, poor.

Peritoneal tumours

S.C. Mok
J.O. Schorge
W.R. Welch
M.R. Hendrickson
R.L. Kempson

Definition

Rare neoplasms with primary manifestation in the abdominal cavity in the absence of a visceral site of origin. Both malignant and benign tumours may occur.

ICD-O code

Peritoneal mesothelioma	9050/3
Multicystic mesothelioma	9055/1
Adenomatoid tumour	9054/0
Desmoplastic small round cell tumour	8806/3
Primary peritoneal carcinoma	8461/3
Primary peritoneal borderline tumour	8463/1

Clinical features

Signs and symptoms

Patients with malignant peritoneal tumours typically present with non-specific manifestations including abdominal discomfort and distension, digestive disturbances and ascites. Less frequently, a palpable mass or pelvic pain may be evident. Benign peritoneal tumours are usually asymptomatic.

Tumour spread and staging

Malignant peritoneal tumours spread primarily by exfoliation of cancer cells from the primary site of origin. Lymphatic and haematogenous dissemination also com-

monly occurs. However, some tumours have been shown to arise from separate intra-abdominal sites and are believed to have a multifocal origin [2576]. The staging involves a combination of radiological and operative findings, but these tumours do not have individual staging systems given their relative infrequency. Most malignant tumours are confined to the abdominal cavity at initial presentation. Benign peritoneal tumours do not metastasize and present as an isolated lesion, often detected at the time of operation for another indication.

Mesothelial tumours

Definition

Benign or malignant mesothelial tumours that arise within the peritoneum.

Peritoneal malignant mesothelioma

Definition

Malignant mesothelial tumours that arise within the peritoneum. Epithelial mesotheliomas may be divided into diffuse, well differentiated papillary and deciduoid types. A less common variant is the sarcomatous mesothelioma, which includes the desmoplastic type.

Epidemiology

Age and sex distribution

Patients with diffuse mesotheliomas are on average 50 years old [1443], and those with well differentiated papillary tumours are 58 [383].

Incidence and mortality

Primary neoplasms of the peritoneum are rare compared to the wide variety of benign and malignant peritoneal müllerian proliferations that women develop. Two clinically benign to low grade proliferations, multicystic mesothelioma and well differentiated papillary mesothelioma are more common than diffuse malignant mesothelioma, and the latter is vastly less common than primary or secondary extraovarian serous carcinoma.

Aetiology

Well differentiated papillary, diffuse epithelial and deciduoid mesotheliomas appear clinically related to asbestos exposure in some cases [383,2633].

Clinical features

The most common presenting features are ascites and abdominal pain [1443].

Macroscopy

The tumour typically consists of multiple nodules measuring <1.5 cm in greatest

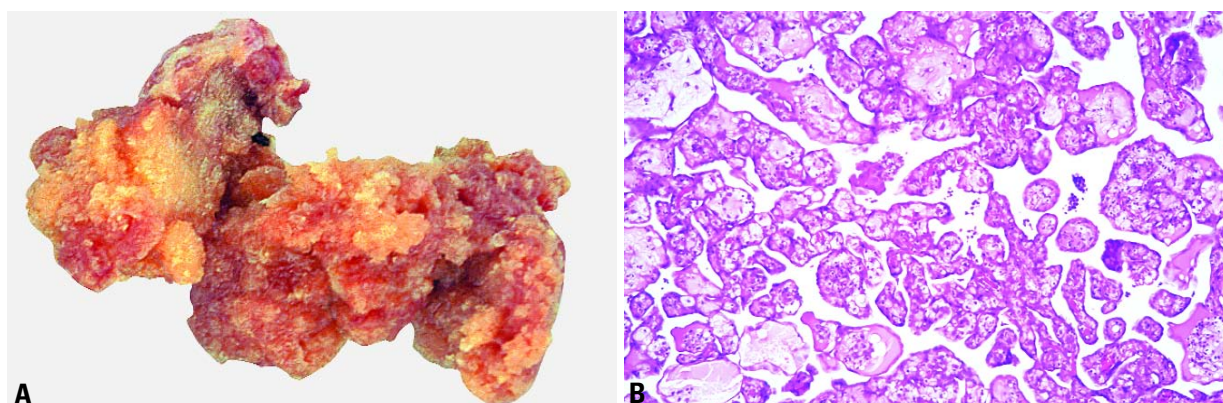


Fig. 2.138 Well differentiated papillary mesothelioma of the peritoneum. **A** Note the distinct papillary architecture of this peritoneal tumour. **B** Papillae with fibrous connective tissue cores are lined by a single layer of uniform mesothelial cells.

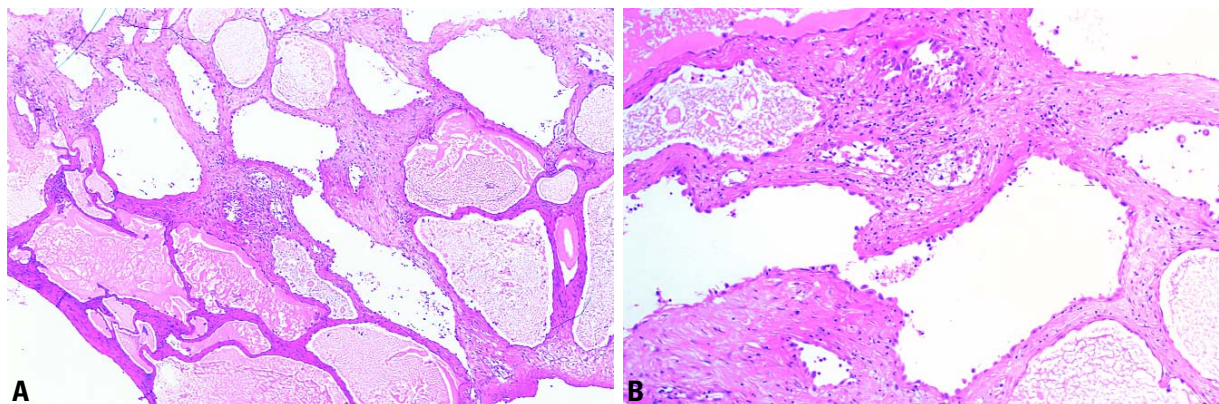


Fig. 2.139 Multicystic peritoneal mesothelioma. **A** Note the multiple cysts lined by mesothelial cells within a fibrous stroma. **B** Irregular cysts are lined by a single layer of cuboidal mesothelial cells.

dimension [1443]. The serosal surfaces have an appearance indistinguishable from the more common peritoneal carcinomatosis or extraovarian carcinoma.

Histopathology

Well differentiated papillary and diffuse malignant mesotheliomas are the most common types. Diffuse and well differentiated papillary mesotheliomas typically are composed of characteristic uniform cells with abundant eosinophilic cytoplasm. Another variant of epithelial mesothelioma is the deciduoid type that simulates an exuberant ectopic decidual reaction [2633]. Sarcomatous mesotheliomas, including the desmoplastic type, also occur but are relatively less common than in the pleura [493].

All well differentiated papillary mesotheliomas have, at least focally, a conspicuous well developed papillary architecture or a tubulopapillary pattern. A single layer of uniform, cuboidal or flattened mesothelial cells with bland nuclear features lines the papillae and tubules. Mitoses are rare. Occasionally, mild cytological atypia is present. Extensive fibrosis associated with irregularity of the glandular elements is common, and such areas may be confused with invasive foci of malignant mesothelioma or adenocarcinoma. Psammoma bodies are present in some cases.

Differential diagnosis

The most reliable indicator of malignancy in these tumours is invasion of fat or of organ walls; however, in small biopsies invasion may be difficult to assess [493]. In the peritoneal cavity entrapment of

benign cells in organizing granulation tissue or between fat lobules is frequent and confusing [493].

Diffuse peritoneal malignant mesotheliomas may macroscopically and histologically show a carcinomatous growth pattern and thus may be confused with primary peritoneal serous papillary neoplasms. In this context immunohistochemical detection of calretinin in the nuclei and Ber-EP4 were the most useful markers, whereas other mesothelial markers had too low a sensitivity for practical use [2113]. Well differentiated papillary mesothelioma lacks the stratification, complex papillae and the mixed cell population of low grade serous neoplasms and lacks the stratification, cytological atypia and mitotic figures of serous carcinoma. Similarly, it lacks the cytological atypia of diffuse malignant mesothelioma and in some instances is localized within the peritoneum. The absence of a history of a prior operation or reactive changes elsewhere and the formation of convincing papillae distinguish well differentiated papillary mesothelioma from mesothelial hyperplasia.

Prognosis and predictive factors

The diffuse epithelial mesotheliomas are typically highly aggressive; however, unlike pleural mesotheliomas, a sizeable number of tumours are relatively indolent [1443]. No morphological features were found to separate the favourable and unfavourable group of these tumours. The well differentiated papillary type is often localized and has a relatively favourable outcome [383,1027] compared to the diffuse peritoneal type.

Multicystic mesothelioma

Definition

A multiloculated cystic mesothelial tumour that typically has an indolent course. In a few instances multiple recurrences occur, and the disease may progress to diffuse malignant mesothelioma [1039].

Synonym

Multilocular peritoneal inclusion cyst.

Epidemiology

The tumour most frequently occurs in young to middle aged women.

Clinical findings

Patients typically present with an abdominal or pelvic mass associated with chronic pain. Occasional tumours are found incidentally at laparotomy.

Aetiology

An association with asbestos exposure has not been reported.

Macroscopy

Typically, the lesion is a large multicystic mass that may be solitary but is more commonly either diffuse or multifocal and consists of multiple, translucent, grape-like clusters of fluid filled cysts delimited by fibrous bands. The individual cysts are usually less than 1.0 cm in diameter but may be up to 20 cm.

Tumour spread and staging

The tumour affects chiefly the pelvic peritoneum, particularly the cul-de-sac, uterus and rectum, and there may be an

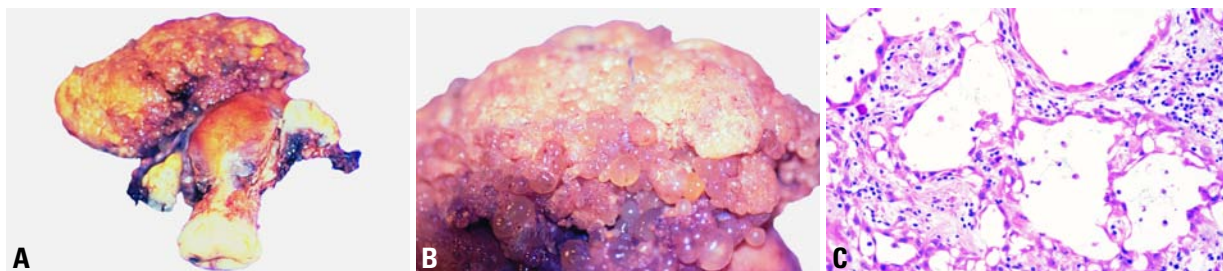

Fig. 2.140 Cystic adenomatoid mesothelioma. **A** The tumour emanates from the uterus. **B** The lesion shows numerous cysts and vesicles in the extrauterine component. **C** Even in the more solid areas of the extrauterine tumour, small cysts dominated microscopically.

abdominal or retroperitoneal component. It grows along the serosa as multiple translucent, fluid-filled cysts. Occasionally, the cysts are solitary or form a free floating mass.

Histopathology

The tumour is made up of multiple cysts lined by one to several layers of flattened or cuboidal mesothelial cells embedded in a delicate fibrovascular stroma [3087]. The lesions typically do not have atypia or significant mitotic activity; however, the occasional presence of cytological atypia may lead to a misdiagnosis of malignancy. Hobnail-shaped cells, foci of mesothelial hyperplasia and, less frequently, squamous metaplasia may be seen. Fibrous septa are usually prominent and may occasionally produce foci with the appearance of an adenomatoid tumour. The stroma may show marked inflammatory change that make it difficult to recognize the nature of the lesion.

Differential diagnosis

The chief differential diagnostic consideration is malignant mesothelioma. Attention to the macroscopic appearance, i.e. multiple cysts rather than solid plaque-like necrotic masses and the usual absence of cytological atypia are sufficient to avoid the error in most cases. Cystic lymphangioma may mimic a multicystic peritoneal mesothelioma, but the cells lining the former do not express keratin.

Histogenesis

The majority of investigators consider this entity to be an unusual type of mesothelial neoplasm that has a tendency to recur locally and may rarely transform into a conventional mesothelioma and show aggressive behaviour [1039,3087]. Some investigators, however, consider the lesion to be a non-neoplastic reactive mesothelial proliferation [2456]. A case termed cystic adenoma-

toid mesothelioma showed a transition from a uterine adenomatoid tumour and is illustrated above.

Prognosis and predictive factors

These tumours have an indolent course, but approximately one-half of cases recur at intervals ranging from 1-27 years [1410,2456]. There are rare instances of multiple recurrences and of transformation into a conventional malignant mesothelioma [1039,3087]. In the largest series 8% of patients with adequate follow up died of tumour [3087].

Adenomatoid tumour

Definition

A benign tumour of the peritoneum originating from mesothelium and forming gland-like structures.

Synonym

Benign mesothelioma.

Epidemiology

Peritoneal origin of this neoplasm is very rare [571].

Macroscopy

Lesions are usually solitary, less than 2 cm in diameter and have a white-grey appearance.

Histopathology

Histologically, multiple, small, slit-like or ovoid spaces are lined by a single layer of low cuboidal or flattened epithelial-like cells. Although adenomatoid tumours can be confused with carcinomas, nuclear atypia is absent or minimal, and mitotic figures are infrequent. Notably, adenomatoid tumours have no significant intracellular mucin, as might be found in neoplasms of müllerian origin. Clinically, they are asymptomatic, and

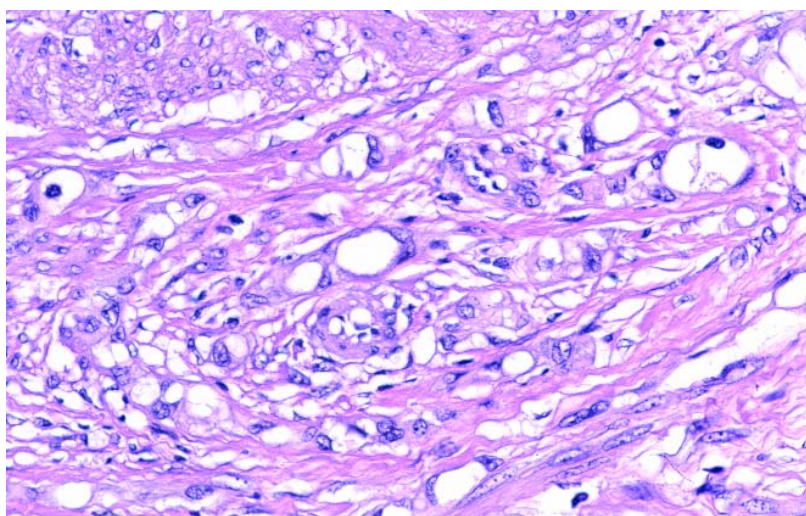


Fig. 2.141 Adenomatoid tumour. Note the small tubules with prominent vacuolization.

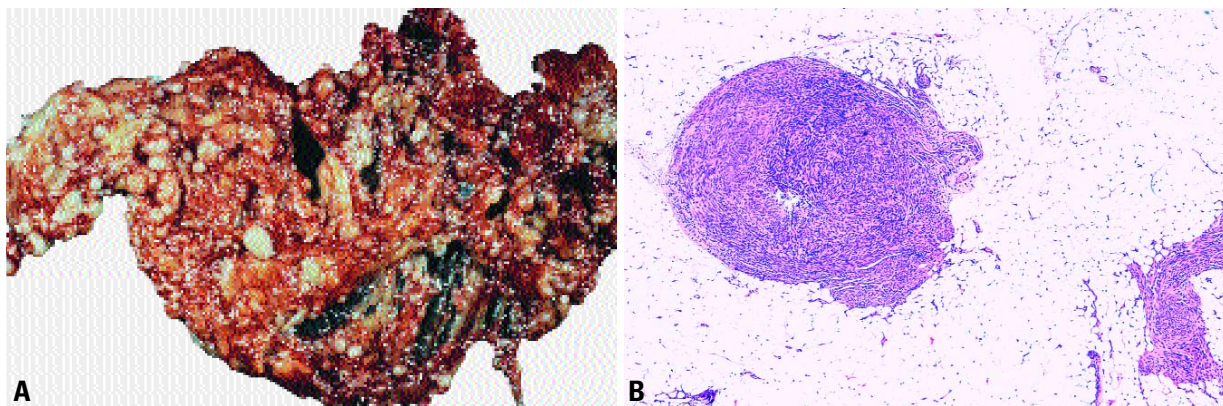


Fig. 2.142 Leiomyomatosis peritonealis disseminata. **A** There are numerous small nodules dispersed throughout the omental surfaces. **B** One of multiple nodules composed of uniform smooth muscle cells in the peritoneum is illustrated.

rarely, if ever, do they recur after adequate excision [506].

Smooth muscle tumour

Leiomyomatosis peritonealis disseminata

Definition

A benign entity in which numerous small nodules composed of smooth muscle are present in the peritoneal cavity.

Synonym

Diffuse peritoneal leiomyomatosis.

Epidemiology

This condition is rare and occurs in women predominantly in their late reproductive years.

Clinical findings

With few exceptions the patients are asymptomatic. The tumours are found incidentally at the time of laparotomy for a leiomyomatous uterus or during caesarean section. At the time of operation the surgeon is likely to be alarmed since this entity may be macroscopically indistinguishable from diffuse carcinomatosis of the peritoneum. Intraoperative consultation is required to establish the diagnosis.

Macroscopy

The tumour typically consists of numerous small, grey-white nodules.

Histopathology

The tumours consist of multiple nodules of well differentiated smooth muscle

arranged in an intersecting pattern. Cases may occur in conjunction with endometriosis or multicystic mesothelioma, and a single case was associated with both conditions [3268].

Prognosis and predictive factors

The tumours may regress spontaneously, and conservative management is appropriate.

Tumour of uncertain origin

Desmoplastic small round cell tumour

Definition

A malignant peritoneal tumour of uncertain origin that shows divergent differentiation and is typically composed of nodules of small cells surrounded by a prominent desmoplastic stroma.

ICD-O code 8806/3

Epidemiology

Desmoplastic small cell tumour (DSRCT) is an extremely rare malignancy that has a strong male predilection and occurs most commonly in adolescents and young adults (mean age 19 years) [984].

Histopathology

Histologically, DSRCT consists of sharply circumscribed aggregates of small epithelioid cells separated by fibrous stroma. The tumour cells typically are uniform with scanty cytoplasm, have indistinct cell borders, and small to medium-sized, round, oval or spindle-shaped hyperchromatic nuclei. Mitotic figures are numerous.

Immunohistochemistry indicates simultaneous divergent expression within the tumour including reactivity for epithelial (keratin, epithelial membrane antigen), neural (neuron-specific enolase) and muscle/mesenchymal (desmin) markers [984].

Histogenesis

These tumours are malignant neoplasms of uncertain histogenesis. Their location primarily in the peritoneum suggests a possible histogenetic relationship with mesothelium. The distinctive immunophenotype suggests multilineage [984,1038].

Somatic genetics

DSRCT has a characteristic reciprocal chromosome translocation t(11;22)(p13;q12) which results in the fusion of the Ewing tumour (*EWS*) gene and the Wilms tumour (*WT1*) gene [900,903]. The resultant chimeric *EWS-WT1* transcript produces a tumour-specific fusion protein that turns the *WT1* tumour suppressor gene into a dominant oncogene [2340]. As a result, cytogenetic analysis can be helpful in excluding the diagnosis of other round cell tumours.

Genetic susceptibility

No familial clustering has been described.

Prognosis and predictive factors

Clinical criteria

Multimodality therapy with induction chemotherapy, aggressive surgical debulking and external beam radiotherapy is advocated for the initial treatment of DSRCT. However, the prognosis is over-

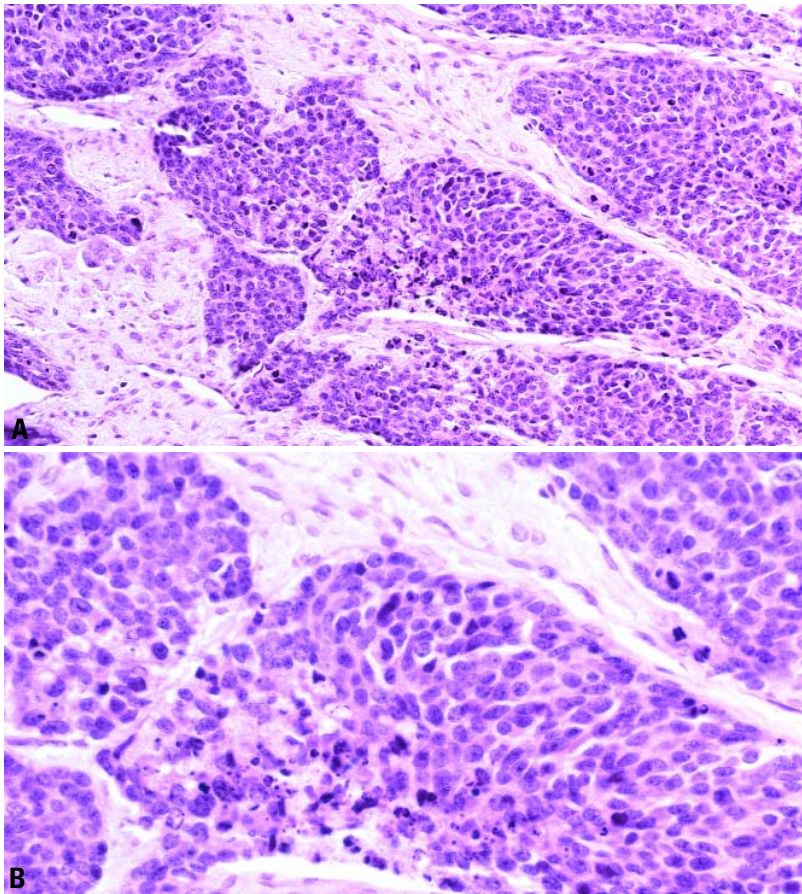


Fig. 2.143 Desmoplastic small round cell tumour of the peritoneum. **A** Irregular islands of tumour cells are separated by fibrous stroma. **B** The tumour cells are small and round with high nuclear to cytoplasmic ratios.

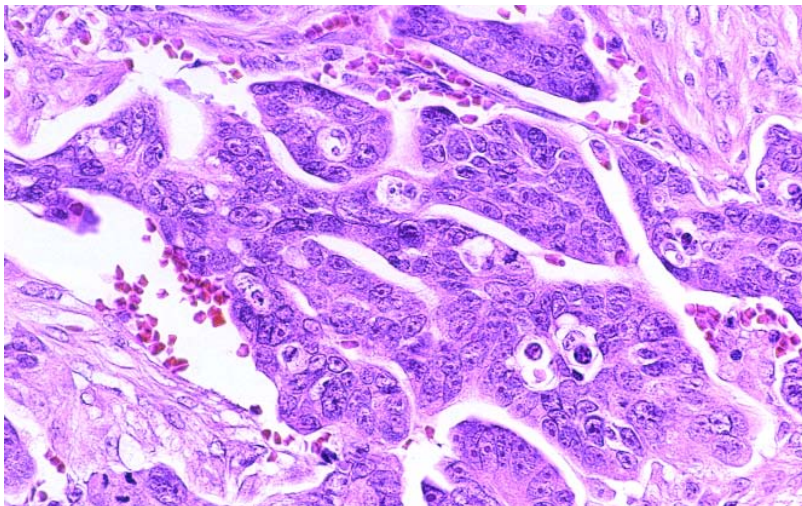


Fig. 2.144 Primary peritoneal serous carcinoma. This serous tumour is composed of papillary fronds and gland-like spaces.

whelmily poor {1038,1547,2310}.

Histopathological criteria

Although the detection rate of micrometastases in bone marrow and body fluids has recently been shown to be higher with reverse transcriptase polymerase chain reaction of the *EWS-WT1* fusion transcript, the clinical significance of molecularly-detectable micrometastases of DSRCT remains unknown {128}.

Primary epithelial tumours of müllerian type

Definition

Primary epithelial tumours of the peritoneum that resemble malignant ovarian surface epithelial-stromal tumours.

Primary peritoneal carcinoma

Definition

A variety of extraovarian neoplasms that histologically resemble surface-epithelial-stromal tumours of ovarian origin.

Epidemiology

Primary peritoneal carcinoma (PPC) occurs almost exclusively in women with a median age of 62 years. The lifetime risk is estimated to be 1 case per 500 women, since approximately 15% of "typical" epithelial ovarian cancers are actually PPCs {2575,2576}.

Histopathology

Histological and immunohistochemical examination of PPC is virtually indistinguishable from epithelial ovarian carcinoma. The most common histological variant is serous adenocarcinoma, but clear cell, mucinous, transitional cell and squamous cell carcinomas have all been reported to originate from the peritoneum. Rare cases of primary psammocarcinoma of the peritoneum have been described {1001}. The following are required to meet the criteria for PPC:

- (1). Both ovaries must be normal in size or enlarged by a benign process.
- (2). The involvement in the extraovarian sites must be greater than the involvement on the surface of either ovary
- (3). The ovarian tumour involvement must be either non-existent, confined to ovarian surface epithelium without stromal invasion, or involving the cortical stroma with

tumour size less than 5 x 5 mm [2575].

Histogenesis

PPC is believed to develop de novo from the peritoneal lining of the pelvis and abdomen [2575]. It may develop in a woman years after having bilateral oophorectomy [2262]. Some cases have been shown to originate from multiple peritoneal sites, supporting the hypothesis that cells derived from the coelomic epithelium may independently undergo malignant transformation [1954,2575,2576].

Somatic genetics

PPC exhibits a distinct pattern of chromosomal allelic loss compared to epithelial ovarian cancer [176,421,1259]. Overexpression of the *TP53*, *EGFR*, *ERBB2*, *ERBB3*, and *ERBB4* genes has been reported, in addition to loss of normal *WT1* expression [2574,2575]. *TP53* gene mutations commonly occur in PPC, but *KRAS* mutations are very infrequent [965,2575]. PPC *BRCA1* mutation carriers have a higher incidence of *TP53* mutations, are less likely to exhibit *ERBB2* overexpression, and are more likely to have a multifocal disease origin [2575]. This unique molecular pathogenesis of *BRCA*-related PPC is believed to affect the ability of current methods to reliably prevent or detect this disease prior to metastasis [1402].

Genetic susceptibility

Germline *BRCA1* mutations occur in PPC with a frequency comparable to the *BRCA1* mutation rate in ovarian cancer. Although the penetrance is unknown, PPC should be considered a possible phenotype of the familial breast and ovarian cancer syndrome [175]. The multifocal disease origin is thought to explain why PPC has been a common cause of detection failures in familial ovarian cancer screening programs. Screening strategies for these women cannot rely on ultrasonography and CA125 testing to detect early disease [1402].

Prognosis and predictive factors

The staging, treatment and prognosis of PPC are similar to those of epithelial ovarian cancer. Optimal surgical cytoreduction for histological grade 1 and 2

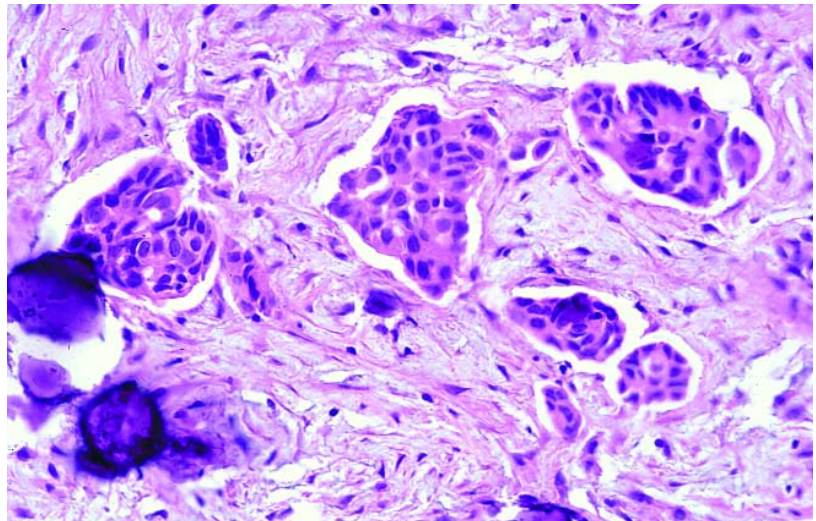


Fig. 2.145 Low grade serous carcinoma, invasive growth pattern. Papillary aggregates of tumour without connective tissue cores are present within retraction spaces surrounded by myxoid fibrous tissue. Note several calcified psammoma bodies on the left.

lesions are associated with longer median survival [2575]. Carboplatin or cisplatin in conjunction with paclitaxel is the current first-line recommended chemotherapy [1436]. The clinical behaviour of psammocarcinoma more closely resembles that of serous borderline tumours than that of serous carcinomas of the usual type. Patients with psammocarcinoma follow a protracted course and have a relatively favourable prognosis [1001].

Primary peritoneal borderline tumours

Definition

A variety of extraovarian neoplasms that histologically resemble borderline surface epithelial-stromal tumours of ovarian origin. By definition minimal or no ovarian surface involvement is present.

Epidemiology

The age in the two largest series has ranged from 16-67 years with a mean of 32 years.

Clinical features

Infertility and abdominal pain are the most common presenting complaints [204]. Occasional patients present with

an abdominal mass. At operation the peritoneal lesions may be focal or diffuse. They commonly appear as miliary granules and may be mistaken for peritoneal carcinomatosis.

Histopathology

The vast majority of cases are serous in type. The histological appearance is similar to that of non-invasive peritoneal implants of epithelial or desmoplastic type [278]. Psammoma bodies are a prominent feature.

Prognosis and predictive factors

The usual treatment is hysterectomy, bilateral salpingo-oophorectomy and omentectomy. Younger patients who desire to maintain fertility may be treated conservatively [278]. The prognosis is excellent. Occasional tumour recurrences with bowel obstruction have been described. Rarely, the patient may develop an invasive low grade serous carcinoma of the peritoneum. Rare deaths due to tumour have been reported.